UNIVERSITY OF CALIFORNIA SAN DIEGO
3 1822 00086 1930

LIBRARY
UNIVERSITY OF
CALIFORNIA
SAN DIEGO

BM

3 1822 00086 1930

WW
13
W874
v. 6

DATE DUE

BIOMEDICAL LIBRARY
UNIVERSITY OF CALIFORNIA, SAN DIEGO
LA JOLLA, CALIFORNIA

DEC 5 1981
DEC 5 1981
NOV 1 0 REC'D
JUL 4 1991
JUL 1 3 REC'D

Digitized by the Internet Archive
in 2007 with funding from
Microsoft Corporation

http://www.archive.org/details/americanencyclop06wood

THE AMERICAN ENCYCLOPEDIA AND DICTIONARY OF OPHTHALMOLOGY

EDITED BY

CASEY A. WOOD, M. D., C. M., D. C. L.

Professor of Ophthalmology and Head of the Department, College of Medicine, University of Illinois; Late Professor of Ophthalmology and Head of the Department, Northwestern University Medical School; Ex-President of the American Academy of Medicine, of the American Academy of Ophthalmology. and of the Chicago Ophthalmological Society; Ex-Chairman of the Ophthalmic Section of the American Medical Association; Editor of a "System of Ophthalmic Therapeutics" and a "System of Ophthalmic Operations"; Mitglied der Ophthalmologischen Gesellschaft, etc.; Ophthalmic Surgeon to St. Luke's Hospital; Consulting Ophthalmologist to Cook County Hospital, Chicago, Ill.

ASSISTED BY A LARGE STAFF OF COLLABORATORS

FULLY ILLUSTRATED

Volume VI — Dioptric System to Exophthalmitis

CHICAGO
CLEVELAND PRESS
1915

Copyright 1915
by the
CLEVELAND PRESS
All Rights Reserved.

INITIALS USED IN VOLUME VI, TO IDENTIFY INDIVIDUAL CONTRIBUTORS

A. A.—Adolf Alt, M. D., M. C. P. and S. O., St. Louis, Mo.
Clinical Professor of Ophthalmology, Washington University, St. Louis, Mo.; Author of *Lectures on the Human Eye; Treatise on Ophthalmology for the General Practitioner; Original Contribution Concerning the Glandular Structures Appertaining to the Human Eye and its Appendages.* Editor of the *American Journal of Ophthalmology.*

A. C. C.—Alfred C. Croftan, Ph. D., M. D., Chicago, Ill.
Author of *Clinical Urinology* and of *Clinical Therapeutics.* Member of the General Staff of the Michael Reese Hospital, Chicago. Formerly Physician-in-chief at St. Mary's Hospital; Physician to St. Elizabeth's Hospital; Physician to the Chicago Post-Graduate Hospital; Pathologist to St. Luke's Hospital. Late Professor of Medicine at the Chicago Post-Graduate College and the Chicago Polyclinic; Assistant Professor of Clinical Medicine, College of Physicians and Surgeons (University of Illinois); Member of the American Therapeutic Society.

A. E. H.—Albert E. Halstead, M. D., Chicago, Ill.
Professor of Clinical Surgery, Northwestern University Medical School; Attending Surgeon, St. Luke's and Cook County Hospitals, Chicago; Consulting Surgeon, Illinois Charitable Eye and Ear Infirmary; Fellow American Surgical Association.

A. S. R.—Alexander S. Rochester, M. D., Chicago, Ill.
Adjunct Eye and Ear Surgeon to St. Luke's Hospital; Member of the Chicago Ophthalmological Society.

B. C.—Burton Chance, M. D., Philadelphia, Pa.
Assistant Surgeon, Wills Hospital, Philadelphia.

C. A. O.—Charles A. Oliver (Deceased).
Joint Editor of *A System of Diseases of the Eye;* Writer of numerous monographs on ophthalmic subjects.

C. E. W.—Lieut.-Col. Charles E. Woodruff, M. D., U. S. Army, Retired.

C. F. P.—Charles F. Prentice, M. E., New York City, N. Y.
President, New York State Board of Examiners in Optometry; Special Lecturer on Theoretic Optometry, Columbia University, New York. Author of *A Treatise on Ophthalmic Lenses* (1886); *Dioptric Formulæ for Combined Cylindrical Lenses* (1888); *A Metric System of Numbering and Measuring Prisms (the Prism-dioptry)* (1890); *The Iris as Diaphragm and Photostat* (1895), and other optical papers.

C. P. S.—Charles P. Small, A. M., M. D., Chicago, Ill.
Late Clinical Assistant, Department of Ophthalmology, Rush Medical College. Author of *A Probable Metastatic Hypernephroma of the Choroid.*

D. H.—D'Orsay Hecht, M. D., Chicago, Ill.
Assistant Professor of Nervous and Mental Diseases, Northwestern Universit Medical School; Consulting Neurologist to the Cook County Institution for th Insane at Dunning, Illinois; Attending Neurologist to the Michael Reese an St. Elizabeth's Hospitals, Chicago.

D. W. G.—Duff Warren Greene, M. A., M. S., M. D., Dayton, Ohi (Deceased).
Formerly Oculist to the National Military Home, St. Elizabeth's Hospital and Ohio Soldiers' and Sailors' Orphans' Home, Xenia, Ohio.

E. H.—Emory Hill, A. B., M. D., Chicago, Ill.
Late House Surgeon, Wills Eye Hospital, Philadelphia; Assistant in Ophthal mology, Rush Medical College (in affiliation with the University of Chicago) Assistant Ophthalmologist to the out-patient department of the Children' Memorial Hospital, Chicago; Assistant Instructor in Ophthalmology, Chicag Policlinic. Member of American Academy of Ophthalmology and Oto Laryngology.

E. K. F.—Ephraim Kirkpatrick Findlay, M. D., C. M., Chicago, Ill.
Assistant Clinical Professor of Ophthalmology, Medical Department, Universit of Illinois; Attending Surgeon of the Illinois Charitable Eye and Ear Infirm ary; Assistant Oculist at the University Hospital.

E. S. T.—Edgar Steiner Thomson, M. D., New York City, N. Y.
Surgeon and Pathologist, Manhattan Eye, Ear and Throat Hospital; Professo of Ophthalmology, New York Polyclinic Medical School and Hospital; Con sulting Ophthalmologist to Perth Amboy and Ossining Hospitals; Member o the New York Academy of Medicine, New York Ophthalmological, and Ameri can Ophthalmological Societies. Author of *Electric Appliances and Their Us in Ophthalmic Surgery,* in Wood's *System of Ophthalmic Operations,* an various monographs.

F. A.—Frank Allport, M. D., LL. D., Chicago, Ill.
Ex-Professor, Ophthalmology and Otology, Minnesota State University; Ex President, Minnesota State Medical Society; Ex-Chairman and Secretary, Oph thalmic Section, American Medical Association; Ex-Professor, Ophthalmolog and Otology, Northwestern University Medical School; Ex-President, Chicag Ophthalmological Society. Author of *The Eye and Its Care;* Co-Author of *A American Text-Book of Diseases of the Eye, Ear, Nose and Throat; A Syste of Ophthalmic Therapeutics,* and *A System of Ophthalmic Operations.* Eye an Ear Surgeon to the Chicago Board of Education and to St. Luke's Hospita Chicago.

F. C. T.—Frank C. Todd, D. D. S., M. D., F. A. C. S., Minneapolis Minn.
Professor of Ophthalmology and Chief of the Division of Eye, Ear, Nose an Throat, University of Minnesota, Medical Department; Chief of Eye, Ear, Nos and Throat Staff, University of Minnesota Hospitals; Eye, Ear, Nose and Throa Surgeon to Hill Crest Hospital; Eye Surgeon to the C. M. & St. P. R. R. Co etc.; Chairman of the Section of Ophthalmology, A. M. A.; President of th Minnesota Academy of Ophthalmology and Oto-Laryngology; Vice-president o the A. M. A., etc. Monographs: *An Exact and Secure Tucking Operation fo Advancing an Ocular Muscle; A Method of Performing Tenotomy which En ables the Operator to Limit the Effect as Required; Mules' Operation; Kera tectasia; Report of a Case with Transparent Cornea; The Implantation of a Artificial Vitreous as a Substitute for Enucleation of the Eyeball; Simpl Method of Suturing the Tendons in Enucleation; Malingering (Pretende Blindness); The Physiological and Pathological Pupil.*

F. E. B.—Frank E. Brawley, Ph. G., M. D., Chicago, Ill.
Co-Author of *Commoner Diseases of the Eye. A System of Ophthalmic Therapeutics* and *A System of Ophthalmic Operations;* formerly voluntary assistant in the Universitaetes Augenklinik, Breslau, and the Royal London Ophthalmic Hospital (Moorfields); Oculist and Aurist to St. Luke's Hospital, Chicago. Editorial Secretary of *The Ophthalmic Record.*

G. C. S.—G. C. Savage, M. D., Nashville, Tenn.
Professor of Ophthalmology in the Medical Department of Vanderbilt University; Ex-President of the Nashville Academy of Medicine; Ex-President of the Tennessee State Medical Society. Author of *New Truths in Ophthalmology* and *Ophthalmic Myology.*

H. B. W.—Henry Baldwin Ward, A. B., A. M., Ph. D., Champaign, Ill.
Professor of Zoology, University of Illinois; Ex-Dean of the College of Medicine, University of Nebraska. Author of *Parasitic Worms of Man and the Domestic Animals; Data for the Determination of Human Entozoa; Iconographia Parasitorum Hominis; Human Parasites in North America.*

H. B. C.—H. Beckles Chandler, C. M., M. D., Boston, Mass.
Professor Ophthalmology, Tufts Medical School, Boston; Senior Surgeon, Massachusetts Charitable Eye and Ear Infirmary.

H. S. G.—Harry Searls Gradle, A. B., M. D., Chicago, Ill.
Professor of Ophthalmology, Chicago Eye and Ear College; Director of Ophthalmic Clinic, West Side Free Dispensary; Member of the Ophthalmologische Gesellschaft, American Medical Association, American Academy of Ophthalmology and Oto-Laryngology.

H. V. W.—Harry Vanderbilt Würdemann, M. D., Seattle, Wash.
Managing Editor, *Ophthalmology,* since 1904; Editorial Staff of the *Ophthalmic Record,* since 1897; Managing Editor, *Annals of Ophthalmology,* 1897-1904. Member American Medical Association; Ex-Chairman Section on Ophthalmology, American Medical Association; Hon. Member, Sociedad Cientifica, Mexico; N. W. Wisconsin Medical Society and Philosophical Society. Fellow American Academy of Ophthalmology and Oto-Laryngology. Author of *Visual Economics* (1901); *Injuries to the Eye* (1912); *Bright's Disease and the Eye* (1912); and numerous monographs on the eye and its diseases. Collaborator on many other scientific books.

J. D. L.—Joseph D. Lewis, A. M., M. D., Minneapolis, Minn.
Ophthalmic and Aural Surgeon to the Minneapolis City Hospital; Consulting Ophthalmic and Aural Surgeon to Hopewell Hospital and Visiting Nurses' Association; Member Minnesota Academy of Ophthalmology and Oto-Laryngology; Fellow American College of Surgeons.

J. L. M.—John L. Moffat, B. S., M. D., O. et A. Chir., Ithaca, N. Y.
Editor *Journal of Ophthalmology, Otology and Laryngology.* Consulting Ophthalmic Surgeon, Cumberland Street Hospital, New York; Member (v.-p. 1905, 1908) American Homœopathic Ophthalmological, Otological and Laryngological Society; Member American Medical Editors' Association; Member (Senior) American Institute of Homœopathy; Senior Member (ex-pres.) New York State Homœopathic Medical Society; Senior Member (ex-pres.) Kings County (N. Y.) Homœopathic Medical Society; Honorary Member N. Y. County Homœopathic Medical Society.

J. M. B.—James Moores Ball, M. D., LL. D., St. Louis, Mo.
Dean and Professor of Ophthalmology, American Medical College of St. Louis, Medical Department of National University of Arts and Sciences. Author of *Modern Ophthalmology; Andreas Vesalius the Reformer of Anatomy.*

M. S.—Myles Standish, A. M., M. D., S. D., Boston, Mass.
Williams Professor of Ophthalmology, Harvard University; Consulting Ophthalmic Surgeon, Massachusetts Charitable Eye and Ear Infirmary and Carney Hospital, Boston, Mass.

P. A. C.—Peter A. Callan, M. D., New York City, N. Y.
Surgeon, New York Eye and Ear Infirmary; Ophthalmologist to St. Vincent's Hospital; Columbus Hospital and St. Joseph's Hospital, New York.

R. D. P.—Robert D. Pettet, Chicago, Ill.
Author of *The Mechanics of Fitting Glasses.*

S. H. McK.—Samuel Hanford McKee, B. A., M. D., Montreal, Que.
Lecturer in Pathology and Bacteriology, McGill University; Demonstrator in Ophthalmology, McGill University; Assistant Oculist and Aurist to the Montreal General Hospital; Oculist to the Montreal Maternity Hospital; Oculist to the Alexandra Hospital; Member of The American Association of Pathologists and Bacteriologists. Author of *The Bacteriology of Conjunctivitis; an Analysis of Three Hundred Cases of Morax-Axenfeld Conjunctivitis; Demonstration of the Spirocheta Pallida from a Mucous Patch of the Conjunctiva; The Pathological Histology of Trachoma,* and numerous other monographs.

T. H. S.—Thomas Hall Shastid, A. B., A. M., M. D., LL. B., F. A. C. S., Superior, Wis.
Honorary Professor of the History of Medicine in the American Medical College, St. Louis, Mo., Medical Dept. of National University of Arts and Sciences. Author of *A Country Doctor; Practising in Pike; Forensic Relations of Ophthalmic Surgery* (in Wood's *System of Ophthalmic Operations); Legal Relations of Ophthalmology* (in Ball's *Modern Ophthalmology); A History of Medical Jurisprudence in America* (in Kelly's *Cyclopedia of American Medical Biography).*

W. C. P.—Wm. Campbell Posey, B. A., M. D., Philadelphia, Pa.
Professor of Ophthalmology in the Philadelphia Polyclinic Hospital and Graduate Medical School; Ophthalmic Surgeon to the Wills, Howard and Children's Hospitals; Chairman of the Pennsylvania Commission for the Conservation of Vision; Chairman of Section on Ophthalmology, College of Physicians, Philadelphia. Editor of American Edition of Nettleship's *Textbook of Ophthalmology;* Co-Editor, with Jonathan Wright, of *System of Diseases of the Eye, Ear, Nose and Throat;* Co-Editor, with Wm. G. Spiller, of *The Eye and the Nervous System.*

W. F. C.—W. Franklin Coleman, M. D., M. R. C. S. Eng., Chicago, Ill.
Professor of Ophthalmology Post-Graduate Medical School; Professor Ophthalmology Illinois School Electro-Therapeutics; Member Chicago Ophthalmological Society.

W. F. H.—William Frederic Hardy, M. D., St. Louis, Mo.
Assistant in Ophthalmology, Washington University Medical School.

W. H. W.—William Hamlin Wilder, A. M., M. D., Chicago, Ill.
Professor and Head of Department of Ophthalmology, Rush Medical College (in affiliation with University of Chicago); Professor of Ophthalmology, Chicago Polyclinic; Surgeon, Illinois Charitable Eye and Ear Infirmary; Ophthalmic Surgeon, Presbyterian Hospital; Member American Ophthalmological Society.

LIST OF LEADING SUBJECTS IN THIS VOLUME

Dioptrometer
Dioscorides
Diphtheria
Diplobacillus
Diplopia
Diploscope
Diptera
Direct smear
Discission
Disinfectants
Dislocation of the eyeball
Disseminated sclerosis, ocular signs of
Distichiasis
Divergence
Donders, Frans Cornelis
Dor, Henri
Douche, eye
Dressings for the eye
Dropper
Drusen
Duddel, Benedict
Dupuytren, Guillaume
Dyer, Ezra
Dyes
Dynamite, ocular injuries from
Dystrophy of the cornea
Ear and eye, relations of the
Ecblepharos
Echinococcus
Eclipse amblyopia
Ectasia, scleral
Ectropion

Eczema, ocular relations of
Egypt, history of ophthalmology in
Electricity in ophthalmology
Electric ophthalmia
Electric ophthalmoscope
Electro-coagulation
Electrodes, ophthalmic
Electrolysis
Electromagnet
Elephantiasis, ocular relations of
Embolism of the central retinal artery
Emmetropia
Emphysema of the orbit
Encephalocele
Endarteritis deformans
Endothelioma of the ocular apparatus
Energy and the eye
Enophthalmos
Entoptic phenomena
Entropion
Enucleation of the eye and its substitutes
Epicanthus
Epilepsy, ocular relations of
Epiphora
Episcleritis
Episcleritis partialis fugax
Ergot
Erysipelas, ocular relations of
Erythremia
Eserin
Ether, ocular relations of
Ethnology of the eye
Ethylene chloride
Evolution of color-vision
Evolution of the human eye
Evolution theory of color-sensation
Evulsion of the optic nerve
Examination of the eye
Exophoria
Exophthalmic goitre

Dioptric system. A refracting system; a lens system; any combination of refractive media.

Dioptrion. (L.) See **Dioptra**.

Dioptrismus. (L.) The employment of a dioptra.

Dioptrometer. The trade name of a patented device for the correction of refractive errors by subjective means. The inventor (Geo. A. Rogers) claims that the instrument possesses the following advantages:



Dioptrometer.

A series of four lenses are tubularly arranged. All of them are of fixed values, and two are in a fixed relative position. The fixed lenses are the ocular and the primary lens, and they are one focal-length of the latter apart. The moving lens is a pair of cross cylinders, axes always at right angles, but rotateable. When together the cylinders have a spherical value and function. Separation of the cylinders introduces a cylindrical value into the series. By the combined rotation of the cylinders, differences of value are located in any desired principal meridians of the eye. The movement of the moving lens, by which the dioptric value of the series is altered at will; and the separation of the cylinders by which a cylindrical value is introduced; enables the operator to place any desired sphero-cylinder value at any axis before the eye. None of these movements disturb the position of the posterior nodal point of the series, which is at the optical center of the eye lens, and remains in that position for all adjustments. Such movements do change the position of the anterior nodal point, and that only. Hence, axial rays pass out of the series at a constant

angle, depending upon the size and distance of the object only—forming the normal angle of vision and maintaining it for every adjustment. The instrument or any adjustment of its lenses, to a spherical, cylindrical or compound value, neither magnifies nor reduces the object, nor can a cylindrical value distort it. As a consequence of the above, standard type sizes and distances are employed, both for distance and near tests. But the lens value obtained is placed at the plane of the optical center of the eye lens, so that it has no thickness. Hence, a value of + 6.62 sph. ⌒ — 4.37 cyl. occupies no more longitudinal space than the weakest lens, such as a + 0.25 sph. To place the above value before the eye in trial case lenses would require four lenses in order to cover the fractional values. Hence, the instrument correction is nearer the true value required, or the specially ground lens to correct the defect, than trial lenses can be. Finally, the control of these values, the mechanical adjustments by which one value is substituted for another, is simple, direct and very precise or exact. The above qualities make the adjustments as quick as desired, robs the work of adjusting a value to the eye of tediousness, takes the "laborious" element out of it. The instrument tests or measures the eye in the existing condition, whether under cycloplegia or not. The periphery of a dilated pupil may be excluded by a perforated disc in the eye cup. The instrument is constructed on a 10 D. basis, which makes all dioptric spaces of one centimeter. It might be constructed on any other basis, and doubtless the binoculars will be on a 12.50 instead of a 10 D. basis, as that shortens the enclosures.

Dioptrometry. DIOPTOMETRY. The art and science of measuring the refraction and accommodation of the human eye.

Dioptron. A speculum for surgeons' use.

Dioptrorganoscope. (F.) DIAPHANOSCOPE. An instrument for illuminating cavities through their walls—a *transilluminator* (q. v.).

Dioptry. DIOPTER. DIOPTRE. Sometimes (improperly) a DIOPTRIC. In *optics*, the unit of refractive power of lenses used by ophthalmic practitioners to correct optical anomalies of vision. Originally in German called Meterlinse (Nagel); subsequently in French named Dioptrie (Monoyer), and later anglicized to Dioptry (Landolt, Knapp, Burnett). It represents the power of a lens whose focal length is one meter=100 centimeters, or 39.37 U. S. standard inches, and which, for convenience in practice, is commonly approximated at 40 inches. As the power of a lens increases, its focal length decreases, and vice versa; or in other words, the power of a lens is in inverse proportion to its focal length. Therefore, in the inch system the power of a lens is expressed through the fractions 1/40, 1/20,

or 1/10 for a lens whose focal length is 40, 20 or 10 inches, whereas in the metric system, for a lens whose focal length is 10, 25 or 50 centimeters, the dioptral power is expressed by 100/10 = 10 D., 100/25 = 4 D., or 100/50 = 2 D., respectively. The metric or *dioptral* system is far more convenient, since the superposition of low powered lenses so frequently resorted to in ophthalmic practice renders it easier to add their powers in dioptries than to add fractions representing their powers in the inch system, which is, therefore, now less frequently used. The focal length of any dioptral lens is readily found through dividing 100 cm. or 40 inches by the given dioptral power. The unit of prismatic power is called prism-dioptry. See **Ophthalmic lenses.**—(C. F. P.) See, also, **Physiological optics.**

Diorama. A spectacular painting, or a connected series of paintings, intended for exhibition to spectators in a darkened room, in a manner to produce by optical illusions an appearance of reality.

Dioscorides, Pedanius. The greatest materia medicist of antiquity. Born about 40 A. D., at Anazarba (later Caesarea Augusta) in Cilicia, of Asia Minor, he became a physician, traveled in Egypt, Italy, Spain, Gaul, Germany, and Greece, and died, it is not known where, but about the year 91.

Familiar with all the medical writers of his time, he was also an independent investigator. His book, "*On Materia Medica,*" is not merely the most complete, it is also the oldest, that has come down to our day. Though devoted to medicines of every conceivable kind, it is especially of interest to modern oculists.

Some of the ocular diseases which Dioscorides mentions, together with a few of the remedies which he recommends in each case, are as follows:

Diseases of the conjunctiva. Pomegranate flowers, sheep's tongue (the plant so-called), hyoscyamus, ironstone, betel, sesame, mouse-ear, and saffron.

Diseases of the lids. Ebony, burnt-sponge, oil of roses, blackthorn (for blepharitis), aloes (for itching). For trachoma: Myrrh, burnt mussel-shell with honey, copper ore, iron ore (hematite), mustard juice, and the juice of unripe grapes.

Diseases of the lachrymal apparatus. The soot from resin and also that from pine cones (for epiphora), decoction of myrtle, with bean meal (for lachrymal abscess).

Diseases of the eyeball. For prolapse of the eyeball, bean meal.

Diseases of the cornea. For ulcers, myrrh; also frankincense and the soot of liquid pitch. For phlyctenules, onion juice. For corneal

scars, cedar, resin of the Ethiopian oil tree, an innocent boy's urine, boiled with honey.

Diseases of the iris. Burnt kernels of dates, bean meal, oxide of iron, lapis lazuli.

Weakness of sight, etc. Oil of bitter almonds, resin of the Ethiopian oil tree, gall of the water scorpion. For glaucoma, saffron-salve. For cataract: petroleum, gall of the water-scorpion, onion juice.

Dioscorides.

Injuries of the eye. Mother's milk, with frankincense, hematite, aloes, bean meal with wine, and lapis lazuli.—(T. H. S.)

Diospyros malabarica. (L.) A species the young leaves and fruits of which are employed in aphtha and ophthalmia.

Diottria. (It.) Dioptry or diopter.

Dioxygen. See **Hydrogen peroxide.**

Dioxyphenylethanolamin hydrochloride. See **Arterenol,** Vol. I, p. 609 of this *Encyclopedia.*

Diphtheria. This well-known infectious disease is characterized by the formation of a membranous, fibrinous, whitish, or grayish deposit at the seat of infection, either occupying the superficial portion of a mucous membrane or forming a membranous coating on a wound. The characteristic lesion generally affects the throat, and often the nasal passages and the larynx; occasionally the conjunctiva, the bladder, or the uterus.

In its many manifestations the disease (including the ocular infections) is due to a peculiar bacillus, first discovered in 1886 and

named the Klebs-Löffler bacillus. For a full account of this micro-organism, see p. 781, Vol. II of this *Encyclopedia*. See, also, the account of **Conjunctivitis, Membranous,** p. 3113, Vol. IV, of this *Encyclopedia*.

The effect of the toxins of diphtheria upon the extrinsic ocular muscles and upon the accommodation is well-known. These pareses are generally temporary, both of cycloplegia, heterotropia and heterophoria, as they usually disappear within a few weeks after the first recovery of the patient from the systemic poisoning. Sometimes, however, the paralysis persists.

The account given by Story (*System of Diseases of the Eye,* Vol. 4, p. 700) of the effect of diphtheritic poison upon the ocular apparatus serves as an introduction to a study of the whole subject. He says that in post-diphtheritic paralysis of accommodation there is a positive increase of hypermetropia,—*i. e.,* during the paralysis the hypermetropia is greater than can be rendered manifest subsequently by complete atropinization. Jacobson (*Archiv f. Ophth.,* Vol. 12, p. 47) has accounted for this by the supposition that the crystalline lens may assume a flatter curvature in long-continued paralysis of the ciliary muscle than it does in the briefer paralysis induced by atropinization. The effects of long-continued atropinization in myopic children support this explanation; but, as Förster observes, the existence of a certain range of accommodation in most of the diphtheritic cases is a fact which tells the other way. Regular astigmatism has also been observed to be present during the diphtheritic cycloplegia, and has been accounted for by the theory of a dynamic lenticular astigmatism, as held by Dobrowolsky and Woinow, which ceases to assert itself during the presence of the paralysis. The lesion of accommodation shows itself at various times, but usually from the third to the sixth week after the commencement of the throat-affection. It generally passes off after a few weeks, but may persist for months. Eserine appears to have some influence in shortening its duration. The acuity of vision also may suffer, probably not from any lesion of the optic nerve or the retina, but possibly from a lenticular astigmatism due to the same cause as the abnormal hypermetropia. The paralysis of accommodation comes on rapidly, and occasionally suddenly. It lasts for weeks or months, and gradually disappears. Most cases seem to occur in from four to six weeks after the onset of the diphtheritis, or in from two to three weeks after its subsidence, and the great majority of patients have been young subjects. The lesion is observed after the mildest and most insignificant attacks as well as after the most severe. It has been stated that retinal

hyperemia is present in some instances, but the vast majority of observers have found the fundus perfectly normal. It is not necessary to have the pharynx affected in order to induce post-diphtheritic paralysis. Diphtheritic inflammation elsewhere is equally potent. Scheby-Buch has collected cases of diphtheritic inflammation in various parts of the body which were followed by paralysis, and in which no pharyngeal diphtheritis was present. Spasm of accommodation has also been observed after diphtheria by Adams (*Trans. Ophth. Soc., U. K.*, Vol. 2, p. 180), but it did not come on till nearly a year after the throat-affection. The external ocular muscles may also be affected. The onset is stated to be extremely sudden, and the lesion rarely persists long. Ptosis has been observed occasionally, and strabismus pretty frequently. Paralysis of both interni or both externi has been recorded. The external rectus seems peculiarly liable to be affected. Remak (*Centralbl. f. prakt. Augenheilk.*, 1886, p. 161) found abducens paresis in ten cases out of one hundred post-diphtheritic ocular lesions. It is possible that the phenomena in some of the cases of the latter group may be accounted for by spasm of convergence. Complete ophthalmoplegia externa has also been observed.

Garcia del Mazo (*Arch. de Oft.*, Vol. 13, p. 354, 1912) records the occurrence of retrobulbar optic neuritis with paresis of the sixth cranial pair following diphtheria in a girl of nine years. Prompt recovery from severe diphtheria followed the use of serum. Early paralysis of the velum palati occurred. Indistinct vision was complained of several weeks later. The visual field was also contracted. Two weeks later both externi were paralyzed. Complete recovery followed.

So far as the *treatment of the diphtheria itself* is concerned, and, of course, the eye symptoms are involved in the general therapy, Croftan (Wood's *System of Ophthalmic Therapeutics*) remarks that, provided antitoxin in the proper dosage is given sufficiently early in this disease complications in diphtheria are exceedingly rare. Many of the local measures that formerly occupied so important a place in the treatment of this disorder have, therefore, become superfluous.

The injection of antitoxin should be made into the subcutaneous tissues, not into the muscles or the fasciæ, nor into any of the superficial cutaneous veins. The best locations for the injections are the external surfaces of the thighs, the abdominal parietes and the upper pectoral region. A proper syringe, sterilized and ready for use, is nowadays furnished with every package of antitoxin. If necessary an ordinary Pravaz syringe can, of course, be employed after steriliza-

tion. Rigid surgical asepsis of the field of the injection should be practised.

The ordinary dose for children under ten years is five hundred units if given on the first day; a thousand units if given on the second day. In children over ten years, and in adults, a thousand units should be given at once and if the symptoms are not very much improved in twenty-four hours, a second thousand should be given and, if necessary, a third thousand at the expiration of another twenty-four hours. If the case is seen in an advanced stage, *i. e.*, on the second or third day of the disease, or if signs of laryngeal involvement have made their appearance, then the first injection of a thousand units should be followed in six to twelve hours, according to the reaction of the patient, by a second thousand units and in another six to twelve hours by a third injection of a thousand units. It will hardly ever become necessary to give more than three thousand units, for after this amount of antitoxin has been injected and the patient fails to show marked improvement, further doses of antitoxin will generally be without effect.

It has been claimed that antitoxin may cause heart failure, paralysis, albuminuria, nephritis and other serious complications. It is true that cardiac failure and paralysis occur as frequently in diphtheria cases that are treated with serum as in cases that are allowed to run their course without antitoxin injections; in fact, some statistics seem to show that more cases of diphtheria (that survive!) develop signs of heart intoxication when treated with antitoxin (See p. 514, Vol. 1, of this *Encyclopedia*) than without; but one is justified in assuming that these cases would have died had they not received the benefit of antitoxin treatment; so that the figures revealed by these statistics in regard to the occurrence of cardiac complication are exceedingly misleading and in no sense justify the conclusion that serum produced the phenomena about the heart and the peripheral nervous apparatus. The albuminuria, renal complications, urticaria, arthritis, etc., that sometimes follow the administration of antitoxin are due to the injection of large quantities of a foreign serum and not of the antitoxin itself; this is borne out by the fact that nowadays when small quantities of a more concentrated serum are used in place of the large quantities of a dilute serum formerly employed, these sequelæ, notably the albuminuria and the skin eruptions, are exceedingly rare. There is, therefore, no compelling reason why antitoxin should not be liberally injected in any case of diphtheria that presents itself.

Other medicines in the overwhelming majority of the cases are

not only superfluous but actually harmful. Antipyretics especially are as a rule dangerous to the heart. In some European clinics inunctions of mercury and silver salts are practised with, it is claimed, good results. The reports are so positive and sound so convincing that as an adjuvant to the antitoxin treatment or as a substitute in case the antitoxin cannot be promptly secured these inunctions may be tried. From 15 to 30 grains (1 to 2 gm.) of unguentum hydragyri, or fifteen to forty-five grains (1-3 gm.) of Credé ointment are rubbed into the skin in different parts of the body for two days; on the third and fourth day the dose of the ointment is increased about one-third. Inunctions should never be made about the region of the neck.

An important paper on the use of the diphtheria antitoxin in acute eye diseases is that of E. Janson (*Klin. Monatsbl. f. Augenh.*, May, 1913). This paper is chiefly directed against the optimistic estimate formed by Darier and others of the French school, of the good effects which may be obtained with diphtheria antitoxin in non-diphtheritic conditions such as hypopyon ulcer, post-operative infection, etc. The possibility of such a paraspecific action is not to be rejected without careful examination. Even in the normal serum there are non-specific bactericidal substances, though in very small quantity. Is it possible that diphtheria antitoxin contains such bodies in quantity sufficient to have an appreciable therapeutic effect? Or is it possible that it acts as a stimulant to the leucocytes and so aids in the defence against bacterial invasion? An increase in the opsonic index towards the staphylococci on the introduction of foreign sera has been described, and moreover some substances (peptone, nuclein, etc.) have been shown to act as leucocyte stimulants, though it has never been proved that any of them has the least practical value in treatment. Darier's idea seems to be that the antitoxin stimulates all parts of the body to throw off antibodies so that almost any enemy within the organism is likely to meet its fate; an idea certainly contrary to the trend of modern opinion, which teaches more and more the strictly specific reaction of the tissues to poisons or foreign substances of all kinds.

The matter, however, is one which should not be left to the uncertain decision of therapeutic enthusiasts or pessimists. Janson has put it to the experimental test by comparing the serological reactions of normal rabbits and of rabbits previously treated with diphtheria antitoxin. He used staphylococcus and pneumococcus (the organisms which chiefly come into the question) except in his agglutination observations, in which the B. typhosus and paratyphosus were more convenient; it was found that as regards agglutination, complement

fixation and the opsonic index, the serum of the treated and untreated animals showed no appreciable difference. The same result was obtained on feeding animals by the mouth with antitoxin. He found also that the antitoxin had no good effect in experimentally produced infections of the cornea or anterior part of the eye.—[George Coats, (*Ophthal. Review,* Sept., 1913.)]

Diplantidian telescope. A telescope showing two co-axial images, and intended for stellar transit work.

Dipleidoscope. An instrument used for determining the meridian transit of a celestial body.

Diplobacillary conjunctivitis. See **Conjunctivitis, Morax-Axenfeld,** p. 3121, Vol. IV of this *Encyclopedia.*

Diplobacillus. The various infections, as well as their bacterial causes proper to this caption, are fully discussed under **Bacteriology of the eye,** not to mention **Conjunctivitis, Morax-Axenfeld** and a number of other headings. It may be added here that the importance of the Morax-Axenfeld diplobacillus is emphasized by Pusey (*Jour. Amer. Med. Assocn.,* July 28, 1906) as a danger to the cornea, while occasioning an annoying conjunctivitis. Its recognition is important, as we have in zinc a specific remedy. The lesion is generally a chronic blepharo-conjunctivitis and the germ is pathogenic for the human eye only. It varies in size, but is usually about 1 micron wide and 2 microns long; the width is fairly constant. When grown on Loeffler's blood serum there is much greater variation than when they are taken fresh from the conjunctiva. The bacilli usually occur in pairs, end on, whether found in secretion or culture, the ends of the bacilli being slightly rounded. Frequently pairs, dividing into four, as indicated by constrictions forming in the middle of each, are met with. Short chains are also found, particularly in cultures. The bacilli stain with all ordinary dyes and are negative to Gram. There is very little conjunctival secretion in a sac infected with this germ, but usually a deposit may be found on the caruncle. The diplobacillus can be grown only at blood temperature and on media containing human body fluids. The serum supplied by the city Boards of Health for diphtheria cultures is an excellent medium. This is liquefied in from sixteen to twenty-four hours, forming holes, the bases of which are moist and without color. After a while these holes become bigger and may coalesce. The bacillus of Petit is the only other germ which can be mistaken for that of Morax and Axenfeld. It liquefies gelatin and grows on all media.

Coats, in his review of the work of Tschistjakoff (*Klin. Monatsbl. f. Augen.,* p. 537, 1911), remarks that it has been known for a consid-

erable time that the Morax-Axenfeld diplobacillus, and its near relation the diplo-bacillus liquefaciens of Petit, are capable of attacking not only the conjunctiva, but also the cornea. Rymowitsch, Rupprecht and Macnab produced iritis by the introduction of cultures within the globe, but Tschistjakoff objects to these experiments in that large quantities of the organism were introduced, so that the conditions little resembled those of a natural infection. By the introduction of small quantities into the anterior chamber he found that a mild iritis was produced which disappeared in three to four days without treatment; in the case of the B. liquefaciens the iritis was rather more severe, and in one case it recurred. Experimental infections of the vitreous produced, with the Morax-Axenfeld bacillus a slight, simple iritis, with Petit's organism a more acute plastic iritis with exudation in the vitreous. As no living organisms could be found within the eye after two or three days it seems probable that the diplo-bacillus is not able to effect a lodgment when accidentally introduced, and this statement is confirmed by the experience of the Freiburg Clinic, which goes to show that when panophthalmitis follows a diplo-bacillary ulcer—a rare occurrence—it is usually due to a mixed infection, not to the penetration of the diplo-bacillus itself. It should be remembered, however, that all animal experiments with the diplo-bacillus suffer from the disadvantage that the organism is not pathogenic in the animal conjunctiva.

Diplobacillus liquefaciens. A bacillus discovered by Petit. See **Bacteriology of the eye.**

Diplochromatism. See **Dichroism.**

Diplococcus. (L.) A coccus consisting of two sharply-defined granules linked together, resulting from segmentation by median constriction. See **Bacteriology of the eye.**

Diplococcus albicans tardissimus. A rare organism discovered by Bumm, said in a few instances to have infected the eye.

Diplococcus citreus conglomeratus. (L.) This is one of the numerous bacteria that are occasionally found as accidental inhabitants of the conjunctival sac and lid edges. It is an aërobic bacterium. An artificial infection of the cornea shows a rather acute, gray infiltration that disappears in a few days.

Diplococcus fluorescens fœtidus. (L.) This coccus is not pathologic, although it is sometimes found in the secretions of the conjunctiva. It is a more frequent visitor to the nasal cavities.

Diplococcus gonorrheæ. The gonococcus of Neisser. See Vol. II, p. 763 of this *Encyclopedia.*

Diplococcus intracellularis meningitidis. MENINGOCOCCUS. Undoubtedly this micro-organism is responsible for some cases of purulent conjunctivitis, and Stephenson urges an examination of pus from the eye for the detection of it. In addition to the account given elsewhere it may be added that Pagenstecher and Wissmann (*Klin. Monatsbl. f. Augenheilk.*, April, 1911, p. 468) report a case of panophthalmitis of metastatic origin in a child, 2½ years old. The patient had developed several attacks of rigidity and opisthotonos. From the vitreous they were able to isolate a Gram-negative diplococcus, which was very similar culturally to, but not identical with, the diplococcus meningitidis intracellularis.

Recently an antitoxin has been prepared (Parke-Davis *Manual*, 1914, p. 34) for the infections of the diplococcus intracellularis. This serum is obtained from the blood of horses immunized against endotoxin and cultures of a number of strains of diplococcus intracellularis meningitidis. In addition to the tests employed for determining its potency, rigid bacteriologic and physiologic tests are employed to establish its safety.

This serum is especially intended for the treatment of cerebrospinal meningitis produced by the diplococcus intracellularis meningitidis. As much depends on an early diagnosis and administration of the serum, it is quite imperatve that when the first lumbar puncture is made for securing the spinal fluid for bacteriological examination the serum should be administered at once; it is not advisable to await the result of microscopic examination. It has been observed clinically that in the presence of the diplococcus intracellularis meningitidis the spinal fluid is more turbid than in other types of infection.

The dose usually administered to young children is 15 cc., while for an adult or in malignant cases 30 cc. (two syringefuls) should be injected at each dose. In severe and fulminant cases a dose of 45 cc. should be injected if indications to the contrary do not exist. The amount of serum injected should be equal in volume to the amount of spinal fluid withdrawn. Four daily injections should be given, and in resistant types of the disease it will be found necessary to give six, eight, or even more injections.

With each package is provided a special needle with a stylet. This needle affords a means for both withdrawing the cerebro-spinal fluid and injecting the serum. The operator should take special pains to see that the stylet is fitted into place so that the bevel corresponds to that of the needle-point before making the lumbar puncture. Rigid asepsis is essential to the successful use of the serum, therefore the same care should be exercised as in a major operation.

The serum is supplied in 15-cc. syringe containers, two in a package, with the special needle and stylet, and two rubber connections for the needle. See, also, **Bacteriology of the eye.**

Diplococcus lanceolatus. See **Bacteriology of the eye.**

Diplococcus pneumoniæ. See **Bacteriology of the eye.**

Diplococcus roseus. (L.) This organism is an atmospheric bacterium and not pathologic. It is occasionally found on the lid-edges and in the conjunctival sac.

Diplocoque. (F.) Diplococcus.

Diplocoria. (L.) That condition of the iris in which there are two pupils.

Diplometer. This is an instrument described by Galezowski (*Recueil d'Ophtalm.*, 1893, p. 111). It is intended for the measurement in degrees of the space between double images in cases of paralysis of the eye-muscles. It is meant to supplement the diplopia-table of Hirschberg, which is best used in the dark-room. The usefulness of this instrument is somewhat impaired by the fact that there is too little extension of the field of vision to be tested, and by the impossibility of controlling the eyes of the patient.

Diplomètre. (F.), n. An instrument for measuring the distance between the pupils.

Diplopia. Diplopy. Double-vision, or the seeing of two images of an object at the same time. It is almost always, but not necessarily, binocular. When, from any cause, one of the extra-ocular muscles fails to act in association with its physiologic fellow (associated antagonist—von Graefe) of the other eye, disturbed binocular vision results, varying from a mere confusion or blurring of the outlines of objects to actual diplopia, provided that binocular vision previously existed, that the false image falls upon the retina, and that there is no associated paralysis of the palpebral levator muscle.

Diplopia results from the fact that images for both eyes of the same external object fall upon dissimilar points of the two retinæ, and are in consequence projected to different parts of the visual field.

Scheiner's experiment, which was used by its author to prove accommodation, shows that *double vision can be had with one eye alone.* The experiment is as follows: Take a piece of cardboard, and with a pin make several holes so close to one another that two or more will occupy a space of less diameter than the pupil. Now place the card in front of one eye, closing the other, and look at a pin placed at the reading distance. It will be seen properly, only somewhat dimmed; if brought nearer or (in myopia) placed farther from

the eye, it will be seen double. Under some pathologic conditions monocular diplopia occurs.—(J. M. B.)

Pollock (*The Lancet,* Aug. 8, 1908) divides all cases of monocular diplopia arising from optical conditions in the anterior segment of the eyeball into two groups—the first with double pupil, and the second where irregular refraction by the cornea and lens produce two or more images on the retina. The first group includes such conditions as a band passing across the pupil, whether congenital in origin or due to inflammatory processes, or to iridodialysis. In these cases diplopia only occurs if the object was out of focus for the eye. Among



Diplopia Test. (Hess.)

Diagram obtained with red glass before the left eye, in paralysis of left superior oblique. Showing primary deviation. The broken lines show patient's projection of the solid black lines.

the second group are a number of varied affections. The lens when dislocated so that the edge passes across the pupil always causes monocular diplopia. Both images are out of focus, the one formed through the margin of the lens is as if myopic, while the other, due to the aphakic condition, resembles hypermetropia. Irregular corneal refraction, from old superficial ulceration, occasionally gives rise to diplopia, but generally of an indefinite character; it is more persistent than some of the other forms. That due to irregular lenticular astigmatism is comparatively rare, except when due to incipient cataract.

The question of the possibility of the retinal origin of monocular diplopia is discussed. Constantin reported a case where diplopia

occurred due to detachment of the retina, the entire upper portion of which was applied to the lower half of the retina, the latter still being in situ and the light thus affecting two portions of the retina at the same time. Pollock's case was that of a woman with double choked disc. She had diplopia in one eye during the early stage of regression of the edema, and he advanced the theory that the diplopia was due to a shrinkage of the retina, which caused slight wrinkling of the layer of rods and cones at the mucula. Light converging to a focus would then affect two neighboring regions and so produce the diplopia.



Diplopia Test. (Hess.)

Diagram obtained with red glass before the right eye in paralysis of left superior oblique. Secondary deviation. Broken lines show patient's projection of solid black lines.

Wölfflin (*Arch. of Ophth.*, Vol. 41, p. 496, 1911) classifies monocular diplopia as follows: First, those without physical basis, as a pseudo fovea. Second, cases with a physical basis, (a) as in Scheiner's test, e. g., traumatic iridodialysis; (b) regular or irregular astigmatism of cornea or lens, this is the most common form; (c) asthenopia, due probably to accommodative changes, the diplopia persists only a few hours; (d) hysteria; (e) cerebral trauma, or trauma altering the centering of the lens; (f) diplopia which occurs in normal eyes as the result of double reflection at the cornea, or decentration of the media.

For the study of diplopia Hess draws four wide green lines, making a rectangle upon a blackboard; the examiner moves a red mark at the

end of a rod over the board crossing the lines. (See the figures.) The patient is provided with a red glass before one eye and a green one before the other, the effect of which is to extinguish each complementary color. He is then asked to follow the red mark as it moves across the board, and to indicate when it crosses one of the green lines. A pair of eyes with normal projection will perceive the mark and the lines in their true positions. An individual with diplopia will see the red mark displaced in relation to the line when the former passes over the latter; on the other hand the red mark will appear to be upon the line when such is not the case; the angular distance between the mark and line will equal the angle of deviation of the faulty visual lines. Control observation can be made by interchanging the red and green glass, when a corresponding field will be obtained under these conditions. A chart of such fields can be readily prepared for permanent reference.

See, also, **Examination of the eye**; as well as **Muscles, Ocular.**

Diplopia, Crossed. In binocular double vision the false image is always in inverse relation to the direction and position of the eye with the paralyzed muscle. Consequently, in, for example, a temporal (external) deviation the false image is nasal (internal); therefore divergent strabismus is characterized by crossed diplopia.

Diplopia, Direct. Homonymous diplopia.

Diplopia incrociata. (It.) Crossed diplopia.

Diplopia larvata. (It.) Masked diplopia.

Diplopia omonima. (It.) Homonymous diplopia.

Diplopia, Paradoxical. This is a term applied by von Graefe to persons affected with convergent strabismus. Tscherning (*Physiologic Optics*, p. 334) says that in patients upon whom he had performed a tenotomy which partly corrected the defect, he found crossed diplopia, although the visual lines were still convergent, and the patients, according to the ordinary rule, should have a homonymous diplopia. Javal was the first to study this phenomenon on patients not operated on. The explanation of this fact is that there is developed what has been improperly named a "vicarious" fovea. The patient has first cultivated the habit of suppressing the image of the strabismic eye; then there is gradually formed an idea of the false position of the strabismic eye; he has learned that an object which forms its image on the fovea of the good eye, forms its image at a point inwards from the fovea of the strabismic eye, and he has learned to localize this image at the place where the object to which it belongs is situated. If we place a prism, apex down, in front of the good eye, the patient sometimes says that he sees only the image of this eye, but generally we

succeed in making him see also the image of the strabismic eye; patients localize it almost on the same vertical line as the image of the good eye, instead of indicating widely separate homonymous images. But the localization of the image is always very uncertain; the patient sometimes says that he sees both images well, but it is impossible to tell which is the image of the strabismic eye.

Diplopia, Physiological. Worth (*Squint,* p. 10) suggests a practical illustration of this phenomenon. If we look steadily at a distant object, and hold a finger about eighteen inches in front of the eyes, the finger will be seen double, the left image corresponding to the right eye, and the right image to the left eye (crossed diplopia). Now look at the finger, and the distant object will appear double, the diplopia this time being homonymous. This "physiological diplopia" must be constantly present, in looking about a room for example, yet we are not ordinarily conscious of seeing double. This customary freedom from diplopia is brought about, not by mental suppression of one of the images, but by the marvelous elasticity of the fusion faculty. Both sets of impressions reach the brain, and, by their combination, assist in our appreciation of the third dimension.

Diplopic. Affected with, or caused by, diplopia.

Diplopie croisée. (F.) Crossed diplopia.

Diplopie homonyme. (F.) Homonymous diplopia.

Diplopie larvée. (F.) Masked diplopia.

Diplopiometer. An instrument for measuring the degree of double vision.

Diplopsis. (L.) An obsolete synonym of diplopia.

Diplosal. Double salicylic acid. This agent is the salicylic ether of salicylic acid, known commercially (*Merck*) under the name of diplosal. Its chemical formula is $OH.C_6H_4.COO.C_6H_4.COOH$.

This formula shows that diplosal is formed by the combination of two molecules of salicylic acid with elimination of one molecule of water. The compound therefore contains more salicylic acid than salicylic acid itself, 100 parts of diplosal corresponding to 107 parts of salicylic acid. Chemically this compound may be regarded as a salol (salicylate of phenol) in which the poisonous phenol is replaced by salicylic acid, or as an acetylsalicylic acid in which salicylic acid takes the place of the inactive acetic acid.

This substance exists as a white crystalline powder, which is devoid of odor and taste; its melting-point is 147° C. It is practically insoluble in cold water and dilute acids; it is very soluble, on the other hand, in dilute alkaline solutions and is gradually decomposed therein with the liberation of salicylic acid.

Diplosal has proved effective in acute and sub-acute articular rheumatism, as well as in influenza, neuralgias, and sciatica—facts which were anticipated from its chemical composition and physical properties. Where profuse perspiration is desired, as in rheumatoid arthritis, it is not so active as acetylsalicylic acid, which has a decided sudorific action. On the other hand, the fact that diplosal does not cause profuse perspiration offers an advantage in the treatment of patients already in a weakened condition.

The dose is from 5 to 15 grains, to be administered three to six times daily; and 45 to 90 grains is the most effective daily dose, without undue risk of causing disagreeable toxic symptoms.

Diploscope. To an instrument intended as a test for binocular vision, Remy of Dijon (*Recueil d'Ophtalm.*, 1901; *Bulletins de la Soc. frs.*

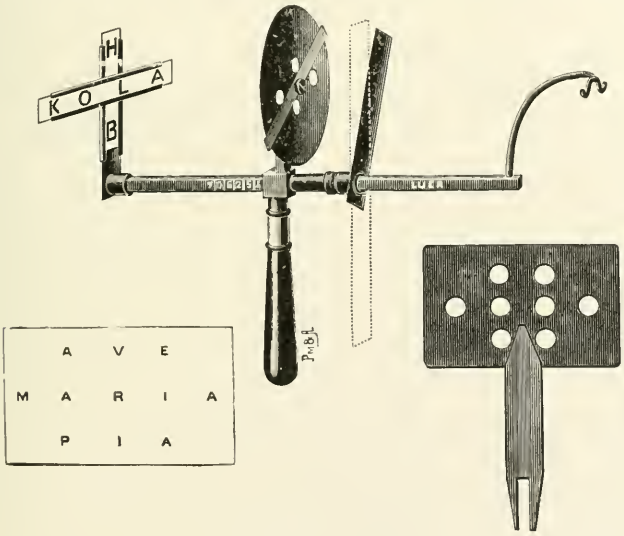

Diploscope of Remy.

d'Ophtalm., No. 29, p. 9, 1911, and several other papers) has given this name. Bishop Harmon furnishes a complete account of it in the *Ophthalmic Review*, Jan., 1909, which is here abstracted in connection with the accompanying figure.

By means of the instrument the inventor claims to obtain:—1. A perfect test for pure binocular vision. 2. A certain means of detecting malingering. 3. A delicate and scientific means of detecting the presence of and estimating the variety and quantity of a squint latent or manifest. 4. A means of training and restoring the vision of a squinting eye which has declined from disuse.

The principle of the diploscope is that of the well-known bar-reading test (q. v.) of Javal. Remy puts a broad bar at the bottom of a tube, the subject looks into the tube and through the spaces on either side of the bar at certain test letters. In Remy's finished instrument the spaces are round holes of which six are provided, but since only two are used at one observation the other four may be neglected.

From a description the reader should be able to set up an improvised instrument, and with that he will be able to test its value. Take a piece of white card 25x10 cm., mark thereon four letters, say KOLA, each 3 cm. square and separated from each other centre from centre by 6 cm.; take a disc of black card 10 cm. in diameter, cut out of it two holes each 22 mm. in diameter, and separated centre from centre by 6 cm. Now fix the test card so as to stand up perpendicular to

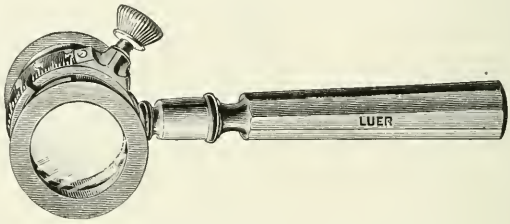

Remy's Double Prism for His Diploscope.

the end of a stick 120 cm. in length; at a point 60 cm. from the test fix a short post perpendicular to the stick and on it pin the black disc with the two holes; turn the disc so that the holes are side by side.

If the experimenter will put the free end of the stick against his nose and look along the stick it is evident he can only see the letters on the test card through the holes in the disc. If he will look at the letters, and he has normal binocular vision, he will see each letter in its proper order, KOLA, and each framed by an image of a hole in the disc—he will see four holes and four letters. Now, on covering one or other eye he will find, that he sees the first and third letter of the test with his left eye, and the second and fourth with his right eye. That, Remy believes, is the best test for binocular vision.

If the experimenter continues to watch the letters his eye-muscles will probably get fatigued; if his eyes diverge he will notice the two central holes approach each other, then fuse, and their letters O and L will be superposed or one will be suppressed; with still greater divergence the letters will be transposed, and appear as KLOA. On the other hand, should his eyes converge, or convergence be produced by a prism, the letters will be transposed and read as OKAL; or if

extreme convergence can be obtained with perception of the letters, then they will be read in the order OAKL.

Lateral deviation can be demonstrated in another way. Replace the four-letter test on the model by a card bearing two of the same sized letters, but one above the other and 102 mm. from centre to centre. Turn the disc round so that the holes take the positions of



Modified Diploscope of Remy.

This device is permanently arranged on a standard instead of the original hand instrument.

XI and V on the clock face. Now look at the letters through the holes: if they are erect one above the other there is no lateral diplopia; if they incline so as to be parallel to the holes then there is convergence; if they incline so as to be perpendicular to the holes then there is divergence. The demonstration with two letters is very good.

As to the utility of the instrument, Harman believes there are certain difficulties that appear to invalidate some of the claims put forward for it. For example, to many it is not easy to follow the direction to look through the holes in the bottom of the tube, even though

they have perfect binocular vision, for they tend to look at the tube and so converge. Others, particularly those who can with facility

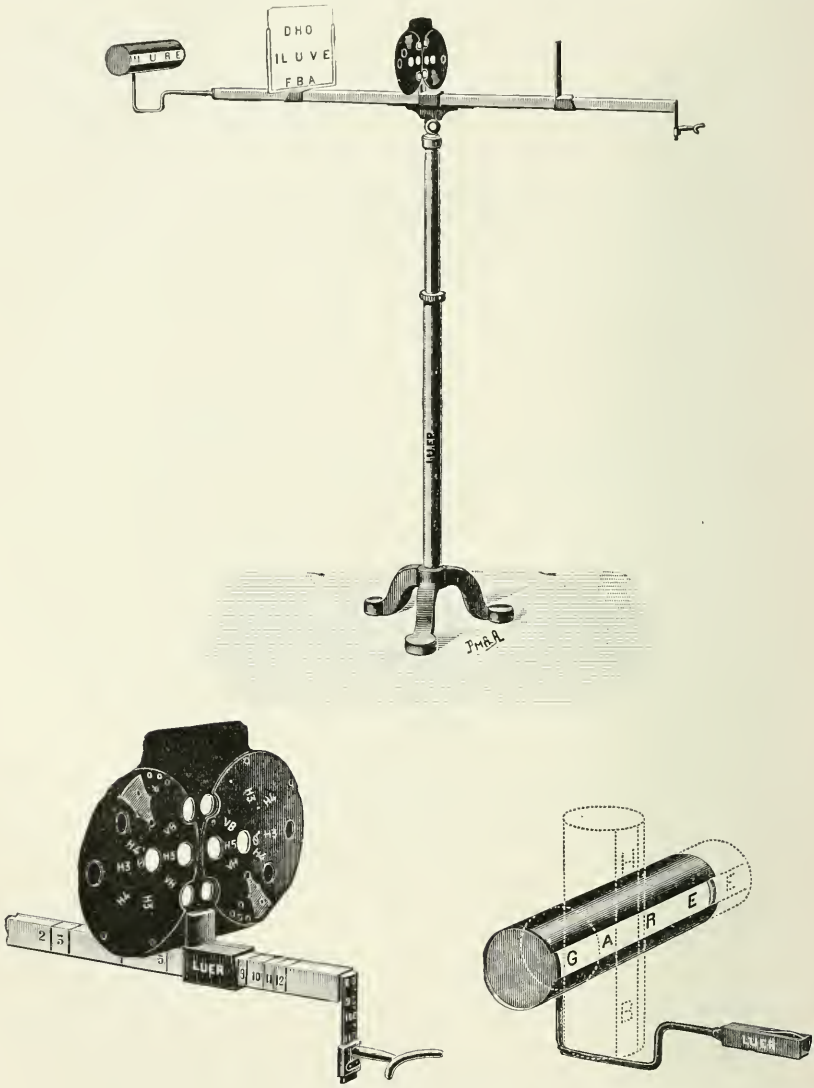

Bourdeaux's Diploscope.

stereoscope prepared pictures without the aid of prisms, tend to stereoscope the two holes and diverge in so doing. For these reasons the test is not a certain trap for malingerers, if a man looks at the tube he may honestly assert he sees no letters clearly.

For estimating with certainty the presence and degree of latent squint it cannot touch the Maddox rod test and the tangent scale. For the purposes of exercising the weakened vision of a squinting eye it cannot compare with the adjustable stereoscopes of Priestley Smith, or of Worth, and the numerous pretty and interesting pictures belonging to them, which go far to attract the children for whom alone these exercises are necessary.

Later Remy used a double prism (see figure), for the production of diplopia, mounted and provided with a handle, and operated somewhat like the Risley prism.

Bjerke (*Arch. d'Opht.*, p. 764, 1909) has further modified Remy's diploscope (which the inventor himself had previously varied by increasing to eight the number of openings for the detection of malingerers) by using a larger screen upon which is placed an arrow and a scale somewhat like the method suggested by Maddox. He uses three diaphragms for the instrument; one with two openings, 30 mm. apart; one with openings 60 mm. apart; and a third with a circular opening, and a larger window, which can be partially closed by sliding shutters, changing the height of the opening. Bjerke also demonstrates the mathematical relation between the various positions of the openings and the apparent positions of objects seen through them.

Diploscope, Bourdeaux's. Although based on the instrument of Remy yet it possesses sufficient additional advantages and improvements to require a separate notice. One of its uses is in the exercise of binocular vision like the Worth amblyoscope (q. v.). The illustration shows the differences between this form of the diploscope and the original device.

Dipper. A holder for lowering a photographic or other plate into a vertical bath.

Dipping. As the Editor (*Toxic Amblyopias,* 1892) pointed out, "dipping" (the habit of rubbing snuff upon the gums with a brush or carrying it to the mouth upon a chewed stick previously dipped in snuff) is mostly confined to the female sex and is said to be prevalent in the southern states. It is probably not a frequent cause of toxic amblyopia. A few cases are, however, on record. Among them is an interesting instance given by Blitz (*Journ. Amer. Med. Assocn.*, Feb. 15, 1890). The patient, a woman, thirty-five years old, from the Tennessee mountains, became so blind that she could barely distinguish light from darkness. She "dipped" a large quantity of snuff daily, but on desisting from the practice and undergoing

treatment, vision was entirely restored in six weeks. See **Toxic amblyopia.**

Diprismatic. Doubly prismatic.

Diprosopia. See **Diprosopus.**

Diprosopos. DIPROSOPUS. In *ichthyology,* having two eyes on one side of the head. *Diprosopa,* a family of fishes having two eyes on one side of the head.

Diprosopus. DIPROSOPOS. A monster characterized by a duplicity of the face and head, frequently associated with hydrocephalus, acrania, defective development of the brain, and spina bifida. The diprosopi have been classified as follows: (1) *Diprosopus diophthalmus.* (2) *Diprosopus distornus.* Fisher has described the first case of diprosopus diophthalmus, or distornus, reported in English. There was anencephalus, a broad duplex nose, two mouths, one oral cavity, two tongues. (3) *Diprosopus triophthalmus.* In this variety there are three eyes, often with other deformities of the face and head, such as acrania, hare-lip, and cleft-palate. (4) *Diprosopus tetrophthalmus.* In this variety the differentiation of the two faces is further advanced, but there are still but two ears. There are present four eyes. (5) *Diprosopus triotus.* In this variety there are usually four eyes and always three ears. (6) *Diprosopus tetrotus.* In this variety, the intermediate stage between diprosopus and dicephalus, there are four eyes and four ears, with considerable duplicity in the cervical region. This is an extremely rare condition in the human race.—(Gould.)

Dip-sector. A form of sextant.

Diptam. DITTANY. DICTAMNUS ALBUS. This plant is one of the constituents of absinthe, and as such may be responsible for some of the (rare) eye-symptoms produced by that noxious drink. See p. 40, Vol. 1, of this *Encyclopedia.*

Diptera. These are two-winged insects, or flies, having two membranous wings with radiating nervures, not folded at rest. The order is a very large one: there are said to be 9,000 European species alone, supposed to be not a twentieth part of the whole number. About 4,000 are described as North American. A few are useful scavengers, but many are injurious insects, and some are great pests. Gnats, mosquitos, gad-flies, blow-flies, bot-flies, tzetzes, etc., belong to this order. It is variously subdivided, one division being into four suborders: the *Pupipara,* which are parasitic, and developed in the body of the parent, as the bee-lice; the *Brachycera,* or ordinary flies; the *Nemocera,* or crane-flies, gnats, midges, mosquitos, etc.; the wingless *Aphaniptera,* or fleas, which are oftener ranked as a distinct order.

Another division is into the suborders *Orthorhapha* and *Cyclorhapha*, according to the character of the metamorphosis: the former with two sections, *Nematocera* and *Brachycera*; the latter with also two sections, *Aschiza* and *Schizophora*.—(*Century Dictionary.*)

A number of these animals and their larvæ are human parasites and are known to attack various parts of the ocular apparatus.

Thomas and Parsons (*Trans. Oph. Soc. Un. Kgdom.*, p. 14, 1909) have reported a case of dipterous larva in the anterior chamber. The patient was a boy aged 2¾, first seen on March 18, 1908. There had been a history of some vague trouble in the left eye for several weeks, but it became definitely red and painful three weeks before coming under observation. There was no history of injury, nor any discharge from the eyes or nostrils, neither had the child suffered from any illness. A thorough examination under an anesthetic showed some slight ciliary injection, cornea perfectly clear, anterior chamber slightly deepened and the aqueous faintly turbid. The iris was discolored and its texture indistinct; the pupil was irregular and partially occluded with brown lymph. Lying on the iris was a small, round, segmented "worm," the head near the angle of the anterior chamber in the lower and outer quadrant, the tail disappearing into the angle in the upper and inner quadrant. The body, curved between these two points, measured about 12 or 13 mm. in length and about 2 mm. in thickness. There appeared to be eight clearly defined segments, not quite so distinct towards the tail; and on magnification a delicate covering of connective tissue could be made out over the body and reflected on to the surface of the iris. No movements were observed.

The eye was enucleated, and microscopical sections were prepared showing, in addition to the presence of the larva, signs of inflammatory exudation in the region of the iris, anterior chamber, and Schlemm's canal.

The sections containing the head of the larva were submitted to Dr. Shipley, of Cambridge, who pronounced it to be the maggot of either a Blow Fly or a Sarcophaga carnaria. This occurrence of a dipterous larva in the human eye appears to be unique, whilst veterinary records contain only one case in which the larva of the Hypoderma was observed in and removed from the eye of a horse.

The mode of entry into the eye is purely conjectural. Both the Blow Fly and the Sarcophagidæ deposit their eggs, or living larvæ, in the nostrils and conjunctival sac, in purulent conditions. From these places the larvæ might work their way through the nasal duct into the lachrymal artery and thence by way of the central retinal or of a

ciliary vessel into the eye. On the other hand, the more direct route from the conjunctival sac through the external tissues of the eyeball is a possibility.

Again the larva may have been an immature form of the Hypoderma lineator of the ox, when its presence in the eye is more easily understood, since these larvæ normally exist in the subcutaneous connective tissue, whilst its recorded presence in the anterior chamber of a horse's eye proves its capability of entering that organ.

Major R. H. Elliot has noted the fairly frequent occurrence of "worms" in the eyes of horses in Madras and the crude methods used for their extraction. The parasites were usually very active, moving in the anterior chamber with great rapidity and sometimes passing into the posterior chamber. They could be easily removed by making a keratome incision and opening it by pressing on its lower lip when the larva was seen to approach its vicinity.

Diradiation. The emission of rays of light, heat, etc., from a heated body.

Directblau. (G.) One of the neutral anilin colors, whose ingestion was at one time thought capable of producing eye symptoms.

Directes Sehen. (G.) Fixation; vision at the fovea.

Direct image. Erect image. This is the image of the fundus oculi as seen directly with the ophthalmoscope, the details of the fundus presenting their natural relations. See **Direct method.**

Direction, Visual. Visible direction. Relative position considered without regard to linear distance. The direction of a point, *A*, from another point, *B*, is or is not the same as the direction of a point, *C*, from another point, *D*, according as a straight line drawn from *B* through *A* and continued to infinity would or would not cut the celestial sphere at the same point as a straight line drawn from *D* through *C* and also continued to infinity. Every motion of a point has a determinate direction; for if any motion from any instant were to lose all curvature, it would tend toward a determinate point of the celestial sphere, which would define its direction at the instant when it ceased to be deflected. It is inaccurate to say that a line has a determinate direction, because a motion along that line has either one of two opposite directions. Yet the word *direction* is sometimes used in a loose sense in which, opposite directions not being distinguished, the direction of a line is spoken of, meaning the pair of opposite directions.—*(Century Dictionary.)*

For a discussion of the laws regulating visible direction, see the *Ophthalmic Record,* Vol. VII, p. 11, 1889, and the same periodical

and volume, pp. 381 and 545, containing articles by G. C. Savage, Harold Wilson and Carl Weiland.

Direct method. DIRECT OPHTHALMOSCOPY. In using the ophthalmoscope (q. v.) by this method the surgeon places his eye close to the patient's eye and looks directly upon the much enlarged and upright details of the interior of the observed eye. In the *indirect* he has the patient removed an arm's length, and usually a convex lens is placed between the patient's eye and the examiner's mirror. The image obtained by this method is inverted and in the air. As the direct method gives a larger magnification, it shows a smaller part of the fundus at one time; it is valuable for the study of minute changes and for the practical estimation of refraction. By the indirect method the portions seen are less magnified, and hence include a larger area. This plan is the better for obtaining a general idea of the condition of the fundus with the location of any lesions. Refraction estimated by this method is both a complicated and an uncertain procedure.—(J. M. B.)

Director-forceps. A name given by N. Bishop Harman (*Ophthalmoscope,* Vol. XI, p. 24, 1913) to a forceps devised by him for making a partial tenotomy of an ocular muscle.

Direct reflex. This is the well-known test for the reaction of the pupil to light. One eye is completely excluded, while the gaze of the other is directed towards a distant object. The open eye is then shaded by the surgeon's extended hand, when its pupil will become considerably larger, returning, after a few slight oscillations, to its original size when the hand is removed.

Direct rotation. Circular motion in the counter-clockwise direction, i. e., such that the inside of the circuit always lies on the left-hand side.

Directschwarz. (G.) One of the neutral analin colors, at one time thought to be responsible for eye symptoms.

Direct smear. This is a useful laboratory device by which discharges, scrapings, etc., from diseased surfaces or tissues are directly and immediately examined on a slide by the microscope. For example, S. H. Browning (*Oph. Review,* April, 1912) has reported the results of the examination of 1,000 cases of conjunctivitis by these means, with cultures as a control test. The method indicates the amount of reliance to be placed on smear preparations. All the cases were examined by direct smears made on slides, and at the same time cultures were made on suitable media. The clinical diagnosis was not made in many of the cases by the surgeon until the bacteriologic findings were reported, so that it has been impossible to compare the clinical

diagnosis with the organism found on bacteriologic investigation. In the cases of ulceration of the cornea which are included in this list, where possible the smears and cultures were made from scrapings from the edge of the ulcer. It is suggested that cultivations should always be made where possible, as this is absolutely essential for the confirmation of the presumptive diagnosis made from the direct smear.

The following table shows the percentage of cases in which the organism was found in the direct smear and subsequently confirmed by culture:

Organism.	Presumptive diagnosis.	Presumptive diagnosis confirmed.
Gonococcus	86.5 per cent.	59.4 per cent.
B. lacunatus (Morax)	59.4 per cent.	32.6 per cent.
B. egypticus (Koch-Weeks bacillus)	86.0 per cent.	41.2 per cent.
Pneumococcus	60.0 per cent.	45.3 per cent.
B. diphtheriæ	61.5 per cent.	61.5 per cent.
B. pneumoniæ	20.0 per cent.	20.0 per cent.
Streptococcus longus	8.0 per cent.	8.0 per cent.

In making the direct smears the following was the technic employed: The lower lid was everted and a platinum loop, sterilized by heating to redness in a flame and allowed to cool, was drawn across the fornix, gathering up any beads of pus or mucus present. The material thus obtained was spread on glass slides in a fairly thin film. Lumps of pus were broken up with the loop and spread evenly. Whenever possible two slides were made, and one stained by carbol methylene blue and the other by Gram's method counter-stained with neutral red. If very little exudate could be obtained, only sufficient for one slide, the film was stained by methylene blue.

Morax-Axenfeld diplo-bacillus, Koch-Weeks bacillus, pneumococcus, bacillus xerosis, gonococcus, staphylocci and Friedländer's pneumobacillus can often be differentiated at once by the microscopic examination alone. It is often difficult or impossible to differentiate the streptococcus from the pneumococcus, and probably many of the organisms in the eye diagnosed as pneumococci are really streptococci, the crucial test being animal inoculation.

In some cases, notably in those of Koch-Weeks infection, the smears gave more useful information, as regards the infecting organism, than the culture. This result is partly due to the difficulty of growing Koch-Weeks bacillus, and partly to the antiseptics so often used in

the eyes of the patient before being seen by the bacteriologist, the antiseptic being present in sufficient concentration to inhibit the growth of the organism on the artificial medium, but not preventing its increase in the living tissues of the conjunctival sac. There were very few cases of gonococcal infection in which the diagnosis could not have been definitely made without resort to cultivation. In some cases the finding in the culture was different to that in the direct smear. This may have been due to errors of observation or interpretation of the microscopic examination. On many occasions a definite diagnosis could not be given upon examination of the direct smear, and some such report as "a Gram-positive diplococcus" was sent out. (*Annals of Ophthalmology,* p. 114, Jan., 1913.)

Direct vision. CENTRAL FIXATION. The perception of an object the image of which falls upon the macula.

Direct vision spectroscope. A series of prisms giving dispersion with a minimum of deviation.

Disassociation of the eyes. The forced employment of monocular vision when binocular sight is possible. For instance, instead of bifocal lenses for presbyopes who have ametropia Percy Dunn (*Ophthalmoscope,* February, 1908) sometimes prescribes the ametropic correction for one eye and the ametropic correction plus the presbyopic correction for the other eye. The patient is then enabled to read with one eye and see at a distance with the other. The author claims that these lenses do not cause discomfort nor confusion, as do bifocals.

However useful the procedure described by Dunn may be in Great Britain the Editor is convinced that it will not do for Americans. When it is impossible or extremely difficult to bring about binocular vision there would seem to be an excuse for the use of one eye only for distance or near work, but the disassociation of the two eyes (in other words, the demoralization of binocular vision) is too serious a matter to permit the statement made in this article to pass uncriticized. It is to be hoped a long time will elapse before the monocle and its congeners become fashionable in this country.

Disc. See, also, **Disk.** A circular, plate-like organ or body. This term is especially applied to the optic papilla of the eye, or entrance of the optic nerve into the eyeball. Its area corresponds, in the field of vision, with the *blind spot.*

Disc, Benham's. A device for eliciting certain color phenomena. One-half of the disc is totally black, while on the other half are arcs of circles of varying sizes. If the disc is made to rotate in one direction, the arcs form concentric circles which present vivid colors in the following order, starting from the middle: red, brown, olive-green, blue.

Rotating the disc in the opposite direction, the order of the colors is reversed. The nature of the phenomena is not yet elucidated.—(C. P. S.)

Dischromatic. DICHROMATIC. Relating to ordinary red and green color-blindness.

Dischromatopsia. DYSCHROMATOPSIA. Color-blindness, in which all colors are seen less distinctly than normal; leading to confusion of near shades of the same color. See **Color-sense and color-blindness.**

Disciform. DISCOID. DISCOIDAL. Resembling a disc or annulus.

Disciform keratitis. DISC-LIKE KERATITIS. Occasionally, in the middle layers of the cornea, a grayish opacity in the form of a disc develops. The superficial layers of the cornea are usually not affected, although small ulcers may appear. Generally a permanent scar remains. Fuchs advises the use of atropine locally, together with the internal medication of any general disease. Dionin locally and in full doses will also be found of use. See, also, **Keratitis disciformis.**

Discission. NEEDLING. Incision or division by a needle, knife or other cutting instrument, of the lenticular capsule or of an intraocular membrane. It is generally applied to operation for after-cataract. See Vol. I, p. 113, of this *Encyclopedia.* It is used in connection with incision of the anterior or posterior capsule in the treatment of juvenile cataract and high myopia (q. v.), or as a preliminary to the removal of senile cataract. See **Cataract, Juvenile**; as well as **Artificial ripening of cataract,** in Vol. I, p. 635, of this *Encyclopedia.*

Although practiced to some extent by the ancients as an aid to depression it is, however, to the merit of modern surgeons that the operation of discission has been established on a firm basis and limited to the removal of soft cataracts.

Banister states: "There are some cataracts which scatter and vanish when the needle is applied to them, because they are not hard and solid to bear the needle, which goeth through them as it would a piece of cheese, whereof, they are commonly called 'cataracta lactea,' because their color and substance resembles milk. That the chirurgeon may meet this inconvenience, he must labor to loose it, pressing it with his needle on either side, for by this means, I have seen, and in the end the party hath recovered his sight."

The same fact had been observed by other surgeons (Read, Maître-Jean) in the early part of the eighteenth century, but it remained for Percival Pott in 1775 to make use of an experience in depression, viz.: that if the capsule of certain cataracts that could not be readily depressed were freely lacerated, they would be absorbed by the action

of the aqueous humor. He was the first to lacerate the capsule as a distinct method of removing cataract of the "mixed kind." He did not attempt anything further in the way of depression, but allowed absorption to remove the lens. He says: "I have sometimes, when I found the cataract to be of the 'mixed kind' not attempted depression, but have contented myself with a free laceration of the capsule, and having turned the needle round and round between my finger and thumb, within the body of the crystalline lens, have left all the parts in their natural situation; in which cases, I have hardly ever known them fail of dissolving so entirely as not to leave the smallest vestige of cataract."

Gleize (1796) in attempting depression (owing to a movement of the patient having lacerated the capsule) had to withdraw the needle. He found that the lens had disappeared on the twentieth day. He then used this method subsequently, and found that soft cataracts disappeared.

Conradi had a similar experience except that in extracting a lens he had made the corneal section and punctured the capsule with a needle; then was obliged to stop. At the end of eight to twelve weeks, the pupil was clear. He operated by discission on a woman of seventy, but at the end of twenty months, no change had taken place in the lens. From these experiences, he proposed discission through the cornea as a regular procedure. He made an opening in the anterior capsule and finally limited the operation to soft and fluid cataracts.

Buchhorn called the procedure keratonyxis.

Langenbeck, Beer and Jäger, Sr., tried discission, the first giving the most favorable reports of the method, while the two last were very unsuccessful. There is no evidence to show that any discrimination was made by any of these three surgeons as to the kind of cataracts to which they applied discission.

Scarpa confined the operation to milky, soft and cheesy cataracts. His method was to make a very free laceration in the anterior capsule and then to cut up the pulpy mass that remained. Contemporaneous with Gleize, Conradi, Langenbeck, Beer, Jäger and Buchhorn, was Saunders, who believed that he had discovered a new process for curing cataracts in children, namely, discission.

He refers to his procedure for curing cataract in children in a letter to the General Committee of the London Infirmary for Curing Diseases of the Eye, in 1809. In a previous report he stated that he had operated successfully on fourteen persons born blind, one of whom was only two months old. He particularly advocated operating on

children when very young, so as to prevent the development of unsteadiness of the eye. His new procedure consisted in freely lacerating the anterior capsule within the area of the pupil and then gently sinking the needle into the body of the lens. This method of operating on children he continued until his death in his thirty-seventh year. He had intended to operate on hard cataracts, but his demise prevented him from following in the footsteps of all his predecessors and finding failure.

If any one surgeon deserves exceptional mention for the early development of discission, that honor belongs to Pott. Possibly Conradi comes next, as he limited the operation to the anterior capsule. His failure to extract after discission led to the disappearance of an opaque lens. The experience gained in this instance, and a failure of discission in aged patients, led him to confine the operation to the young. Saunders comes next in order as he firmly believed he was the first to discover discission for the curing of cataracts in children. He started out right, but he was possessed of the erroneous idea that all cataracts would yield to the new process.

Forms of cataract amenable to treatment by discission. Lenticular opacities occurring in the young, whether congenital or due to disease or traumatism, are to be considered as soft cataracts. It not infrequently happens that congenital cataracts of young persons go slowly on to absorption, so that after a lapse of time, the pupil may be partially clear, or a thickened capsule with little or no lens matter remains.

In passing, it may be pointed out that the traumatic type of cataract disappears much more quickly. The thickened capsule due to cellular proliferation is apt to have calcareous deposits upon it and these prevent a just estimate of how much of the lens remains. This latter class really belongs to the type of secondary cataract and cannot be absorbed as a result of needling. These calcareous deposits are frequently the source of trouble, falling at the time of operation or subsequently, into the anterior chamber, where they are slowly absorbed. They act as foreign bodies while undergoing absorption, and at times set up an irido-cyclitis that may end in the loss of the eye.

Extraction instead of discission in certain forms of soft cataract. If they are of long standing, little or no lens matter remains within the capsule, especially if the cataract be due to accidental traumatism, or to a previous needling. An ordinary discission is of little use in trying to obtain a clear pupil.

The pupil should be fully dilated and a linear extraction done in the following manner: The incision in the cornea should be made above,

about 2 to 4 mm. from the limbus, large enough to permit the exit of the calcareous mass. A cystotome must then be passed into the anterior chamber and the periphery of the anterior capsule freed from the thickened membrane. The aqueous humor, if it has escaped, must be replaced by a normal salt solution. Then introduce into the anterior chamber a closed duck-bill forceps, which must be opened and one blade pushed behind the mass and the other in front; the calcareous mass is then seized and extracted from the eye.

Another method is to insert a de Wecker's scissors instead of the forceps; cut the thickened tissue in two halves, then remove them by the aid of forceps.

In young subjects the sphincter of the pupil contracts very quickly on the escape of the aqueous humor. In order to avoid the necessity for an iridectomy, push the calcareous mass downwards until the upper edge shows free of the pupil, when it can be extracted by either of the above methods. When small pieces of the calcareous mass break off in the manipulation, wash them out with a saline solution by means of an irrigator, as described on page 638, Vol. I, of this *Encyclopedia.*

What is the age limit of discission? As a rule, until the twenty-fifth year the lens is susceptible of absorption when an opening is made in the anterior capsule, permitting the aqueous humor to come in contact with the lens fibres. The nucleus is not generally hard enough to prevent absorption although frequent exceptions are found below this limit, while, occasionally, the lens is absorbed by discission up to the thirty-fifth year and even later. The density of the cortical layers varies considerably even in young subjects, so that it is always a safe procedure to regard the first discission as tentative and not make a large capsular wound, nor to go deeply into the lens substance.

Some surgeons follow von Graefe's precept, viz.:—to make an iridectomy prior to a discission. This is totally unnecessary and inasmuch as discissions are done for the absorption of soft cataracts in young persons, the cosmetic effect ought to be considered and no mutilation done that is not absolutely necessary.

A discission is easy to perform and when carefully done is followed by little, if any, reaction. In the case of infants with congenital cataract, a small capsular opening is quite enough to cause the entire disappearance of the lens in from three to six months. In the type where there is only partial opacity at or about the center of the lens, more than one needling is necessary.

In traumatic cataract, if seen soon after injury, the free use of

atropine with ice-cold compresses should first be employed to prevent too rapid swelling of the lens.

From the eighteenth to the twenty-fifth year, the process of absorption is much slower in all forms of cataract and if the surgeon wishes to depend on discission to remove the cataract he should proceed with caution, and thereby avoid complications.

A second needling should be done from six to eight weeks after the first, if the process of absorption has apparently come to a standstill. The inclination of most operators is to hasten matters and consequently do too much. In this regard, possibly the importunities of older patients form an important factor. However, the question of time with children is of little importance; so that there is no excuse for hastening the process by numerous or extensive needlings.

At the same time, the procedure that entails the least risk is the one that should be chosen in all cases. Possibly an experienced surgeon, who has his patient under full control in a thoroughly equipped eye hospital, with trained assistants, nurses, etc., may take chances and do an extensive laceration of the capsule, but the inexperienced surgeon will be wise if he proceeds more cautiously. In any case, it is not proper to do too much and thereby court disaster, an event which sooner or later is bound to happen even to the most experienced operator.

The instruments required for a discission. The instruments required are an eye speculum, a fixation forceps and a Bowman's needle. The eye speculum and forceps should be put into boiling water for five minutes, the Bowman's needle for a few seconds; then all the instruments should be placed in a shallow tray containing absolute alcohol. Prior to use, they should be washed off in a 4 per cent. solution of boric acid.

Position of the patient for discission. The patient should be reclining upon an operating table. The surgeon when sitting behind the patient has much better control of the eye below, than in any other position, both as to seeing and operating. Local anesthesia is sufficient except in the very young or unruly, where general anesthesia may be necessary. The pupil of the eye to be operated on should be previously dilated ad maximum; the eyelids and eyebrows should be made as sterile as possible. Then insert the eye speculum and flush the field of operation freely with a 4 per cent. boric acid solution. If ordinary daylight is not enough to give a clear view of the cornea, iris and lens, some form of artificial light with a condenser should be used. The surgeon then seizes the globe of the eye below, near the limbus, the eye is rotated downwards and the globe pierced with a

Bowman's needle. The point of entrance should be in the upper-inner (left), or upper-outer (right) quadrant of the eye, two mm. from the limbus, and in sclero-corneal tissue. The flat of the needle is held parallel to the plane of the iris, the point inserted under the conjunctiva, pushed through the sclera into the anterior chamber, the flat of the blade still carried parallel to the plane of the iris to the lower periphery of the capsule. Then the handle of the needle is raised and the cutting edge turned and brought in contact with the capsule, which should be cut by an upward pull of the needle to about three mm., penetrating into the lens fibres about one mm.

The needle is then withdrawn in the same manner that it entered the globe. If the shank of the needle is properly made, the point of entrance is so completely filled that no aqueous escapes. Care is to be exercised that the point of the needle does not become entangled in the iris in passing across the anterior chamber. In either event it is best to postpone operation until another occasion. The eye operated on should be bandaged and the patient put to bed in a darkened room.

Atropine must be used freely (to keep the pupil fully dilated) and continued during the entire period of absorption. If the eye is quiet at the end of the first week, gentle massage of the globe should be done several times daily over the center of the cornea, through the closed eye-lids. This greatly assists the absorption of the cataract. In case of beginning reaction, ice cold compresses should be freely used so as to prevent too free access of blood to the parts.

Dangers and complications of discission. The untoward results liable to follow this operation are: First, glaucoma; second, iritis, irido-cyclitis and panophthalmitis; third, infection.

Glaucoma occurs from this cause in two forms, inflammatory and non-inflammatory. Acute inflammatory glaucoma is the most frequent result of a too free discission, due to the irritation of the rapidly swelling lens substance. It comes on usually within the first five days following the operation. If the attack be severe, with neuralgic pains in the head and globe, accompanied by nausea or vomiting, increased tension of the eye ball and a hazy cornea, a linear extraction should be made without delay, thus permitting the evacuation of the swollen, opaque lens-substance. This operation will dissipate all signs of inflammation, providing the operation is done at the onset of the symptoms.

A non-inflammatory or chronic form that may occur months or even years after operation, is due to the contraction and thickening of capsular bands that pull on the ciliary process. Cutting these bands so as to end the traction, stops the process, and this is best done with

scissors. [I have seen six such cases where iridectomy proved of no avail and relief was only obtained by severing these capsule fibres.—Ed.]

Iritis may occur; likewise, irido-cyclitis may result from too rapid swelling of the lens-substance. These sequelæ are best treated by leeches to the temple, the free use of atropin and hot (from 120° to

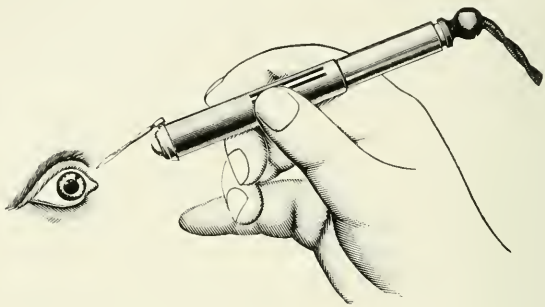

Von Speyr's Discission Apparatus.

130° F.) compresses, continuously applied to the closed eye-lids of the affected eye.

These conditions when severe are difficult to diagnosticate from the signs and symptoms due to infection, especially when the process re-

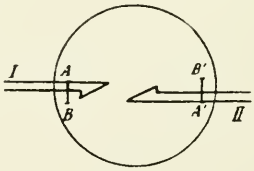

Weill's Method of Introducing Harpoon Needles to Tear Secondary Membranous Cataract.

sults in panophthalmitis. It is, indeed, a question as to what rôle infection plays in post operative uveitis; it is possible that germs may be introduced at the time of the operation.

Needling through the clear cornea. Some operators prefer to make the puncture, especially where a small central incision of the anterior capsule is desired, close to the limbus but within the transparent cornea. The technique differs somewhat from the previous operation in that the length of the cut is less and the point of the needle penetrates the lenticular substance somewhat deeper.—(P. A. C.)

A form of illuminated discission needle resembling that suggested by Chandler (Vol. I, p. 123 of this *Encyclopedia*) and employed in the same fashion, is the apparatus of von Speyr.

Weil (*Zeitschr. f. Augenheilk.*, Feb., 1908) thinks he has found a safe and effective operation for secondary membranous cataract, by using two of Stilling's harpoon needles. These are introduced with the flat side parallel to the iris near the temporal and nasal margins of the cornea, thrust through the center of the membrane, rotated 90 degrees about the axis of the instrument to catch the membrane on the barbs, and then withdrawn until the membrane is sufficiently torn. This tearing is effected without any traction on the zonule or ciliary body. A mark on the handle indicates the direction of the barb. To withdraw them from the eye the needles must be rotated into the position in which they were originally introduced; and the back of the needle pressed firmly against the side of the corneal opening along which it entered. Thus, in the figure, the needles are to be pressed against the ends of the incision A and A^1, allowing the barb to pass out as it entered at B and B^1. Great care and some patience must be exercised in this withdrawing of the needles. Weil, who has performed the operation 130 times, has seen no bad result, except one case of glaucoma which yielded to eserin, and one of hemorrhage from the iris, which was torn in withdrawing the needle. In other hands, however, the barb has been broken off, necessitating a magnet extraction.

Jackson (*Amer. Ophth. Soc.*, Vol. 13, p. 394, 1912) discusses the technic of discission, which he has successfully used for complete cataract in two patients after the age of forty. In patients under thirty, if not excluded by the time required, it is a method always to be considered. It is safer to introduce the needle through the vascular limbus than through the clear cornea. The needle is entered almost parallel to the plane of the iris until the point has passed the edge of the pupil. The point is carried as directly as may be to the center of the lens nucleus, and is then directly withdrawn. This procedure differs from that of Kuhnt and some others in that the discission is not confined to the anterior cortex, but attempts to open a channel for the aqueous to the very center of the nucleus. In older children and adults, if this has not been done, absorption of the cortex may leave a loose, firm nucleus which is very difficult to divide or break up with any form of knife-needle. At the second operation the aim should be to disintegrate the nucleus without much opening of the capsule. The needle having been carried into or through the nucleus, is turned and made to cut up and down so that the nucleus

may be broken up into several fragments. Plenty of time should be allowed between successive operations.

Discission des Nachstars. (G.) Discission of secondary cataract.

Discissions-Messerchen. (G.) Discission knife.

Discissions-Nadeln. (G.) Discission needles.

Disc, Keratoscopic. A name for the keratometer or disk of Placido. See **Placido's disk.**

Discleral illumination. Transillumination. See **Diaphanoscopy.**

Disc-like keratitis. See **Keratitis disciformis.**

Disc, Mason's. This is an incorrect spelling (in most text-books of ophthalmology) of *Masson's* disc or disk. See **Discs, Photometric.**

Disc, Mason's pupil. PUPIL STOP. A. B. Mason (*Ophth. Record,* December, 1912) has devised a pupil disc to be used in the trial frame of the same size as the ordinary trial lens. It is 35 mm. in diameter and 2 mm. thick. The opening in the center is 8 mm., corresponding to the average size of the dilated pupil. The slide has openings 2, 3, 4, 5 and 6 mm. in diameter, so arranged that any one of them can be centered over the opening on the slide. The method of using the disc is as follows: The size of the pupils with accommodation at rest is noted at the preliminary examination. With the pupils dilated and the patient seated at the trial case, the disc is inserted in the trial frame, with that opening on the side that corresponds to the size of the pupil noted at the preliminary examination, accurately centered in front of the eye. The trial case examination is then made in the usual way. The author believes that in measuring refraction spheric aberration should be corrected; short eyes—far-sighted—have positive spheric aberration, which, in nearly every case, if left uncorrected, changes the refractive error; long eyes—near-sighted—have negative spheric aberration, which, if left uncorrected, does not change the refractive error, though the vision is not as acute.

Disc, Masson's. See **Discs, Photometric.**

Disc, Maxwell's. Maxwell modified the revolving disc of Masson by adding both colored, white and black paper discs of two different sizes, so as to obtain two mixtures at once, by covering the central portion of the larger disc with smaller ones. See **Discs, Photometric.**

Discoid. Disc-shaped.

Discoid cataract. COPPOCK CATARACT. NETTLESHIP'S CATARACT. DOYNE'S CATARACT. For an account of this rare form of congenital, familial and stationary cataract, see **Coppock cataract;** as well as **Congenital anomalies.** Foster says that the term discoid was formerly applied to ordinary senile cataract.

Discoloration. A loss or withdrawal of color.

Discoloration of the cornea. See **Cornea, Melanosis of the.**

Discolore. (F.) Of two colors.

Discomyces. A genus of parasitic organisms probably belonging to the *Fungi.*

Discomyces equi of Rivolta. See **Botryomycosis of the eyelids.**

Disc, Optic. Optic papilla. Porus opticus. Optic nerve-head. The nerve-head is situated about three millimetres to the nasal side of the posterior pole of the eye, and is the point of entry of the optic nerve into the retina. It measures from 1.4 to 1.7 millimetres in diameter and is generally circular or ellipsoidal in shape. In the astigmatic eye the optic disc often appears oval or ellipsoidal when in reality it is round. Owing to the magnification when the ophthalmoscope is used, the papilla appears to be from 9 to 18 millimetres in diameter. Near its centre is a depression, the physiologic excavation, which marks the divergence of nerve-fibres. The excavation is funnel-shaped, the base being anterior. A trace of the hyaloid artery of fetal life is occasionally seen here as a thread of connective tissue running from the papilla into the vitreous. Surrounding the papilla are two rings: an inner, due to exposure of the sclera, is whitish, and is called the scleral ring; and an outer one, due to the showing of choroidal pigment, is named the choroidal ring. At the bottom of the excavation a few dark spots are seen, from the gray stippling of the lamina cribrosa. In color the papilla is grayish-pink or reddish, and stands out in marked contrast to the reddish-yellow of the remaining parts of the fundus. The color of the papilla varies with the age and complexion of the individual, the color of the surrounding parts of the fundus, and with the illumination used. A bluish discoloration of the disc has been observed as a congenital abnormality. A more common anomaly is the presence of opaque nerve-fibres, which condition is due to the fact that the medullary covering of the axis-cylinders exists in the fibre-layer of the retina. In such a case the fundus shows a patch of a brilliant white color extending out from the disc. Generally the white area is in contact with the disc. It rarely occurs that the opaque fibres are found at a great distance from the nerve-head or that they occupy a large area of the fundus. The physiologic cup or depression may occupy a large part of the nerve-head, but never extends to the scleral ring. Under normal conditions many variations are seen in the size and depth of the cup and in the arrangement of the blood-vessels.—(J. M. B.) See, also, Vol. I, p. 397, of this *Encyclopedia.*

Disc, Opticohyaloid. See **Conus, Opticohyaloid.**

Disc, Placido's. See **Placido's disk.**

Disc, Rekoss. This important device has been utilized in many ophthalmoscopes and other optical instruments. It is made of the well-known double revolving discs, carrying a series of lenses. As originally invented, the two discs had each five round openings; four of these were filled with concave lenses from six to thirteen inches in focal length; the fifth was empty; by a simple turning of the discs, any one lens or any combination of two lenses could be utilized. A small spring kept the discs in place.

Discs, Ophthalmic. Gelatine lamels. These form convenient and economical applications of different remedies—many of them (like homatropin, hyoscin, holocain, novocain) expensive alkaloids—to the eye. They are generally put up in sealed glass tubes as round, gelatine plates in which are incorporated therapeutic agents in every possible dose and combination. Wyeth and Co. in the United States, Savory and Moore in England are well-known manufacturers of these discs.

Wyeth's Ophthalmic (gelatine) Discs.

Some discs of use in ophthalmic practice have been made with boric acid and similar excipients, but these are not adapted to application direct to or solution in the conjunctival sac. They should be first dissolved in water and the solution instilled with a medicine-dropper. Dried tuberculin discs may be utilized in this fashion in the Calmette test.

Discs, Photometric. For the purpose of determining the lowest limit at which the eye begins to distinguish objects—especially of distinguishing differences in brightness—these devices are, among others, employed. The principal discs are those of Masson, Helmholtz and Benham. Tscherning (*Physiologic Optics*) thus describes these different kinds of apparatus:—The disc of Masson is white of which sectors of different sizes have been blackened (see the figure). By subjecting this disc to a sufficiently rapid rotation, we see three gray rings separated by white intervals. Supposing that the sector *a* is 20°, the sector *b* 10° and the sector *c* 5°, and supposing, which is not strictly true, that the black does not reflect any light at all, the brightness of the three gray rings would be 340, 350 and 355, if we place the light of the white rings at 360. The difference between the

exterior gray rings and the white will be 5, and the relation between this difference and the white will be $\frac{5}{360} = \frac{1}{72}$, which represents the value of the refraction of *Fechner* of the examined subject, if he can distinguish the three images. If he can distinguish only two, the fraction of Fechner is $\frac{360 - 350}{360} = \frac{1}{36}$, and so forth. A great number

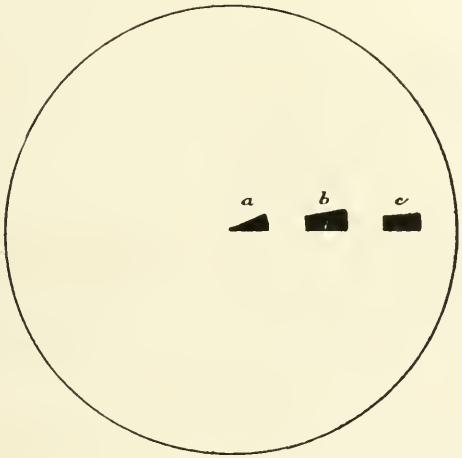

Disc of Masson.

of rings must be used; the illumination must good, and the patient must not be too far away, in order to eliminate the influence of a diminished visual acuity. It is evident, however, that we cannot completely eliminate it; the acuity may be so poor as to prevent the patient from distinguishing anything. To obtain an impression of a uniform gray with the disc of Masson, it is necessary that it rotate with a certain speed, about 20 to 30 times per second. If the disc carries several black and white sectors, alternating, the speed may be less. In case the speed is not sufficient, the disc gives a scintillating impression and we often observe on it very beautiful colors. The disc *A* (see the figure) has been described by Helmholtz: with a certain speed the external ring shows very vivid colors, among which the red and green predominate; they are often arranged in a manner which recalls a series of short spectra, as we observe them with gratings.

But the phenomena are very changeable; in the second ring, which has only four sectors, the yellow and blue predominate with this speed, but only to a slight extent. If we increase the speed the external ring gives a uniform gray, while the second ring assumes the appearance which the external ring had previously. In the figure, *B* represents the disc of *Benham*. If we make it rotate in the direction of the arrow, the arcs form concentric circles which present quite vivid colors in the following order, starting from the middle: red, brown, olive-green, blue. Making the disc rotate in the opposite direction, the order of the colors is reversed. The most beautiful of the colors



A, Disc of Helmholtz; *B*, Disc of Benham.

is the red; the circles seem traced in blood. The nature of these phenomena is not yet elucidated. We must not think that it is due to a decomposition of the white light, for the experiment succeeds perfectly when illuminating the disc with homogenous light, providing it is sufficiently strong. We even see colors of this kind when looking towards the homogenous sodium flame.

Discs, Volkmann's. This device is a method for determining the angle between the apparently perpendicular meridians of the two eyes. Volkmann placed two small, revolving discs on a vertical wall so that the distance separating their centers would be equal to the distance between the eyes. On each disc was shown one radius. He observed the discs as with the stereoscope, the right eye fixing the disc on the right, the left eye that on the left. He placed one of the radii vertically, and then tried to place the other so that the two radii would appear to form a single straight line; they should form an angle of about two degrees.

Discs, Walker's color. These colored test objects consist of a handle having mounted at either end a circular disc on each side of which a different color is shown. These discs are mounted at right angles to each other, so that only one color is visible at a given time. The retaining rim is made with a knife edge, and the objects are therefore essentially rimless.

The objects are made in seven sizes, and the area of each object, not the diameter, is stamped on the handle. The smallest disc is 1/64 sq. cm.; the largest one 16 sq. cm.

Double-End, Graduated Discs for Test Objects. (Clifford Walker.)

Discus opticus. (L.) Optic papilla.

Disdiaclast. Any doubly refracting body.

Disesthésique. (F.) Literally, doubly sensitive; a term suggested by Milne-Edwards, pertaining to points on the two retinæ corresponding to each other in sensibility.

Disinfectants. Agents that prevent infection or that relieve its disagreeable or dangerous consequences are as much used in ophthalmology as in general surgery. Among the disinfectants are most of the antiseptics or germicides. Special mention may be made of mercuric chloride, acetozone, antinosin, antipyonin, enzymol, formol, glycozone, hydrogen peroxide, hydrozone, chlorine water, Labarraque's solution, chlorinated lime, lysol, calcium permanganate, perhydrol, phenol and chlorinated soda.

H. A. Kiefer (Wood's *System of Ophthalmic Therapeutics*, p. 51), on account of the extremely contagious character of trachoma, making it possible for the patient to reinfect himself from the various objects with which he comes in daily contact, thus undoing the work that the surgeon has accomplished by operations and other forms of treatment, has made it a practice for the past ten or twelve years thoroughly to fumigate all the patient's belongings. This includes his wearing apparel, bed-clothes and especially the pillows, and all other things that pertain to his wardrobe and apartments, and the room he occupies in sleeping. The fumigation is accomplished just before or after opera-

tion, or while he is in the hospital. If it is not a surgical case it is done just as soon as possible. The fumigation should be repeated at each operation. In non-operative cases he has the fumigation repeated every few weeks while the case is under his care, just as in operative cases.

A few examples of the varied uses of ocular disinfection are the following: In two years' work by Elliot at Madras, not a single instance of suppuration had followed any intra-ocular operation, although these operations included about 1,000 cataract operations, and 300 trephinings for glaucoma. On the morning of operation the lids are everted and irrigated with mercuric chloride (1:3,000) for one or two minutes. The contents of the Meibomian glands are expelled by firm pressure, and the conjunctival sac carefully swabbed out with small, steam-sterilized, cotton-wool swabs, using a sterilized salt solution poured freely over the surface.

For the disinfection of the hands Terson (*Ann. d'Ocul.*, Vol. 150, p. 192, 1912) recommends washing in 90 per cent. alcohol for five minutes without preliminary soaping, because previous moistening of the hands dilutes the alcohol and lessens the effect on the skin. Experiment shows this method is equal to prolonged cleansing with soap and water. It has been used by general surgeons, giving excellent results. He has also added to the alcohol a little iodin, sufficient to color it, without much discoloring the hands.

As to the use of sterile gloves, he points out that they diminish the sensibility, the suppleness, in a word, the dexterity of the fingers of the ophthalmologist. But where the hands of the surgeon are the seat of infection, against which it is essential to guard the patient; or, if the surgeon must be defended against the patient's infection, as in dressing a chancre, malignant pustule, etc., the gloves may properly be used. Elschnig (*Klin. Monatsbl. f. Augenheilk.*, June, 1913, p. 793), because of the favor they have found with general surgeons, recommends that sterilized rubber gloves be worn for all operations in which there will be bleeding, and sutures to be handled which might serve as a medium of infection. He wears underneath the rubber gloves a pair of sterilized cotton gloves.

For disinfection of the hands before operating on the eyeball without gloves, or before drawing on the gloves for other operations, Elschnig washes with soap and spirits of soft soap, in sterile, warm, running water; or brushes them for three minutes, dries with gauze, dips them in a solution of oxycyanate of mercury, dries again, then washes in 70 per cent. alcohol, and dries with sterile compresses. For an irritable skin he recommends inunction with fresh sterilized lanolin and vaselin.

Ziegler (*Opth. Rec.*, Vol. 22, p. 28, 1912) recommends for cleansing the hands a neutral liquid soap, made with 10 per cent. of alcohol, 10 per cent. glycerin, and cottonseed oil.

Possek (*Zeitsch. f. Augenheilk.*, Vol. 30, p. 462, 1912) disinfects instruments in 70 per cent. alcohol to which a trace of alkali has been added. From this the instruments are taken as required for use.

The disinfection of the field of operation by touching the parts with a match-stick wrapped lightly with cotton dipped in tincture of iodin, is proposed by Jacquean (*Jour. Amer. Med. Assocn.*, Vol. 60, p. 1746, 1912). Kraupa (*Zeitsch. f. Augenheilk.*, Vol. 30, p. 459, 1912) found in cataract cases streptococci present in 28 per cent. These cases are not suitable for operation, and washing the conjunctiva does not free it from the germs. Other cocci, present in 40 per cent. of the cases, are less important.

Disk. See **Disc.**

Disk, Choked. See **Choked disc,** page 2074, Vol. III of this *Encyclopedia.*

Dislaceration. DOUBLE-NEEDLE OPERATION. One of the operations, first practiced by Bowman, on secondary cataract (see **Discission**), and, later on, detached retina (*Ophthalmic Hosp. Reports*, 1864, p. 133.)

Dislocatio bulbi. Dislocation of the eyeball.

Dislocation of the eyeball. DISLOCATIO BULBI. While this term includes both of the following it is desirable, as Barck has said, to make a distinction between these terms. Luxation means that the eyeball lies in front of the lids, which close spasmodically behind it. The optic nerve and muscles are stretched, but their connection with the globe and with the other orbital structures is maintained. Avulsion indicates that, owing to rupture of the optic nerve and the severance of the majority or all of the extrinsic muscles, the connection is broken.

Luxation may occur spontaneously, as in some cases of exophthalmic goitre, and in persons with abnormally shallow orbits and prominent eyeballs. It may also occur when, after the introduction of an eye speculum, the patient struggles, cries, or coughs. Dépoutol saw a young man with an opisthognatous face who could dislocate his eyeball by blowing the nose violently. Generally, however, luxation results either from the impact of a large, blunt, foreign body; from self-inflicted injury produced by the insane with their fingers; or from the barbarous practice of "gouging," which is said to be common among the natives of Uganda, Africa. In a few instances luxation has occurred in difficult instrumental deliveries.

Avulsion is produced in this manner: the missile causative of luxa-

tion also acts as a lever, with sufficient energy to sever the optic nerve and lacerate the muscles. The unyielding orbital margin acts as a fulcrum. Avulsion has been caused by falls upon blunt projecting bodies. Thus, it has resulted from a fall upon keys which were in their locks, from the impact of a boar's tusk, etc. Inspection will at once reveal the true condition. In luxation the eyeball may or may not be ruptured. If torn, the case will probably require enucleation. If the globe is simply luxated the prognosis is generally favorable, although severe damage may have been done to the optic nerve, retina, choroid, and lens. In avulsion the eye is lost.



Avulsion of the Eyeball. (Barck.)

The treatment consists in the earliest possible replacement of the eyeball within the orbit. This may be easily accomplished by separating the lids and gently pushing the globe backward. If it is attended with great difficulty, owing to the swelling of the lids and their tight constriction, retractors should be passed under the lids. In the event of failure, the outer canthus must be cut, the lids replaced, and the wound stitched. After reduction, rest and ieed compresses are indicated, after which a compress bandage should be worn for some time. If the eyeball is ruptured the indications for treatment are such as are described elsewhere for this condition. If a case of avulsion is seen early and some of the muscles are still attached, an attempt may be made to stitch the globe into place with the hope of saving it for cosmetic reasons. If there is cause to believe that the germs of infection have been carried into the orbit, an enucleation should be made. —(J. M. B.)

Parsons (*Pathology of the Eye*, p. 1181) confines the term dislocation of the globe to displacement of the eye into one of the neighboring cavities—antrum of Highmore, ethmoid, etc.—is always the

result of very severe injury. Fractures of the floor of the orbit leading to depression are not extraordinarily rare; as a rule they cause only traumatic enophthalmos (q. v.), so that dislocation of the eye into the maxillary antrum may be regarded as an extreme form of this condition. The earliest case of dislocatio bulbi is by Henricus Smetius a Leda (1575) (*Centralbl. f. Augenheilk.*, Vol. 23, 1899); the eye was displaced into the nose, and some vision is said to have been retained through the nasal aperture. Dislocation into the antrum is recorded by Becker (*Archiv f. Ophthal.*, Vol. 12, p. 2, 1866) (by a cow's horn), v. Langenbeck (*Archiv f. Ophthal.*, Vol. 13, p. 2, 1867) (fall between railway engine and tender), and Tweedy (*Lancet*, 1881) (by a cow's horn). In v. Langenbeck's case vision was normal after reposition, but a corneal ulcer developed and the eye shrank. In Tweedy's case the eye was blind though there was a red reflex. See, also, Vol. I, p. 719, of this *Encyclopedia*.

In Strachow's case (*Klin. Monatsbl. f. Augenheilk.*, Feb., 1910, p. 208) diplopia and extreme dislocation of the eyeball inward and downward were present; swelling at the upper inner angle of the orbit; nasal polypi and pus in the superior meatus. At the operation it was found that the orbital and posterior wall of the frontal sinus had been destroyed, the cavity greatly enlarged and filled with pus and polypoid mucous membrane. The pus attained the dura without, however, causing cerebral symptoms. The cavity communicated with the posterior ethmoidal cells, which circumstance explains the flow of pus from the superior meatus.

In Donaldson's case (*Ophthalmoscope*, Vol. 8, p. 217, 1910) one eye of a new-born child was dislocated on the cheek during instrumental delivery. The eye was at once replaced. Three years later the eye was normal and sight good.

Dislocation of the lens. See **Lens, Dislocation of the.**

Dislogamento della pupilla. (It.) Displacement of the pupil.

Disparate points. The opposite of **Corresponding points of the retinæ.**

Dispensary furnishings, Ophthalmic. See **Hospitals, Ophthalmic, Equipment of.**

Dispersif, -ive. (F.) Pertaining to dispersion; causing dispersion.

Dispersing lens. Divergent lens. A double concave, plano-concave, or convexo-concave lens which causes the rays of light to diverge, so that instead of coming to a focus they appear to come from an imaginary focus situated at the same point as the incident ray.

Dispersion. Dispersion of light. The deviation produced between the constituent rays of a composite ray of light which has been refracted by a prism or peripheral part of a lens. The point of dispersion is

the point where the refracted rays begin to diverge, owing to their different wave-lengths. When a ray of solar light is made to pass through prisms of the same angle, but of different substances, it is found that spectra are formed of different lengths, the prism producing the longer spectrum being said to have the greater dispersive power. The angle between any two given deviating rays is called the dispersion of this pair. See, also, **Chromatic dispersion.**—(C. F. P.)

Dispersion, Chromatic. See **Chromatic dispersion.**

Dispersion of the optic axes. The variation in the value of the axial angle for rays of different wave-lengths.

Dispersion photometer. A photometer for determining the intensity of brilliant light sources.

Dispersive. Having the power of causing the different colored rays of a beam of light to diverge.

Dispersive power. The power or ability of an optical instrument to separate colors, so as to form a spectrum. See page 2193, Vol. III, of this *Encyclopedia.*

Displaced macula. EXTRACENTRAL MACULA. This is a congenital malformation which may not be as rare as is usually claimed. Doubtless the marked cases, associated with other fundus anomalies, are very rare. One example of the latter defect is a case reported by Adam (*Ophthalmic Review*, Oct., 1912), a student, aged 20, who had suffered for years from strabismus, one eye being directed inwards and upwards. When the fixing eye was covered the other remained in the position of convergence and upward deviation, when a reduction of vision to—perhaps—ability to count fingers merely might have been expected—but so far from that the eye, even in this position, possessed nearly full vision. With the ophthalmoscope the appearance of a macula was found to be situated in the corresponding position in the fundus, and to it what seemed like connective tissue bands ran from the disc. A further peculiarity in the fundus was that the lower half of the retina was almost entirely devoid of vessels.

Displacement of the eye. DISLOCATION OF THE EYEBALL. AUTOENUCLEATION OF THE EYE. See Vol. I, page 711, of this *Encyclopedia.* Also, see the first synonym above.

Displacement of the lens. A synonym of dislocation of the lens. See **Lens, Dislocation of the.**

Disposition. TENDENCY TO OCULAR DISEASE. PREDISPOSITION TO DISEASE. IDIOSYNCRASY. As in general conditions and in systemic diseases so in ocular complaints and lesions is there often a peculiar tendency to disease. The exact meaning of this state of affairs is not easy of

definition. Sometimes it takes a distinctly hereditary form; in other instances there is nothing about the patient to indicate what particular disease he is most likely to acquire. For example, it is well known that some people have an idiosyncrasy against certain toxic agents—often drugs. This is exemplified in the various toxic amblyopias. Some individuals are readily poisoned by, and some part of their ocular apparatus suffers from, such agents as tobacco, methyl alcohol, quinin, etc., while others do not seem to be especially affected by them.

Disque ciliare. (F.) Ciliary ring.

Disque de Masson. (F.) Masson's disc. See **Discs, Photometric.**

Dissecting microscope. A simple or compound microscope, for monocular or binocular vision, used in dissecting very minute objects, the ocular tissues, for example.

Dissection glasses. These were invented by von Brücke for the improvement of vision in anatomical (dissection) work. The device is a binocular microscope provided with strong convex lenses combined with correspondingly strong abducent prisms. See **Dissecting microscope.**

Dissectionsbrille. (G.) Lenses used in dissection. Dissection microscope.

Disseminated choroiditis. See Vol. III, page 2141 of this *Encyclopedia.*

Disseminated choroiditis of Fuchs. ANTERIOR CHOROIDITIS OF FUCHS. See Vol. III, p. 2140 of this *Encyclopedia.*

Disseminated sclerosis, Ocular signs of. This disease, variously styled *multiple sclerosis, multiple-cerebro-spinal sclerosis* and *insular sclerosis,* is of toxic origin, affecting both the spinal cord and brain in varying degree, and at any and all levels. The sclerotic foci irregularly and widely disseminated throughout the nervous system give rise to a great variety of symptoms of which the more common are muscular weakness and spasticity, intention tremor, nystagmus, scanning speech, augmented by special sense changes, anomalous reflexes, bulbar disturbances and psychic phenomena.

This disease is rich in eye symptoms, upon which much depends for its early diagnosis. Any portion of the eye may be affected. The pupils are likely to be contracted, and unequal in size, with diminished reaction to light and accommodation, but the Argyll Robertson pupil is very rare. Hippus has been observed. According to Uhthoff, the extrinsic eye-muscles are involved in 17 per cent. of the cases. The disturbance is usually bilateral and transient. One muscle only may be paralyzed or there may be complete ophthalmoplegia. The abducens is most frequently paralyzed, and next to that the oculomotor. The paralysis is not usually complete. The nuclear nature of the dis-

case is sometimes shown in the lack of associated movements. Uhthoff observed paresis of upward associated movements. Nystagmus is a very frequent symptom, true nystagmus being present in 20 per cent. of the cases, and the remainder usually show nystagmiform movements—the ocular ataxia of Swanzy. These are shown by directing the patient to look from the usual line of sight: e. g., up and out.

Optic-nerve atrophy occurs in about 50 per cent. of the cases. The process is generally a slow one, and is seldom extreme. Vision may be more or less affected. A transient form of blindness is not uncommon. Hemianopsia is never present, which, as a localizing symptom, places the lesion, as far as visual symptoms are concerned, peripheral to the optic commissure, although the lesions causing the different ocular palsies may be as far back as the nuclei of the nerve governing the muscle. The occasional disturbances in the field of vision are central scotoma, irregular and regular retraction of the field, and dyschromatopsia, particularly for red and green.—(J. M. B.)

The failure of vision in multiple sclerosis is also discussed by Williamson (*Lancet,* May 2, 1908). He reports six cases that came under observation on account of such visual failure. It may or may not be accompanied by evidence of optic atrophy. In the absence of other symptoms, these cases are generally diagnosed as primary optic atrophy, or retrobulbar neuritis, but they should be carefully watched for other evidence of the disease. Wernicke (*Centralbl. f. prakt. Augenheilk.*, May, 1908), assuming that nearly all cases of tabes have followed syphilis, believes that syphilitics in whom a specific iritis occurs remain free from tabes. When it is remembered that only a small minority of syphilitics suffer from tabes, and only a very small minority from iritis, it is evident that very extended experience or statistics will be required to support such a proposition. Knauer (*Münch. med. Wochenschr.*, Sept. 15, 1908) reports a case of tabes in which eye crises, such as have been described by Pel, occurred with other disturbances of sensation. Massia and Delachanal (*Gaz. des Hôpitaux,* Nos. 1 and 4, 1908) give an elementary description of what they term the "tabetic eye."

The clinical history and *post mortem examination* of a woman, aged 43, who died five months after the development of a severe acute cerebrospinal affection (a sequel of acute disseminated sclerosis) is reported by Roenne (Graefe's *Arch. f. Ophth.* lxxxiii, III, p. 505). About a month after the onset of the nervous symptoms the right eye grew rapidly blind from retrobulbar neuritis with orbital symptoms, terminating with atrophy and temporal hemianopic defect of the visual field of the left eye. The post-mortem examination revealed

in the cervical and dorsal medulla, optic tracts, chiasm and optic nerve patches of acute disseminated sclerosis. As these showed abundant inflammatory changes, the affection might also have been called an acute or subacute disseminated myelitis. Roenne, in consequence, makes some remarks on the relation between affections of the optic nerve occurring in acute myelitis and multiple sclerosis. The marked onset of the retrobulbar neuritis, sometimes with amaurosis, but with tendency to restitution, the inclination to attack the papillo-macular bundle, the less prominent ophthalmoscopic changes, and the accompanying orbital symptoms, edema of the lids, temporal headache, pain on ocular movements and sensitiveness of the eye to pressure, are encountered in numerous cases of myelitis and multiple sclerosis. There are also anatomo-pathological analogies in both affections: primary localization in the chiasm and tracts, apart from the optic nerve, which under other conditions seems to be extremely rare, and the characteristic formation of foci in the visual path. That in some cases the changes in the chiasm and optic nerve in sclerosis differ from those in myelitis are not peculiar. In the one case it is a terminal process; in the other a constantly acute stage comes under examination. Hence Roenne surmises that the affection of the optic nerves in both diseases is identical, or very closely related, and both diseases are two forms of the same etiology, and that numerous cases, diagnosed as myelitis with optic neuritis, are to be regarded, like the reported one, as acute disseminated sclerosis.

Of the cranial nerve changes, those relating to the optic nerve (50 per cent.) and ocular muscles (17 per cent., Uhthoff) are conspicuous.

Holden (*Jour. Am. Med. Assn.*, July 11, 1908) thinks that a non-toxic retrobulbar neuritis, not due to syphilis, sinusitis, diabetes, neoplasm or trauma, is, as a rule, a manifestation of multiple sclerosis, even though all other symptoms of this disease are absent. So much greater then the necessity for ophthalmologists to know something of this disease, however unpromising its therapeutic prospect.

Treatment. Prophylaxis and causal treatment are futile. The rapid development of weakness and spastic paralysis early in the disease frequently calls for prolonged rest in bed. There are few diseases in which there is a more pronounced tendency to remissions and exacerbations, and in each acute aggravation a rest cure may prove necessary. Much benefit when in or out of bed is to be derived from the employment, for both upper and lower extremities, of the Frenkel exercises (vide **Tabes**), modified to suit the muscular and motor impairment in each case. In no instance would it be wise to practice

one system of gymnastics continuously. Only as the symptoms warrant should a graded system of exercise, massage and movements, and bathing combined, be carried to the point of a good gain, and then interrupted until the next evidence of decline appears.

Good nutrition must be maintained and re-enforced by plenty of fresh air, various "water cures" and resorts, where the equable division of rest and diversion will materially influence all parts of the body and conserve the general strength. Daily baths are permissible, but the temperature should never exceed 90° to 95°. Electrotherapy is of no value, and may prove harmful.

In the chronic spinal diseases it has been the habit to give the iodides in small doses (sodium iodide, gr. x-xx daily) for a long period of time, but I am unable to confirm the appreciable improvement noted by others in cases so treated. Apparent benefit has come from the judicious use of arsenic, quinine, cod liver oil and other tonic drugs. In the terminal stages, when cystitis and decubitus supervene, appropriate measures are indicated.

In all the efforts at treatment, a proper value must be placed upon the tendency to spontaneous remissions. What has been said of the enormous importance of suggestion and mental therapy in chronic invalidism from tabes, applies with equal force in multiple sclerosis.—(A. C. C.)

Dissépiment. (F.) Septum; diaphragm; partition.

Dissimilation. This is a term applied by Hering to the decomposition of the visual substances aroused by the sensation of white as well as by two primary colors. The assimilation of these agents arouses in the one case the sensation of black, and of the two others colors which are complementary to them.

Dissimulation, Ocular. The pretense that an actual, existent disease or injury of the eye does not exist. See **Legal relations of ophthalmology,** about the middle third of the section.

This subject is also fully discussed by Segelken (*Berlin. Klin. Wochenschr.*, Sept., 1913, p. 1763) and dissimulation goggles, for the detection of pretenders, pictured and described.

Dissipable. Liable to dispersion.

Dissociation. See **Disassociation.**

Dissolving views. Pictures shown on a screen, and made to change gradually into the succeeding pictures.

Dissymmetric. Dissymmetrical. Without symmetry.

Distacco della coroide. (It.) Detachment of the choroid.

Distacco della retina. (It.) Detachment of the retina.

Distalbrille. The trade name (Zeiss) of double lenses mounted in spectacle frames, like opera glasses, for improving the vision of high myopes and other weak-sighted patients. They are furnished for both distance and near work.

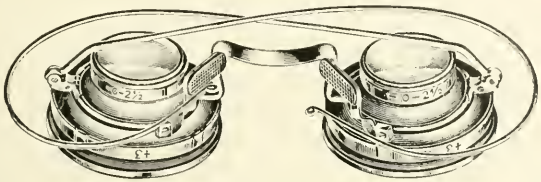

Distalbrille (—16. D.) with Astigmatic Lenses. (Zeiss.) Other lenses may also be added.

Distance, Estimation of. Donders (*Accommodation and Refraction of the Eye*, p. 153) points out that with differences in the distances, magnitude, and form of objects, are connected peculiar modifications in the requisite movements of the eyes, in the accommodation and chiefly in the retinal images; and in the changes, which these undergo by accommodation, and by movements of the eyes or of the head, and of the whole body. It is exclusively from these modifications that the mind is in a position to form an opinion as to distance, magnitude, and form. This, however, for the most part, takes place spontaneously, quite involuntarily, or at least without consideration. The rapidity of the judgment, without analysis of the elements on which it is based, is the result of practice, partly of the individual, partly of his parents, and is, in the latter sense, innate. In the first place, we observe that the estimation of distance and that of magnitude are correlative. Three cases are to be distinguished. (1) We know the true magnitude of the object, and thence form, by the magnitude of the retinal image, our opinion as to the distance; (2) we know the distance and base thereupon our opinion of the magnitude; (3) distance and magnitude are both imperfectly known, and through reciprocal influence an idea is developed, which brings both into connection with one another, and thus at the same time more accurately defines them. The connection just mentioned between our estimation of distance and of magnitude is particularly striking when we project the ocular spectrum of a flame upon a wall, in which case we suppose the flame larger, in proportion as we withdraw from the wall, and smaller in proportion as we approach it, notwithstanding that the retinal image of course remains unchanged.

Distance, Focal. Focal length. As has been several times pointed out under appropriate headings, the value of the lens in physiologic optics is to cause the rays of a pencil of light to converge towards or diverge from a certain point. The point at which the pencil of light is concentrated is called a focus, and the focus for a pencil of parallel rays is the *principal focus;* while its distance from the lens is its *principal focal distance,* or *focal distance.*

Distance sense of blind. See **Blind, Distance sense of.**

Distant organs, Operations on, for relief of eye symptoms. These procedures are discussed under various appropriate headings. See, for example, **Brain tumor,** as well as **Brain puncture,** and **Decompression.** Additional captions are, for example, **Thyroidectomy** and **Exothyropexy**; also **Sympathectomy.** Such subjects as **Exophthalmus, Pulsating,** and **Exophthalmic goitre** also furnish illustrated descriptions of procedures employed in their operative treatment. See, in addition, the heading **General surgery in its relation to ophthalmology.**

Distanzametropie. (G.) Anomalies of distant vision.

Distanzschätzung. (G.) Estimation of depth.

Distention theory. This is the well-known *mechanical* or distention theory of retinal detachment. It originated with von Graefe and is referrable, chiefly, to highly myopic eyes in which the condition is frequently observed. The elongation of the antero-posterior axis of the eyeball, assisted by the accompanying hyperemia, was supposed to drag from its place the retinal membrane.

Distichiasis. Trichiasis. Misplaced cilia. An abnormal direction of some or all of the eyelashes, so that they are arranged more or less regularly in two rows, the affected ones rubbing against the eyeball, where they cause irritation and inflammation, and invite dangerous infection of the ocular structures. This subject has already been fully discussed in Vol. III, p. 2216 of this *Encyclopedia.* It may, however, be added here that a few recent operations have been devised for relief of this condition. One of these is the operation proposed by Marquez (*Archivos de Oftalmologia,* Feb., 1910), which is a modified combination of the Jaesche-Arlt operation for transplantation of the ciliary margin, with one recently suggested by Santa Cruz, of Madrid, for treatment of distichiasis. The steps of the operation are as follows: The lid is held by means of forceps, which have been modified by Marquez from those of Snellen by making that part of the fenestrated blade which corresponds to the lid-margin continuous instead of open. Along the free margin of the lid two incisions are made, connected at their ends, and including between them the area

containing the supernumerary lashes. A semilunar piece of tissue is removed from the anterior surface of the lid according to the Jaesche-Arlt method. The posterior incision on the lid-margin is then extended deeply, so as to reach to the area involved in the Jaesche-Arlt procedure, thus separating this part of the lid into two layers. The anterior layer is again divided into two layers by extension upward of the second marginal incision, which now meets the first in such fashion as to remove the tissue containing the supernumerary lashes. The lid forceps being removed, the loose anterior layer containing the normal cilia is transplanted upwards, so as to take the position formerly occupied by the tissue removed according to Jaesche-Arlt.

Sameh Bey (*Clin. Opht.*, Vol. 18, p. 301, 1911) has modified the operation of Anagostakis-Panas for trichiasis in the two following points: 1. Drawing down the inferior border of the tarsal flap to form a small pad below the ciliary border. This new position prevents the cilia from turning inward against the cornea. 2. Placing the sutures deeply in the upper parts of the tarsus and suspensory ligament. This procedure results in the formation of vertical cicatrices whose subsequent contraction prevents prolapse of the lid and maintains the ciliary border in its new position. With these modifications, relapses are rare.

Grout (*Arch. of Ophth.*, Vol. 40, p. 296, 1911) has operated upon seven cases by von Blaskovics' method. The first incision is made about 2 or 3 mm. from the lid margins, down to the tarsus, parallel to the lid border. The hair follicles must be avoided. A second incision is made 1 mm. from the first, and parallel to it. This leaves an island of skin and underlying tissue 1 mm. broad attached to the tarsus. The lid is now split by an incision in the intermarginal space, connecting with the first incision, thus freeing a strip containing the cilia. The island of skin is now deflected and brought down to the intermarginal cut, with the skin surface showing on the lid margin; and is secured there by two mattress sutures. Wicherkiewicz (Graefe's *Arch. f. Ophth.*, Vol. 80, p. 439, 1911) states the historical position of his operation, which was never described in an eye journal, but was published in 1888 in the *Berliner Klinische Wochenschrift*. He quotes sections of this original account, and describes the steps of the operation as he now performs it.

Chronis (*Arch. di Ott.*, Vol. 19, p. 100, 1911; *Ann. of Ophth.*, Vol. 21, p. 797, 1911) gives a description of his father's operation for trichiasis and entropion of both lids: An incision into the skin 3 mm. from the margin, removal of the palpebral and Horner's muscles, and of successive layers of the tarsus until a deep furrow has been made.

The skin above the margin is then sewed to the tarso-orbital fascia, and allowed to unite by secondary intention. An intermarginal incision 1 mm. deep just behind the cilia completes the operation.

Begle (*Arch. f. Augenheilk.*, Vol. 74, p. 62, 1912) adds one to a total of about twenty-five cases of congenital distichiasis previously reported in the literature. The patient was a woman of thirty years. The posterior row of cilia lay close to the eyeball, and during movements of the globe rubbed the cornea with their entire length. The anomaly was more marked on the lower than on the upper lids. The posterior row of lashes sprang from the normal position of the openings of the Meibomian glands. Here and there on each lid margin was a glandular opening in line with the cilia. Some of the cilia were removed by electrolysis, but the greater part by excision of a strip of the posterior lid margin, the defect being filled with mucous membrane from the lip. Microscopic study showed absence of the Meibomian glands, which were represented by hyperplastic sebaceous glands, discharging into the follicles of well-developed accessory cilia, and also by small simple sebaceous glands irregularly scattered just beneath the lid margin and discharging upon its surface. See the major heading **Entropion (trichiasis).**

Distilled water of eyebright. A once popular preparation made by distilling off one-half [two-thirds (*Sard. Ph.*, 1773)] from a mixture of 1 part of the herb of *Euphrasia officinalis* (q. v.) and 2 parts of water (*Palat. Disp.*, 1764), or by mixing 10 parts of the herb and 25 of water, and distilling off 20 parts.

Distinctions-Vermögen. (G.) Visual acuity.

Distinzione della cheratite. (It.) Diagnosis of keratitis.

Distoechia. (L.) An obsolete synonym of distichiasis.

Distoechiasis. (L.) An ancient name for distichiasis.

Distoma. Distomum. The old name of a group of Trematoda or flukes, one or two species of which have been reported as occurring in the human eye. The name has now no scientific standing. The two forms in question, found only once each in man, are properly known as *Agamodistomum ophthalmobium* and *Monostomulum lentis.*; they have been variously designated as *Distomum oculare, D. oculi humani, D. ophthalmobium, Dicrocoelium oculi humani*, etc. The first form was observed and described by von Nordmann in 1832, as follows: "In the course of the month of May Professor Jüngken removed the lenses from two elderly blind women. I was present. The second case furnished the first instance of the presence of microscopic trematodes in the human eye, as eight specimens of monostomes lay in the lens substance. The animals were found in the outer layers of

the lens, were 0.1 line long, and moved slowly after they had been put into warm water. The investigation was made immediately after the operation.'' This description is sufficiently indefinite to occasion discussion as to the real character of the objects. They were undoubtedly immature forms and it is also clear that the case referred to is still unique.

In the same year Ammon described in great detail the case of a child in Dresden with congenital hard and soft cataract. At the autopsy the eye was removed and ''Geschiedt, who studied under the microscope the lens substance with reference to the entozoa discovered in the opaque human lens by von Nordmann in Odessa, found 4 distomes of the presence of which I likewise convinced myself at the autopsy.'' Geschiedt did not venture to determine the species. He gives the size as one-fourth to one-half of a line in length. When extended the animal had a lanceolate form, with length to breadth in proportion of 3:1. The color was white. The anterior sucker was one-third smaller than the ventral. The pharynx was short and narrow, and connected directly with an intestinal canal of nearly equal caliber. The latter, divided somewhat in front of the ventral (median) sucker, extended on both sides of the latter to the caudal end, and there, covered by the ovaries, could not be followed further. Of the organization of the ovaries nothing definite was to be recognized. ''In one individual I thought I could detect the irregular transverse position of the cotyledons.'' Some years later Ammon published four figures of the parasite which do not agree with each other or with the description given by Geschiedt. As in the other case no agreement has been reached as to the origin and relationship of the parasite. Both parasites are certainly erratic in their occurrence in the eye and probably even abnormal in their presence in the human host. However, since various flukes are not uncommon in domestic animals, and some occur frequently in the eye, the presence of such a parasite occasionally in the human eye may confidently be predicated.—(H. B. W.) For further data on these forms see **Parasites, Ocular.**

Distoma ophthalmobium [Diesing]. A variety from ¼ to ½ a line long, with large suckers and a forked intestinal canal, and without sexual organs; found between the crystalline lens and its capsule. By some it is regarded as an immature *Distoma hepaticum*. See **Distoma.**

Distorted image. An image whose linear dimensions do not bear the same relative proportion to each other as corresponding dimensions in the object. See, also, **Image.**—(C. F. P.)

Distortion. In *optics,* a form of aberration in which the image-area is not an entirely faithful reproduction of the object area. An image which is free from distortion is exactly similar to the object in its entire extent, and is called *orthoscopic,* or "angle true," because straight lines are reproduced as straight lines, and homologous angles in the object and the image are equal. When an image is formed by paraxial rays neither linear nor angular distortion exists, but when the image is formed by peripheral rays—as in the case of the eyepiece of a telescope—there will be linear distortion in the image; and if the eye is not on the axis of the lens, or if the faces of the lens are not perfect surfaces of rotation, there will be angular distortion. In all cases of oblique reflection or refraction, the image does not in general consist of an assemblage of *points,* but of circles of confusion overlapping each other, and it is therefore called indistinct. A lens which projects an orthoscopic image is called a "*rectilinear lens.*" *Barrel-shaped distortion,* a decrease in the magnification towards the margin of the field produced by a lens-system in which the ratio tan θ'; tan θ of the slope-angles decreases as the slope-angle θ (which see) increases, so that spaces of equal area in the object-plane appear as distorted spaces of gradually decreasing size towards the edges of the image. Also called *negative distortion. Cushion-shaped distortion,* an increase in the magnification towards the margin of the field produced by a lens-system in which the ratio tan θ': tan θ increases as the slop-angle θ also increases, so that spaces of equal area in the object-plane will appear distorted into spaces of gradually increasing size towards the edges of the image. Also called *positive distortion.*—(C. F. P.)

Distortion of skull. Cranial asymmetry. See **Cranial deformities.**

Distributive cells. See page 1923, Vol. III, of this *Encyclopedia.*

Districhia. An old name for distichiasis.

Districhiasis. An obsolete synonym of distichiasis.

Districhosis. An unused synonym of distichiasis.

Distruzione del sacco lagrmiale. (It.) Extirpation of the lachrymal sac.

Disturbi visivi senza reperto ottalmoscopico. (It.) Visual disturbances without ophthalmoscopic changes.

Disuse-amblyopia. Argamblyopia. Defective vision from non-use of the eye.

Diszissionsgabel. (G.) Instrument for discission of the lens.

Ditain. Echitamine. A bitter, astringent alkaloid from the bark of Alstonia scholaris, an East Indian, Philippine and Australian tree. It is a poisonous agent, acting on the system (and ocular apparatus) almost the same as curare.

Dithymol diiodide. See **Aristol.**

Ditrichiasis. (L.) One of the numerous, discarded synonyms of distichiasis.

Dittany. The common English plant, *Dictamnus albus.* See **Diptam.**

Dittopia. (L.) Diplopia.

Dittopsia. (L.) (Obs.) Diplopia.

Dittorrhaphis. (L.) A double couching-needle, and its employment.

Diurnal motion. The apparent motion of the heavenly bodies from east to west.

Diurne. (F.) Daily.

Divaricatio palpebrarum. (L.) An obsolete term for ectropion.

Divergence. Exophoria. Exotropia. The separation of the eyes from each other by abduction of one or both. As a rule we regard the oculo-muscular condition in convergence as being the exact opposite of divergence. Although this is not always exactly true, yet in excess of divergence there is exophoria for both the distance and near fixation. The convergence near point is nearly normal. The adducting power is low (or it may be normal) and the abducting power is excessive. In insufficiency of divergence there is esophoria for distance and orthophoria or possible exophoria for near. The convergence near point is normal. The adducting power is normal and the abducting power is greatly diminished.—(J. M. B.)

A series of experiments was made by C. O. Roelofs (Graefe's *Archiv für Ophthal.*, lxxxv, page 66) to determine the *maximal divergence in different states of accommodation;* the relative position of rest while fixing an object at considerable distance, and during stimulation of accommodation by negative lenses; and finally the relative position of rest during fixation of an object at various distances. It was found that with practice and patience the experimenter reached the same maximum of divergence, whatever the amount of accommodation exerted, and, vice versa, that with any degree of divergence any amount of accommodation within the normal range could be used. During monocular vision the exophoria became gradually greater in the course of half an hour, and during monocular vision with accommodation the association between accommodation and convergence became gradually less pronounced.

The position of rest was determined in 93 persons with emmetropia, 80 with myopia and 69 with hyperopia. As emmetropes, were reckoned those persons who had not more than 0.5 D. myopia or hyperopia in either meridian. The influence of the refractive condition on the position of rest is shown graphically and in a series of tables.

Roelofs concludes that the anatomical position of rest of the eyes

of almost all human beings is exophoria; orthophoria is the result of convergence innervation; the strong inclination to orthophoria in emmetropes and ametropes with good binocular vision is the result of well-developed associations, in the first place between innervation for accommodation and for convergence, and secondly, between the idea of distance and innervation for convergence; these two associations, acquired through experience, can only be developed in the presence of good binocular vision.

In the presence of binocular vision, hyperopia often causes marked esophoria. Myopia more frequently produces exophoria, although at times it results in esophoria; while the esophoria of hyperopes depends upon the assistance afforded by convergence to the stronger accommodation needed for sharp vision, the exophoria of myopes results from the absence of association between accommodation and convergence. If binocular vision is abolished, the sense of distance can cause convergence innervation, but convergence is not necessary for accommodation.

The esophoria of myopes may be explained on the basis of a giving up of binocular vision for distance on account of the poor visual acuity, whereas at close range, binocular vision is retained, these conditions resulting in the development of an association between the perception of retinal stimuli and a certain degree of convergence.—(*Ophthalmic Literature*, Oct. 1913, p. 157.) See, also, **Muscles, Ocular**; as well as **Exophoria.**

Divergent. Separating from a common centre.

Divergent lens. A concave lens that causes refracted rays of light to diverge from a virtual focus.

Divergent rays. Rays that continually separate or diverge further and further from each other, the more they recede from the object.

Divergent squint. DIVERGENT STRABISMUS. EXOTROPIA. EXTERNAL SQUINT. The permanent monocular variety is the most common, but the alternating form is more frequent than in convergent squint. As a rule, divergent squint appears later in life than does convergent, because it is usually associated with high degrees of myopia, which condition, for the most part, is an acquired anomaly. It is also seen as a sequel of insufficiency of convergence—a condition which may be met with in any state of refraction. Excessive divergence of the axes of the orbit in the course of the development of the skull may lead to divergent strabismus (Weiss). Diplopia is of more frequent occurrence than in convergent squint, probably because binocular vision has been maintained to a later period of life.—(J. M. B.) See **Muscles, Ocular.**

Divergenza. (It.) Divergence.

Divergenzbreite. (G.) Amplitude or extent of divergence.

Divergenzfernpunkt. (G.) The punctum remotum of divergence.

Divergenzlähmung. (G.) Paresis of divergence.

Divergenzschielen. (G.) Divergent squint.

Divergenzwinkel. (G.) Angle of divergence.

Diverging lens. A concave lens, that causes refracted rays of light to diverge from a virtual focus.

Diverging meridians. This is a term used in connection with an examination for heterotropia. The ocular meridians diverge when the upper extremity of one vertical meridian is directed towards the temple while the same meridian of the opposite eye continues to be perpendicular.

Divided spectacles. FRANKLIN GLASSES. BIFOCAL LENSES. Spectacles, each lens of which consists of two parts, one for distant and one for near sight.

Divider, Nesfield's ligament. A small, sharp-pointed instrument for operating on the ocular muscles.

Nesfield's Ligament Divider.

Diving birds, Vision of. As Hess and others have shown, the accommodation of diving birds (Cormorants, Grebes, Loons) is a problem of much complexity and great interest. In the pursuit of their prey they must be guided first by distant vision in air and then in a few minutes by near vision under water, and inasmuch as the refracting action of the cornea is eliminated under water an enormous effort of accommodation becomes necessary (the human eye would require some forty additional diopters). See **Comparative ophthalmology.**

Division of cataract. Discission.

Divixtus. A Gallic physician whose name appears upon one of the ancient oculistic seals. He probably flourished in the second or third century A. D. Nothing else is known about him.

Divulsor, Prince's. An instrument, shaped like a strabismus hook, employed to separate a pterygium from its attachment to the eyeball. See the figure.

Dix, John H. An eminent American ophthalmologist, the first in the New World to perform Dieffenbach's operation for strabismus. Born at Boston in 1813, he received the degree of Bachelor of Arts from

Harvard College, in 1833, and that of Doctor in Medicine from Jefferson Medical College, Philadelphia, in 1836. In 1846 he studied the eye in various European universities. He practised in Boston, where he had a large following and was very skilful. He died in 1884.—(T. H. S.)



John H. Dix.

Dixon, James. Born in 1813, he became in 1836, a Member, and, in 1843, a Fellow, of the Royal College of Surgeons. He practised in London for many years, at first in Green St., afterwards in Portman Square. He was, for a time, assistant at St. Thomas's Hospital and Surgeon to the London Ophthalmic Hospital.

He was not a prolific writer, although he published *A Guide to the Practical Study of Diseases of the Eye* (2d ed., 1859; 3d ed., 1866), and the article, "Diseases of the Eye," in Holmes's *System of Surgery* was written by him. He also wrote a few brief articles and letters for medical journals.

Dixon was a gentleman of the old school, affable, courteous and extremely obliging. The *British Medical Journal* speaks of his "high-bred and courteous personal bearing." All agree that a better and more loyal friend could never have existed. And every human being seemed, potentially at least, to be his friend.

In 1870 he met with a sorrow from which he was never able to recover—the death of his wife. Very soon after this blow, he left London, and, retiring to his country home at Dorking, spent the remainder of his life (more than a quarter of a century) in the study of history and literature. In the retirement of this country home he died Jan. 6, 1896, aged 82.—(T. H. S.)

Dobell's solution. LIQUOR ANTISEPTICUS ALKALINUS. ALKALINE ANTISEPTIC. A rather formidable array of drugs is used in this well-known preparation. As commonly published the formula is: Potass. bicarb., Sodii benzoat. āā 32.00; Borax, 8.00; Thymol, Eucalyptol, Ol. menth. pip. āā 0.20; Ol. gaultheriæ 0.40; Tinct. persionis 15.00; Alcohol 60.00; Glycerin 250.00; Aqua dest. ad 1000.00.

The directions are to "dissolve the potassium bicarbonate, sodium, benzoate and borax in six hundred and fifty (650) cubic centimeters of water; the thymol, eucalyptol and oils in the alcohol. Mix the alcoholic solution with the glycerin and add the aqueous liquid, then the tincture of cudbear, and lastly enough water to make one thousand (1000) cubic centimeters. Allow to stand a few days, then filter, adding a little magnesium carbonate [or a little purified talc.] to the filter, if necessary, to get a brilliant filtrate."

This mixture is more frequently used in rhinology than in ophthalmology, but G. E. Blackham prefers it as a hot bath to the eye in all inflammatory diseases of that organ. He employs it as a 5 to 10 per cent. solution for this purpose.

Dochmiasis. DOCHMIOSIS. ANKYLOSTOMIASIS. See page 487, Vol. I of this *Encyclopedia*.

Dochmius ankylostomus. DOCHMIUS CERNUUS. DOCHMIUS DUODENALIS. ANKYLOSTOMA DUODENALE. A parasite found in the intestinal canal of man, giving rise to the disease ankylostomiasis. See Vol. I, p. 490 of this *Encyclopedia*.

Dodecagon. A polygon of twelve sides and angles.

Dodoens, Rembert. He was also called Dodonée and Dodonaeus. Born at Mecheln, Holland, June 29, 1517, he studied medicine at Lyons, afterwards travelling in France, Italy and Germany. He was for a short time body-physician to Maximilian II and Emperor Rudolph. At length he became professor of botany at Leyden, where he died March 10, 1585.

He seems to have been a man of warm heart, and, in spite of his Flemish ancestry, of considerable irascibility. He was, beyond all question, one of the most learned physicians of his time.

In addition to numerous valuable works of a wholly general character, he wrote "*Praxis Medica*" (Amsterdam, 1616) which contains a chapter on ophthalmology.—(T. H. S.)

Dodonæus. A Dutch physician of the 16th century, who gave some attention to ophthalmology. See **Dodoens, Rembert.**

Dodonée. A Dutch physician of the 16th century, who gave some attention to ophthalmology. See **Dodoens, Rembert.**

Dog. The brain of a young dog was highly esteemed by Pliny as a remedy for what was then called "glaucoma." Dog's milk was also used as an ocular depilatory.—(T. H. S.)

Dogiel, Jan von. A celebrated Russian physiologist, much of whose work has been important for ophthalmology. He was born Mar. 7, 1830, at Zalesia, in Lithuania. After his general training in the gymnasium at Kowno, he entered the Medico-Chirurgical Academy at St. Petersburg. Later he proceeded to Moscow, where he received the degree of Doctor in Medicine in 1863. After a number of years in political and military service, he studied at Heidelberg under Helmholtz, Kirchhoff, and Bunsen, then, for two full years, in Ludwig's laboratory at Leipsic. Returning to his native land in 1868, he became professor of physiology at St. Petersburg in the same year.

His most important contributions to our specialty are: "Zur Lehre der Irisbewegung" (with J. Bernstein, *Verhandl. d. Naturhist.-Med. Vereins*, Heidelberg, 1866); "Ueber den Muskulus Dilatator Pupillæ bei Säugethieren, Menschen und Vögeln (*M. Schultze's Archiv f. Mikr. Anat.* 1870 and 1886); "Die Betheiligung der Nerven an den Schwankungen in der Pupillenweite." (*Pflüger's Arch.* Bd. 56, 1894); "Zur Kenntniss der Eiweissreactionen und von dem Verhalten des Albumins der Lichtbrech. Medien des Auges." (*Pflüger's Arch.* Bd. 19, 1879).—(T. H. S.)

Dog-louse. The ricinus, or dog-louse, was employed in Greco-Roman antiquity as an ocular depilatory.—(T. H. S.)

Dohlhoff, Georg Eduard. A well-known German surgeon, who devoted considerable attention to ophthalmology. Born at Halle, Germany, July 24, 1799, he there studied medicine, graduating in 1819. In 1822 he settled in Magdeburg, and in 1826 became assessor (see **Legal relations of ophthalmology,** first third of article, in this *Encyclopedia*), and in 1832 Councillor in the Medical College of the Province of Saxony. His only ophthalmologic writing was "Ueber die Augenheilkunde des Celsus" (Graefe and Walther's *Jour.*, 1823). Dohlhoff died May 27, 1852.—(T. H. S.)

Doijer, D. A celebrated Dutch ophthalmologist, who taught his special subject at Leyden, Holland, for 27 years. The place and date of his birth are unknown. He was the first, however, to be appointed to the chair of ophthalmology in the Government University. He was an intimate friend of Donders, of Utrecht, and of Meyer, of Copenhagen. For a time he was military surgeon in the Dutch East Indies (Java). In 1860 he returned to his native country to resume the study of the eye. Having studied with Donders again for two and a half years, he returned to Batavia, where, in a very short time, he resigned his military position, and engaged in private practice as ophthalmologist. Becoming financially independent, he returned to his native country in 1869, being then 42 years of age. He was almost immediately elected extraordinary professor of ophthalmology at the Royal University of Leyden.

He was a man of great industry and of high moral character.

He died at Leyden, Dec. 21, 1896.—(T. H. S.)

Dolichocephalic. DOLICHOCEPALOUS. Having a skull with a long antero-posterior diameter as compared with the transverse; or having the cephalic index less than 75 (Broca) or less than 70 (Thurnam).

Dolichocephalus. A skull having a relatively long antero-posterior diameter.

Dolichos pruriens. (L.) It is the minute hairs on this plant that were once used as a remedy; and these highly irritant agents have been known to injure the eye when introduced into the conjunctival sac, or when brought in contact with the eyeball. Apart from this form of injury there is nothing specific about the minute traumatisms, and instances of ocular injury from this source are extremely rare.

Döllinger, Ignaz. A celebrated German anatomist and physiologist, of some importance in ophthalmology. Born at Bamberg May 27, 1770, son of the body-physician of the Prince Bishop of Bamberg, he pursued his academic studies at the University of Bamberg, and then studied medicine at Würzburg, Padua, and Vienna. He received the medical degree in 1794, and two years later became professor of medicine at Bamberg. In 1803 he was called to the chair of anatomy and physiology at Würzburg, a position which he held for twenty years, when he removed to Munich in order to accept the corresponding chair in the university at that place. Later, he accepted the chair of the same subjects at Landshut. His most important investigations related to the circulation of the blood, to the processes of secretion, and to embryology. He wrote, however, "Ueber das Strahlenblättchen im Menschlichen Auge" (Nova Acta Acad. Caes. Leop. nat. Curiosum,

IX, pag. 268) and "Illustratio Ichnographica Fabricae Oculi Humani" (Wirceb. 1817, 4). Döllinger died at Munich Jan. 14, 1841.—(T. H. S.)

Dollond, John. The inventor of achromatic lenses. Born at London, Eng., June 10, 1706, he followed for many years the occupation of his father, that of silk-weaving. However, his leisure hours were all employed in the acquisition of a thorough knowledge of physics, mathematics, and the ancient languages. In 1752, he gave up weaving and entered into partnership with his son Peter, who for a number of years had been in the business of manufacturing optical instruments.

In 1758 Dollond invented the achromatic lens, a device which, in the opinion of Sir Isaac Newton, was an absolute impossibility. Newton had, in fact, declared that "all refracting substances diverge the prismatic colors in a constant proportion to their mean refraction," and believed the matter to be beyond dispute. Euler, in 1747, suggested the possibility of an achromatic lens-system, basing his belief on the mistaken assumption that the human eye is achromatic. Dollond, proceeding further, discovered the basic fact that flint glass does really produce a greater dispersion in proportion to its refraction than does crown glass. The rest of the problem was easy. He merely combined a double-concave lens of flint glass with a double-convex lens of crown glass. The images produced by the combination (a proper proportion between the constituent lenses being observed) were, though enlarged, yet absolutely achromatic.

In 1761 Dollond became a Fellow of the Royal Society and Optician to the King. A little later in the year, while reading a work on astronomy, he was stricken with apoplexy and soon died.—(T. H. S.)

Dolomedes. One of the order of Spiders whose bite is said to be poisonous. When the skin of the lids or of the neighborhood of the eye is involved the usual symptoms of local poisoning occur.

Dolor oculi. Eye-ache. Ophthalmodynia. These are indefinite terms applied to those pains that, from many different causes, affect the eyeball and the region of the orbit. Although they generally result from eye-strain, yet they often form one of the symptoms of certain inflammatory diseases of the eye, neuritis, nasal sinus disease, etc., or they occur as part of a neuralgia or hemicrania. The *treatment* of this symptom is, of course, entirely dependent upon its cause.

Domats. (F.) A place in the department of Yonne, France, where there is a spring the water of which is used by the inhabitants for affections of the eyes.

Dombrowski, John Paul. A well-known ophthalmologist of central Illinois. Born in Poland in 1857, he removed with his father's family at a very early age into eastern Germany, where, at Königsberg, he received his preliminary education. His medical degree he received at the University of Berlin in 1880.

Taking a surgeoncy on a steamer in the Brazil trade, he made many trips to South America. On one of these trips he formed the acquaintance of a Mr. Wolff, editor of a German newspaper at Peoria, Ill., who persuaded him to settle in Peoria, Ill., where he soon acquired a large and lucrative practice, not only in Peoria but in the entire central part of Illinois.

In 1894 he returned to Germany for further study and research. Returning to Peoria, he was even more successful than before. He was an indefatigable student, spending many hours daily at his books and at the expense of his health. For many years before his death he suffered much from digestive disturbances. It was his habit to rise at 4 or 5 a. m., light the fire prepared in a stove in his study, and then crawl into an arctic sleeping bag, and read the current English, French and German literature of his special field. On the stove he kept a pot of coffee from which he drank to excess.

He spent considerable time in perfecting himself in operative surgery of the head, sending to Chicago for dissecting material. This material was kept in an old ice-box in a back room of the house. One cadaver, that of a child, was sent directly to the house by mistake, where it was opened in the presence of the entire family, and the consternation that ensued may be easily imagined.

In appearance Dombrowski was tall and slender, with heavy black hair, brushed à la pompadour. His eyes were very black and piercing, and he wore a small black mustache. He spoke with a marked German accent, which he was unable to overcome in spite of much study.

His recreations were very few. He was fond of music, and was an accomplished pianist. He was a member of a German bowling club, although he attended very irregularly. One of his few luxuries was his team of magnificant black horses. These he delighted to drive at breakneck speed, caring little whether the carriage ran on two wheels, or the usual four. This habit was so confirmed that Mrs. Dombrowski and his three children would never ride with him.

In the spring of 1904 he was stricken with pneumonia, and had so little resistance that he could not recover. He died at his home in Peoria, March 28, 1904, aged 47.—(T. H. S.)

Domestic animals, Ocular diseases of. See **Veterinary ophthalmology.**

Dominance, ocular. DOMINANT EYE. The theory that either the right or left eye is the chief eye—the one preferably used for vision when a choice has to be made—and the one related to right- or left-handedness—has been taught by a number of observers. Durand and Gould (*Jour. Am. Med. Assocn.* July 30, 1910) suggest, for the purpose of detecting the dominant eye, the use of a screen 4 by 12 inches, in the center of which is an opening with a tube 4 inches long extending from it. The patient directs the eyes at a white disk hung on the opposite wall, then holds the screen at arm's length and looks through the opening. Only one eye can see the disk through the opening, and one will naturally use the eye with which he is accustomed to see things best. Covering the other eye the disk still remains visible, but on covering the dominant eye, it disappears.

Of fifty-eight left-handed persons with equally good vision in both eyes, whose ocular dominance Enslin (*Münch. Med. Wochenschr.* 57, 1910) examined by the Rosenbach test (holding a pencil between the eyes and a small object across the room and then closing one eye), twenty held the pencil before the left eye. On the other hand, all the right-handed individuals with equal vision in both eyes, who were examined, held the pencil before the right eye.

Donaldson, Ebenezer. Born in County Cork, Ireland, he studied at the Dublin School of Medicine, and, after the completion of his work, settled in Londonderry. He founded the Londonderry Eye, Ear and Throat Hospital, of which he was joint surgeon with Dr. Hunter. He never entirely relinquished general practice, but much of his practice was ophthalmic, and he was a constant contributor to the *Ophthalmoscope*. He died in 1909, aged 49.—(T. H. S.)

Donberg's capsule forceps. This is one of the many instruments intended to remove a portion of the anterior capsule as a part of the



Donberg's Capsule Forceps.

operation for cataract extraction. See page 1692, Vol. III, of this *Encyclopedia*.

Donders, Frans Cornelis. One of the greatest ophthalmologists of all time. He was born May 27, 1818, at Tilburg, in Noord-Braband, Holland, the son of a merchant who died a year later. Of nine orphans, the subject of this sketch was the only boy. From his 13th to his 17th year, he attended the Latin school at Boxmeer, where, from all

accounts, the instruction in everything excepting Latin only, was extremely poor. The mother desired her son to become a theologian and minister, and Donders, it seems, for a time attempted to develop himself in accordance with his mother's wishes—though all the while his predilection ran toward natural science. In contests such as these,



Frans Cornelis Donders.

youth, eventually, is seen to have its way. So, in 1835, the subject of this sketch began his medical studies in the military-medical department of the University of Utrecht. After several years of study there, also at Vliessingen and at The Hague, he proceeded to the University of Leyden, where he received his medical degree in 1840. His thesis

was entitled "Dissertatio Sistens Observationes Anatomico-Pathologicas de Centro Nervoso."

He was then for a time "Lector Anatomiæ et Physiologiæ" at the Royal Military-Medical School at Utrecht. This position he resigned in 1848, in order to accept the extraordinary professorship of these subjects in the Utrecht University. Now 30 years of age, and renowned in both anatomy and physiology, he had not even dreamed of devoting his attention especially to ophthalmology. Little by little, however, because of his investigations into the anatomy and physiology of the eye, he was drawn to the specialty in which he was soon to become so famous. The change was much assisted by the fact that, as physiologist, he was frequently consulted by practising physicians with regard to questions of physiologic optics.

In 1851, the *annus mirabilis* for ophthalmology (for was not that the year in which the ophthalmoscope was invented?) he went to London to attend the first great exposition in that city, and, while there, he chanced to call at the house of Sir William Bowman, the noted English oculist, and, as luck would have it, whom should he meet in that house but the celebrated German ophthalmologist, Albrecht von Graefe? Between these three warm-hearted, as well as distinguished, men, arose at once an intimacy that was never broken up until, in 1870, the youngest of the trio, the lamented Albrecht von Graefe, was removed from the circle by death. Until that date, however, these three men were in constant correspondence with one another. They were, in fact, a constant source of stimulus and encouragement, each to the other two, and of aid and assistance to one another in every proper way.

From the time of his meeting with Bowman and von Graefe, the ophthalmologic genius of Donders seems to have been thoroughly aroused. He had written on ophthalmology before this time, but now first one epoch-making book or article on the favorite subject, and then another, came sparkling from his pen—for he always wrote with a crystalline clearness and with a kind of *verve* which showed his heart was in his work.

In 1852 he was made professor-in-ordinary of ophthalmology in his home university. From that time forward he wrote more brilliantly than ever.

His masterpiece was entitled "*The Anomalies of Refraction and Accommodation*" (ed. by New Sydenham Society, 1864; German trans. by Otto Becker in 1866; an Italian, by A. Quaglino, and a French by de Wecker in "*Manuel d'Ophtalmologie*"). This epoch-making affair has not been wholly superseded even to the present

day. What ophthalmologic library, indeed, can be considered complete without a copy of "Donders"?

The most important of his other writings are as follows:

(Composed before the meeting with Bowman and von Graefe:)

1. "De Bewegingen van het Menschelyk Oog" (1846).

2. "Ueber die Bestimmung des Sitzen der Mouches Volantes" (*Zeitschr. für Physiolog. Heilk.*, 1847). For further historical information on this subject, see, herein, the sketches of **Deschales** and **Pitcairn.**

3. De Anwending van Prismatische Brillenglazen tot Genezing van Scheelzien" (*Het Nederlandsch Lancet,* 1848).

(After the fateful meeting:)

4. "De 1852: Voedings-Beginseln. Grondslagen Eener Algemwene Voedingsleer."

5. "Over den Invloed des Luchtdrukking op de Hartswerking" (*Ned. Lancet*).

6. "Bewegingen van Longen en Hart by de Ademhaling" (1853).

7. "De Werking der Oogspieren" (1854).

8. "Over de Verhouding der Onzichtbare Stralen van Sterke Breekbaarheid tot de Vochten van het Oog" (1854).

9. "Over den M. Cramptonianus en Over het Accomodatie Vermogen by Vogels" (1855).

10. "Winke über den Gebrauch von Brillen" (1858).

11. "Het Lichtbrekend Stelsel van het Menschelyk Oog in Gezonden en ziekelyken Toestand" (1861).

12. "Astigmatisme en Cilindrische Glazen" (1862).

13. "De l'Action des Mydriatiques et des Myotiques" (1865).

14. "Invloed der Accomodatie op de Voorstelling van Afstand" (1869).

15. "Het Binoculaire zien en de Herkenning der Derde Dimensie" (1869).

16. "Explication sur les Systénes Chromatiques" (1882).

From 1855 until his death, he acted as co-editor with Arlt of the Graefe "*Archiv für Ophthalmologie.*"

In 1858 he founded the "Nederlandsch Gasthuis voor Ooglijders" (Eye Hospital for the Netherlands). The funds for the institution were all contributed voluntarily by the Dutch people.

Donders also invented a number of ophthalmic instruments and apparatuses. Of these the most important is his "Ophthalmotonometer."

In 1866-67 he founded his physiologic laboratory which soon was known throughout the ophthalmologic world. In fact it was in this

laboratory that many of Donders' most important discoveries and inventions were made.

On the occasion of his 70th birthday, a notable festival was held in Utrecht, laymen and doctors alike participating. Very much sorrow, however, was shown, as well as joy, on this celebrated occasion, for, by the rigorous laws of Holland, a man of 70 years must leave forever his position as a teacher.

Soon after the 70th birthday, with its elaborate festival and its strange commingling both of joy and of grief, Donders proceeded again to London, where he was honored in every way. While, however, he was in that city, he suddenly lost the faculty of speech. His memory, too, very soon began to fail. Then consciousness itself disappeared, and, at length, on Mar. 24, 1889, he passed away—honored and mourned, it is scarcely necessary to add, by many thousands.—(T. H. S.)

Donders' isoscope. An instrument consisting of two sets of parallel vertical wires, one of which can be superimposed on the other; it is designed to show that the vertical lines of separation of the retina do not correspond exactly to the vertical meridians.

Donders, Painful accommodation of. This symptom-complex refers to the asthenopic accommodation of hysteropes. It is also known as the *hysterical kopiopia* of Förster, as well as the *hyperesthesia of the ciliary muscle* of Nagel.

Donders' pseudo-isochromatic wools. See **Color sense and color-blindness,** in Vol. IV, p. 2458, of this *Encyclopedia.*

Donders' reduced eye. See **Reduced eye**; as well as **Physiologic optics.**

Donegana's operation. For iridodialysis. By means of a special needle the iris is first detached and then incised from its circumference toward the center.

Donné, Alfred. A Parisian anatomist, physiologist, and hygienist, of some importance in ophthalmology, because of his "Recherches Physiologiques et Chimico-Microscopiques sur les Globules du Sang, du Pus, du Mucus, et sur ceux des Humeurs de l'Oeil" (1831). He was born at Noyon (Oise) in 1801, received his medical degree in 1831, gave courses in microscopy, and was appointed sublibrarian to the Faculty. He died Mar. 7, 1878.—(T. H. S.)

Donné's galactoscope. This is an ocular testing instrument for determining the percentage of cream in fresh, unboiled milk. The instrument consists of two parallel pieces of glass fixed in two copper tubes which screw into each other so as to be easily approximated or separated. The milk to be tested is dropped between the glasses by means of a funnel, and the former are separated until the film of

the milk is sufficiently thick to obscure the light of a candle at the distance of a metre. From the degree of separation of the glass the percentage of cream is calculated.

Donovan's solution. SOLUTION OF ARSENOUS AND MERCURIC IODIDES. Each 100 cc. contains a gram each of arsenous iodide and red mercuric iodide. This is a well-known antiperiodic and alterative, given in 5 to 10 minim doses, for a number of skin eruptions—especially of luetic origin—and other affections of the eyes in common with other organs of the body.

Doppelbilder. (G.) Double images.

Doppelbilder, Gekreutze. (G.) Crossed diplopia.

Doppelbilder, Gleichnamige. (G.) Homonymous diplopia.

Doppelfokusgläser. (G.) Bifocal glasses.

Doppeltsehen. (G.) Diplopia.

Doppelzapfen. (G.) Twin cones.

Dorea. An obsolete term of unknown origin, synonymous with hemeralopia.

Dor, Henri. A celebrated Franco-Swiss linguist and ophthalmologist. Born at Vevey, Switzerland, Oct. 4, 1835, he received his medical degree at Zurich. He then pursued the study of ophthalmology in many lands, in each of which he acquired a consummate mastery of the language. His most important ophthalmologic teachers were: in Vienna, Jaeger; in Berlin, von Graefe; in Paris, Sichel and Desmarres; in London, Bowman and Critchett; and, in Edinburgh, the almost equally famous William Mackenzie.

Still later, Dr. Dor went to Utrecht, where he studied with Donders. Now, Donders himself was a very accomplished linguist, and the following story is told of the meeting of these two "word-masters." Said Donders, in addressing his class that day, "Gentlemen, we are honored by having among us a doctor from foreign parts. After today I shall address you in French." Dor interposed at once, saying that, in a very brief time, he would be able to understand Dutch. But Donders could not be moved. Said he: "This university is open to all the world, and, if a German arrives, I shall lecture in German; if an Englishman, in English." Then he added, with a smile, "And every student of medicine should be able to understand these languages."

Returning to Switzerland in 1860, Dor settled at first at Vevey. Seven years later, however, he removed to Berne, in order to accept the chair of ophthalmology in that university. In 1876 he moved again—to Lyons—hoping to be appointed to the chair of ophthalmology in the university there. Gayet obtained the chair, but Dor continued to reside and to practice at Lyons until his death, a long time later.

Dor, though never professor of ophthalmology in Lyons, nevertheless founded in that city an eye-clinic, in which it is said he cared for 35,014 patients in 35 years (1877-1912).

Together with Edouard Myer, of Paris, he founded in 1882 the "*Revue Générale d'Ophtalmologie.*" The editorship of this excellent publication he retained until his death.

Dor was one of the founders of the French Ophthalmological Society and of the Heidelberg Congress, and was also a foundation



Henri Dor.

member of the Oxford Ophthalmological Congress. He was a Chevalier of the Légion d'Honneur and of the Mérite Agricole, and had also been honored by numerous other decorations.

One of his hobbies—if so it may be called—was Esperanto. As was said by one of his friends, "He taught, thought and dreamed Esperanto." His knowledge of nine modern and of five ancient languages seemed only to have emphasized and impressed upon him the full length, breadth and depth of the Babylonian curse—as well as

its extension in time. He was fond of saying that the greatest bar, not only to scientific progress, but also to the brotherhood of man, was the existence of hundreds, even thousands, of different tongues, constructed in accordance with every conceivable rule of unreason and folly.

Speaking of "the brotherhood of man," we may very well say that this expression forms, as it were, a key to the personal character of Henri Dor. For Dor was indeed a brother to every human being. He was always cheerful, genial, jovial, kindly, courteous, and, above all things, practically helpful. The present writer recalls the fact that, only a few years since, when he had had occasion to inquire in France regarding certain matters of Gallic ophthalmology, he was referred, as the merest matter of course, to Henri Dor. "Dor will tell you all about it, and be glad of the opportunity." And so it proved. Dor wrote, and wrote fully. Later, unasked, he wrote again, fearing that he had not made his former letter altogether clear. Then, in a week or thereabouts, he wrote once more, to add some bit of information which he had omitted from both the former letters, as a matter of course inadvertently. And so the man ever was, to those within and to those without his well-beloved profession, according to the reports of all who communicated with him either personally or by correspondence. He had rather, far rather, incommode himself than any other person living. He was also a man of singular purity of character. "Dor," in French, means "of gold," and, for this reason, the great ophthalmologist was appropriately named; for he had a heart of gold that was gold and gold only, from center to circumference, without one taint of dross.

Dor was a tall, thin, spare man, cursed with extreme myopia, but of such enormous industry and intelligence that even that serious handicap appeared to him to be only a slight drawback.

He died Oct. 28, 1912. May his memory be cherished, for he was more than merely a celebrated linguist and a skilful ophthalmologist; he was a true friend and a good man.—(T. H. S.)

Dormiol. Choral-amylene hydrate. This nervine calmative is a mixture of anhydrous chloral with amylene hydrate. It is an oily, colorless fluid, with an odor of camphor and a cooling taste. It does not mix with water but ethyl alcohol and fixed oils readily dissolve it. Würdemann advises it as a safe and reliable hypnotic after cataract extraction. The dose is ½ to 1 dram (2-4 cc.) of a ten per cent. solution.

Dornapfel. (G.) Datura stramonium.

Dornaugig. (G.) Having the eye furnished with spinous processes.

Dornblüth, Friedrich Karl. A German military surgeon, of a slight ophthalmologic importance because of his "Bau der Cornea Oculi" (*Zeitschr. für Rat. Med. N. F.*, Bd. VII and VIII). Born at Plau, in Mecklenburg, July 31, 1825, the son of a well known physician, Albert Ludwig Dornblüth, he studied at Rostock, Leipsie and Heidelberg, receiving his medical degree in 1849, not in 1825 (the year of his birth) as Hirsch's "*Biographisches Lexikon*" will have it. After considerable service as military physician, he settled as practising physician in Rostock, where, in 1899, he became Medical Councillor. —(T. H. S.)

Dorrell's needle. This is a paracentesis needle (see cut) for the preparation of vaccines from the aqueous. To prevent contamination of the aqueous, the conjunctiva at the point of entry of the needle point is cauterized.

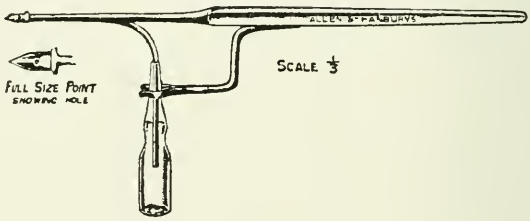

Dorrell's Needle for taking Fluid from Aqueous or Vitreous for Preparation of Vaccines.

Dos. (F.) The back.

Dosten. (G.) *Origanum vulgare* (q. v.) one of the sources of absinthe.

Dots, Gunn's. Crick dots. Small, yellowish points seen at the macular region. See page 3560, Vol. V, of this *Encyclopedia;* also **Gunn's dots.**

Dotted cataract. See p. 1486, Vol. II of this *Encyclopedia.*

Dotto della glandola lagrimale. (It.) Duct of the lachrymal gland.

Double-bodied microscope. A microscope which is so constructed that the object under examination can be observed simultaneously by more than one person.

Double concave lens. A lens, both surfaces of which are concave.

Double cones. Twin cones. In some instances these elements of the retina show peculiar modifications in which the cone-cells are double, as described on page 2773, Vol. 4 of this *Encyclopedia.*

Double convex lens. A lens, both surfaces of which are convex.

Double extension. An arrangement by which the base-board of a camera may be extended to nearly double its length.

Double-image prism. A prism consisting of two right-angled prisms of quartz or calcite, cemented together so as to form a prism of rectangular section, being used to split a single ray of light into two divergent rays. A double image prism, also called *bi-refringent prism*, may be used to measure the dimensions of an optical image, such as that on the cornea by means of the Javal-Schiotz ophthalmometer.

Double inversion. An example of what must be one of the rarest of occurrences is reported by George F. Arps (*Annals Ophth.*, July, 1914). A 7-year-old boy, whose father is ignorant and dull and whose mother is illiterate, intemperate and immoral, during the first month of school attempted neither reading nor writing. At the end of the fifth or sixth week he was induced to attempt to write on the blackboard, when it was discovered that the child appeared to perceive the letters of the copy upside down and backwards. The following examples illustrate: The words "cow," "come," "in," "see" and "rat," when written on the blackboard were copied as follows: ,,cow,, ,,come,, ,,in,, ,,see,, ,,rat,,. When the words were written upside down and backwards, he copied them right side up and forwards. After six months of school he sometimes but not always copied correctly. See **Mirror writing**, as well as **Inversion.**

Double prism, Maddox. This valuable instrument, for the measurement of anomalies of the oculomuscular balance, consists of a prism of 175°, so worn that the apex bisects the pupil and produces uniocular diplopia, the two objects thus seen determining the line of equilibrium for the other eye. See, also, **Muscles, Ocular**; as well as **Examination of the eye.**

Double projection. This condition is exemplified in a case reported and discussed by Stirling and Maddox (*Ophthalmoscope*, Vol. II, p. 660, 1913). Stirling presented a case of transient and variable phoria, varying from 7 degrees esophoria to slight exophoria, and to 10 degrees esophoria, according to tests employed, rod and deflecting prisms being used, a second case of similar variability but showing also vertical imbalance, and a third in which esophoria shows by rod test, but with a 2 degree prism, base out, it is converted into exophoria up to 6 degrees. With finger test there is distinct exophoria. This case had a marked deviation in early life.

Maddox discussed these erratic findings and felt that they were due to double projection, a true and an acquired projection. This was formerly designated as "false macula," but projection being a cerebral and not a retinal act, the term projection was preferred. Stirling's test with prisms deflected the line to such a point that the

other projection was forthcoming, and this converted an esophoria into an exophoria, or vice versa, and thus clouded the findings. Temporary squint disappearing with changes in refraction and with growth, or hyperphoria at first uncompensated, might thus explain the first case.

Double refraction. In *optics,* a twofold deviation of a ray of light in passing through certain crystallized substances, first discovered by Erasmus Bartholinus, 1669, in Iceland spar, a rhombic crystalline form of carbonate of lime, also called calcite. When a ray of light falls on a calcite crystal it is not refracted according to Snell's law of refraction, but forms two refracted rays, one of which does not necessarily lie in the same plane as the incident ray and the normal to the refracting surface. On looking through a crystal of calcite placed over an illuminated pin-hole, two bright images are seen. If the eye is placed vertically above the crystal, and the latter is rotated, one image is stationary, and is termed the *ordinary image.* The second image is displaced from the first in a direction parallel to the shorter diagonal of the rhombic face through which it is observed; this image rotates with the crystal, and is termed the *extraordinary image,* projected by the *extraordinary rays.*—(C. F. P.)

Double sensation. A term applied by Hilbert (*Klin. Mon. f. Aug.,* 52, May, 1914, p. 706) and others to color audition, that is to sensations which, arising from adequate excitations of a sensory nerve, elicit simultaneous perceptions in a second sensory nerve. For example, Hilbert observed for years the following case of acoustic photisms: A woman, musically highly educated, has, when hearing musical pieces, perceives moving and acting persons. They wear the most variegated costumes and appear on foot or on horseback. At each piece of music the same persons appear always and always in the same play; never in other scenes, or scenes belonging to other pieces. She considers these accessory perceptions as perfectly natural and as belonging to the music. See **Chromatic audition**; as well as **Color-music.**

Double sight. An obsolete term for diplopia.

Doublet. A magnifying glass composed of two lenses superposed, and so combined as to reduce or prevent aberration. The smaller, nearer the eye, receives the rays refracted by the larger one (which is nearer the object) before they reach their focus.

Double vision. See **Diplopia.**

Doubling. This is a term used in ophthalmometry that corresponds to the French term *dédoublement.* See **Ophthalmometer.**

Douche d'air chaud. Hot air douche.

Douche, Eye. This is an old and simple device for applying hot or cold fluids (plain or medicated) directly to the eye and conjunctival sac. They may be used either as a spray or in irrigation, and supply useful methods for the local application of remedies. They are gen-

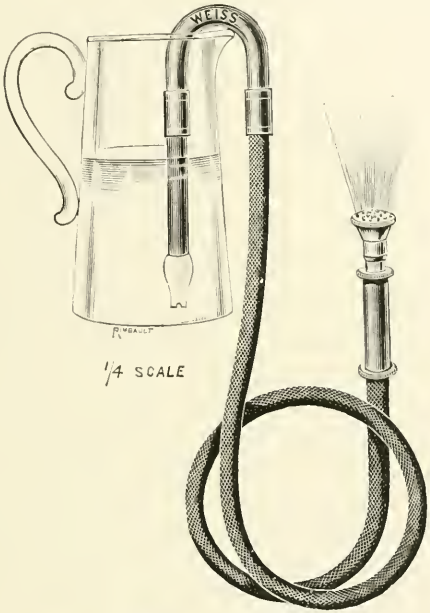

Bader's Eye Douche.



Bowman's Eye Douche.

erally employed to cleanse the eye of secretions, as well as to raise or lower the temperature of the eye and to apply remedies to corneal ulcers and other lesions. Care must be observed, in the former instance especially, not to direct too forceful a stream of liquid against the eyeball. The so-called *eye-cup* and *undine* are modifications of the douche. Sometimes, also, the last-named is made double-walled to contain ice for refrigerating purposes.

Douche, Steam eye. A form of hot steam or alcohol atomizer suitable for the treatment of corneal ulcer has been invented by several sur-

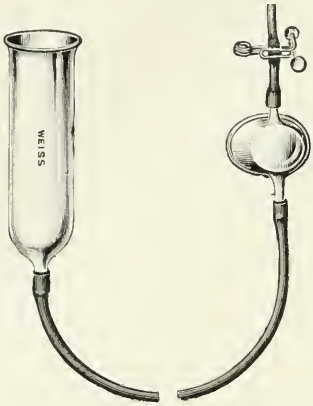

Rayner Batten's Eye Douche, for Continuous Treatment, Based on the Hydrophthalmoscope.

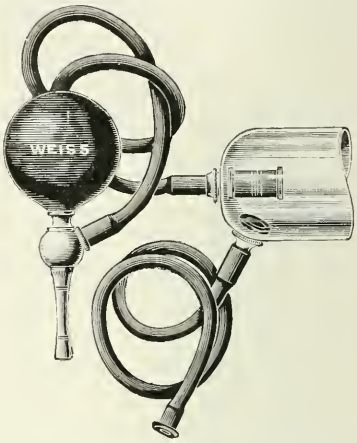

Eye Douche with Glass Eye Cup, Provided with India-rubber Ball and Tubes.

Schweigger's Eye Douche.

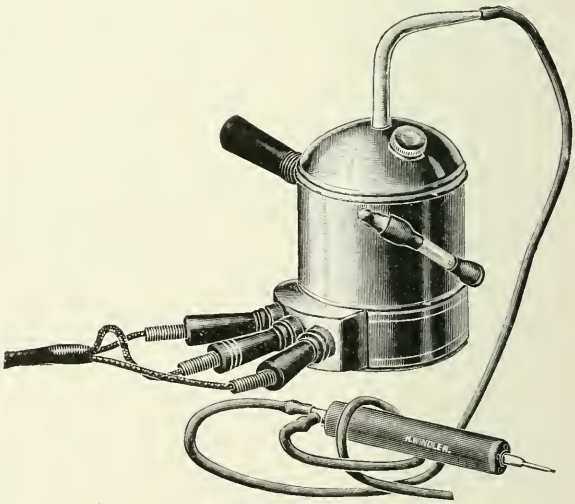

Wessely's Steam Eye Douche.

geons. Wessely has devised one in which the temperature of the vapor may be made to vary from 78° to 98° C. See the cut.

The apparatus of Perlmann (*Klin. Monatsbl. f. Augenheilk.*, June,

1910) is much simpler and is intended to supply hot steam only. The inventor uses it in many painful diseases of the face and eyes.

Douleur. (F.) Pain.

Dove. In ancient Greco-Roman times the blood of the dove was highly esteemed as a remedy for nyctalopia and for *hyphema conjunctiva*. The dove must be of a wild sort—the male was preferable to the female—and, best of all, was a male wood-pigeon, or ring-dove (palumbus). The blood was only properly to be secured from a vein on the under surface of the wing, or by plucking out a large feather, and then the life-filled remedy was squeezed out hot, and allowed to drop directly into the eye.—(T. H. S.)

Dove, Experiment of. In studying the anatomy of contrast, Dove experimented with colored shades the result of placing a colored glass opposite a mirror. We then see two images of a white object, one by reflection from the anterior surface of the glass, the other by reflection from the mirror; this latter has the color of the glass, since the rays have passed through the glass twice. The first, which ought to be white, shows by contrast the complementary color. With a black object on a white ground, the sash of a window for example, we have the phenomena reversed. See, also, **Color mixture.**

Dove's stereoscopic lustre. See **Color mixture, Binocular,** in Vol. IV, p. 2400, of this *Encyclopedia.*

Down-growths. Epithelial invasion. This term is commonly applied to those penetrating wounds—operative and other—of the eyeball in which the epithelium covering the globe penetrates into its interior. A good example of this process is seen in many of the operations for glaucoma. The conjunctival or corneal epithelium sometimes lines or, indeed may be the cause of, the operative fistules or fistulettes that exert a beneficial action on the disease by establishing permanent drainage of the ocular interior. Morax and Duverger (*Annales d'Oculist.*, Jan. 1909) early referred to penetration of the corneal epithelium into the anterior chamber. Epithelial penetration of the eye is seen only after perforating wounds; one case has been quoted by Meller, in which this complication followed a perforating ulcer of the cornea, but an iridectomy had subsequently been performed. It occurs most frequently after accidental wounds, usually by sharp-pointed implements, such as scissors, forks, etc., and this class of case is almost always in children under the age of 10. Instances in which the condition follows operation wounds, are usually met with in patients operated upon for cataract.

Published cases indicate that a peripheral position of the corneal wound, irregularity of its edges, delay in healing by inclusion of iris

tissue or lens capsule, are conditions favorable to the occurrence of epithelial invasion. When healing is complete a prolonged period of quiet ensues, in which the eye is free from any sign of irritation: this period has varied from 10 months (in one of the author's cases) to ten years (in a case of Stoelting's). After this period of quiescence, the first indications of the complication become manifest: these may be anatomical alterations of the anterior chamber, the development of cysts of the iris, or symptoms of ocular irritation. In the author's first case, these symptoms included intense photophobia, lachrymation and blepharospasm, peri-ocular pain. Whatever may be the explanation of these symptoms, the writers think it important to point out that they may be present at a stage in which there are no recognizable signs of the formation of an epithelial cyst. The second phase of the affection is characterised by the appearance of a cyst, or cysts, in the anterior chamber; and the third stage is usually one of hypertony.

The prophylaxis of this complication of penetrating wounds is to be found in the perfect coaptation of the lips of the wound, and the absence of any inclusions of iris or capsule, conditions which are often difficult of achievement especially in accidental wounds. Treatment consists in the removal of the eyeball, or of its anterior segment. Ablation of the cysts, which has been accomplished, gives only a temporary result. There is, however, no evidence to show that epithelial invasion ever extends posterior to the barrier offered by the zonule and lens capsule, and hence retention of the posterior segment of the globe is, so far as recurrence of cysts is concerned, unobjectionable. (Review by J. B. Lawford, in the *Oph. Review,* June, 1909.)

Doyne's cataract. Discoid cataract. Coppock cataract. Nettleship's cataract. Priestley Smith (*Trans. Ophth. Soc. U. K.,* XXX, p. 37, 1910) has suggested that the condition previously spoken of as Coppock cataract, and first demonstrated by Doyne, should be permanently distinguished by the name Doyne's discoid cataract. He has worked out an interesting new pedigree of the condition, including fifty-one descendants, of whom twenty-six, or 50.9 per cent., are affected. Of the latter fifteen are male, and eleven female. The men are largely farm laborers, but some are coal miners. With one exception every affected person who has had offspring has transmitted the disorder, the exception being a man who has at present only one child. There is no instance of parents both of whom were unaffected producing an affected child.

According to Collins and Mayou (*Pathology and Bacteriology,* p. 41) congenital, triradiate opacities of the lens are in this form of cataract met with both in front and behind the nucleus, and are some-

times seen on the anterior surface of lamellar cataract. They are also met with behind the nucleus in the disc-shaped opacities which are often hereditary. These cataracts must be distinguished from discoid cataracts in which the whole lens has the shape of a disc. In Doyne's cataract it is the area of opacity in an otherwise normally shaped lens which is discoid. See **Coppock cataract**; as well as p. 2868, Vol. IV, of this *Encyclopedia.*

Dragon tree. DRACÆNA DRACO. The sap of the dragon tree was used by the ancients to remove corneal opacities.—(T. H. S.)

Drahtgitter. (G.) Ocular protector. Wire mask.

Drahtschlinge. (G.) Wire snare, or loop.

Drahtsiebbrillen. (G.) Protective spectacles of wire gauze.

Drain. (F.) Drainage-tube.

Drainage à demeure. Fixed or permanent drainage.

Drainage, Capillary. Although this procedure for the treatment of hypopyon ulcer of the cornea has many evident drawbacks, yet it has been advised for the purpose by Rollet and Moreau. See **Capillary drainage.**

Drainage, Ocular. INTRAOCULAR DRAINAGE. Under the caption **Circulation of the intraocular fluids** this subject has already been to a large extent discussed. In addition it may here be noted that in an essay on intraocular pressure and drainage Schoenberg (*Archives of Ophthalm.*, March, 1913) calls attention to the well-known fact that when the Schiötz tonometer is continuously applied on the eye a certain length of time the tension gradually decreases, which means that a certain amount of fluid has been expressed from the eye.

He defines the index of ocular drainage as the rate or rapidity with which the ocular fluid may be expressed by the weight of the tonometer applied on the eye.

The intraocular pressure may be low in a certain eye, and yet the drainage capacity may be impaired and the elucidation of this fact may clear up the diagnosis in doubtful cases of incipient glaucoma.

Investigation by this method of the eyes of two rabbits and three patients with optic atrophy, showed that the index of drainage is not the same in every patient or in the same eye at different periods.

Investigation of a number of eyes in varying stages of glaucoma showed an impairment of function. In patients with a tension within normal limits and yet a condition of latent glaucoma, the diagnosis may apparently be cleared up to a certain extent.

Altogether he believes that there is always a gradual reduction of intra-ocular pressure if the tonometer is applied on a normal eye for a certain number of seconds.

The rate of reduction of intra-ocular pressure varies not only in various eyes, but also in the same eye if taken at different periods.

Experimental evidence seems to indicate that changes of intra-ocular pressure in one eye may often be followed by similar changes of intra-ocular pressure in the other eye.

Neither the experiments on rabbits and cats nor the examinations in the operating-room give any clue regarding the existence of a reflex or biochemical action starting from some distant region and influencing the intra-ocular pressure. The extra-ocular muscles play an important rôle in the various normal fluctuations of the intra-ocular pressure.

The ocular drainage in glaucomatous eyes differs from that of normal eyes. The slower the rate of drainage, the nearer the eye is to an acute attack or to absolute glaucoma; the more rapid the rate of drainage, the nearer to a state of compensated glaucoma. A reduction of the rate of ocular drainage may mean latent glaucoma in spite of an intra-ocular pressure which is within the normal limit (below 26 mm. Hg).

The continuous fluctuations in the intra-ocular pressure and ocular drainage in normal eyes, the relative dependence of the intra-ocular pressure on the general blood-pressure, and of the latter on the ductless glands, and the probable relation existing between the intra-ocular pressure of both eyes, suggest that the present tendency of devising all possible operative procedures for the relief of intra-ocular pressure in glaucoma is only a palliative measure. It is not logical. The essence of glaucoma is not an increased intra-ocular pressure just as a high blood-pressure is not the essence of arterio-sclerosis.

Dransart's operations. For *ptosis* and *detached retina.* In the former instance the occipito-frontalis muscle is attached to the lid by means of cicatricial bands. These are produced by threads, which are allowed to ulcerate their way through the tracks along which they were passed. For *retinal detachment* an iridectomy is done, followed by the recumbent position, a pressure-bandage, and hypodermic injection of pilocarpin.

Draw tube. A tubular sliding support in optical instruments.

Dreams, Visual images of. See **Psychology, Ocular.**

Drehachse. (G.) Axis of rotation.

Drehblende. (G.) Revolving diaphragm.

Drehpunkt. (G.) Center or point of rotation.

Drehungsaxe. (G.) Axis of rotation.

Dreifasertheorie. (G.) The Helmholtz or three-color (red, green, violet) theory. See **Color-sense and color-blindness.**

Dressings for the eye. This important subject is treated in a special way under various captions dealing with single operations. E. C. Ellett (Wood's *System of Ophthalmic Operations*, Vol. I, p. 242) remarks that the materials used for *dressing the eye after operation* are principally gauze and cotton, held in place by bandages, adhesive plaster, shields, masks, patches and shades. See, also, Vol. I, p. 142, of this *Encyclopedia*.

Surgical gauze is usually plain, not impregnated with any medicament, but sterilized by heat. A piece of suitable size and shape and two or three layers thick is applied next to the wound. If wet with a non-irritating antiseptic solution, such as boric acid, it will adapt itself more perfectly to the irregularity of the part, and thus be less apt to shift its position, though this renders it less absorbent than if applied without wetting. Some surgeons tease out absorbent cotton into a thin layer, with the fibers all running one way, and apply this, wet, next to the skin. Whether gauze or cotton be used in this way, over it is placed a pad of absorbent cotton. The size of the pad must vary with the object to be attained, varying according to whether we do or do not wish to make any pressure on the parts. In case there are cavities left in the tissues after operation, as after removal of the lachrymal sac, additional pads of gauze are so disposed as to close, by pressure, these cavities so far as possible.

It was formerly the custom with many surgeons, and is still the practice with some, to use, instead of plain gauze, that which is impregnated with some antiseptic. The ones most commonly used were the bichloride of mercury, the cyanide of mercury, carbolic acid, boric acid and iodoform. It is probably unnecessary to use any of these, in other words the dressing should be aseptic and not antiseptic, in the event of clean wounds. In the case of sloughing wounds, or surfaces, and particularly cavities, which are healing by granulation, an antiseptic gauze for dressing may have some advantages. Iodoform gauze is objectionable on account of its odor, but is thought by many to be of special value in sloughing wounds or to stimulate the granulation of bone wounds.

Wolffberg (*Wohnschr. f. Therap. u. Hyg. d. Auges*, April 2, 1908) recommends dressings made of paper wool, because this substance is convenient, absorbs freely and is better suited for making pressure. Hiers has for years used as a dressing a pad applied with adhesive plaster. He describes gauze pads especially prepared for the purpose, aseptic and kept in hermetically sealed containers. Such pads are applied and removed easily, even by those not especially trained. They cost less than a bandage, and interfere less with head-dress. Genth's experiments with infected dressings, with regard to their

influence on the healing of aseptic wounds of the eyeball, lead him to conclude that scrupulous care in sterilizing dressings is unnecessary. Even when completely sterilized they become contaminated on touching the lids, or when they take up fluid from the conjunctival sac.

Mitchell (*Ophth. Rec.*, p. 64, 1909) uses a dressing made from thin celluloid board. A piece of this is cut into shape to fit the orbit, and a sector is cut out, extending from the upper periphery nearly to the center, where its straight sides meet at an angle of 25 degrees. These sides are brought together, made to overlap one-fourth of an inch at the margin, and held in place by a paper fastener. This gives the shield a low, flat, conical form with a border that fits the parts. It is held in place by strips of adhesive plaster. Talbot (*Jour. Amer. Med. Assn.*, ii, p. 1478, 1909) has described a shield made from wire netting, either monocular or binocular, which Wyler points out is essentially the lattice shield of Fuchs that has been in use for twenty-five years.

Drittes Augenlid. (G.) Nictitating membrane.

Driver's test. This is a simple and ready device for the detection of feigned blindness. Driver interposes a vertical ruler, four centimetres broad, at a definite distance between the eyes of the patient and two of Snellen's test-types in such a way that the ruler acts as a screen hiding the right test-type from the left eye, and the left test-type from the right eye. If the patient succeeds in reading the letters on the two scales, he discloses his fraud, and at the same time indicates the degree of vision of the eye which he claims is defective.

Droit. (F.) Straight, right, erect.

Droit externe de l'œil. (F.) Abducens oculi. External rectus.

Droitier. (F.) A right-handed man.

Droit inférieur de l'œil. (F.) Rectus inferior.

Droit interne. (F.) Rectus internus.

Droits des médecins. (F.) Medical ethics.

Droit supérieur de l'œil. (F.) Rectus superior.

Dropper. Drop-bottle. Medicine dropper. Eye dropper. Drop-tube. Pipette. This useful little instrument may be described as a small glass tube, pointed and polished at one end, and having a rubber tube or cap at the other. Strohschein's eye dropper, from which the rubber top is removed for sterilization, the pipette inverted and set into the bottle with the tapering end uppermost, both being then sterilized together, is very serviceable. One precaution for keeping pipettes clean is not to allow them to come into contact with the conjunctiva or eyelashes of the patient, and to wash them out after using, in sterile water or some antiseptic solution. Drop bottles, in

shape similar to the ordinary pipettes, with a somewhat longer but blunt beak, are also in use. They require, however, skill on the part of the patient, who must hold his head approximately horizontal during the process of instilling lotions from them into the eye.

To apply solutions to the eyeball with a medicine dropper let the patient lie down, or, sitting up, hold his head slightly tilted to the right (to medicate or cleanse the left eye, to the left for the right eye) and slowly drop about ten drops of the solution upon the closed lids. A pool of the mixture will form at the inner canthus and gradually overflow into and bathe the eye from that point when the lids are opened. In this way the patient experiences no discomfort and will be able to rotate the eye-ball in all directions so that the irrigating fluid comes in contact with the whole surface.

For the purpose of making (from discs, compressed tablets, etc.) fresh solutions and preserving them from dust and other contamination, Parke, Davis & Co., have prepared a medicine bottle and dropper, consisting of a graduated bottle with a capacity of 4 drachms of liquid. The tablets may be dissolved in the necessary amount of water, and the bottle closed by a pipette of improved form, the ground sides of which fit into the neck of the bottle as a stopper, the whole forming an air-tight container. The pipette is closed at the top by means of a rubber diaphragm which, when pressed down and then released, will cause some of the solution to ascend the tube. By again gently pressing the diaphragm, one or more drops can be easily forced out.

Chalk's bottles (England) have a rubber cap on a hollow stopper and may be either of clear or amber glass for eyewaters and similar lotions. They are often surrounded with metal cases that may be sterilized and are durable and suitable for traveling.

A very convenient form of eye-dropper is a test-tube with a spout half way up the side of it. In this eyedrops may be warmed if desired and by simply inclining the tube the patient can instill the drops into his own eye. By plugging the point-end with sterile wool a solution may be kept sterile.

Single drops are instilled with best results by forming a drop at the end of the pipette and simply touching the edge of either lid with it. If the remedy, eserin or atropin, for instance, is to chiefly affect the internal eye, the method of instillation should be different. In that case the upper lid-edge should be drawn away from the globe—the patient looking down—and the single drop applied to the raised margin beneath the eyelashes. The watery solution flows over the upper palpebral surface to the upper sulcus, thence over the globar surface to the lower cul-de-sac, by which time it has been evenly dis-

tributed over the largest possible absorbing area, leaving little or none to flow through the puncta into the nose.

This consideration is of some importance when powerful remedies like duboisin, eserin, hyoscin, cocain, atropin, etc., are employed for long periods or in strong doses and one is desirous of avoiding their constitutional or toxic effects, or where, as in the case of homatropin and other expensive remedies, the fullest effect is required from the smallest dose or weakest solution. In both instances this plan serves to promote complete absorption and the maximum local effect of the instillation.

In many cases of sensitive eyes or still more sensitive patients who complain that a collyrium irritates, the eyewater should be warmed. As it is not feasible to warm the bottle each time drops out of it are to be used, the medicine dropper may be completely filled with very hot water, then emptied and a few drops of the collyrium drawn up into the pipette. The heat of the glass will be sufficient to warm the eyewater, when it should be immediately instilled.

To insure slow and complete absorption of remedies it is a good plan to dissolve them in, or mix them with, some oily or fatty menstruum such as olive, almond or castor oil, vaselin, lard, etc. These oily solutions and ointments form most valuable applications in chronic diseases of the eye.

Irrigation of the conjunctival sac and the anterior surface of the globe for sterilizing these and for the removal of discharge and other accumulations, is accomplished by means of weak solutions of any one of the antiseptics used in ocular therapeutics, e. g., bichlorid of mercury (1-10,000), normal salt solution, boric acid, borate of soda (4 per cent.), formalin, 1:5000, or sterilized water. The lavage should be copious, and is most effective when the solution is warm.

Of the many appliances at our command one of the most useful for the purposes of irrigation is the undine, although an ordinary fountain syringe, the usual hospital irrigator or a rubber tube syphon, will serve every purpose. Care should be taken that the stream of water which strikes the eye should not come with too much force and that the end of the pipette should not touch the cornea, or anterior portion of the eyeball, lest these parts be injured. Thorough flushing of the parts rather than the employment of force is the object of irrigation. The nozzle of the irrigating apparatus (the glass pipette of a large medicine dropper acts admirably) should, consequently, not be directed at the globe; it ought to be held nearly parallel with the lid edges.

In irrigating the upper sulcus and upper aspect of the globe the

patient looks down while the upper lid is gently drawn away from the eyeball. This exposes the upper cul-de-sac to the cleansing action of the irrigating stream. To cleanse the lower sac the patient looks up, while the surgeon draws down the lower lid. The stream in most cases should be directed towards the inner canthus and not allowed

Convolute Eye Dropper.

to fall directly on the eyeball. If this precaution is not taken the patient will invariably resist, by closing the lids tightly, and difficulty will be experienced in effecting a thorough irrigation.

The convolute eye dropper receives its name from a spiral glass tube arrangement in the neck of the dropper as may be seen by re-

Container and Medicine Dropper of De Lapersonne.

ferring to the cut. This "pigtail" prevents any of the solution rising into the top of the dropper and coming into contact with the rubber. This is prevented even if the dropper is allowed to lay on its side.

The bottle contains approximately one ounce and has a comparatively broad base. The rubber cap is made of the best quality bandage rubber, is greatly superior to the ordinary rubber top, besides being easily removable.

Another practical medicine dropper is the *compte-gouttes* of De Lapersonne which, however, is used as a combined container and pipette. The dropper having been filled with the sterile solution (cocain, atropin, stovain, etc.) is closed by melting the end of each

arm by the alcohol flame. When about to be used the terminals are broken off. They are marketed in six colors, each color corresponding to a particular agent; so that no label is needed. See the figure.

Dropping experiment. A simple experiment devised by Hering to show whether there is normal, binocular act of vision. A cylindrical tube, 25 cm. long, and wide enough to be looked through with both eyes, has at one end, and fastened on its outside, two long needles, which must be so bent outward that they cannot be seen on looking through the tube. A fine silken thread connects the point of one needle with that of the other. Midway between the needles is a knot in the thread, or a small bead, which then lies in the centre of the field of vision of the tube. The tube is held close before the face, with the thread horizontal, and the patient looks through the tube with both eyes; the bead in the middle serves as a fixation point. Small balls of different sizes are allowed to fall about twelve times, one after the other, some before and some behind the bead. One who sees binocularly can tell with certainty whether a ball falls within or beyond the fixation point, while one who perceives the retinal image of one eye only is frequently deceived. (Foster.)

Dropping of nasal fluid. See **Hydrorrhea, Nasal.**

Drop serene. GUTTA SERENA. An old term for amaurosis.

Drop-shutter. A rapid photographic shutter.

Dropsy, Epidemic. The only ocular complication, known to the Editor, of this tropical disease is that described by Maynard (*The Indian Medical Gazette,* Vol. 44, No. 10). He drew attention to a condition of increased intraocular tension, occurring as a complication of, or at all events, in association with, the affection. At the time of writing he had met with more than twenty cases. The ocular signs he has found are a slightly steamy cornea; a small or moderately dilated pupil, acting sluggishly to light; an absence of vascular injection; a decided increase of tension. Subjectively the patient notices dimness of sight and colored rings, and occasional pain. In two-thirds of the cases pathological cupping of the disc was present. The retinal veins were usually engorged and they and the arteries showed pressure-pulsation. In some, recovery had ensued; in others complete blindness.

Two-thirds of the patients were men, one-third women. The ages of all but two were under 36.

Maynard was not prepared to specify the exact nature of the condition he described, and its relation to epidemic dropsy.

Dropsy of the capsule of Tenon. A term applied by Carron du Villard to a variety of exudation cyst involving the capsule of Tenon.

Dropsy of the eye. Hydrophthalmia.

Dropsy of the lachrymal sac. Distension of the lachrymal sac with mucus or muco-pus.

Dropsy of the optic sheath. An accumulation of serous fluid between the outer and inner sheaths of the optic nerve, said to occur usually between the eyeball and the optic foramen; or between the optic foramen and the chiasm.

Drouot, Théophile. A well-known Parisian oculist and empiric of the early 19th century. Born at Bordeaux, in 1803, he received his medical degree at Paris in 1832. He seems to have practised mostly in Paris; part of the time, however, in Bordeaux. He wrote: "Recherches sur la Crystallin et ses Annexes" (Bordeaux, 1837); "Nouveaux Traités des Cataractes, ses Causes et sa Traitement sans Opérations Chirurgicales" (Paris, 1840, av. pl.); "Des Maladies de l'Oeil, Confondus sous les Noms d'Amaurose, Goutte Sérene" (1841); "Des Erreurs des Oculistes" (1843); "La Vérité sur le Traitement des Cataractes et sur les Résultats des Opérations Chirurgicales"—containing a vicious attack on Sichel—(1848); "Traité Médical des Cataractes, des Neuralgies, des Amauroses" (1857).

His medical treatment of cataract consisted in the use of quinine, quassia, potassium iodide, belladonna, and aconite, according to the symptoms present in the given case.—(T. H. S.)

Druck. (G.) Tension or pressure.

Druckempfindlichkeit. (G.) Tenderness to pressure.

Druckmesser. (G.) Manometer. Tonometer.

Drucksteigerung. (G.) Increase of tension.

Druckstreichungen. (G.) In massage, a combination of friction or stroking and pressure or kneading.

Druckverband. (G.) Compress bandage.

Drug conjunctivitis. This is the title commonly given to *atropin conjunctivitis*, and it may properly be applied to those uncommon cases of conjunctival follicles which are caused by the application of certain medicines (atropin, cocain, homatropin, hyoscyamin, duboisin, eserin, and arecolin) to the conjunctiva. The toxic effect may follow a single application of the drug or may come only after prolonged use of it. In the former case the skin of the lid becomes dry, red, and swollen and may appear like erysipelas. Examination will show the presence of follicles, which are particularly numerous in the lower fornix. This type of the disease is more often found in adults than in children.

In the second form, after long use of a mydriatic or miotic, there is the sudden appearance of an acute catarrhal conjunctivitis with

mucopurulent discharge. Inspection shows the presence of follicles.

Glorieux considers that the affection is a paralysis of the vasomotor nerves, with sequent dilation of conjunctival vessels. Idiosyncrasy must be a factor in some cases. A frequent cause is the presence of germs in the solution used, or the existence of a chemical impurity. Some cases are caused by the transference of septic material by unclean eye-droppers.

The use of the drug should be discontinued and hot applications of the dilute subacetate of lead can be used. De Schweinitz uses a 1 per cent strength solution of creolin in atropin conjunctivitis. Tannin and glycerin solutions are valuable remedies. The skin of the lids should be smeared with the ointment of ammoniated mercury (1 to 20). See, also, Vol. I, p. 674, and Vol. V, p. 3167 of this *Encyclopedia*.

Drummond, James L. A comparative anatomist, who did excellent work in connection with the comparative anatomy of the eye. His life dates are unknown. An Irishman by birth, he studied at the University of Edinburgh, receiving his medical degree in 1814, with the thesis, "De Oculi Anatomia Comparativa." He practised for a time in Belfast. His most important composition was "On Certain Appearances Observed in the Dissection of the Eyes of Fishes" (1815).—(T. H. S.)

Drum, Test. A cylinder, one opening of which is covered with kid or parchment for testing the sharpness of instruments.

Drüsen. Glands.

Drusen. Verrucosities of the lamina vitrea. Beard (*Semiology and Diagnosis*, p. 350) gives the following excellent account of these fundus changes: This affection may be confounded with *retinitis punctata albescens*. The anatomic feature consists in more or less numerous minute, nipple-like prominences which spring from the inner surface of the *lamina vitrea*, elevating and causing pressure atrophy of the pigment epithelium. They manifest themselves as *light spots* or *white spots* in accordance with the density of the epithelial pigment, and the altitude of the excrescences. In the darker eyegrounds, with only moderate elevation of the growths, the dots are smaller and of orange tint. With lighter eyegrounds or excessive development of the "drusen" the spots are larger, rounder, and brilliant yellow or white. Their diameter, however, is never greater than 1 mm. ophthalmoscopic magnification. They are not outlined with pigment, and they are most frequently bilateral, though not symmetrically so. Their favorite localities are the peripapillary and perimacular regions. They appear in clusters or constellations, and this consti-

tutes one of their most distinctive traits. Individually their form is not so round as that of the white spot of white punctate retinitis.

At times these growths reach such proportions as to disturb the function of the rods and cones upon which they impinge, but ordinarily they do not interfere with vision. They are essentially an expression of senility. This is the affection that was described in 1881 by Mr. Warren Tay, then assistant to Hutchinson, and that has, in consequence, been often referred to as Tay's choroiditis; and probably the same that, when situated at the posterior pole, was by Nettleship called central senile guttate choroiditis. These spots are not to be confused with Gunn's dots, which appear only in the macula and in young subjects; nor with the irregular light or white patches, alternating with pigment, in central senile atrophy. The disease is slowly progressive.

A case of drusen of the head of the optic nerve is reported by Fejer (Graefe's *Archiv. f. Ophth.*, LXXII, p. 454, 1909). The patient gave a history of prolonged illness with typhoid and kidney disease; and vision was reduced to 5/30 with contraction of the field, due to optic atrophy. In a case reported by Chevallereau (Graefe's *Archiv. f. Ophthalm.*, 73, p. 454, 1909) there were also hyaline bodies in the choroid, and cholesterin crystals in the vitreous. Vision was reduced to ¼ and ⅓.

Hesse (Graefe's *Archiv. f. Ophthalm.*, p. 219, 1910) gives the photographs of the fundus of both eyes of a woman, aged 80, showing typical drusen of the choroid in the macular region. A photograph taken three years later shows extensive changes at the macula with hemorrhage. The case raises the question whether such drusen are as harmless as is commonly supposed, or whether the subsequent macular changes may not have been a further evolution of the primary formations.

Lauber (*Zeit. f. Augenh.*, Vol. 29, p. 201, 1913) records three instances of drusen of the optic nerve. In the first case the margins of the optic nerve head were indistinct, the vessels strongly contracted. The crystals were in the upper part of the disk. Function was normal. In the second case the crystals were in the nasal portion of the papilla and the neighboring retina. There were several small scotomata about fixation in the third instance. The patient was blind in one eye and could count fingers with the other. There was optic atrophy, assumed to be due to hypophyseal tumor. The crystals were in both papillæ. The author points out that the accompanying neuritis may in some cases be excited by the crystals rather than the cause of their formation. In a patient with pigmentary degeneration of the retina, Thom-

son (*Ophthalmoscope,* Vol. 11, p. 19, 228, 254, 1913) saw in both eyes rounded, semi-translucent, grayish masses over the margin of the optic disk. He believes the nodules to have been hyaline. In a case of pigmentary degeneration of the retina in which the pigment extended almost up to the disk, Oliver (*Ophthalmoscope,* Vol. 11, p. 716, 1913) saw hyaline masses at the disk. In one eye there were oblong, glistening, semi-translucent, yellowish-white masses overlying both the nasal and temporal margins of the disk. In the left eye there were several masses of similar appearance but of more round outline. The retinal vessels lay beneath.

Drüsenartig. Resembling a gland in structure.

Dry catarrh. Hyperemia of the conjunctiva.

Dry collyria. A class of collyria for the eyes, composed of dry ingredients, generally in compressed, tablet form, intended to be dissolved in water. Originally collyria were all of this form.

Dry objective. An objective is called "dry" when the slip covering the object is separated from the objective by a layer of air.

Duane's clinometer. A device for estimating torsional deviations of the eye. This apparatus may also be used in the study of metamorphopsia.

Duane's syndrome. Duane's Table. The collective symptoms of a complex, congenital anomaly of the ocular motility. These, according to Green, are given by Duane himself as follows:

1. Complete (less often partial) absence of outward movement in the affected eye. 2. Partial (rarely complete) deficiency of movement inward of the affected eye. 3. Retraction in adduction. 4. Oblique movements up and in or down and in, in adduction. 5. Partial closure of the eyelids of the affected eye in adduction. 6. Paresis or marked deficiency of convergence, the affected eye remaining fixed while the sound eye is converging.

Fifty-four cases had been collected by Duane in 1905, and, to these, Green (John, Jr., of St. Louis, Mo.) has added four.

In general, treatment may be said to be of no use. In a single case, however, that of a young girl "without the power of adduction since two years of age," an adductive power of 30 degrees was obtained by splitting the superior and inferior recti muscles and inserting the temporal halves "at the line of attachment of the external rectus." (See *Trans. Am. Acad. of Oph. and Oto-Lar.,* 1913).—(T. H. S.)

Du Bois, Abram. Born in 1810, he died in New York City, Aug. 29, 1891. He was a pupil of Dr. Kearney Rodgers, and one of the founders of the American Ophthalmological Society. He wrote very little, but was an excellent operator and a munificent benefactor of

ophthalmology. For nearly fifty years he was attending and consulting surgeon to the New York Eye and Ear Infirmary, and, after his death, his family presented the sum of $80,000 for the erection of a new pavillion at that institution as a memorial to the husband and father. William A. Du Bois, Matthew B. Du Bois, and Catherine Du Bois, sons and daughter of Abram Du Bois, also presented to Columbia University the sum of $18,000, to be used for the purpose of founding a scholarship in ophthalmology to be known as "The Doctor Abram Du Bois Memorial Fund." The holder of the scholarship is expected to devote himself to post-graduate studies, preferably of a scientific character, connected with ophthalmology in foreign and American universities.—(T. H. S.)

Duboisia hopwoodii. The *Duboisia pituri* of Australia, a plant closely allied to *Duboisia myoporoides.* The leaves are chewed by the natives as a stimulant, and yield duboisin (q. v.).

Duboisia leichardtii. An Australian plant allied to *Duboisia myoporoides.*

Duboisia myoporoides. The cork-wood of New South Wales. It is a tall shrub found in Australia, bearing white flowers and a globular berry. The leaves contain duboisin, this plant being one of the chief sources of that alkaloid.

Duboisin. The leaf of the *Duboisia myoporoides* (corkwood elm) contains about one per cent. of alkaloids, mostly hyoscyamin, a little hyoscin and another crystalline alkaloid called pseudohyoscyamin. As a mydriatic duboisin sulphate (probably mixed alkaloidal sulphates) is used as a substitute for atropia, 1 grain to the ounce of water being considered equal to a one per cent. solution of atropia.

This alkaloid is also obtained from atropa belladonna, hyoscyamus niger, datura strammonium and several other varieties of duboisia, besides the myoporoides of New Caledonia, e. g., the D. hopwoodii, or pituri-plant, of New South Wales and Queensland. The leaves and small branches of the various varieties of duboisia are chewed by the natives as a stimulant. Duboisin is thus probably a mixture of several alkaloids. It is easily dissolved by ether and alcohol, but is not readily soluble in water. It occurs as a brownish, hygroscopic substance which is two or three times more powerful than atropia. Merck furnishes it as the hydrochloride, although the N. D. refers to the commoner salt, duboisin sulphate. This drug is prescribed as a substitute for atropin when the action of that remedy is unsatisfactory, although hyoscyamin differs little or none from it clinically, and is probably identical with part of it chemically.

Santos Fernandez (*Révue Générale d'Ophtal.,* Dec., 1912) formerly

used atropin, but since de Wecker and Panas reported so favorably upon the more powerful and less toxic effect of duboisin, has been converted to its use. Children absorb atropin very readily through the lachrymal passages, and show marked intoxications which do not follow duboisin. This also applies to adults who show drug idiosyncrasies. The action upon the nervous system of duboisin is sedative and hypnotic, and can be used with success in mania, insomnia, alcoholism, etc. Children are flushed and excited by atropin, so that the author always dilutes one drop of a one-half per cent. solution in fifteen drops of water in newborn children, as we know that atropin dilates the pupil in doses of 0.0002. In one case a young woman was delirious after atropia for several hours, and from instillations into the conjunctival sac. However, he also relates a case in which one drop three times a day of a one per cent. solution of duboisin was quite toxic. Fernandez finds the cycloplegic action of atropin and duboisin nearly equal, but the toxicity of the latter is less violent and less frequent than the former, and he recommends its exclusive use, without exception, in all cases of children.

Duboseq's colorimeter. An instrument for determining the amount of hemoglobin in the blood by a comparison of its color with the tints of a graded series of crimson-glass plates.

Duchenne's disease. A disease of the pons and other cerebral structures, producing the nuclear form of facial paralysis, including lagophthalmos.

Duck. The blood of the duck was often employed in Greco-Roman antiquity as a remedy for ocular wounds.—(T. H. S.)

Duction power. The force inherent in an extrinsic muscle (or group of muscles) to rotate the eyeball in one or more directions. Thus, we speak of *sursumduction*, *abduction*, etc.

Duct, Lachrymo-nasal. During the third month of embryonic life, there arises from the conjunctival portion of the naso-lachrymal groove an epithelial bud, which develops straight downward through the mesenchyma into the nose. Hence, the ductus nasolachrymalis, thus formed, is a secondary growth and does not represent the primary cells position of the lachrymal duct.—(H. S. G.) See, also, **Anatomy of the eye,** as well as **Histology of the eye.**

Ductus ad nasum. Nasal (or lachrymo-nasal) duct.

Ductus oculi abducentes. A synonym of *venæ vorticosæ.*

Duddel, Benedict. Sometimes spelled *Duddell.* Neither the time nor the place of his birth or of his death is ascertainable. He is supposed to have practised in London, but there is much doubt even about that. However, he was certainly an English oculist, who flour-

ished in the earlier decades of the eighteenth century. He was, we may say with equal certainty, a pupil of Woolhouse, the great English oculist and charlatan, who practised in Paris.

Duddel's works are as follows: "Prosodia Chirurgica" (London, 1729); "Treatise on the Diseases of the Horny Coat of the Eye and the Various Kinds of Cataracts" (London, 1729); "Appendix to the Treatise of the Eye and the Cataract, with an Answer to Cheselden's Appendix Relating to His New Operation Upon the Iris of the Eye" (London, 1833); "A Supplement to the Treatise on the Diseases of the Horny Coat," etc. (London, 1736).

Duddel is especially important for the history of cataract extraction. He it was who proposed (in the third of the works above mentioned) that, in cases of soft cataract which would not go to the floor of the vitreous chamber under the pressure of the cataract-needle, to make an incision in the cornea and the anterior capsule of the lens, and so to extract the cataract. The date of this proposal was 1733, so that, as the letter in which Daviel announced (in "*Mercure de France*") his method of extraction did not appear till 1748, it is easy to see that Duddel was, in a sense, a predecessor of Daviel in the performance of cataract extraction. However, Duddel actually extracted only such cataracts as had been dislocated into the anterior chamber, and, moreover, had in mind, it would seem, nothing but cataracts of the soft variety.

The way in which Duddel performed his operation is interesting. He employed a lancet concealed in a canula. With this device he perforated the cornea, just beneath the lower margin of the pupil. Then, drawing the lance back into the canula, he introduced the latter (with the lance still in it) into the anterior chamber and as far as the inferior pupillary border. Pulling the edge of the iris down, he once again made use of the lancet, this time for the purpose of incising the anterior lenticular capsule. He then seized the lens with a hook, and drew it forth.

Duddel also contributed useful information concerning the development of after-cataract. Thus, in answer to Taylor's inquiry as to whether, after a couching operation in a young person, a cataract can again appear in the same eye, without the reclined lens having mounted to its old position, Duddel replied that this could be the case, the cause thereof being a cloudiness in the anterior capsule of the lens (arachnoides) produced by an inflammation in that structure.

There is also a curious passage in the first of Duddel's ophthalmologic writings ("A Treatise," etc.) in which he declares that, in mirror-makers, little balls of mercury form in the anterior chamber

of the eye and that these can be removed in no other way than *viâ* an incision in the cornea.—(T. H. S.)

Duddell, Membrane of. A synonym of the membrane of Descemet. See **Duddel, Benedict.**

Dufour, Marc. Born in 1843 at Villeneuve, he received his medical degree in 1865 from the University of Zürich. Then he studied ophthalmology under Horner in Zürich, Liebreich in Paris, and von Graefe in Berlin. For a time he was first assistant to von Graefe. Then he was called to the Lausanne Asile des Aveugles, serving first as chief assistant, then as chief. Serving for a time with the Swiss Ambulance Corps in the Franco-German war, he settled again in Lausanne, becoming professor of ophthalmology in the university.

He was a skilful operator, a prolific writer, an honest and amiable man. He is said to have been a most charming talker.

He received the decoration of the Legion d'Honneur in 1906.

While engaged in a consultation at the Lausanne Augenklinik, he fell dead, of apoplexy, July 29, 1910.—(T. H. S.)

Dugas, Louis Alexander. Born at Washington, Ga., in 1806, he received his early education from a private tutor. Having studied for a time with a preceptor, Dr. John Dent, of Augusta, he proceeded to the University of Maryland, at which institution he received his medical degree in 1827. For the next four years he studied in Europe. Returning to America, he settled for the practice of his profession in Augusta. In 1832 he was one of the founders of the Medical College of Georgia, in which institution he held the chair of surgery from that date until his death. He was several times president of the Georgia Medical Association and, from 1851 to 1858, was editor of the *Southern Medical and Surgical Journal.*

Though chiefly a general practitioner, he devoted much attention to the eye. He invented the Dugas operation for corneal staphyloma, much in vogue for many years, though now a little antiquated. He was the first in history to treat purulent ophthalmia by solutions of chlorid of sodium—a method of treatment which, as is very well known, not infrequently succeeds when the silver solutions are useless.

In 1833 he married Mary C. Barnes; in 1840, Louisa V. Harriss.

He died at Augusta, Ga., in 1884.—(T. H. S.)

Dugés, Antoine. A French physician, obstetrician and comparative anatomist, of some importance in ophthalmology. Born in 1798, he received his medical degree at Paris in 1821. For a time he was prosector of the medical faculty at Paris; then he removed to Montpelier and died in 1838.

Aside from works of a general character, he wrote:

1. Recherches Expérimentales Relatives à l'Opération de la Cataracte. (*Memorial des Hôp. de Midi,* 1830, pp. 255-260.)

2. Hémiopsie Circulaire Guérie par les Narcotiques. (*Ephém. Méd. de Montpellier,* 1828. Vol. II, pp. 254-263.)—(T. H. S.)

Duhring's disease. DERMATITIS HERPETIFORMIS. At least one case has been reported by Balzer and Sevestre (*Rec. d'Opht.,* p. 93, 1909) where bullæ formed on the lid margins and were followed by symblepharon and corneal opacities. See, also, **Dermatitis herpetiformis.**

Dujardin's test. This is one of several tests for ocular malingering. See p. 1178, Vol. II, of this *Encyclopedia.*

Duke Carl Theodore of Bavaria. A member of the Royal family of Bavaria, who became a celebrated ophthalmologist. See **Wittlesbach.** —(T. H. S.)

Dumbness, Word-. See **Visual aphasia;** as well as **Neurology of the eye.**

Dumb telescope. A telescope tube without glasses, for sighting only.

Dunbar's serum. See **Pollantin.**

Duncan, Robert Hunter. A prominent Canadian ophthalmologist, who was born at Barrington, Nova Scotia, and died Oct. 31, 1910, at Jamaica Hospital, Long Island. His early education was received at Mt. Ellis University, New Brunswick, his medical training at the College of Physicians and Surgeons, Baltimore, Md., at which institution he graduated in 1889. He was next a student for some time at the Manhattan Eye and Ear Hospital, New York City. For ten years he was superintendent and resident physician of St. John's Hospital, New Brunswick; surgeon to the Pacific Mail Line, and ophthalmologist to St. Bartholomew's Clinic.—(T. H. S.)

Dunkelapparat des Auges. (G.) A name given by von Kries to the retinal rods.

Dunkelkur. (G.) Dark cure. Confinement in a darkened room.

Dunkelsehen. (G.) Dimness of vision.

Dunkelsehschärfe. (G.) Visual acuity with dim illumination.

Dunkelzimmer. (G.) Dark-room.

Dünnes Augenfell. (G.) A thin or moderately developed pterygium.

Dunstbad. (G.) Vapor bath.

Duplicate lenses. This device is a convenient means of carrying duplicate lenses and the necessary parts and tools for fitting them into the spectacles or eyeglasses for the use of travelers, etc. As illustrated, the box contains two lenses (marked so that anyone may know how to insert them in their frame), a screw driver and a little bottle containing screws. See figure on next page.

Duplicate Lenses for Travellers and Others.

Duplicateurs. (F.) Devices for producing double images, mainly for the purposes of ophthalmometry. See **Doubling.**

Duplication of the disc. This condition is extremely rare in man. The case of a man, aged 42, presenting the appearance in the right fundus of two optic discs partly overlapping each other is reported by Sherer (*American Medicine,* November, 1908). Careful study of the minutiæ led him to believe it to be a case of aberrant growth of medullary nerve sheaths. This condition, while rare in man, in some lower animals is very frequent and in others, notably the rabbit, is constantly and normally present. It may be confused with areas of chorio-retinitis, of fatty deposits, or of albuminuric retinitis, but may generally be differentiated by its frayed or fringed edge. This character was absent in this case, also it was exceptional in that the disc did not have a reddish appearance, in contrast with the area of medullated nerve fibers. These areas of medullated nerve fibers usually border on the disc, but sometimes occur at other places in the fundus. Some authorities believe they do not affect vision, but the writer here quoted, with others, thinks they do.

Duplicity, Theory of. Theory of separate perception which ascribes distinct and different functions to the retinal rods and cones.

Dupuytren, Guillaume. One of the most celebrated surgeons of all time. Born Oct. 5, 1777 (1778?) at Pierre Ruffière, a small town of

Haute-Vienne, near Limoges, France, he removed at the age of twelve to Paris. Shortly afterward, he began the study of anatomy and surgery, and, at the age of sixteen (seventeen?) had been appointed prosector, and became a successful teacher. In 1801, still hardly more than of age, he began to lecture on pathological anatomy, and two years later wrote "Propositions sur quelques Pointes d'Anatomie, de Physiologie, et d'Anatomie Patologique" (1803). From this time forward, his life consisted of an even more rapid succession of scien-

Guillaume Dupuytren.

tific achievements. Among his appointments were body-surgeon to Louis XVIII and Charles X, and General Inspector of the University. He was made a baron. In the fall of 1833 he suffered a slight attack of apoplexy, and, in the following spring, made a journey to Italy in search of health—which, however, he failed to find. Feb. 8, 1835, he died.

The powers of Dupuytren are still a great tradition. As an observer he possessed almost miraculous ability. Keen-sighted, strong of inference, he got at the heart of an obscure trouble, as it seemed to those who stood about him, almost instantaneously. His operative dexterity seemed almost equally marvelous. Still more wonderful, this

versatile Frenchman enjoyed an even more exalted reputation as a lecturer. Never at a loss for a word, speaking in brief pictorial sentences, which, almost without exception, were strikingly germane to the subject, he attracted instantly and held throughout the time assigned to him the excited attention of even the dullest student. He is said to have preferred, among his patients, the poor and humble to the well-bred and the rich, and often to have operated on dozens of the extremely indigent while multi-millionaires were cooling their heels in his well-nigh forgotten waiting-room. In his work about the hospital he wore a white gown. In the street and at home, he was very simply dressed. He was always rough in manner, sometimes actually shouting, but kind of heart and truly in love with his work.

As to his oculistic ability, opinions differ much. The most adverse opinion is that of Guépin, of Nantes, who said of him: "I have followed closely the great Dictator of the Hôtel-Dieu, M. Dupuytren, and I am very far indeed from accepting the usual estimate of the man. From 1824-1829 I never saw him form one single artificial pupil. I have seen him fail in two-thirds of his cataract operations. I heard, as the patients answered him, that they saw, under the influence of the terror which he instilled into them; while, in reality, they were not able to count my fingers. The whole world knows his method of operating for lachrymal fistula, brilliant for the moment, but reprehensible for its ultimate result."

Dupuytren's procedure for the "cure" of *fistula lachrymalis,* was, perhaps, his greatest contribution to ophthalmology—great, that is, in a negative sense. It was, of course, inevitable that this barbarous proceeding should sooner or later be tried, and sufficiently advertised (as a failure) to be more or less permanently condemned. It consisted of an incision in the anterior wall of the lachrymal sac, and then of the introduction, *via* the incision and the nose, of a golden canula. The method was by no means new with Dupuytren, though it was generally supposed to be so. It had been anticipated, both by Wathen and Foubert. These surgeons, however, had not been able to secure for their discovery a very extensive attention; hence, as the "Dupuytren procedure" was often a cause of caries, palatal perforation, and even death, it was well that the famous operator re-discovered it, so that, by bringing it to wide-spread notice, it could be condemned forever. Not quite, perhaps, forever. The procedure is still "discovered" from time to time and announced with great *éclat* in ophthalmologic journals.

Dupuytren wrote little. The greater portion of his accomplishments have come down to our time in the books and articles of his

numerous and appreciative students. Nevertheless, or perhaps as a necessary result of this very circumstance, the gifted Frenchman stands out sharply and vividly in the imagination of the twentieth century profession as a teacher, a surgeon, a quasi-oculist, and, despite his rough exterior, as a kind, warm-hearted man.—(T. H. S.)

Duralscheide. (G.) Dural sheath.

Dura mater. This outer membrane of the brain and spinal cord is divided into the *cerebral,* and *spinal* or *rhacidian* dura. The cerebral portion is mostly identical with the endocranium. It furnishes, among other ocular relations, a covering to the orbit and a sheath to the optic nerve. See **Orbit.**

Dura membrana. One of the numerous, obsolete, synonyms of the sclera.

Dura oculi. Fibrous or external coat of the eye.

Durchblutung. (G.) Hemorrhage (into a tissue or organ).

Durchfall. (G.) Diarrhea.

Durchkreuzung der Sehnerve. (G.) Decussation of the optic nerve.

Durchleuchtung. (G.) Transillumination. Diaphanoscopy.

Durchleuchtungslampe. (G.) Transilluminator.

Durchmesser. (G.) Diameter.

Durchscheinend. (G.) Diaphanous. Translucent.

Durchschnitt. (G.) An average.

Durchschnittspunkt. (G.) Point of intersection.

Durchschwitzung. (G.) Diapedesis.

Durchsichtig. (G.) Transparent.

Durchsichtigkeitsmesser. (G.) Diaphanometer.

Durchstochen. (G.) Perforated.

Durcissant. (F.) Hardening.

Durcissement. (F.) Induration. Hardening. Sclerosis.

Dure mère. (F.) Dura mater.

Dusche. (G.) Douche.

Dust. When one considers for a moment the constituents of ordinary dust—especially that rising in the wind from the streets of towns—the possibilities of infection of the eyes therefrom can easily be imagined. Doubtless foreign body injuries and epidemic conjunctivitis (from the microbic content) represent the most obvious examples of this source of disease; while the conjunctival hyperemia set up in irritable eyes by purely mechanical particles is another. True and Fleig (*Rec. d'Ophtalm.*, 33, p. 14, 1911) have drawn our attention to the damage inflicted on the external eye by the dust of tarred roads, especially when, in motoring, the eyes are not fully protected by goggles.

Dusting powders. See **Powders for insufflation.**

Dusty miller. See **Cineraria maritima.**

Dutch liquid. A vulgar name for *ethylene dichloride.* The oculotoxic symptoms set up by this powerful agent will be discussed under its own heading as well as under **Toxic amblyopia.**

Dutrieux, Pierre-Joseph. A French ophthalmologist, who performed the most of his professional duties in Africa. Born at Tournai, Belgium, in 1848, he received his medical degree at Ghent and proceeded at once to Egypt. He settled in Cairo, and was soon appointed Professor to the local School of Medicine and body-physician to the Viceroy of Egypt. Returning to Belgium, he was soon appointed by the King to the leadership of an expedition to the Congo. Ruined in health, he returned from Africa and practised as an ophthalmologist in Paris, dying, however, Feb. 5, 1899, at the early age of 41.

His chief ophthalmic compositions are: "Considérations Générales sur l'ophtalmie Communement Appellée Ophtalmie d'Egypte, Suivie d'Une Note sur les Opérations Pratiquées à l'Ecole Khédiviale des Aveugles en Caire, avec une préface en Forme de Lettre à Riaz-Pascha" (Cairo, 1878); "Contribution à l'étude des Maladies et de l'Acclimatement des Européens dans l'Afrique Intertropicale" (Ghent, 1880).—(T. H. S.)

Duval, Mathias. A well-known Parisian anatomist, whose life-dates are not procurable. He received his medical degree at Paris in 1869, and became an associate professor of the faculty. He paid some attention to ophthalmology, and wrote a thesis entitled "Structure et Usages de la Retine" (1872).—(T. H. S.)

Duveté. (F.) Downy.

Dway-berries. The fruit of *Atropa belladonna.*

Dyeing. Although this process has a number of relations—mostly indirect—to the science and practice of ophthalmology it is probably inappropriate to say much about it here. The reader is referred to the headings **Toxic amblyopia,** as well as the matter under **Dyes, Hair,** and some of the minor sections of **Color** for consideration of various dyes and their effects upon the eye. See, also, **Aniline colors;** and **Dyes.**

Dyer, Ezra. A well-known ophthalmologist and one of the founders of the American Ophthalmological Society. Born at Boston, Oct. 17, 1836, he received the degree of Bachelor of Arts from Harvard University in 1857. In 1859 he received his medical degree from the same institution. Proceeding at once to Europe, he studied at Dublin, Bonn, Vienna, and Berlin. While in Vienna he came within the influence of Arlt, and so was induced to turn his attention to ophthal-

mology. In Berlin he studied with von Graefe, to whom he bore a letter of introduction from Arlt.

Returning to America in November, 1861, he settled in Philadelphia, and soon had an excellent practice. In the following year, at the invitation of Surgeon-General Hammond, he took in charge "all the eye and ear cases then in the Philadelphia Army Hospitals." While engaged in this work, he personally treated hundreds of cases daily, under the most adverse circumstances. Concerning these matters, the following passage occurs in one of his letters to his wife: "To-day I had over ninety to dress myself. On my way home from the hospital I saw, just above the bridge, a whole train of wounded rebels, and they wanted attention. I hitched Prince and 'went in.' The day was hot, and, though I took off coat and waistcoat, I was drenched. Deliver me from such a scene again. They were brought in freight cars, lying on the floors, which were swimming and slippery from filth. We got water and sponges, and some good women brought old linen and made lint and bandages, while I climbed into the cars and worked. Many of the shelled wounds had mortified and were full of maggots. The poor fellows did not complain, but were in a horrid state, Officers and men were all together, and as soon as one was fixed up a dozen said: 'Doctor, can't you look at me now? I don't know how long I have been here.'"

Dyer was always active in medical society work. In 1865 he read before the American Ophthalmological Society a paper entitled, "Asthenopia not Connected with Hypermetropia," in which he proposed "for cases of asthenopia not depending on any error of refraction or muscular insufficiency, a system of ocular gymnastics." This excellent means of treatment has ever since been known as "Dyerizing."

In 1866 he published a notable paper on "Fracture of the Lens from Death by Hanging."

For a time he was ophthalmologist to the Wills Eye Hospital, and also held a number of other appointments, but, in 1873, owing to the chronic illness of a member of his family, he removed to Pittsburgh, where, it was thought, the change of scene and climate might prove of service to the sick one.

In Pittsburgh, too, he was soon very busy, and was promptly connected with the Dispensary and a number of hospitals.

It was in Pittsburgh that he wrote the paper entitled "The Treatment of Asthenopia by Systematic Exercises." This article he read in 1876 before the International Ophthalmologic Congress, which met in New York.

One day in the autumn of 1879, leaping suddenly to the slippery deck of a ferry boat that was just on the point of departing from the dock, he fell and ruptured the ligaments of the left knee. After this accident he was always lame, and, now and then, the knee would give way under him. This distressing accident led to another still more serious. In the spring of 1880, while stepping from a horse car, the injured knee gave way, and he fell, breaking the right thigh and dislocating the right hip. After remaining in bed for six months, he was once more able to go about, but never again did he fully recuperate. Two years later, a spinal affection supervening, he sought for a milder climate in Newport, R. I. Here, in spite of his serious condition, he invented the perimeter, still known by his name. During the earlier portion of his stay at Newport, he seemed to be slightly improved; but, beginning again to decline, he was taken by his family to Florida. Here, too, however, he failed to receive the expected benefit; so, on Feb. 5, 1887, he was taken on board a ship bound for New York, and, four days later, while still on board the vessel, he died.—(T. H. S.)

Dyerization. See **Dyerizing**.

Dyerizing. Dyerization. A method of treating asthenopia, when the symptoms are due neither to refractional error nor to heterophoria, by means of certain ocular exercises. It is often desirable, in persons suffering from asthenopia due to incompetent ciliary muscles, to exercise them much as we do a weak musculature elsewhere—the adductive ocular muscles, for example. By such a plan one may regulate, at the same time, the amount of near work, the occasion and the circumstances under which it is done by the defective focusing apparatus.

As Dyer originally pointed out, it is well to begin by allowing the patient to read, or sew, three or four times a day a certain number of minutes just short of the time that commonly sets up asthenopic symptoms. Suppose he can read five minutes, but ten minutes' close application cause blurring or smarting, or eye ache? Let him, then, read five minutes (by the watch) four or five times a day; the second day for six minutes four or five times; the next day seven minutes; the next, eight minutes, and so on. The patient should, while taking these exercises, always stop on the approach of symptoms, it matters not how short a time he has been reading or writing, and postpone until the following period his efforts to do near work. After each exercise is a good time to apply soothing collyria, cold water, evaporating lotions, etc., to the eyes and ocular region. These exercises and the other treatment for the asthenopia should be continued until the patient is able

to do a fair amount of near work without discomfort. See **Dyer, Ezra.**

Dyes. While the various artificial colors, such as those made from coal-tar and those synthesized from other substances, are gradually revolutionizing the use of pigments in all fields where colors are used, a similar revolution has already been effected in the field of dyeing fabrics. Natural coloring-matters, such as cudbear and logwood, which were formerly among the mainstays of the dyers, are now seldom used. For the artificial colors not only give a wider range of colors and shades, but are cheaper, and very much easier to use. It was as dyes, rather than as pigments for painting, that they were first introduced; and while their application as dyes differs from their use as paints and stains, their composition is identical.

Without regard to the natural scientific grouping of artificial colors, the dyer divides them into six or more groups based upon their practical application. A recent grouping by Farrell is as follows: 1. Direct or substantive cotton dyestuffs. 2. Acid dyestuffs. 3. Basic or tannic-acid dyestuffs. 4. Mordant dyestuffs. 5. Vat dyestuffs. 6. Developed dyes.

The first of these, direct or substantive cotton dyestuffs, are probably the most important to the dyer, as most of the colors are azo compounds, and dye vegetable fibers direct from an aqueous bath, with the addition of some such salt as sodium chloride. Some of them are also adapted to dyeing such animal fibers as wool and silk, and the shades are usually very fast.

The second of these, the acid dyestuffs, are the sodium salts of sulphonic acids and the nitro-colors. These are particularly useful in dyeing animal fibers.

The third, or basic dyestuffs, are substantive to wool and silk fibers, but may also be used to dye vegetable fibers. They are not very fast colors, however, and are not used generally.

The fourth, mordant dyes, are little used on account of the difficulty of applying them. The one color for which they are used extensively is Turkey-red on cotton textures, the color being produced from alizarine and an alumina lime and fatty-acid mordant.

Vat dyes, or the fifth group, are difficult to apply but they include the important dyestuff, indigo.

The sixth group, or developed dyes, are produced in the fibers from the substances that are not dyestuffs. In this group come the important aniline black, and the colors produced by the combination of naphthols with the diazotized amido compounds.

The number of these artificial dyes runs into the hundreds and

there are endless methods of applying them. As the composition of many of the colors and the methods of applying them are trade secrets, it is impossible to consider them individually, or to treat the subject in anything but the most general way. (*The Mechanical Arts.*)

Dyes, Hair. Fernandez (*Archiv. of Ophth.*, January, 1913) discusses various hair dyes, refers to several forms of eye involvement that have been caused by the use of such dyes, and draws the following conclusions: 1. All hair dyes in use at the present time, are more or less toxic in effect, and may give rise, under certain circumstances, to general and local eye troubles. 2. The injurious effects experienced are of two classes, inflammatory and toxic, although both may be present at the same time. The trouble may be only ocular in character, or it may affect the general system as well as the eyes. 3. The dyes which do the most harm, are those containing aniline derivatives. As they are very easily prepared, they are the dyes most generally used. 4. Fortunately, as the aniline derivatives are powerful colorants, only a small quantity of the dye is necessary to produce the desired results, and there is, therefore, less danger to the eyes and the general health. See, also, **Cosmetics.**

Dyes' method. This is a form of venesection thought by Gilbert (Graefe's *Archiv für Ophthalm.*, 80, 2, 238) to be especially valuable in the treatment of glaucoma. It consists in the abstraction of 3 grm. of blood per kilo body-weight, followed by diaphoresis. Reference is also given to a paper by Eversbusch (*Oph. Review*, p. 345, Dec., 1912) on the subject. The cornea was anesthetized by alypin and the tension carefully estimated by Schiotz' tonometer in the evening and again on the following morning immediately before the venesection, and a third time the same afternoon. Subsequently two measurements were made daily for several days. The results are tabulated and show that in all cases a definite reduction of tension was obtained. Of 13 eyes with glaucoma simplex 11 showed the greatest reduction after 6 to 8 hours, and this remained in 4 cases for 24 hours. The effect gradually passed off in from two to four days. In inflammatory cases the reduction of tension appeared later and was still present after four days. The variations in intraocular tension were found closely to accompany similar changes in blood pressure. The author attributes the results not alone to the removal of blood, which was rarely more than 250 grm. in amount, but also to the active tissue change induced by the smart diaphoresis which followed. The following suggestions are made for the treatment of glaucoma: 1. In the prodromal stage. Periodic venesection controlled by observations on ocular tension and blood pressure, together with miotics and gen-

eral treatment. 2. Before operation. Venesection 6 to 24 hours beforehand in glaucoma simplex and 24 to 48 hours beforehand in glaucoma inflammatorium.

Dymal. The trade name for a preparation which is essentially a *salicylate of didymium.* Dymal is a fine, starch-like, pinkish-white powder, free from any tendency to cake; insoluble, non-poisonous and odorless. The preparation is a siccative, cicatrisant, deodorizer and antiseptic, free from all disagreeable by-effects. It has the advantage over most antiseptic dusting powders of being absolutely odorless; nor does it stain. It leaves the wound surface free for observation, since the powder, if not too abundantly applied, usually disappears by the next day, while the dressing is readily removed without preparatory wetting.

Kopp, of Munich, first called attention to the advantages of this remedy, and it has since been employed extensively in the treatment of ulcers, burns, wounds and various cutaneous affections; for instance, eczema, acute or subacute; impetigo, artificial dermatitis, herpes, etc.

Dymal is used as a dusting powder in wounds and as a 10 to 20 per cent. ointment in various dermatoses.

Dynactinometer. ACTINOMETER. An instrument for measuring the intensity of the photogenic rays and computing the power of object glasses.

Dynameter. A graduated glass plate used to determine the magnifying power of a telescope.

Dynamic convergence. According to Worth (*Squint*, p. 3) when the two eyes look at a distant object, the visual axes may, for practical purposes, be considered to be parallel. When, however, a near object is looked at, the two eyes must rotate inwards, in order that both visual axes may be directed to the same object. This active inward rotation of the eyes is called *dynamic convergence.*

Dynamic refraction. A term intended to distinguish active from static refraction. The latter is what is ordinarily called refraction, i. e., the refractive condition with inactive accommodation. When accommodation is exerted, the refracting power of the eye increases. By the use of the accommodative power, for example, a young person with hypermetropia may make himself dynamically (or apparently) emmetropic or even myopic.

Dynamisches Schielen. (G.) Dynamic squint.

Dynamite, Ocular injuries from. Dynamite injuries are among the most dangerous and serious lesions of the eye. This explosive appears to lacerate and destroy the tissues much more extensively and effect-

ually than the old-fashioned forms of blasting powder. The injuries are found principally among miners and workers in stone quarries—generally speaking, in those engaged in any form of heavy blasting. The dynamite in the cartridges is usually made of nitroglycerine mixed with a silicious marl. Often in the hole bored for the purpose several cartridges are placed one upon another. The upper cartridge carries powder and a fuse; and above all is placed a tamponade of sawdust, sand, clay or water. Sometimes only one cartridge explodes, so that a part of the charge remains intact, and upon attempting to supply a new fuse, an unexpected explosion occurs, perhaps injuring several workmen. When such an accident occurs, to the mechanical violence of the foreign bodies—including small pieces of rock—are added the pressure of hot air and the burning of the powder used in igniting the dynamite. When such an explosion affects the face we have deep burns of all the parts, complicated with impregnation of the skin with powder, grains of sand, pieces of rock, as well as parts of the metal cartridge or its cap. Later on, examination of the eyes often exhibit incurvation of the eyelashes and a variety of foreign bodies lodged in the conjunctiva and cornea. These may lie superficially or they may penetrate deeply into the tissues, even perforating the iris or lens. Foreign bodies may pass entirely through the lens, causing a traumatic cataract, and lodge in the vitreous humor. In some cases they pass through the posterior wall of the eyeball into the orbit. The form of the eyeball is, however, generally preserved.

In cases of dynamite explosions we often find bleeding into the anterior chamber, prolapse of the iris, iridodialysis, dislocation of the lens, hemorrhages into the vitreous, rupture of the choroid and retinal hemorrhage. During the first few days after an accident the skin of the face and eyelid is often so swollen that an exact examination of the eye is impossible. The conjunctiva and cornea may appear (because of the implantation of numerous small, white and brown foreign bodies or grains of powder) as if they were tattooed. When they are elevated above the surface the rubbing of the lid edges over these obstructions causes violent ciliary pain. Patients also complain of severe burning and pricking in the eyes, and there is usually marked blepharospasm, photophobia and lachrymation. If many foreign bodies have lodged in the cornea, it becomes cloudy and the epithelium is easily removed.

We may distinguish between slight and severe injuries from dynamite explosions. To the former class belong superficial burns and injuries of the lids, the conjunctiva, and the cornea; among the severer cases are to be counted (in addition to the lesions just mentioned)

perforations of the cornea, sclera, or iris; prolapse of vitreous; traumatic cataract, and foreign bodies in the interior of the eye.

As a rule both eyes are injured. Of the 31 cases reported by Beckmann, 27 were so injured; 15 had a perforation in one and 4 in both eyes; 12 lost the sight of one and 2 of both eyes; 9 eyes were enucleated. In three cases the process ended with one-sided, in two with bilateral, phthisis bulbi, following acute panophthalmitis or chronic iridochoroiditis.

The *prognosis* in cases of perforation of the globe by the missles just referred to is obvious; it depends especially upon whether fairly large foreign bodies, such as pieces of rock, have penetrated the inner parts of the eye and whether an infection of the intraglobar tissues has taken place. Hemorrhages into the vitreous humor may clear up to some extent, but, nevertheless, may eventually end in detached retina. In young people a traumatic cataract may be spontaneously absorbed, or in older people may be surgically removed, with good results. As a rule, more or less thick opacities are left in the cornea at the place where the foreign body penetrated. Aseptic pieces of sand or quartz that have passed into the vitreous humor may remain *in situ* without irritation, and upon being examined with the ophthalmoscope may even remind one of the picture of synchysis scintillans. On the other hand, foreign bodies in the cornea sometimes cause ulcers, which always leave behind opaque tissue and, if in the pupillary region, seriously damage sight.

In a relatively large number of cases, however, in spite of severe lesions of the eye there nevertheless remains wonderfully good visual power, and in spite of the fact that patients bear life-long marks on the face and conjunctiva from dark-colored scars.

The severity of the injury and the loss of earning-power is often increased by other lesions of the body—by fractures of an extremity or the loss of a finger (which is sometimes entirely torn off) or by extensive burns and wounds of the soft parts of the arms and hands. As a rule, months pass before the more serious consequences of a severe dynamite explosion are relieved to such an extent that a surgeon is no longer needed.

In *treatment* it is necessary above all to prevent infection. The swelling of the face and lids, which may make the patient unrecognizable, is best treated, and the extrusion of grains of powder and sand that have penetrated beneath the surface is accomplished most quickly, by applying a dressing of iodoform or nosophen-vaseline. Either of these is thickly smeared on a face-mask which has an opening cut for the nose and mouth. The bandage is renewed once a day and

the eyes are washed with a lukewarm solution of boric acid, while atropin-cocain vaseline is daily applied to the conjunctival sac. We remove only the superficial foreign bodies, so far as this is easily done, although as a rule they come out spontaneously on the dressings. Prolapse of the iris should be snipped off; scleral wounds ought to be closed by suturing, if it is intended to preserve the eyeball. If the eye is so badly injured that relatively painless healing with the retention of eyesight is out of the question, we prefer early exenteration to danger of panophthalmitis or iridochoroiditis with possible sympathetic ophthalmia. In the event of persistent irritation, in the course of healing, lukewarm poultices should be applied. These often relieve the situation and even modify a traumatic iritis, as well as hasten the absorption of a traumatic cataract.—(Vossius, in the *Encyklopädie der Augenheilk.*, p. 246.)

John B. Corser (*Penn. Med. Journ.*, Jan., 1913) reminds us that *dynamite caps* are made of copper in much the same way as gun cartridges and are used to explode larger charges of dynamite, giant powder or other high explosives. When exploded, the copper shell breaks into many small, sharp pieces which seem to have a peculiarly strong penetrating power. The caps are handled carelessly by those using them and fall into the hands of boys and others ignorant of their dangerous characters. They occasionally are dropped by the miners and go out of the mines in the coal and are exploded when thrown with the coal into the fire.

The immediate effect of dynamite cap explosions on the ocular structures varies with the nearness of the eye to the exploding cap. A small spot on the sclera or cornea may be the only indication that a piece of the shell has struck and possibly entered the globe. On the other hand, complete rupture and disorganization of the globe may result. If a piece of the shell has entered the eyeball and cannot be removed, the eye will sooner or later be lost, owing to the irritating chemical action of the copper on the ocular contents. The rapidity with which inflammation ensues depends on the part of the eye in which the piece of copper lodges. The ciliary body and iris seem to be the parts most sensitive to the presence of copper. The vitreous will tolerate its presence for a longer period. Treatment will only prolong vision by aiding the resistance of the tissues, but blindness finally results. The difficulties met in trying to remove these pieces of copper from the eye can rarely be overcome and it must have occurred to everyone having these cases, how different it would be if the piece of metal causing the injury were iron or steel instead of copper. If dynamite caps were made of iron or steel instead of copper these cases

would still be serious, but how much less so when the foreign body is of a metal that can be attracted by a magnet.

Dynamogenesis. A term applied by Brown-Séquard to the accidental development of nervous power; for example, the increased power of vision in one eye when the other is excited by a luminous impression.

Dynamometer. This term has been applied to a number of different optical and ophthalmic instruments. It is, first, an instrument (occa-

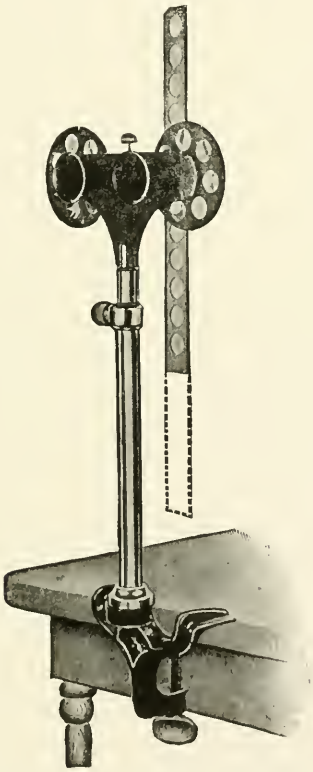

The (Hardy) Van Slyke Dynamometer.

sionally called a *dynameter*) for estimating the magnifying power of lenses.

Secondly, it is sometimes applied to the ophthalmodynamometer of Landolt.

Finally, it has been utilized to designate Van Slyke's instrument for measuring the dynamic prismatic power or strength of the extrinsic muscles of the eye and for diagnosing muscular asthenopia.

The instrument may be used for exercising the extrinsic muscles as well as for diagnostic purposes, and will be found as useful for the former as it is satisfactory for the latter purpose.

With this instrument the operator is able to differentiate between muscular and accommodative asthenopia, or between that which is due to a weak extrinsic or a strained ciliary muscle. See the figure.

Dysæsthesia visualis. Impairment or loss of the sense of sight.

Dyschromatopsia. DYSCHROMATOPSY, DISCHROMATOPSIS. Color-blindness, or perverted color-sense. See p. 2420, Vol. IV, of this *Encyclopedia.*

Dyscoria. (L.) Irregularity in the shape of the pupil.

Dysdacrya. Any lachrymal affection.

Dysdacryosis. A disease of the lachrymal apparatus.

Dysentery, Ocular symptoms of. According to Santos-Fernandez (*System of Diseases of the Eye*, Vol. 4, p. 712) these may be divided into two groups, first, a reflex group and, secondly, those that are determined either by the special infection which produces dysentery or by such secondary infections as originate in them. Among the first we may include paresis of accommodation, atrophy of the papilla, opacities of the vitreous, and false granulations. In the second may be placed conjunctivitis, keratitis, and choroiditis, produced by the passage of germs proceeding from the large intestine (at times suppurating or sphacelated) through the circulatory channels of the organism.

Cases of metastatic ophthalmitis have been reported as arising from dysentery, while in Magnus's table two instances of this disease are supposed to have led to the development of optic atrophy.

Dyserethisia. Diminished sensibility or irritability.

Dysgraphia. See **Visual aphasia**; **Neurology of the eye**; also, p. 198, Vol. I, of this *Encyclopedia.*

Dyslexia. See **Visual aphasia**; **Neurology of the eye**; also, Vol. I, p. 221, of this *Encyclopedia.*

Dysmenorrhea. According to Parsons (*Pathology of the Eye*, Vol. 4, p. 1304) dysmenorrhea may be due to disease of the sexual organs or to general disease. In the former case it has been by various authors thought to be associated with episcleritis and scleritis, hyphema, iritis, iridocyclitis, iridochoroditis, vitreous hemorrhage, papillitis, retrobulbar neuritis, paralysis of extrinsic muscles, subjective defects of vision, etc. Dysmenorrhea may be due to other diseases and cause ocular manifestations, e. g. tuberculosis, anemia, hysteria, etc. Chromidrosis may occur under these conditions, and xanthopsia is recorded.

Dysmyotonia. Muscular atony. *Dysmyotonia congenita* is the muscu-

lar atony and obstinately rigid condition of the muscles observed in Thomsen's disease.

Dysopia. Dysopsia, Dysopsy. Painful or defective vision. Dimness of vision; also the state of having small or deformed eyes.

Dysopia dissitorum. A term applied by Cullen to myopia.

Dysopia lateralis. "Skew-sight," or vision to one side; an affection in which an object can be seen only when held obliquely before the eye. It may be due to some opacity of the cornea or lens, but is also the result of an oculomuscular or fundus defect.

Dysopia luminis. Nyctalopia.

Dysopia proximorum. (L.) A term used by Cullen to indicate hypermetropia and presbyopia.

Dysopia tenebrarum. (L.) Hemeralopia.

Dysopsia. (L.) A synonym of dysopia.

Dysorasis. (L.) A synonym of dysopia.

Dysostose cléidocrânienne. This term is applied by French authors to a skull deformity which is sometimes accompanied by other malformations. R. Bergmeister (*Beiträge zur Augenheilk.*, No. 79, 1911) reports a double, congenital case in a girl, æt. 12, with this cranial anomaly. The patient was an intelligent, fair-haired child, who presented other points of interest as follows:—The lower jaw was exceedingly small, the angle was blunt, while the other face bones were of normal size; there was no limitation of movement in the mandibular joint. When looked at in profile the appearance of the child's face was similar to that of a bird's. The biparietal measurement was slightly increased, and there were furrows over the site of the longitudinal and lambdoid sutures, due to well-marked depressions along these lines, and to the bones of the skull curving up sharply from the site of the suture; at the bottom of these furrows the bones were wanting, and it was easy to feel the brain pulsation. The hair on the anterior half of the head appeared normal, while that on the posterior half was thin, and arranged in tufts, the skin being quite normal.

Radiographs demonstrated the absence of bone in the furrows, the absence of any attempt at a metopic suture, and the presence at one spot of a supernumerary bone like a Wormian bone in the lambdoid furrow; the base of the skull appeared normal, the teeth were in good order, two lower molars on each side being present. There were no other skeletal defects, the clavicles were particularly mentioned as being well formed. There was no evidence of rickets, and a radiograph of the thorax showed no shadow suggesting an abnormally large persistent thymus gland. The globes were of normal size, there was nystagmus, and the cataracts were of a milky-white color, the left

being almost of the nature of a Morgagnian cataract. Perception and projection of light were good, and the results of operation were successful. [Abstract in the *Oph. Review,* Nov., 1911, by R. R. James.]

Dyspepsia. As is well known to every ophthalmologist, diseases of the digestive apparatus play an important part in many ocular affections, especially in muscular asthenopia and in eye symptoms dependant upon certain general dyscrasiæ. It is, consequently, important that the systemic state of ophthalmic patients suffering from any sign of this rather indefinite complaint should be carefully investigated. See **General diseases.**

Dysphotia. (L.) An obsolete term for myopia.

Dystrophia musculorum progressiva. PRIMARY MYOPATHIA. PSEUDO-HYPERTROPHIA. This form of muscular atrophy was first described and labelled by Erb. Occasionally (but rarely) not only the muscles of the buttocks and the extremities but those of the face are affected by this form of atrophy. When the facial muscles are involved it generally includes the orbicularis palpebrarum. When that happens the atrophy varies in degree between slight defects in closure of the lids and a marked lagophthalmos. In very rare cases—of the bulbar paralytic type—the extrinsic eye-muscles are also involved.

Dystrophic cataract. Those lenticular opacities that affect the lens as a result of interference with its normal nutrition. Cataract due to exposure to X-rays or to excessive violet light, as well as "thyroid" cataract—*cataracta zonularis*—diabetic cataract, etc., are examples of this form of the disease.

Dystrophy of the cornea. This section should be read in conjunction with **Cornea, Dystrophy of the,** in Vol. V, p. 3356 of this *Encyclopedia,* to which it is, in a sense, supplementary.

The name *epithelial dystrophy of the cornea* was given by Fuchs to a condition not properly classified as either suppurative or non-suppurative keratitis. H. M. Traquair has reviewed Fuchs' article (Graefe's. *Archiv für Ophthalmologie,* 76, 3, 1910) in which this rare degenerative affection of the cornea which affects only elderly persons, especially women, is well described. Both, or only one eye may be affected. The disease begins with loss of corneal sensibility to touch, then dimness of the cornea occurs with or without slight signs of inflammation, if the latter, loss of vision first attracts the patient's notice. The opacity is superficial and appears diffuse to the unaided eye. It is most pronounced in the pupillary region, fading away gradually into the surrounding clear area, and extending as a rule more downwards than upwards. The most marked alterations are in the epithelium, the surface of which is matted or roughly uneven,

having an opaque and swollen appearance, and shows either definite blebs or small dark points, visible by means of a lens, which correspond to little cavities in the epithelial substance. These, as well as the blebs, appear black against the pupillary background indicating that the chief site of the opacity is in the epithelium. If this, however, is removed the cornea itself usually shows a very delicate superficial stippled opacity.

The corneal surface is quite insensitive to touch and when one eye only is affected the sensibility of the apparently normal cornea is greatly diminished. The deeper parts of the eye are normal unless the case is complicated by increased tension which, however, is absent as a rule.

The opacity increases slowly but surely in the course of years. Finally a more sharply demarcated, definitely-grey opacity forms in the pupillary area. It is raised above the level of the periphery which is only faintly opaque and consists of a layer of new-formed connective tissue between Bowman's membrane and the epithelium. Vision is then reduced to counting fingers at a very short distance.

Four cases occurred in men and nine in women, the latter including the three in which the tension was raised. In seven the condition was binocular, in five monocular and in another there was doubt as to the second eye. Most of the patients were over fifty years when the disease showed itself, and with the exception of one who had chronic nephritis all were in good health.

The differential diagnosis is between this condition and glaucomatous corneal haze, interstitial keratitis, keratitis profunda, and other forms of chronic corneal opacity. The etiology is unknown excepting in so far as old age and the female sex seem to be predisposing causes. The relative frequency works out at one in twenty thousand of all eye affections.

Treatment is of no avail; massage with various ointments, dionin, hot steam, hot air, tincture of iodine after removal of the epithelium, and Bier's congestion were tried but without permanent benefit. The prognosis is bad, but if only one eye is affected there is hope that if the other is not affected soon it may escape altogether. Up to the present, pathological investigation has been limited to the examination of a trephined disc of the superficial layers of the cornea in an old case. (*Ophthalmic Review*, Jan., 1911.)

In the November, 1911, issue of the *Ophthalmic Review*, Traquair again abstracts the report of a case of dystrophy of the corneal epithelium, this time by Paul Knapp (Graefe's *Archiv für Ophthal.*, 78, 2, 1911) who after a successful cataract operation in a woman of

68 years found indications of glaucoma which became quite definite after another year. As well as the usual superficial dulness of the cornea, which disappeared under appropriate treatment, some deeper corneal opacity began to appear at this time which remained permanent and increased so that five years after the cataract extraction, and in spite of two sclerectomies, there was slight + tension, both deep and superficial corneal opacity, and vision reduced to fingers at 2 m. The age, sex, commencement in the right eye, combination with glaucoma, insidious onset, and the symptom of clouded vision in the morning improving during the day, corresponded with the conditions noted by Fuchs. The corneal sensibility of the left apparently healthy eye (from which the lens had also been extracted) was depressed.

Paul Knapp lays stress on the difference between the opacity due to glaucoma and that due to dystrophia epithelialis which is of a chronic progressive nature, and the improvement in vision during the day, whereas in glaucoma the vision usually gets worse as the day goes on, in cases in which diurnal variation is present. He suggests that the condition is due to edema of the corneal tissue and that the daily improvement is due to the movements of the upper lid which act as a form of massage. Acting on this view he massaged the cornea with the finger on the upper lid and obtained a very definite, but only temporary, improvement, both subjective and objective. He concludes that the condition depends on a nervous disturbance—evidenced by the reduction of sensibility—followed by chronic edema of the cornea, especially of its epithelium.

Uribe y Troncoso (*Anales de Oftalmologia,* October, 1911) has observed a case resembling those described by Fuchs. The patient, a woman of 30 years, had noticed poor vision of the left eye for a year. The sight was completely obscured at intervals, when a thick, gelatinous secretion gathered between the lids. Her history included a pustular skin eruption, amenorrhea since puberty, and convulsions. The affected eye showed no vascularization of the conjunctiva. The cornea was cloudy, of a dull, whitish-gray color, and the opacity occupied the lower two-thirds of the cornea. By oblique illumination it was seen to be made up of numerous white points. The cornea was without sensibility. The iris reacted well to light. Fluorescin produced no discoloration. The inferior cul-de-sac contained a little white, thick, mucous secretion. With the Schiötz tonometer the tension was found to be 14 mm. Hg. The only fundus lesion found after dilating the pupil was a posterior staphyloma. After unsatisfactory treatment with dionin and collargol, the patient failed to return.

Rochon-Duvigneaud and Ducamps (*Soc. d'Opht. de Paris,* July,

Clin. Opht., V. 19, p. 469, 126, 1913) describe a case of symmetrical marginal dystrophy in a young man 17 years of age with a lesion of the left eye 1 to 3 mm. long, located at the inner lower quadrant within the corneal margin. It was non-ulcerative and gray. The center of the cornea was perfectly normal and no part of the cornea stained with fluorescein. The affected area showed marked hyperesthesia, the other being normal. Vision equaled one-third, not improved with glasses. There was neither pain nor reaction, the patient having been ignorant of the corneal affection, having consulted him on account of a blepharitis.

Motolese (*Ann. di Ott.*, v. 42, p. 272, 126, 1913) saw a man 53 years of age with epithelial dystrophy which had existed six months before consulting him. There was moderate corneal congestion in the left eye, with partial anesthesia; total anesthesia in the right. The opacity lay mostly central and resisted all forms of treatment instituted. At the end of six months small, transparent vesicles appeared on the cornea towards the lower nasal limbus. Reese (*Arch. of Ophth.*, V. 42, p. 181, 126, 1913) also reports a case in an old lady 74 years of age which progressed steadily for four years, notwithstanding treatment. Vesicles also appeared here, with a wrinkled appearance of the epithelium over the opacity. De Schweinitz saw one typical case appear in a patient following a successful cataract extraction. The tension was normal and only the one eye was affected. Another case reported by him was bilateral. He thought dionin and biniodid of mercury had helped one, whereas treatment had been unavailing in the other case. Alt (*Amer. Jour. Ophth.*, V. 30, p. 39, 127, 170, 1913) saw some extraordinary alterations in the corneal epithelium of a glaucomatous eye with a milky-white thickening of the upper portion of the cornea resembling pannus. On section, this was seen to be between Bowman's membrane and the epithelium and consisted of connective tissue and blood-vessels. In the center of the cornea were two vesicles.

Arnold Knapp (*Trans. of the Am. Ophth. Soc.*, 1911) reports a case which illustrates the differential points between dystrophia of the cornea and senile sclerosis of the cornea. After a cataract extraction upon a woman of 82 years, which progressed satisfactorily otherwise, the cornea became anesthetic, showed a faint superficial opacity, and its surface became uneven and finally stippled. The tension was normal. Treatment was of no avail and there was practically no change in the appearance of the eye until her death, a few months later. The other cornea had been in the same condition during the period of observation and perhaps from the time of a previous

operation twelve years before. This condition is peculiar to old age. The opacity increases slowly, is generally more pronounced in the pupillary area, and finally newly-formed tissue is deposited in the cornea between Bowman's membrane and the epithelium. In senile sclerosis the corneal opacity is deeper in the cornea and the superficial changes are absent.

As Reese (*Ophthalmic Record, March,* 1913, p. 131) points out, there are three forms of the disease: one due to deposits of mucin and occurring in myxedematous subjects; a second, due to thyroidectomy, and a third, the greyish-green discoloration of the cornea occurring in disseminated sclerosis. The majority of cases of dystrophy may be regarded as an expression of local disturbances of nutrition. Reese reports one case which he treated with dionin, holocain and massage locally, and the glycerophosphates internally, and there was no appreciable improvement.

Cases have also been described by de Schweinitz, Pfalz and Hoppe (*Trans. Sec. on Ophth.,* Coll. Phys., Phila., Feb. 20, 1913). Each observer records a single case. The last reporter saw the condition in a woman of 30 years or less. Pfalz' patient was a man aged 58. Hoppe's patient was a man of 70. In the youngest patient the trouble had lasted about a year. In most of the other cases it dated back ten years or more.

Dzondi, Karl Heinrich. Born Sept. 25, 1770, at Oberwinkel, Waldenberg, Germany, he first studied theology, then philosophy. Still later, he turned to medicine, receiving his degree in that subject at Würzburg in 1806. In 1811 he became Professor of Surgery and Director of the Surgical Clinic at Halle. He died of apoplexy, June 1, 1835.

Among his more important general compositions are: "Lehrbuch der Chirurgie" (Halle, 1821) and "Die Dampfmaschinen, ein Neues Heilmittel" (Leipzig, 1821) which still possess at least an antiquarian interest.

Dzondi was a celebrated ophthalmic operator, and, as to other matters in our field (in particular, blepharoplasty), published in 1835, a popular work on ocular hygiene, which bore the attractive title, "Die Augenheilkunde für Jedermann, Welche Lehrt, die Gesundheit der Augen zu Erhalten und die Krankheiten derselben Bald und Sicher zu Heilen."—(T. H. S.)

E

Eagle, Golden. AQUILA CHRYSAETOS. This bird furnished several substances to the pharmacopœia of the ancients, notably its bile and excrement. The latter was used in French practice until this century.

The gall and the brain of the eagle were esteemed in Greco-Roman antiquity as a remedy for weakness of the eyes. These were simply smeared upon the lids. The curious practice was based, by a false method of reasoning, upon the eagle's well-known visual powers.—(T. H. S.)

Eales, Henry. A well-known ophthalmologist of Birmingham, England. He was born at Newton Abbott in 1852, the son of the Vicar of Yealmp-



Henry Eales.

ton, Devonshire. His medical education was received at University College, London, where he was awarded two silver medals in anatomy and one in materia medica. In 1873 he was made a member of the Royal College of Surgeons. He served for a time as House Surgeon to the Birmingham and Midland Eye Hospital, later becoming Medical Tutor and Demonstrator of Anatomy at Queen's College, Birmingham.

In 1878 he was made one of the Honorary Surgeons to the Eye Hospital. In 1911 he was President of the Ophthalmic Section of the British Medical Association.

He was, at the time of his death, Medical Referee for Ophthalmic Cases under the Workmen's Compensation Act.

He did not write much, but all that he wrote was clear, sound, and practical. His most important composition was entitled "State of the Retina in 100 Cases of Granular Kidney." He also wrote on strabismus, retinal hemorrhage, and glaucoma.

He was a kind and courteous man, loved by those who knew him intimately, popular with all. He was, however, inclined to fits of depression and worry, and would never indulge in vacations.

He died Feb. 8, 1913.—(T. H. S.)

Ear and eye, Relations of the. This subject has been discussed under the caption, **Deafness, Ocular relations of,** and elsewhere in this *Encyclopedia,* but it may be added here that the points of contact between otology and ophthalmology are surprisingly few, although much has been written upon them. Some of the more important communications are given in the following abstracts:

The frequency and character of eye lesions as a result of otitic disease is discussed by Spicer (*Practical Medicine Series,* 1907), who states that there are widely diverse reports as to the conditions found in meningitis, thrombosis and brain abscess. Some observers find very few in large numbers of cases, others find a large percentage in a comparatively small number of cases. The author concludes that we may have one or more of the following ocular manifestations of the external signs: nystagmus, paralysis of the motor and sensory functions of the eyes and dilation of the pupils. Cellulitis also occurs with protrusion of the eyeball, which may be fixed by infiltration of orbital tissue. Internally, we may have optic neuritis or choked disc, of which he has found 34 instances. Papillitis occurs occasionally, also neuroretinitis and optic atrophy. The vessels are quite frequently changed in character. A seroplastic purulent choroiditis is noted, rarely ending in panophthalmitis.

In Peyser's (*Berl. klin. Wochnschr.*, No. 26, 1908) case the paralysis of the external rectus followed a subperiosteal abscess complicating otitis after scarlatina. He attributes the palsy to propagation of the inflammation through the external soft parts to the orbit, and not to an intracranial process. In Hedon's (*Montpellier Med.*, April 9, 1908) case paralysis of an externus developed after double otitis media following grip.

In Knapp's (*Arch. of Ophth.*, September, 1908) case paralysis of the abducens occurred in connection with otitis media without perforation. Pain in the right eye, cheek and gums, and inability to chew, were also present. Such a complexus of symptoms is indicative of a lesion in the Gasserian ganglion, as suggested by Baldenweck, who regards the anatomic lesion as an otitis at the petrous apex, the extension taking place along the cancellous tissue from the tympanum to the apex of the petrous pyramid. The proximity of the Gasserian ganglion to the sixth nerve at this point explains the involvement of that nerve, but the extension along the carotid venous plexus has never been demonstrated. The associated involvement of the ganglion is not so clear.

Rauge (*La Clin. Opht.*, November 25, 1908) observes that Gradenigo's syndrome—paralysis of the abducens during the course of chronic or acute otitis—is still unexplained. He reports several instances. Elze (*Wochnschr. f. Therap. u. Hyg. d. Auges*, October 1, 1908) observed two cases of diplopia from injury to the head, after concussion with symptoms of labyrinthine disease and involvement of a semicircular canal; to the affection of which latter structure the ocular disturbance was probably due. In aural neuroses caused by eye-strain Theobald (*Tr. Sec. on Ophth., A. M. A.*, p. 104, 1909) finds three varieties of tinnitus which may result from eye-strain. The more common vascular type, the low-pitched whirring or fluttering caused by irregular contractions of the tensor tympani, and the high-pitched intermittent tinkling produced by contractions of the stapedius. He has also found a "muffled" or "stuffed" sensation in the ear, and pain in or about the ear as a reflex of eye-strain. Whether the vertigo not unusually associated with eye-strain is to be regarded as an aural reflex he does not undertake to decide. Four cases are reported in which the symptom mentioned had been relieved one or more times by the correction of errors of refraction or tenotomy.

Rollet (*Ann. of Ophth.*, p. 189, 1909) finds that diseases or strain of the eye may produce a reflex deafness as well as vertigo and tinnitus. Lewis (*Ann. of Ophth.*, p. 59, 1909) calls attention to the clinical evidence of such a connection between the eye and ear that irritation and improper functioning of the former may disturb the latter. He finds that a symptom-complex resembling Ménière's disease may be produced through incoordinate action of the eye, and he believes that the clinical facts indicate that the cerebellum exercises governing functions of a special importance in the physiology of vision. He reports three cases that seem to indicate the ophthalmic organ of such otic disturbances.

Earle's extraction of cataract. A small lancet, not now used, was arranged to move backward and forward between the blades of a forceps. The instrument was introduced through the sclerotic and choroid; the lancet was withdrawn by means of a spring in the handle, and the blades of the forceps were then opened and the cataract seized and removed.

Earning power, Loss of. See **Legal relations of ophthalmology,** about the middle third of article; also **Visual economics.**

Earth, Fuller's. KAOLIN. PORCELAIN CLAY. This substance, a native aluminium silicate, is freed from gritty particles by washing. It is a soft, white powder (or occurs in lumps), odorless and with an earthy taste; insoluble in water. It is used as an absorbent, dusting powder, or an excipient in pills. Its use in ophthalmology is confined to that of a dusting powder in the treatment of eczema.

Ear wax. This substance was employed by both Calissen and Himly as an application to the point of a cataract (couching) needle, just prior to its use. *Sebum cutaneum* was similarly employed.—(T. H. S.)

Easter flower. See **Pulsatilla.**

East Indian ophthalmology. See **Hindu ophthalmology.**

Eau. (F.) Water. An aqueous solution of a medicinal substance.

Eau antiophtalmique. (F.) See **Aqua ophthalmica,** Vol. I, p. 543, of this *Encyclopedia.*

Eau antiophtalmique d'Yvel. (F.) An old form of collyrium made by mixing 24 parts of zinc sulphate, 8 of copper sulphate, 5 of camphor, and 2 of saffron, and dissolving a thimbleful of this powder in a pint of water; used as a remedy for chronic inflammation of the eyelids.

Eau azurée. (F.) Solutio cupri ammoniacalis.

Eau camphrée. (F.) Aqua camphoræ.

Eau de Cologne, Ophthalmic relations of. Until comparatively recently Cologne water was prepared with ethyl alcohol or Cologne spirits. Recently it is often made up with pure or deodorized wood alcohol, usually with the so-called "Colonial spirits" which is nothing more than a purified (deodorized) methyl-alcohol. In consequence of this change of menstruum drinkers of eau de Cologne are subjected to the poisonous influence of the wood alcohol. In this way quite a number of people have been blinded. This subject is further discussed on p. 3253, Vol. 5, of this *Encyclopedia.* See, also, **Toxic amblyopia.**

Gifford (*Ophthal. Record,* Vol. X, p. 343, 1901) gives a definite account of a patient (a man), thirty-five years of age, whose vision was affected by the ingestion of Cologne water prepared with the so-called Colonial spirits.

Eau de fontaine. (F.) Spring water.

Eau de Goulard. (F.) Goulard's water. An aqueous solution of lead subacetate with the addition of a little alcohol.

Eau de la duchesse de Lamballe. (F.) A preparation, formerly applied to the eyes, made by mixing 1 part of lead acetate, 2 parts of alum, and 250 parts each of rose-water and plantain-water.

Eau de l'épicier. (F.) Eau de Provence. Eau de la duchesse d'Angouleme. A collyrium prescribed by Bridault, and made of 1 gramme each of zinc sulphate, rock candy, and iris, 200 grammes of water, and 20 drops of alcohol. Applied, in part, to ophthalmia.

Eau de Mars. (F.) An old collyrium made by pouring Hoffmann's liquor and an alcoholic extract of wormwood over red-hot flints.

Eau de Provence. (F.) An ophthalmic mixture of 1 gramme each of zinc sulphate, rock candy, and iris, 200 grammes of water, and 20 drops of alcohol. See **Eau de l'épicier.**

Eau de puits. (F.) Well-water.

Eau des sources. (F.) Spring-water.

Eau divine. (F.) A solution of 25 parts each of alum, nitre, and copper sulphate, and 1 part of camphor in 5,000 parts of water.

Eau douce. (F.) Soft water.

Eau dure. (F.) Hard water.

Eau d'Yvel pour les yeux. (F.) A preparation made by boiling 61 parts of rue in 734 of water till reduced one-half, adding 30 of zinc sulphate and 11½ of copper sulphate, and, when these are dissolved, 1 9/10 of camphorated brandy; or by triturating 5 parts of camphor and 2 of saffron with a little water, adding water enough to make 1,227, and 38 each of the sulphates of zinc and copper, and filtering. (Foster.)

Eau forte. (F.) Nitric acid.

Eau ophtalmique. (F.) See **Aqua ophthalmica.**

Eau ophtalmique bleue. (F.) Solutio cupri ammoniacalis.

Eau ophtalmique danoise. (F.) This collyrium is a mixture of 5 parts camphor, 8 of lead acetate, 16 of zinc sulphate, and 1,500 of rose-water. It has also been prescribed as 5 parts of zinc sulphate, 8 of lead-water, 28 of spirit of camphor, and 1,200 of distilled water.

Eau ophtalmique de Benedict. (F.) An astringent eyewater composed of 20 to 28 parts of copper aluminate, 5 to 16 of Sydenham's laudanum, and 540 of distilled water.

Eau ophtalmique de Blasius. (F.) This collyrium is a mixture of from 5 to 6 parts of copper aluminate, 15 of hydrolate of opium, and 46 of distilled water.

Eau ophtalmique de Bogle. (F.) A collyrium made by mixing 5 parts of aloes, 7 each of zinc sulphate and antimony oxide, 180 of distilled

water, and 1 drop of oil of rosemary to the ounce. The mixture is then allowed to stand for a month, when it is filtered.

Eau ophtalmique de Conrad. (F.) A preparation no longer official, consisting of a grain (6 centigrammes) of corrosive sublimate, either tincture of opium, extract of opium, or Sydenham's laudanum in varying amount, and rose-water or infusion of elder-flowers varying from 37 to 180 grammes. Some of the pharmacopoeias added to this collyrium a little licorice, quince-seed, or tragacanth. (Foster.)

Eau ophtalmique de Crespy. (F.) A preparation composed of 12 parts of zinc sulphate, 3 of powdered orris-root, and 700 of water.

Eau ophtalmique de Graefe. (F.) A collyrium containing 0.12 part of copper aluminate, 28 parts of rose-water, 4 parts of quince mucilage, and 2 parts of Sydenham's laudanum.

Eau ophtalmique de Jaeger. (F.) A collyrium containing 1 part of copper aluminate, 2 parts of pyroligneous acid, and 480 parts of water.

Eau ophtalmique de Loches. (F.) This eyewater contains 3 parts of tincture of aloes, 5 each of aluminium sulphate and zinc sulphate, 20 of alcohol, and 450 each of distilled water and melilot-water.

Eau ophtalmique de Rust. (F.) A collyrium containing from 18 to 24 centigrammes of copper aluminate, 30 grammes of aqua sambuci, 12 drops of tincture of opium, and 5 drops of lead-water.

Eau ophtalmique de Theden. (F.) An astringent collyrium containing 1 part of ammonium chloride, 2 parts of copper aluminate, and 20 parts of rose-water.

Eau ophtalmique fortifiante. (F.) This mixture (collyrium) contains 7.6 parts each of lead-water and spirit of camphor, 3.8 of zinc sulphate, and 245 of aqua chamomillæ.

Eau ophtalmique mercurielle. (F.) This collyrium is no longer an official preparation. It consisted of a grain (6 centigrammes) of corrosive sublimate, either tincture of opium, extract of opium, or Sydenham's laudanum in varying amount, and rose-water or infusion of elder-flowers varying from 37 to 180 grammes. Some of the pharmacopœias added to the collyrium a little licorice, quince-seed, or tragacanth.

Eau ophtalmique resolutive. (F.) AQUA OPHTHALMICA RESOLVENS. A preparation once official in the Hamburg Code of 1835. It contains 1 part of antimony and potassium tartrate, 60 parts of laudanum, and 240 of water.

Eau saturnine. (F.) Liquor plumbi subacetatis dilutus.

Eau zincée camphrée. (F.) A solution, used occasionally as an eyewater, of 18 parts of zinc sulphate and 8 of camphor in 786 of boiling water; or of 28 parts of zinc sulphate and 8 of camphor in 786 of water.

Ebbinghaus's theory. See **Color-sense and color-blindness.**

Ebène. (F.) Ebony.

Ebenheit. (G.) Evenness.

Ebenheit des Feldes. (G.) Flatness of field.

Ebers, Georg Moritz. This well-known German Egyptologist was born at Berlin, March 1, 1837. He discovered and translated numerous papyri, of which the most important, from an ophthalmic standpoint at least, is the medical document known as the "Papyrus Ebers." This writing, discovered at Thebes in 1872, forms our chief, indeed almost our only, source of knowledge concerning ancient Egyptian ophthalmology. Prior to 1872 our scanty fountains of information were Greek and Roman authors—e. g., Herodotus, Celsus, Plutarch, Galen.

The papyrus Ebers consists of 110 pages, describing all the diseases (and the remedies therefor) that were known to the Egyptians at the time when the document was written—about B. C. 1500. Eight pages are devoted exclusively to diseases of the eye. The ophthalmic portion of the work Ebers translated into German and published at Leipsic with the title, "Papyrus Augenkrankheiten." Many ocular diseases are named in this early work on ophthalmology, but none are described in detail. Numerous prescriptions are given.

Ophthalmology is often declared to have had its origin in Egypt, and the ophthalmic portion of the papyrus Ebers is frequently declared to be the oldest document in existence in which are mentioned the diseases of the eye. Both these statements, however, are erroneous. The papyrus Ebers, as stated already, dates back to only B. C. 1500; the Code of Hamurabi, however, which, though a legal composition, contains a number of important references to ophthalmology and ophthalmologists, as well as a number of laws concerning both these heads, extends across "the dark backward and abysm of time" to the year two thousand two hundred and fifty years before Christ—a hoary document before the papyrus Ebers was even dreamed of.

(A detailed account of the ophthalmologic portion of the papyrus Ebers will be found under **Egyptian ophthalmology,** as well as under **History of ophthalmology.**)

Ebers was the author of a number of well-known historical novels, of which the most important are: Uarda; The Bride of the Nile; The Emperor; A Thorny Path.

He died in August, 1898.—(T. H. S.)

Eble'scher Papillarkörper. (G.) Conjunctival follicles.

Eblouissement. (F.) A momentary dullness of vision produced either

by the too sudden impression of light or by some subjective cause, such as disease of the eye or cerebral congestion.

Ebn Sina. See **Avicenna.**

Ebony. *Diospyros ebenum.* (*Ebenus,* Pliny xxiv, 52.) A favorite remedy among ancient Egyptian and Greco-Roman ophthalmologists. The sawdust from ebony wood was first macerated in wine for four-and-twenty hours, then made into little cakes, or (solid) collyria. An infusion of the roots was also sometimes employed.—(T. H. S.)

Ebranlement. (F.) A shock. Commotion.

Ebranlement de la rétine. (F.) Commotio retinæ.

Ebranlement des tissus. (F.) Contusion of the tissues.

Ebstein's theory. A theory as to the origin of gout, which the author claims is a nutritive tissue disturbance in the first instance, afterwards leading to necrosis. In the necrotic areas urates are deposited.

Ebullioscope. A thermometric instrument for determining the boiling point of spirits.

Eburnation. Conversion into an ivory-like substance.

Eburné. (F.) Ivory-like.

Ecaillette. (F.) A small scale.

Ecailleux. (F.) Scaly; squamous.

Ecart. (F.) Separation; divergence.

Ecartement. (F.) Separation; divergence; abduction.

Ecarter. (F.) To draw away from the median line of the body or limb.

Ecarteur. (F.) A retractor or instrument for holding structures apart. Also, an abductor muscle.

Ecblepharos. An ancient form of prothesis, or artificial eye.

This term has been revived by Mueller (of Wiesbaden) to indicate a

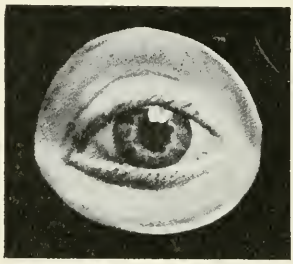

Ecblepharos. (Mueller.)

form of artificial eye to be used in obliteration of the conjunctival cul-de-sacs, in cicatricial orbit, or in any form of destruction of that cavity,

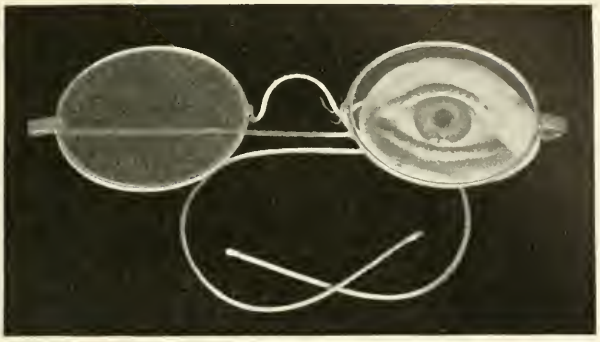

Ecblepharos Secured to the Spectacles. (Mueller.)

Face without Ecblepharos.

Right orbital cavity completely destroyed and covered with skin.

Face with Right Ecblepharos. (Mueller.)

The foregoing defect remedied by an outwardly attached eye.

in which it is not possible—even after operative measures—to insert an artificial eye.

Each eye is made according to model and pattern to suit the particular case and, mounted on a silver plate, is soldered to the patient's spectacles. The accompanying figures give a fair idea of this device and its employment in obtaining a good cosmetic result in an otherwise disfiguring class of cases.

Eccanthis. (L.) A fleshy growth at the angle of the eyelids.

Eccauma. (L.) According to Ætius, gangrenous blepharitis.

Eccentric. Excentric. Not in the center; not having the same center.

Eccentric pencil. In *optics*, a pencil of light or ray-bundle that is incident to or that emerges from a peripheral portion of a mirror or lens.

Ecchimosi della congiuntiva. (It.) Ecchymosis of the conjunctiva.

Ecchymosis conjunctivæ. This subject has been fully discussed on pages 3011 and 3015, Vol. IV of this *Encyclopedia*.

Ecchymosis of the lid. Constitutes what is popularly termed a "black eye." On account of the exposed location of the eye and the lax condition of the lid skin, contusion with discoloration is more frequent in this location than in any other region of the body.

Treatment.—The ordinary black eye, if seen at once, is best treated by cold applications (cloths wet with iced water), or with an evaporating lead lotion:

℞

Liq. plumbi subacetatis	
Alcohol.	āā f℥i
Aq. destil.	Oi.

Where a definite blood-clot has formed within the palpebral tissues, the common practice of incising the skin and allowing the blood to escape, or applying two or three leeches to the orbital margin is a good one. An antiseptic dressing should be subsequently applied. Unless treatment is resorted to within two days, no remedy will be of use. It is then best to cover up the discoloration with flesh-colored paint. I would advise every practitioner to keep on hand some water colors for this purpose. No production of his artistic hand will be more appreciated than that which disguises such a noticeable blemish. See **Eyelids, Ecchymosis of the.**

Ecgonine. This alkaloid, $C_9 H_{15} NO_3 + H_2 O$, is produced synthetically along with benzoic acid and methyl alcohol, by the action of hydric chloride on cocaine in closed tubes at a temperature of 100 degrees C. It forms colorless, monoclinic prisms of a slightly bitter, but sweetish, taste. It is very soluble in water, less soluble in absolute alcohol, and is insoluble in ether. *Ecgonine hydrochloride* is found as white crys-

tals, soluble in water, very slightly in alcohol. Both agents act as local anesthetics, but in no respect rival the desirable qualities of cocain, holocain, eucain or acoin.

Echaudure. A scald, or burn with hot steam or liquid.

Echelle. (F.) Type. Test type.

Echelle de laines. (F.) Wool skein test.

Echelle optométrique. (F.) Test types for determining the acuity of vision.

Echelle optométrique à main. (F.) Test types for near vision.

Echelle optométrique murale. (F.) Test (visual) types for the distance.

Echelles d'optotypes. (F.) Optotypes.

Echelon grating. In *optics,* a diffraction grating invented by Michelson and used to observe a very high order of spectra. It consists of a number of superposed exactly similar glass plates built up in *echelon,* or steps of equal width, and through which an enormous increase in resolving power is obtained. The echelon grating is not applicable for the analysis of sunlight or for similar purposes. See **Diffraction.**—(C. F. P.)

Echelon-lens. A lighthouse projector, consisting of a series of annular lenses arranged concentrically in echelon or steps.

Echidnin. The venom of the viper and other poisonous snakes. It is a nitrogenous principle found in the poison sac.

Echimosis. A "simplified" spelling of ecchymosis.

Echinacea angustifolia. Black sampson. A perennial herb growing in the United States. It is prescribed occasionally in ophthalmic practice because it is claimed to have alterative value in strumous and syphilitic conditions. The dose of the fluid extract of the root is 25 to 30 minims.

Echinococcus of the ocular apparatus. Hydatid cyst. The embryo or scolex of *Tænia echinococcus,* the tapeworm of the dog. It is found in man, most frequently in the liver, lungs, and brain, embedded in a cyst-like structure. Echinococcus is an exceedingly rare intraocular parasite. In the same way hydatid cysts of the orbit or neighboring cavities is extremely uncommon. According to Parsons (*Pathology of the Eye,* p. 438) it has been found in the former case in only two undoubted instances. The clinical features of the two cases were similar. In both the cyst was visible as an opacity on the posterior surface of the clear lens, and appeared closer to the observer than a posterior cataract. There was no red reflex, and the eye was blind. In Werner's case the tension was raised; in Hill Griffith's glaucoma was induced by atropin. Anatomically both were simple cysts, containing no daughter cysts

as distinguished from brood capsules; each completely filled the eye behind the lens. One was situated in the vitreous, the other between the retina and the choroid. Probably the difference in situation accounted for the sterility of the former, and the contact of the latter with the vascular choroid possibly led to a better state of nutrition and promoted the development of brood capsules. In neither case was a connective-tissue capsule present. As regards the mode of infection, while cysticercus can be caused by auto-infection, this is impossible in the case of hydatid, since the tænia echinococcus has never been seen

Intraocular Hyaline Laminated Ectocyst, Curved inwards. (Parsons.)
The outer surface is greatly wrinkled.

in man. In Werner's case the cyst was a typical echinococcus. It consisted of two layers—an outer, thick, homogeneous, and elastic, with a great tendency to curl inwards, and composed of numerous fine laminæ and an inner or parenchymatous layer (endocyst) much more delicate, and composed of a finely granular substance containing many nuclei, but no outlines of any cells. It is traversed by a fine network of stiff homogeneous cords, seen only in surface preparations. There were small white bodies on the inner surface, which proved to be brood capsules; they arise from the parenchyma, and are connected with it by a narrow stalk. In some of them Werner counted as many as fifteen heads or scolices. Some are retracted, the circle of hooklets being visible in their interior, while others are fully extended, and show their structure very well, viz., the rostellum with hooklets, four suckers, and below this a neck-like constriction. Each head is attached to the inner surface of the capsule by a small stalk which passes into its base.

Heads in an early stage of development can be seen in most of the capsules.

Orloff (*Ann. d'ocul.*, February, 1908) removed a tumor of the upper lid, the shape of a date seed, which the microscope showed to be an alveolar echinococcus. The reporter believes that the growth was primary in the lid; and that no nucleus of infection existed elsewhere in the organism of the patient.

Cosmettatos' (*Klin. M. f. Augenh.*, Sept., 1912, p. 345) two cases of echinococcus of the orbit both led to final loss of the eyeball. The first case, that of a 30-year-old woman, was of four years' duration. The second occurred in a 55-year-old priest whose other eye had been hopelessly damaged by an explosion some years before; and who therefore declined operation when it was first proposed on the eye in the affected orbit. This case was of six years' duration. Cosmettatos directs attention to the differential diagnosis of echinococcus cysts of the orbit and other orbital cysts and advocates exploratory puncture; but warns that as punctured cysts infect very readily one should be prepared to go on to complete removal of the cyst in every case. In Redondo's (*Arch. de Oft.*, XII, p. 471) case ptosis had existed for eight years when marked proptosis and corneal ulceration made operation imperative. Exploratory puncture yielded fluid in which were found the scolex and segments of tænia echinococcus. The cyst contents were aspirated and 1 :1,000 bichlorid solution injected. After three days, with forceps and expression, the cyst membrane was extracted through a cutaneous incision.

Slerandi (*Woch. f. Ther. u. Hyg. des Auges,* Dec. 12, 1912) reports a case in a 44-year-old man, the first symptom being ptosis, noticed nine years previous to his admission to the clinic. On admission there was ptosis, exophthalmos, a fluctuating mass behind the eye, and perforating ulcer of the cornea with iris prolapse. Puncture showed scolices. Incision and irrigation with sublimate. Five days later extrusion of the sac, followed by a speedy cure. Subsequently ptosis operation. The conservative treatment in this class of cases thus receives further support.

According to Parsons (*Pathology of the Eye,* Vol. 2, p. 723), Berlin collected thirty-nine cases of *hydatid cysts of the orbit*, to which Lagrange added thirty-two more. He says that they may occur in any part of the orbit, slightly more commonly below, and up and out. Unlike hydatids in other parts of the body, they show no special preference for the muscles, though such have been described. It is very exceptional for them to originate in the orbital walls. They may invade the walls and cranial cavity, etc., secondarily, or the orbit from

the cranium. They usually vary in size from a pea to a nut, though they may become as large as a large orange. They are at first spherical, other shapes resulting later from external pressure. They are remarkably free from adhesions to neighboring structures, these being probably always due to injury, followed by inflammation. Growth is usually slow, though it is sometimes apparently very rapid. Most cases of hydatid cysts in the orbit occur in young people; only 2 out of 36 patients were over 40. Males are affected slightly more than females; the opposite is the case, however, taking all parts of the body. Brood capsules and heads are formed later in echinococcus cysts than in most others; they are more commonly absent than present in man, and even more so in some situations than in others, the orbit being one. When scolices or hooklets are found in the fluid they are absolutely pathognomonic. The cyst wall has the characteristic lamination of all hydatid cysts. Thierfelder examined the cyst wall in its original surroundings. The cyst was imbedded in highly vascular tissue, which was infiltrated with inflammatory cells. The muscles had undergone colloid degeneration. There are rarely brood capsules and scolices on the inner surface of the mother cyst, but these, when they occur, are generally formed in daughter cysts, which themselves arise from the germinal layer of the mother cyst, or from brood capsules or scolices. The daughter cysts may reach 100, as compared with several thousands in the liver. The fluid contents show no cells, like serous cysts, nor fat, like dermoids. It remains clear on boiling, and on the addition of acids. It is usually neutral in reaction; specific gravity, 1009 to 1015. It contains no albumen, but large quantities of sodium chlorid. It often contains grape sugar, sometimes succinic acid, and inosit. Jacobson found 0.54-0.84 per cent. of sodium chlorid; this may be tested for by silver nitrate. Small quantities of albumen may be found after the echinococcus is dead, or after rupture or puncture. The fluid is clear at first, but becomes milky after the death of the parasite. After rupture of the cyst the walls fall together, calcium carbonate and phosphate are deposited, as well as cholesterin, and suppuration often takes place. The eyeball may be destroyed by pressure or exposure due to the proptosis. See, also, **Cysticercus cellulosæ**, Vol. V, p. 3661 of this *Encyclopedia*.

Echinophthalmia. (L.) An old name for an inflammation of the edges of the eyelids with bristle-like appearance of the lashes.

Echitamin. An amorphous alkaloid obtained from the bark of *Alstonia scholaris*, the Devil's tree. This plant is a native of India and Polynesia. It has a paralyzing power comparable to that of curare;

and is also called **Ditain.** The effects upon the eye are practically the same as those induced by Curare.

Echmasis. An obstruction or an obstructive disease.

Echophotony. PHOTISM. The production of color sensations by means of aërial waves, or sound.

Eclair. (F.) A flash of light. Lightning.

Eclairage. (F.) Lighting; illumination.

Eclairage inoffensif. (F.) Non-actinic light.

Eclampsia. This is an ancient (and now obsolete) term applied to a sensation of light flashing before the eyes. In *general medicine*, it is an acute affection occurring without structural lesion of the nervous system, characterized by general or partial convulsions, with more or less complete loss of consciousness.

Adam (*Ophthalmology*, p. 629, July, 1912) has observed in 44 out of 92 cases of eclampsia visual disturbances, mostly due to uremic amaurosis, 4 to albuminuric retinitis or neuroretinitis. In 35 cases the ophthalmoscopic condition was normal, in 5 there was sclerosis of the choroidal vessels with thrombosis and extensive hemorrhages, in concordance with the frequency of thrombosis in various organs in eclampsia. The autopsy in one case verified this condition of the eye. In all probability some of the fundal alterations were due to cerebral or other lesions of which the eclampsia was merely an incident.

Eclectic. A medical practitioner who professes not to be governed by any general theory or system of practice, but to select from all systems that which most conforms to reason and experience. Every rational therapeutist is an eclectic.

Eclimeter. An instrument for approximately measuring the vertical angles or zenith distances of objects on the horizon.

Eclipse amblyopia. ECLIPSE BLINDNESS. SOLAR BLINDNESS. ECLIPSE OPHTHALMIA. SOLAR GLARING. BLINDNESS FROM DIRECT SUNLIGHT. SCOTOMA HELIECLIPTICUM. The action of bright sunlight, on the ocular tissues, as seen in an eclipse of the sun when the eye is unprotected, is partly due to the heat rays, but more especially to the actinic, or chemically active, ultra-violet rays. In all probability the latter alone affect the lens and retina, the aqueous humor acting the part of a heat screen. In eclipse blindness there is frequently a central positive or negative scotoma. With the ophthalmoscope there is sometimes seen a whitish area about the macula. This finally gives place to pigment deposits with or without a grey, central area.

Four cases of glaring consequent upon the eclipse of 1905 are described by Menacho (*Archiv. de Oftal. Hisp.-Am.*, May, 1906). The same author previously described some seventeen cases seen after the eclipse of 1900. He attributes the diminution in the number of cases

to two circumstances: the recent experience of the public, the hygienic campaign by the newspapers and the fact that the sky was overcast during the greater part of the more recent eclipse. In three of the observations, visual disturbances were noticed immediately after the eclipse. These consisted in central scotomata of greater or less extent. The ophthalmoscopic signs were the following: a disc red in one case, in another a slight pigmentary ring on the outside of the disc; the rest had normal discs; in one case, a slight focus of choroiditis. The two first cases were cured by the galvanic current, strychnia and smoked glasses. In the last the visual trouble disappeared without treatment, but there remained an acute conjunctivitis occasioned by the light of the sun. In the fourth observation an intense chronic catarrhal conjunctivitis was noted. Alumnol baths (2 per cent.) and applications of nitrate of silver brought a cure in two weeks. The writer believes, from all the data which he collected, that the conjunctivitis had a purely photochemical origin.

Menacho compares the retinal phototraumatisms with those produced by the light of a voltaic arc or of any focus of intense light. He previously published an observation of the first, and he now includes one of the second: central relative scotomata caused by being obliged to look continually during two days at the reduction zone of an electric furnace. He also relates another case caused by looking for a long time at the moon which shone with an intensely brilliant light. In this case there existed in the right eye a large scotoma; left eye, notable concentric reduction for white, less for colors. Thus the author proves that any luminous focus may produce perturbations in the eye which suffers its encounter.

As regards pathogenesis, he divides the manifestations into two groups: one of a purely functional nature caused by physico-chemical reactions either too intense or too prolonged; and the other organic lesions, due especially to the action of thermic and chemical radiations.

The eclipse of the sun on April 17, 1912, injured many eyes. Birch-Hirschfeld (*Bericht der Oph. Gesell*, p. 241, 1912) calculated that there were more than 3,000 cases treated in Germany, of whom perhaps 10 per cent. received serious or permanent injury. The four points of interest in these cases are, the ophthalmoscopic appearances, the clinical symptom of a central scotoma, the anatomical basis of the lesion, and the etiology, viz., to which region of the spectrum the lesion is to be attributed.

Thirty-four patients, with 50 injured eyes, were examined, most of the patients being in the second and third decades of life. Only four of the patients possessed light-blonde hair and grey-blue eyes; the others

had dark hair and well pigmented eyes. This indicates that the pigmentation of the epithelium and the uvea as connected with the absorption of light influences the intensity of the lesion.

Most of the cases occurred at a time when the right lower third of the sun was eclipsed, but in no case was it possible to demonstrate either a scotoma, or a foveal lesion of corresponding form.

Almost in every case the first symptom was a moving, flickering cloud in the middle of the field, which soon became a circumscribed spot, and continued to move restlessly even after many months. One of the patients complained of erythropsia, and several of the binocular cases of nyctalopia.

The cases may be divided into three groups. Twelve of the eyes had normal acuity of vision, 19 had an acuity of from 6/9 to 6/15, and the 19 remaining eyes had an acuity of from 6/18 to 6/60. Of the latter group 3 were cured, 10 improved, and 6 remained unaltered, while of the 19 in the second group 11 obtained normal acuity in some weeks or months, 6 improved to some extent, and 2 remained unaltered. The ophthalmoscopic appearances were examined repeatedly, both with the ordinary ophthalmoscope and Gullstrand's. In only four cases was the fundus normal; in all the others, changes were to be seen in the macular region, often indeed very trifling. In one group of cases the form of the foveal reflex appeared enlarged, indistinct and of irregular form, and its neighborhood became of a dark brown-red color. There were 19 cases in this group.

Between this indistinctness of the fovea and a circumscribed grey or yellowish exudation all stages were observed. In some cases the diameter was one-fifth that of the disc. The shape was circular, oval, or half-moon, though not corresponding to the shape of the sun at the moment of blinding. A dark-red macular exudation was observed four times, but no bright-red ring surrounded it as in the cases of Deutschmann and others, and no hemorrhage was ever observed.

On two occasions a slight prominence of the foveal exudation could be perceived with the stereoscopic attachment of Gullstrand's ophthalmoscope. These visible lesions disappeared completely in the course of some weeks in 11 cases. In 16 other cases there developed an irregular pigmentation of the macula and minute irregular punctiform stipling, and these appearances remained without alteration for many months.

As regards the relation between ophthalmoscopic appearances and lesions of function no direct connection could be established. Out of 15 eyes with slight temporary ophthalmoscopic changes, or none at all, 7 had considerable disturbance of vision, 4 a slight disturbance, and 4 none; while of 30 eyes with prominent ophthalmoscopic changes 14

had no visual defect, 7 a very moderate defect, and 9 a severe defect in sight. From this we may conclude that the visible ophthalmoscopic changes are not the essential causes of the defective sight.

Thirty-one eyes out of 50 had a central and 19 a para-central positive scotoma. In all cases it was absolute at the commencement, becoming frequently relative in the course of time. As in the majority of the cases the scotoma to be measured was positive, it could be charted by the patient himself. Its size varied, in 36 eyes between ½ degree and 1 degree, in 9 eyes less than ½ degree, in 5 greater than 1 degree. In four cases the scotoma measured 3 degrees. In 24 cases with a scotoma less than ½ degree the visual defect was slight, while in 13 eyes with a scotoma greater than 1 degree only 4 had a slight defect, and 9 considerable blindness. The shape of the positive scotoma was circular in 7 cases, a vertical oval in 12, horizontal oval in 4, irregular in 10, and kidney shaped in 3. The size of the scotoma corresponded approximately to that of the sun's image in 28 eyes, but its form bore no relation to that of the sun.

But the central positive scotoma does not correspond to the whole region affected.

In most of the patients there was also a relative central scotoma specially for yellow, and this was accurately observed in 20 cases. It varied in dimensions between 1 degree and 10 degrees diameter, the more recent the blindness the larger the scotoma. In days and weeks it diminished in circumference, while the central positive scotoma remained unaltered. The author believes that this central relative scotoma is of prognostic value, as the more rapidly it diminishes in size the more favorable the prognosis.

As regards the anatomical basis of this blindness experiments have convinced A. Jess that intense light produces more severe changes in the eyes of well-pigmented rabbits than in albinos. His later experiments corroborate his former observations as well as those of Czerny, Deutschmann and Widmark, in which the anatomical basis of sun blindness was shown to be a necrosis of the external retinal layers with transudation from the choroid and destruction in the pigment epithelium. The inner retinal layers were only affected secondarily. This supports the theory that the ultra-violet rays have no essential connection with this blindness. Whether it is the heat rays or the light rays or both together which cause the lesion is a point which Birch-Hirschfeld answers by stating that the heat rays are no more essential than the ultra-violet rays, and that the light rays must be regarded as the noxious agent. Of course this does not deny the possibility of a burning of the retina by light rays being brought to focus upon it.

A simple experiment demonstrates how the lens can act as a burning-glass, and also the action of the pigmentary epithelium.

A glass box the size of the eyeball is filled with water at 37 degrees centigrade, and a lens of 20 D. with an iris diaphragm placed in front so that its focus is at the posterior wall of the box. If paraffin with a melting point of 50 degrees centigrade be smeared on the back of the box, and the axis of the lens directed towards the mid-day sun it takes several minutes before the paraffin is melted by the image of the sun. If, however, a piece of black paper is placed to represent the pigment epithelium behind the paraffin the latter is melted in a few seconds. If ferro-sulphate solution is used instead of water, so as to exclude most of the heat rays, the effect is hardly altered. It cannot be possible for the tissues to endure such a temperature without serious injury.

Treatment for this affection is practically useless. Dionin and subconjunctival injections may possibly have some effect, and as regards prophylaxis, a really dark glass is the only efficient protection.

In the subsequent discussion Jess presented some 70 charts of visual fields showing the ring scotoma he had described and all stages in its progress towards recovery. This relative scotoma is certainly a pathological phenomenon, and in its nature and course resembles the paracentral scotoma described by Birch-Hirschfeld as caused by the "Uviol" lamp. Jess is familiar with the color-blind area described by Birch-Hirschfeld.

Best has observed a decrease in the adaptation of the retinal periphery in eclipse blindness, and Van der Hoeve concentric contraction of the fields of vision, an observation made by many others.

Hoppe has noticed a peculiar condition of the central vision, which continued for months in most cases, persisting even after return of normal vision. The highest acuity lasts only for a second or two, a mist then obscures the test letters for two or three seconds, to disappear in its turn, and so on. Abnormally rapid fatigue and delayed recovery of function are shown by this symptom. (Review by J. B. Story in *Oph. Review*, May, 1913.)

Several of the observers who took part in the discussion of the foregoing report have published independent papers on the subject, several of which are here abstracted. Hoppe (*Muench. med. Woch.*, 1912, No. 45) reported seven cases in which more or less serious ocular injury occurred because of prolonged observation of the recent solar eclipse; in a few, in spite of protective measures. All were blondes, with light colored irides. In five cases both eyes were affected. In one there was conjunctival injection with lachrymation.

The fundus changes confined themselves to the macular region, consisting of a circular or vertical, oval, yellowish-orange disc surrounded by a darker, red-brown zone. Scintillation of the disc was rather frequently observed.

Four patients exhibited a positive absolute scotoma, two a sharply-defined, circular defect in the lower right hand portion of the scotoma. There was, of course, impairment of central vision, also marked retinal fatigue enduring some weeks. Foerster's photometer revealed decreased sensibility in the central retina. Metamorphopsia within the scotoma occurred in four patients. In the region of the scotoma the color sense was entirely lost, but fully regained in two weeks. While an ideal restoration of the retinal functions did not occur, useful vision was regained in every case within six weeks after exposure.

A. Jess (*Arch. f. Augenheilk.*, 1913, lxxiv, p. 78) examined 36 patients who complained of glaring after observing the eclipse of 1912. In 15 both eyes were affected; in 21 only one eye; altogether 51 eyes. Since disturbances of the center of the fundus corresponded in most essentials with those reported by numerous other observers, Jess does not enter into them. In one case vision was reduced to 1/60, and in the fovea an unusually large red central focus was found surrounded by a disciform, reddish-grey area but no swelling. The visual field showed, besides the central scotoma, a complete obscuration of the white square and total color-blindness, from the fortieth to the twentieth degree. In the corresponding area of the retina, which lies from 6 to 12 mm. from the fovea, no pathologic changes could be ascertained. The patient was admitted to the clinic and given iodide of potash. Vision improved rapidly and after three weeks was normal. A small, oval, well-defined focus could still be found, and the patient complained of a small central nebula, which at times was very disturbing, but the peripheral scotoma had entirely disappeared. After the discovery of this very marked ring-scotoma all other cases were carefully examined with regard to it, and in 26 patients a total, or partial, ring-scotoma was found. In most cases it was total and, if partial, it was located in the lower half of the visual field. It always was temporary and only in six cases lasted long. It consisted not only in a disturbance of the color perception, but was relative for white and in a few severe cases absolute for colors. It cannot very well be attributed to the direct influence of the rays of light, but was probably caused by a disturbance in the blood supply accompanying the foveal lesion. That the visual disturbance was noticeable in a ring-shaped zone may be explained by the lesser resistance of the retinal elements in these parts, which corresponds with their hypesthesia to colors, as

found by Birch-Hirschfeld. Also the view is very plausible that disturbances of circulation may very easily damage the ring-shaped zone of the choroid, which is almost free of arterial anastomoses.

Boehm (*Klin. Monatsbl. f. Augenheilk.*, April, 1913) gives a complete statistical synopsis of the ocular lesions from sun-glare during the eclipse of April, 1912, reported in the provinces of Silesia and Posen, and of those collected by Axenfeld, with consideration in detail of 26 cases observed at the clinic of Uhthoff and 26 at the clinic of Axenfeld, altogether 412 cases. The ophthalmoscopic changes were chiefly limited to the macular region. Boehm emphasizes the fact that changes of the macula are, in general, difficult to interpret, because slight pathologic alterations are frequently difficult to distinguish from normal variations. With regard to the view of some authors that the crescentic foveal foci of the macula are direct optograms of the sun, he quotes the statement of Uhthoff, that it is utterly impossible that the glaring and directly damaging action of the sun can be expressed in so well-defined a figure. The changes are, according to most authors, due to exudation, circumscribed hyperemia of the choroid, changes of the pigment epithelium, greater pigmentation of the macula, and destruction of the sensory epithelium.

The prognosis of the macular changes is relatively favorable, as they may partly or completely subside. In some cases conjunctivitis was observed. The clinical symptoms consisted in burning and stinging sensations in the eye, headache, flickering and impairment of vision. The central scotomas were mostly positive, sometimes negative; their form showed no relation to the shape of the disc of the sun, at the moment of glaring.

The small central scotoma is one of the most characteristic phenomena of glaring by the sun. Although especial attention was paid to the detection of ring scotoma, Boehm could not find it in any of his cases.

In general, the central retinitis terminates favorably. The positive scotoma became smaller, the dark spot lighter and its borders more indistinct. Fifty-three cases healed completely; in the remaining cases the disturbances diminished, but did not entirely subside. A few eyes were severely and permanently injured. The refraction seemed to have some influence on the occurrence of the retinitis. Most patients were emmetropic or slightly hypermetropic. Metamorphopsia was observed in some cases. According to Aubaret, micropsia or macropsia occurs if the nervous elements of the retina at the macular region undergo an irregular displacement, metamorphopsia, if they undergo

a regular displacement. In one case a uniform diminution of the color sense was noted.

Kaz (*Woch. f. Ther. u. Hyg. des Auges,* Dec. 5, 1912) reported a case of transient paresis of the sphincter iridis, one of partial cataract, and a case of kerato-conjunctivitis following observation of an eclipse of the sun. The first case occurred in a hypermetrope, and he thinks prolonged ciliary spasm responsible for the paresis.

A moderate astigmatic error was present in the second case. In neither case were fundus changes observed. He refers to Lasarew's cases, in which macular hole formation occurred only in emmetropic eyes, and to the possible influence of refraction upon the intensity of the macular lesion, as suggested by Tschemolossow. Perhaps the ametrope is more liable to injuries of the anterior segment because of decreased macular irritation which encourages prolonged exposure. It was impossible to determine the refraction in the third case on account of corneal opacities.

Valois and Lemoine (*Révue Générale d'Ophtal.,* September, 1912) reported their findings in eighteen cases of young people who observed the eclipse of April 17, 1912, without using protective glasses. Depending upon the length of time exposed to the light, and whether one or both eyes were used, the symptoms varied considerably in degree, but were fairly constant in quality. Victims complained first of dazzling, then of a fixed spot which concealed objects in the center of sight; whence some patients turn their heads to increase sight. The central scotomata have sharp edges and variable color, some black, green, red, or with variegated edges and points. Most often the spot is yellow and gives the symptom of xanthopsia. Next to the scotoma the amblyopia is second in frequency. This is variable in degree, but vision is always diminished, and even if normal, fatigue shows itself so rapidly as to produce a decided asthenopia. At first the pupil shows a miosis which rapidly changes to dilation, resulting in a mydriasis with diminished light reflex.

The fundus is usually normal. Occasionally hyperemia of the disc or a woolly veiled appearance of retina is seen. None of the eighteen cases had hemorrhages. Resolution was rapid, scotomata disappearing after a fortnight, in one case after a month; the amblyopia was a little slower in leaving.

Preventive treatment. Majewski (*Rocznik Lekarski,* Vol. 2, p. 3, 1912) thinks that the public should be warned before each eclipse of the danger one risks in looking at the sun with the naked or insufficiently protected eye. The danger is not confined to total eclipses; a partial eclipse being no less dangerous, because it attracts

less attention and the observers are more bold. Inasmuch as each ecliptic period completes its revolution in eighteen years, it includes forty-one eclipses, of which at least one is visible every two years at the same point on the globe. Therefore the dangerous periods (we might even call them epidemics) recur every two years. The author believes that on the approach of each solar eclipse the duty of the proper authorities would consist in giving timely warning by every possible means of publicity, such as street notices, newspapers, schools, etc., how by simple means one may satisfy his curiosity without damage to his vision. By this simple preventative measure thousands of people may be spared permanent and irreparable damage to their eyes. (Translation from *Ophthalmology,* Oct., 1913.)

Treatment consists in the dark-room cure and rest of the eyes. If the symptoms persist, blood letting from the temples or mastoid is employed; with mustard foot-baths and energetic purgation; also instillation of pilocarpin to reduce the size of the pupil; after subsidence of the congestion, if vision is still poor, strychnia hypodermatically. If a complete cure has not taken place in four or five months, potassium iodid is the only thing that will help.

Ecmetropia. An obsolete name for ametropia.

Ecole. (F.) School.

Economics, Visual. Both lay and professional opinions on this subject are undergoing considerable changes (probably from a wide-spread interest in and discussion of the subject) and decided alterations in the conclusions reached thereby will shortly be reflected in the literature. For this reason it has been deemed best to postpone a review of the subject until the rubric **Visual economics** is reached, in a later volume of this *Encyclopedia.* In the meantime the reader is referred to the exhaustive works on this subject by E. E. Holt (who will contribute the section to this *Encyclopedia*), H. Magnus and H. V. Würdemann. The original work of Magnus has been translated by Würdemann and, in collaboration with him, published in this country under the title *Visual Economics,* Seattle, Wash., 1902.

A summary of the conclusions of these writers, as well as original observations touching this matter, will also be found under the major heading, **Legal relations of ophthalmology** by Thomas Hall Shastid, and by the same author on p. 110, Vol. I, of Wood's *System of Ophthalmic Operations.*

Ecpeplegmenos. (L.) Said of patients that remain quiet with the eyes open, neither saying nor doing anything.

Ecran d'eclairage. (F.) Reflector.

Ecran mobile. (F.) Movable screen.

Ecriture bâtarde. (F.) Sloping or slanting writing.

Ecriture droite. (F.) Upright or perpendicular writing.

Ecriture penchée. (F.) Sloping or inclined writing or penmanship.

Ectasia. Ectasis. Ectasy. Ectasion. Abnormal distension or dilatation of a part or organ.

Ectasia bulbi. (G.) Protrusion or bulging of some portion of the eyeball.

Ectasia corneæ. Corneal ectasia. Kerectasia. Various forms of protrusion of the cornea are fully considered on page 3359, Vol. V, of this *Encyclopedia* under the heading **Cornea, Ectasia of the.**

Ectasia sacci lacrimalis. (L.) Distension of the lachrymal sac. See **Dacryocystitis,** in Vol. V, p. 3709, of this *Encyclopedia.*

Ectasia, Scleral. Scleral staphyloma. This form of bulging of the

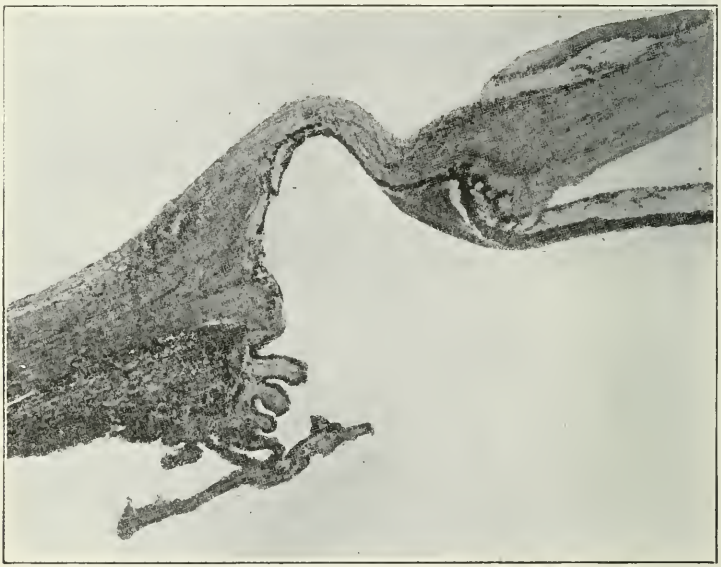

Intercalary Staphyloma (Parsons).

eye-coats may be classified as anterior, posterior, and equatorial. Anterior scleral and equatorial staphylomata appear as bluish-black or grayish projections. Their color is due to the thinned sclera permitting the dark choroid to appear. In anterior ectasiæ the limbus of the cornea forms the anterior border of the projection; in some cases both cornea and sclera participate in the bulging. Anatomic examination of enucleated eyes shows two forms of anterior scleral ectasiæ, the ciliary and the intercalary. The former shows a bulging of that part of the sclera which is lined by the ciliary body, while the latter is a protrusion between the ciliary body and the corneal margin.

Equatorial ectasiæ can be seen only when the eye is turned strongly to the side opposite the projection. Ectasiæ occur at one or more places, where the venæ vorticosæ pass from the globe, but are said not to form a ring such as sometimes occurs in anterior staphyloma. They are the result of chronic choroidoscleritis. On microscopic examination the choroid and sclera are found atrophic and adherent.

The posterior ectasiæ involve the posterior segment of the globe. They cannot be seen except the eye be removed or the ophthalmoscope

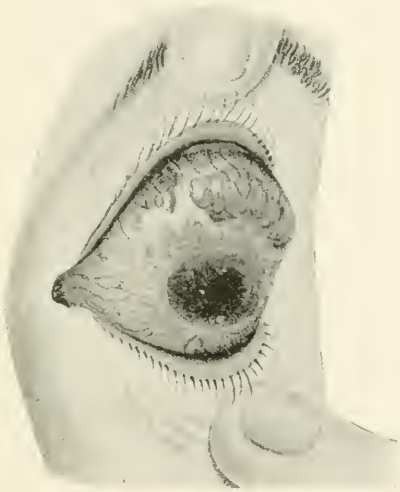

Cirsoid Ciliary Staphyloma (Ball; Vossius).

be used. These posterior projections are divided into (1) the posterior staphyloma of Scarpa and (2) the posterior staphyloma of von Ammon. The former is a protrusion situated at the temporal side of the optic nerve entrance. If large, it involves the nerve itself. Arlt discovered that this form of ectasia is frequently the cause of myopia (axial myopia). The antero-posterior diameter of the globe is elongated, and the fundus shows a white crescentic patch embracing the temporal side of the disc. The posterior scleral protrusion of von Ammon lies below the posterior pole, and is a congenital condition which arises from incomplete closure of the fetal eye-cleft. At the present day it is best known by the name inferior conus. Often in such cases there is an accompanying coloboma of the choroid and iris. The conditions described above are partial ectasiæ.

While in the adult the sclera is rigid, and gives way only in certain weak places, in the young subject the eyeball can be enlarged in every

direction. Such an ectasia of the sclera is often accompanied by an enlargement of the whole cornea (megalocornea) or by a corneal staphyloma and is known as *total ectasia of the sclera.*

The causes of scleral ectasia include those factors which either diminish the resistance of this coat or increase intra-ocular pressure. Thus, glaucoma and exclusion of the pupil by iritis belong to the latter class, while diminished resistance of the sclera follows scleritis, tumors, gummata, tubercular nodules, injuries, and the congenital condition mentioned above.

The results of scleral ectasia are loss of vision from increase of tension, great disfigurement in the anterior and equatorial forms, and constant irritation from exposure of the protruding mass after it reaches such dimensions that the lids cannot cover it. The posterior protrusion in staphyloma often leads to great increase in the near-sight without producing increased tension. Vision is often much reduced in these cases. The ectasia of von Ammon remains stationary, and, since it is situated below the macular region, it does not impair vision.

Anterior and equatorial ectasiæ of the sclera should be treated by iridectomy, for the purpose of reducing tension. If this is accomplished, the process stops. If iridectomy cannot be performed, the eye is to be left to its fate, and ultimately an enucleation will often become necessary.—(J. M. B.)

Ectasion. Distension. A synonym of ectasia.

Ectasis equatorialis corporis ciliaris. (L.) Equatorial staphyloma of the ciliary body.

Ectasis annularis. (L.) Annular staphyloma, usually confined to the ciliary region.

Ectasis corneæ. (L.) Staphyloma corneæ.

Ectasis intercalaris. (L.) Staphyloma of the cornea at the limbus or sclero-corneal margin.

Ectasis iridis. (L.) An expansion of the iris caused by a relaxation of the dilator fibres and a contraction of the sphincter, causing a contracted pupil.

Ectasis postica. (L.) Posterior staphyloma.

Ectasis scleræ. (L.) Staphyloma scleræ.

Ectillotic. An agent capable of removing hairs; a depilatory.

Ectiris. (Obs.) That part of Descemet's membrane that lies in front of the iris.

Ectochoroidea. The outer layer of the choroid.

Ectocornea. A name for the external epithelium of the cornea.

Ectoderm. Epiblast. The primitive outer wall of the body; the ani-

mal germinal layer. From it are derived many of the ocular structures. See **Development of the eye**; also, Vol. 5, p. 3862 of this *Encyclopedia.*

Ectofrontal fold. A term employed by Owen, to indicate a rather ill-defined region between the ectofrontal fissure and the orbital fissure.

Ectogenous. Developed from the outside; generally referring to pathogenic bacteria and toxines.

Ectoparasite. In biology, a parasite that lives on the exterior of its host.

Ectophthalmus. (L.) Having eyes outside of the head.

Ectopia. (L.) A morbid or developmental anomaly of situation of an organ.

Ectopia bulbi. Ectopia oculi. (L.) A condition of arrested development in which there is no brain, and in which the vault of the skull is almost entirely wanting, the frontal bones and orbits are stunted, and the greater part of the eyeball projects uncovered. (Foster.)

Ectopia della lente. (It.) Dislocation of the lens.

Ectopia lentis. Dislocation of the crystalline lens from the lenticular fossa, from rupture or lack of development of the suspensory ligament. It may be congenital or acquired. See **Lens, Dislocation of the.**

Ectopia oculi. Abnormal position of the eyeball in the orbit.

Ectopia pupillæ. Corectopia. Displacement of the pupil. That condition in which the pupil occupies a decidedly eccentric position. This anomaly may be either congenital or acquired—in the latter instance the result of operative measures or of accidental traumatism. Risley and Weisenburg (*Ophth. Rec.*, p. 240) report the presence of ectopia pupillæ in a child with hydrocephalus. The right pupil was displaced up and in. When first observed it was intermittent; since, at a second observation, it was found quite normally situated and the pupil of the fellow eye displaced. The pupils responded to light but dilated again even while exposed to strong light. There was consecutive atrophy of the optic nerves. Weisenburg considers that there was a dilatation of the third ventricle and that therefore the dilatation of the pupil was of central origin. See **Corectopia**; as well as **Congenital anomalies of the eye,** in Vol. IV, p. 2776, of this *Encyclopedia;* also, **Injuries of the eye.**

Ectopia tarsi. (L.) A peculiar form of congenital defect of the lid, described by Blasius and Fleischmann, in which this form of ectopia is caused by a separation of the tarsus from the rest of the lid, and a second lid is developed between the latter and the eyeball. (Foster.)

Ectopion. (L.) A synonym of ectopia.

Ectopisis. (L.) An obsolete term for ectopia.

Ectopismus. (L.) (Obs.) Synonym of ectopia.

Ectopium. (L.) A synonym of ectopia.

Ectopy. An abnormality of position. Ectopia.

Ectorbital. Situated upon or connected with the external (temporal) portion of the orbits.

Ectoretina. The external or pigmentary layer of the retina.

Ectosquelette. (F.) Exoskeleton. The external covering-skin, carapace or scaly coat of an animal.

Ectothalamus. (L.) The outer, medullary lamina of the optic thalamus.

Ectozoön. An external animal parasite; an ectoparasite.

Ectrogeny. A term employed by Serres to describe a malformation consisting in a lack or defective development of a part.

Ectropion. Ectropium. Ectropion in general. A condition in which there is eversion of an eyelid, which generally exposes the conjunctiva.

Ectropion may be partial or complete. Czermak has classified it as follows: 1. Ectropion from traction on the anterior part of the lid: (a) cicatricial ectropion, and (b) ectropion from division of the lid by a wound vertical or oblique to the musculature (the so-called wound-coloboma). 2. Ectropion from relaxation of the lid-margin: (a) in paralysis of the orbicularis muscle (paralytic ectropion), and (b) in relaxation of the tissues and loss of the muscle-tone of the palpebral portion of the orbicularis (the ectropion of chronic conjunctivitis, chronic inflammation of the lid-margins, and of senility). 3. Ectropion from malposition of the tissues in consequence of pressure on the lid-margin from behind, or from backward traction on the convex tarsal surface: (a) spastic ectropion, (b) in ectasiæ or tumors of the anterior part of the globe with exophthalmos, (c) from pressure on the lower lid by conjunctival and tarsal tumors, (d) from traction of tumors on the peripheral part of the tarsus or on the conjunctiva. These are cases of mechanical ectropion.

The *symptoms* of ectropion are the turning out of the lid, epiphora, and thickening of the conjunctiva. The skin of the cheek is eczematous. If the ectropion is slight, it causes so little discomfort that many persons do not seek relief. If the eversion is great, corneal complications are likely.—(J. M. B.)

Spastic ectropion, also known as muscular or acute ectropion, usually affects only the lower lid. This is perhaps due to the comparative narrowness of the cartilage and to the absence of such a correcting influence to eversion as the overhanging supraorbital ridge furnishes to the upper lid.

This form of ectropion is caused by the contraction of the orbicularis, opposed by a globe surface farther forward than its normal position. The lower lid is thus pulled up and back by the action of the muscle, which has the effect of pushing the free edge down and out by the resistance offered by the protruding eye-ball. As a result the action of the marginal fibres is overcome and eversion results. Once established the condition is perpetuated by the action of these same fibres, and by the swelling of the palpebral conjunctiva which results from exposure to the air and from congestion due to interference with the circulation. When both lids are affected and the condition becomes extreme it is called blepharo-paraphymosis.

The commoner causes are chemosis of the conjunctiva, and protrusion of the globe from orbital cellulitis.

The *treatment* of almost every form of ectropion is surgical and, generally, operative.

For the correction of spastic ectropion the most essential thing is to remove the cause, if possible, and to restore to position and mechanically support the lids until the acute trouble has subsided. If the exciting agent be a pronounced chemosis the conjunctiva may be freely incised to promote its reduction. If it be a conjunctivitis it should be treated according to the indications. Whatever the cause proper measures should be taken to correct it and the lids restored to position and held there by strips of adhesive plaster, by bandaging or other means. If the cramp in the muscle has produced an eversion which will not remain reduced, a canthotomy, combined with free severing of the external canthal ligament, is indicated.

A complete and illustrated account of the various operative procedures employed from the earliest times to correct and cure this serious condition is furnished under **Blepharoplasty**, beginning with page 1059, Vol. II of this *Encyclopedia*. A few additional observations are the following:

N. H. Goodnow (*Ophthalmology*, April, 1913) reports the case of a man, aged 47, whose upper lid was destroyed by a caustic paste. Two operations with Thiersch grafts failed to relieve the condition. A Wolfe graft from the arm 4½x1½ inches in size was then transplanted to the freshened area left by freely dissecting loose the lid, with excellent results.

A new principle in ectropion operations, introduced by A. E. Davis (*Jour. Am. Med. Assocn.*, Nov. 18, 1911) consists in shortening the tarsus at the temporal extremity, and then attaching this extremity to the periosteum of the temporal border of the orbit, on a level slightly above the lid commissure if the lower lid is affected, and

below the commissure if the upper lid is in fault. The operation is performed as follows in atonic ectropion:

1. A canthotomy is performed extending to and slightly beyond the orbital margin, exposing the periosteum. 2. The edge of the lid including the cilia is pared off to a slightly greater extent than the piece of tarsus to be removed. 3. The skin and orbicular muscle are separated from the external canthal ligament and the outer end of the tarsus. 4. A triangular piece of the tarsus, more or less extensive according to the extent of the ectropion and lengthening of the lid border, is excised. In case of redundancy of the skin, a triangular piece of skin equal to that of the removed tarsus is removed. 5. A No. 6 silk suture is placed through the outer extremity of the shortened tarsus near the margin, the needle being passed from without inward; then the needle is carried through the periosteum of the rim of the orbit (slightly above the commissure if the lower lid is being operated on, and slightly below if the upper lid is being corrected); the needle is brought out and continued through the skin from the under surface outward. The suture is tied in a single knot. If enough tarsus has not been removed to correct the deformity, the suture is loosened, a little more of the tarsus excised, and the anchoring suture reapplied as before. See the cuts.

The skin wound is closed with fine silk sutures. A dry gauze dressing is put on and a bandage applied. The skin sutures should be removed on the third or fourth day, while the anchoring suture, which can be reached on the skin surface, where it is brought out on purpose, should not be removed until the seventh day.

In cases of excessive atonic ectropion and in many cases of cicatrical ectropion, instead of a piece of skin being cut from the lid itself, a triangular piece may be removed beyond the external canthus, as in the Dieffenbach-Szymanowski operation. Then the undermined skin from the lid is slid over and sewed in position, just as in that operation. It supports the cartilage which has been anchored to the periosteum, and the combined operation is very effective and is advised in marked cases of ectropion.

This principle of anchoring the tarsus to the periosteum applies in many cases of cicatricial ectropion, in fact in most of the cases in which the tarsus itself has not been destroyed. Even when the skin must be replaced by a flap or a skin graft, if the tarsus is first freed and the outer extremity anchored to the periosteum of the rim of the orbit, the result, as a rule, is satisfactory.

Warschawski (*Klin. M. f. Augenh.*, October, 1911, p. 490) highly recommends Straub's modification of Kuhnt's operation of extirpa-



This and the following five figures show the author's operation for ectropion. Canthotomy, the first step.

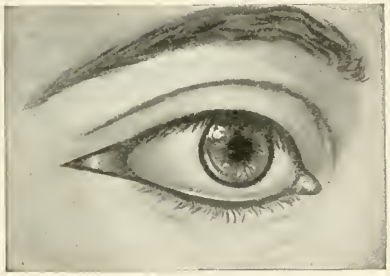

Tarsorrhaphy.

Triangular piece of tarsus removed.



Triangular piece of skin removed.

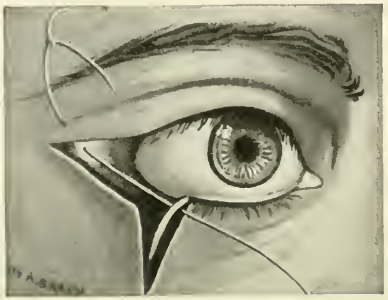

Insertion of anchoring suture.

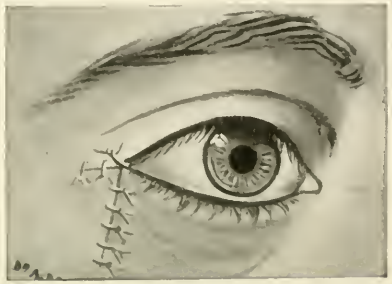

Completed operation.

Davis Operation for Ectropion.

tion of the tarsus for trachomatous ectropion. He has performed the same in 136 cases with satisfactory results. The modification consists in taking up the conjunctiva after exsection of the cartilage, by three double sutures, passing the six needles between the remaining edge of the tarsus and the skin of the lid and so carried through the skin that the threads appear between the cilia. The ends are then united in pairs, in doing which care must be taken that the lid margin turns outward.

For spasmodic ectropion Piccaluga (*Ann. di Ott.*, xl, p. 97, 1912) advises for the lower lid a modification of his proposal for the upper lid. Two incisions are made through the skin of the lower lid, parallel with the ciliary margin. The skin above the upper incision and that below the lower incision are slightly undermined, and these two skin margins are brought together by sutures, burying the intermediate strip of skin. It is claimed that retention of this buried strip makes useful pressure on the tarsal plate.

In a case of marked double ectropion, the result of a nitric acid burn, Ziegler (*Ophth. Rec.*, xxi, p. 207, 1912) had performed on the right eye a Davis plastic operation at the external canthus of each lid and an extensive Hotz-Thiersch transplantation on the upper lid of the same eye. He found that his galvano-cautery puncture of the mucous surface of the lids of the other eye was sufficient to restore them to their normal position.

In a case of extreme cicatrization of the orbit Cramer (*Ophthalmology*, viii, p. 96, 1912) obtained an excellent result by restoring the lower fornix by Kuhnt's operation for ectropion from blepharitis.

L. Kugel (Graefe's *Arch. f. Ophth.*, 84, I, p. 79) found that the excision of the whole posterior plate of the lid, according to Boucheron, leaving a small seam along the inner ciliary border, gave more certain results and in general a much better adaptation of the lid to the eyeball than the method of Kuhnt-Szymanowski. The excision of the posterior plate, however, had one disadvantage, viz., the shortening of the conjunctival sac. As the chief impediment for the normal position of the lid in ectropion lies in the thickened and bent tarsus, Kugel modified this method by confining the excision to the tarsus, so that the conjunctiva is not shortened. He considers this a radical operation for senile ectropion, by which the two obstacles are completely removed which prevent the normal position of the lid in ectropion: elongation of the lid in the direction of the ciliary border and its thickening, while the procedure of Kuhnt-Szymanowski corrects only the elongation of the lid, and the thickening remains.

Ectropion anguli externi. (L.) Eversion of the external angle of either the upper or lower eyelid.

Ectropionater. An instrument devised by Carl Hertzell (*Deutsch. Med. Wochenschr.*, No. 26, 1911) for everting the upper lid. It is intended to do its work thoroughly and to expose completely the upper folds of the conjunctiva. Meantime, with the aid of the unoccupied hand, applications to, and even minor operations upon, the parts are carried on without the necessity of providing an assistant.

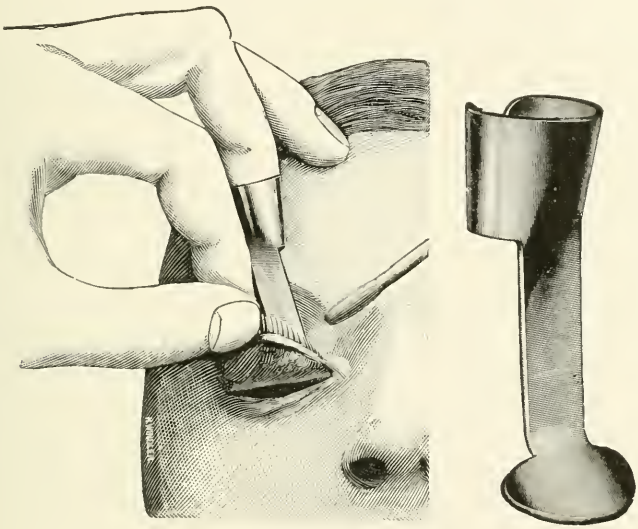

Hertzell's Ectropionator.

Its purpose and method of employment are shown in the accompanying cuts.

Ectropion des Pigmentblattes. (G.) Ectropion of the pigment layer. A condition existing in some cases of glaucoma, in which, by atrophy of the anterior layers of the iris, the retinal pigment layer projects over the pupillary margin.

Ectropionization. Eversion of the upper eyelid and exposure of the conjunctiva to facilitate therapeutic manipulation.

Ectropion luxurians. (L.) See **Ectropion sarcomatosum.**

Ectropion mechanicum. (L.) Ectropion of the eyelids due to the pressure of orbital tumors.

Ectropion, Muscular. A synonym of spastic or acute ectropion; not to be confounded with the almost obsolete term *ectropion musculare* (q. v.).

Ectropion musculare. (L.) Ectropion of the eyelids due to some disturbance of nutrition in the tissue of the orbicular muscle, either atrophy or fatty degeneration.

Ectropion musculare paralyticum. (L.) Ectropion of the lower lid from paralysis of those fibres of the facial nerve which supply the orbicular muscle or of the entire facial nerve.

Ectropion musculare spasmodicum. (L.) Spasmodic or spastic ectropion of the eyelids, usually occurring in purulent and violent phlyctenular conjunctivitis accompanied by blepharospasm. This may occur spontaneously with the lids themselves or come on after the lids have been everted for treatment.

Ectropion of the uvea. Ectropium uveæ. This is the name applied to that congenital condition in which chocolate-brown masses, composed of from one to ten nodules, project from the margin of the pupil on to the margin of the iris. They are composed of uveal pigment, which may become detached and float in the aqueous humor. The affection has been incorrectly called papilloma of the iris. It is common in the horse. In the lower animals, the horse, goat, hyrax, llama, etc., it is known as "soot-balls," or the *umbraculum.*

Two cases of congenital ectropium uveæ have been microscopically examined by Meyer (*Arch. f. Augenh.*, v. 73, p. 16, 1913), who ascribes this state to the formation of new connective tissue in the anterior layers of the iris tissue which produces traction on the pupillary margin. The pigment in the new-formed connective tissue he believes is probably wandering pigment which originated in the ciliary body.

Gutmann's (*La Clin. Opht.*, xvi, p. 557, 1911) first case of ectropium uveæ occurred in an adult affected with amaurosis and cataract; the second in a child of 10, also amaurotic from an injury received at the age of 5. In an eye highly degenerated from inflammation, Lohmann (*Klin. Monatsbl. f. Augenh.*, Jan., p. 75, 1911) observed extensive ectropion of the pigment layer of the iris which was drawn forward over the anterior surface of that structure. Adam's (*Centralbl., f. pkt. Augenh.*, Feb., p. 39, 1911) case of binocular ectropion of the iris is interesting from the symmetrical situation in both eyes (inward and slightly downward); and as showing the mechanism of its occurrence through mechanical dragging.

Finally, Okuse of Tokio (*Klin. Monatsbl. f. Augenheilk.*, April, 1911), has examined a section of iris removed from the eye of a youth presenting congenital ectropion uveæ. The iris tissue was markedly pigmented, especially in its anterior layers. The sphincter, both in its width and thickness, was of enormous dimensions. It was bent sharply towards the pupillary margin, so that the inner end of the

muscle layer reached far forwards. The posterior pigment layer was greatly thickened; at the iris root it was somewhat too thick, but the nearer it approached the pupil the more numerous became the irregular outgrowths, which, however, only increased the thickness towards the pupil. At the pupil margin there was a projecting outgrowth which inclosed an irregular triangular cavity corresponding to the sinus annularis of Szily. Of the three walls the inner one was thick and plump, while the lateral walls reaching near the pupil were thin. The posterior wall was irregular. The surfaces toward the cavity were all smooth. Further forward there was another pigment knob. The cells were cylindrical in type. He considers the condition an anomaly of development consisting of a forward traction of the epidermal layer of the iris. See **Comparative ophthalmology**; as well **Congenital anomalies.**

Ectropion palpebrarum. (L.) Ectropion of the eyelids.

Ectropion sarcomatosum. An obsolete and misleading designation of hypertrophied and fleshy conjunctiva in the succulent forms of trachoma and some other forms of conjunctival infection. The conjunctiva is decidedly hypertrophied, papillomatous, in places covered by thick scabs, and of great vascularity, and has an appearance in places as if the epithelium had become epidermis. It occurs when the inner surface of the lid has been exposed for a long time to the air.

Ectropium. Same as Ectropion (q. v.).

Ectropiumnaht. (G.) The suture or stitch employed in the treatment of ectropion.

Ectropium sarcomatosum. Ectropion associated with marked hypertrophy of the everted conjunctiva. See **Ectropion sarcomatosum.**

Ectropium uveæ. See **Ectropion of the uvea.**

Ecussoné. (F.) Shield-shaped.

Eczema, Ocular relations of. Eczematous disease of the eye and its appendages, in association with eczema of the skin, occurs coincidently with areas of the disease on the general surface. It may with equal frequency, occur preceding or succeeding outbreaks elsewhere, that is, eczema may extend to the lids from other parts of the face, or it may begin in the lids as an extension from a conjunctivitis. Because many conditions are spoken of as eczematous, it is well for us in our study of the ophthalmic aspects of the disease, to apply the term eczema to those affections of the lids, conjunctiva and cornea, which are associated with eczema in other parts of the body, and whose course and prognosis depend upon those of the general disease.

Eczema, according to Stelwagon, may be considered to be a catarrhal inflammation of the skin, of variable chronicity, characterized in the beginning by the appearance of erythema, papules, vesicles or pustules, or a combination of these lesions, with a variable amount of infiltration and thickening, terminating either in discharge with the formation of crusts, or in desquamation, and accompanied by more or less intense itching with a feeling of heat or burning.

Eczema of the ocular structures is hardly ever found in the first weeks of infancy. It is found, however, very frequently during childhood; seldom after puberty, and rarely in advanced age. In adult life it is generally observed during convalescence from the infectious fevers and other severe diseases; and, among the anemic and feeble, during pregnancy and in the puerperium. In the aged, especially in gouty subjects, eczema of the face may occur accompanied by a persistent and intractable, as well as painful, conjunctivitis. It is very frequently present in those suffering from uncorrected ametropia, and in these treatment is often unavailing until the proper spectacles have been worn.

While eczema may be manifested in several members of a family it cannot be said to be hereditary, although persons with familially tender skin may present the disease when subject to contributory and other exciting causes.

In the writer's experience, persons of dark hair and complexion are less likely to be affected with eczema than the blond and more florid, and, among children, girls seem to have been affected more than boys, yet among adults, men have been affected more commonly than women.

Eczema can hardly be said to be contagious, at least in the light of present-day knowledge. So far, a direct, specific cause is not known, yet as facts accumulate the future may disclose it to be micro-organismal.

Eczema of the lids is either acute or chronic. When it is chronic it is developed either from an acute eczema, or it has been chronic from the start. It may be confined to the lids alone, or it may be part of an eczema distributed over the surface of the body, especially on the face and scalp. It is rarely primary in the ocular structures.

Acute eczema is often caused by the maceration and softening of the epidermis brought about by the application of external irritants, such as the irritation produced by the prolonged bandaging of inflamed eyes; the improper use of poultices, adhesive plasters, etc.; the application of mercurial salves; or the prolonged use of solu-

tions of atropia. In these cases there may be an extensive erythema which at the end of a few days is converted into eczema.

Eczema of the lids occurs both in children and adults. It appears often in the erythematous form, or but rarely in the vesicular, and it may become squamous or scaly, papular and pustular. It may exist alone, or be accompanied by, and be secondary to, disease of the conjunctiva, in which case it becomes a part of the well-known "conjunctivitis eczematosa," when it is usually associated with "the scrofulous diathesis." In this last condition very serious complications may be present, therefore as it is so closely allied to phlyctenular disease of the conjunctivo-cornea, reference should be made to the sections on the phlyctenular diseases of the conjunctiva and cornea. Notwithstanding the fact that absolute proof of scrofulous and tubercular diseases is lacking, the positive frequency with which phlyctenular disease of the conjunctiva and cornea is associated with an "attenuated tuberculosis" cannot be denied. Therefore phlyctenular disease and eczematous disease, for the present at least, can be relegated to the position of separate and distinct entities.

At the same time authentic instances are on record in which adults with extensive eczema have had severe inflammation of the conjunctivo-cornea in which the cornea has become implicated even to the point of perforation. This form of disease of the conjunctiva may therefore be considered as analogous to eczema of the skin as found upon the face and upon the edges of the lids themselves. (See **Blepharitis** for a more extensive description of the inflammations of the tarsal borders than can be given here.)

The simultaneous occurrence of eczema of the skin and of the eye denotes, in many cases, a common diathetic origin, while it may be explained in others as having been transferred from a spot on the skin to the eye, or from the eye to the skin.

When the lids alone are affected, it usually depends upon a local cause, as from the constant discharge of tears in conjunctivitis; from obstruction of the lachrymal ducts, ectropion, etc., in which case the lower lid is the one more often attacked.

In children, the constant coryza from which they suffer is to be attributed to an eczematous affection of the nasal mucous membrane; indeed the nasal mucous membrane usually is affected, not only as an accompaniment of disease of the lids and conjunctiva, but the starting point of eczema of the eye may be found in the transference of the disease from the nasal passages.

The most frequent type of infantile eczema is that found associated with gastro-intestinal derangements in otherwise healthy children.

Usually, the lids are not involved, but strumous children may show cracks and fissures about the canthi and at the junction of the skin and mucous surfaces. Involvement of the glands of the lid borders may give rise to seborrhea. The fornix and palpebral conjunctiva are rarely, if ever, attacked by eczema, though there may be an intractable catarrh, a true eczematous blepharitis. (See **Blepharitis.**)

In adults, eczema of the lids usually is of the erythematous type, constituting the "hyperemia of the ciliary border." The disease is usually marked by remissions, with redness and soreness of the borders, with the formation of crusts, pustules and ulcers at the roots of the lashes. The disease is chronic, yet it may not seriously interfere with the nutrition and growth of the eyelashes. Many of these subjects are the victims of uncorrected ametropia.

In others, there may be thickening and redness of the lid borders with matting of the cilia together into tufts embedded in thick, yellow crusts underneath which may be found shallow ulcers. In this form, the hair follicles are affected, and the hair bulbs swollen and thickened. There is usually, in such cases, disease in the lachrymal passages, with eczema of the nostrils and patches of it in the eyebrows and on the scalp.

The pustular is the more severe type and may involve all four lid borders. Crusts may be found about the follicles covering over bleeding ulcers, burrowing into and seriously interfering with the nutrition of the tarsus. Usually the lashes become distorted, when they may drop out, the edges of the lids hard, rounded and everted, and the lachrymal punctum closed and displaced, so that a flow of tears annoys the patient.

Marked edema may accompany acute eczema of the lids, and for the first few days it may be difficult to distinguish it from erysipelas, and for as long as the skin is red and swollen the disease looks like erysipelas. In erysipelas, however, the skin is infiltrated in its entire depth so that the skin is manifestly thicker and firmer than it is in eczema.

The primary principles of treatment consist in both local and general measures. The strictest bodily cleanliness must be maintained, the diet and sleep regulated, and all psychic depressants removed. Attention should be given to the naso-pharynx, the lids should be cleansed of the scales, and then protected by bland salves and dusting powders.

Ophthalmic eczema may give rise to a conjunctivitis which may vary from a simple catarrh due to the entrance of irritating and decomposed secretion into the conjunctival sacs, to one severe enough

to take on the forms of a purulent conjunctivitis. Notwithstanding this, in severe eczema of the face, integument of the scalp and eyelids, the conjunctiva may be completely unaffected, or at most only slightly reddened. Conversely the overflow of the lachrymal secretions may so macerate the integument of the lids and face as to set up an intractable eczematous eruption.

Eczematous conjunctivitis is characterized by the efflorescence of more or less numerous eminences at the limbus, red in color, about the size of a millet-seed. In time these eminences break down, by the softening and maceration of the surface, and, later, through the process of ulceration entirely disappear, being replaced by more or less thickened epithelium. During the evolution there is localized hyperemia while the rest of the conjunctiva is free from congestion. The larger nodules may persist for a long time, in which case when the inflammation is great, the tarsal conjunctiva is affected and participates in the invasion. The efflorescences may be large, but few in number, or there may be only a single one. When small, they are more numerous, and then they may be scattered over the conjunctiva and cornea and the hyperemia about them so great as to give the eruption an appearance of a more diffuse inflammation.

The nodules may remain upon the bulbar conjunctiva or extend on to the cornea. Marginal ulcers of the cornea may form and later perforate with the subsequent incarceration of the iris in the scar, and displacement of the pupil. Usually, however, the cornea is affected in the superficial layers only, and when the nodules are small they may disappear by resorption in a few days, to be followed by scarcely any opacity; on the other hand, when the inflammation is greater, the exudation spreads, and extends to the deeper layers so that ulceration occurs followed by perforation. The healing of such ulcerations is always succeeded by permanent opacity. In certain cases, equally serious so far as searring of the cornea is concerned, the ulcer spreads without penetrating very deeply; its progress can be noted by the manner of its creeping over the surface. The course of such an erosion is chronic. Marked pannus arises, the obliterated vessels of which remain throughout life.

The infiltrate may lie in the deeper layers and there produce extensive destruction, though mild cases undergo resorption and are followed by but little damage. A not very vascular pannus may form on the surface of the cornea. Such a pannus is usually so thin that it suddenly fades and disappears. It may occupy any sector of the cornea, which distinguishes it from the pannus of trachoma, which is invariably found on the upper part of the cornea.

Conjunctivitis eczematosa is accompanied by profuse lachrymation. The discharge is thin, and the lids are not, as a rule, stuck together as in catarrhal conjunctivitis. Intense photophobia and violent blepharospasm, usually out of all proportion to the severity of the lesions, are invariably present.

At first one eye is affected, but as the violence abates in it the other eye becomes involved, and as the second eye improves the first eye is again invaded, and so on for weeks, months or even years. The disease commonly begins in childhood, while the attacks may recur and recur until late in puberty. It may affect adults at critical periods in their life-history: women may be affected during pregnancy, and again at the menopause.

A single efflorescence may speedily fade without any harmful results, but because of the great likelihood of recurrences, the disease is one of the most serious of eye diseases, especially when the cornea is affected. The numerous maculations following the healing interfere with the sight and favor the development of myopia and of squint. In addition, because of the length of the course of the disease, the development of the mental and physical health of the child is interfered with.

From the constant flow of tears the lid borders become inflamed, and eczema of the lids and cheeks is a frequent, if not a common, accompaniment, with excoriations at the angles of the lids. Ectropion and blepharophimosis may follow later on.

Eczematous disease of the conjunctiva and cornea often follows measles and scarlatina, and is usually accompanied by imperfect intestinal digestion and the presence of intestinal parasites. Usually the teeth are carious, and invariably there are adenoids and other diseases of the naso-pharynx.

It is difficult to define the underlying dyscrasia upon which this ocular disease is based. Eczema, as has been pointed out, is conceded by dermatologists to be a catarrhal inflammation set up by various external and internal causes in an inherently weak and debilitated skin. Microbic and parasitic organisms, or their products, may be exciting causes, together with the effects of the chemic, toxic and other externally irritant substances which may take part in the reaction exciting to inflammation, yet as no specific micro-organism has so far been isolated, many observers are inclined to the belief that it cannot be microbic in origin. And it cannot be classed as a trophoneurosis, although nerve changes have been noted, yet they are not primary; the itching, so persistently a symptom, is without doubt dependent upon secondary changes in the nerve twigs. The rete and papillary

layers are involved, while in severe and chronic cases, the corium and subcutaneous tissues may be invaded. The process is characterized by hyperemia and exudation, accompanied by dilatation of the vessels and proliferation of the epithelium and connective tissue cells. The crusts on the surface, which are usually stained with blood and pus, are formed by the drying of the exuded serum mingled with the fluid from the degenerated cells. On the conjunctival surface the nodule is formed by an accumulation of leucocytes beneath the epithelium. This fluid is at first sterile, but later, when the surface has been macerated and ulceration follows, it may become infected by any micro-organism likely to be present. There is always more or less hyperemia of the conjunctiva, although it never becomes general but is always focused towards the nodule. The ulceration may heal easily even in the cornea.

It is not quite exact to say that eczema has its origin in the scrofulous diathesis, since we are inclined to consider scrofula as a synonym of tuberculosis of glandular and osseous structures, neither can we claim it to be tubercular when no tubercle bacilli are found in the unruptured efflorescences. Yet it is impossible to separate these considerations from our minds when we are confronted by an individual whose ocular disease presents the forms outlined here. Of one thing we may be certain, in the great majority of cases, namely, that at sometime more or less remote, if not immediately present, there has been an eruption of eczema on the lids or face, and that naso-pharyngeal symptoms are invariably an accompaniment, and that they are dependent upon lesions in the mucous membrane comparable to those seen on the skin. We are therefore justified in returning to Horner's view that such symptoms are indeed manifestations of eczema.

Occasionally difficulties arise in the diagnosis of eczematous conjunctivitis, the distinctive sign of which is the focal character of the efflorescence and its localization on the cornea and in the region of the limbus. Herpes of the conjunctiva may simulate a phlyctenule, but herpetic vesicles are usually clustered some distance from the limbus; they are transparent and soon fade, accompanied by but few if any marked symptoms. The elevations of spring catarrh are larger than the elevations of phlyctenules and spring catarrh is never accompanied by ulceration. Trachomatous conjunctivitis involves the lids and retrotarsal folds as well as the globe, and it rarely invades the limbus.

From the foregoing it would seem that eczematous conjunctivitis is largely the local expression of a systematic disturbance. The treat-

ment of any case therefore requires a search for the cause of the general affection, which affection must be removed if possible. At the same time measures should be adopted for the relief of the ocular symptoms and the two courses must be maintained for many weeks. Errors of diet must be corrected; starchy foods and sugar must be excluded from the dietary. The meals should be regulated, and all digestive derangements eliminated. Intestinal worms should be dislodged. A clean skin is as imperative as fresh air, and life must be largely spent out of doors. The internal uses of calomel; quinine and iron (a valuable preparation is formed by the suspension of gr. xxx. of the dried sulphate in an ounce of the tincture of the chlorid, of which twenty drops should be taken in milk or water at meals).

Locally atropin is indicated; the irritation can be lessened by cocain or holocain, and by the use of fresh solutions. Calomel may be dusted on the affected area, and the daily application of the yellow oxide of mercury may be of equal service. Sluggish healing may be excited to greater activity by applications of glycerine suspensions of sulphate of copper. The naso-pharynx, the skin, and the glandular lesions must be given full attention, and as soon as possible errors of refraction should be adequately corrected.—(B. C.)

Eczematous conjunctivitis. Conjunctivitis with lesions resembling those of eczema, or it may be due to an extension of eczema to the eye.

Eczematous keratitis. See **Keratitis fascicularis.**

Edema. A swelling due to an effusion (commonly serous) into the connective tissue. See, also, **Œdema.**

Edema conjunctivæ. Œdema of the conjunctiva. Chemosis of the conjunctiva. This condition occurs when the areolar tissue of the conjunctiva is distended by serous exudation. It is generally a symptom of some other disease—for example, acute conjunctivitis, choroiditis, iritis, sinusitis, or orbital cellulitis. According to de Schweinitz (*Diseases of the Eye*, p. 306) *angioneurotic edema* of the conjunctiva, with swelling and hyperemia, may appear without any apparent cause and with marked suddenness. In paralysis of the external straight muscles the overlying conjunctiva is often decidedly edematous, and this may be an early symptom of the condition. Chemosis of the conjunctiva following the use of iodid of potassium has been reported by the author, and it may succeed a general outbreak of urticaria. In the *treatment* of this condition, when it is excessive, the swollen tissues may be scarified and bathed with an astringent collyrium.

Edema fugax. A temporary edema, probably due to atmospheric changes, occurring in the face, eyelids, and neck of (especially) chlorotic patients.

Edema of the cornea. PRESSURE OPACITY OF THE CORNEA. This condition is usually secondary to and the result of increased intraocular tension, but it sometimes appears in connection with several other diseases. This uniform condition of the cornea is most pronounced at the center and chiefly involves the epithelial layer which, upon close inspection, is seen to be uneven. In advanced cases, minute vesicles or blebs may appear on the cornea. When due to glaucoma, it appears most frequently in the inflammatory form. The opacity is diffuse, dull-gray or smoky in appearance. See **Cornea, Pressure opacity of the.**

Edema of the eyelids. PALPEBRAL EDEMA. ŒDEMA OF THE LIDS. This symptom is generally associated with *injury to the head or local affections of the lids* themselves, such as styes, bites from insects, burns, infective conjunctivitis, etc., or it may be important evidence of a diseased condition of the kidneys, heart or general vascular system.

Treatment should be directed to the cause while, locally, benefit is derived from the application of *evaporating lotions and soothing collyria.* For instance, Webster Fox (*Text-book,* page 551) advises the following prescription as a frequent application:

℞

Liquor. plumbi subacetatis dil.,	
Tincturæ opii,	7.39 (fl. ʒij)
Tincturæ belladonnæ āā,	5.53 (fl. ʒjss)
Tincturæ arnicæ,	30.00 (fl. ℥j)
Aquæ camphoræ,	40.00 (fl. ℥iss)
Aquæ dest.,	120.00 c.c. (fl. ℥iv)

Relapsing transient edema of the eyelids has been frequently observed since attention was called to it about fifteen years ago. Various explanations, none very convincing, have been advanced by different writers. Brunetière reports several cases and comes to the following conclusions: The expression essential or idiopathic edema of the lids is an improper one, which should be dropped as it does not indicate a definite condition. There are various forms of acute edema of the lids, just as there are different varieties of conjunctivitis and iritis. Of the numerous causes invoked to account for the edema two have been particularly insisted upon: arthritic and hysterical. Brunetière believes that while both arthritism and neuropathies are frequently present, they are of but secondary importance as predisposing causes. The exciting cause he believes to be toxic; in some cases exogenous, alimentary or medicamentous; in others and more numerous, auto-intoxication from gastro-intestinal disturbance.

Lazareff observed a young girl affected with spasmodic paralysis of syphilitic origin who suddenly became affected with a spongy edema of the left upper lid. The upper tarsus was thickened and the lid swollen, red and tense. Specific tarsitis was diagnosed and six days of treatment with mercury brought about a cure. A week later the edema returned and this time in both lids; an induration, the size of an almond, adherent neither to the skin nor the tarsus, appeared over the tarso-orbital ligament. The same treatment as before brought about a cure in fifteen days. Two weeks later there was a relapse with considerable extension of the edema over the forehead, nose, cheeks, etc. A series of mobile enlargements were present in the distended cellular tissue of the invaded region. A strange comcomitant symptom was the fact that the enlargements migrated from one point to another, disappeared and reappeared. After an exhaustive discussion of the pathogeny of the affection and of analogous cases in literature, Lazareff concludes that the symptoms depended upon a disturbance in the secretion and circulation, due probably to central and peripheral nervous lesions. The patient, in fact, was affected with active cerebral syphilis.

Wilson obtained satisfactory results in a case of swollen lid following an attack of erysipelas, by carrying two silk threads subcutaneously parallel to the margin of the lower lid, one near the lid margin, the other near the margin of the orbit; and then from below the outer canthus downward in the cheek for an inch or more.

Elgood reports a small epidemic of eight cases of edema of the lids with pyrexia. The edema was quite marked and at first attracted attention, but subsided within two or three days. Fever continued for several days to three weeks and there was gastro-intestinal disturbance suggesting typhoid fever. But the Widal test proved negative.

Edema retinæ. This term is a synonym of Commotio retinæ. See Vol. IV, p. 2517, of this *Encyclopedia*.

Edema, Solid. This is one of the forms of elephantiasis (q. v.).

Edema theory of glaucoma. See **Glaucoma**.

Edessenum. (L.) A collyrium, ascribed to Ætius, made by mixing a sufficient quantity of water with 1 part each of gum tragacanth, gum arabic, starch, and sarcocolla, 2 parts of opium, 4 parts of white lead, and 8 parts of cadmium sulphate.

Edge of a prism. The thin edge or apex of a prism represents the angle made by the refracting surfaces, being opposed to the thickest part or base.

Edinger's fibres. These are visual, cortical fibres of the optic tract, found in amphibia.

Edocéphale. EDOCEPHALUS. HEDOCEPHALUS. A term employed by Geoffroy St.-Hiliare to describe a monster having the two ears near together (or united under the head), atrophied jaws, no mouth, a single median eye, and above the eye a nasal tube resembling a penis.

Edridge-Green's color perception lamp. See Vol. IV, p. 2410, of this *Encyclopedia.*



Edridge-Green's Color Perception Lamp.

Edridge-Green's color perception spectrometer. See Vol. IV, p. 2412, of this *Encyclopedia.*

Edridge-Green's theory of vision and color. A ray of light impinging on the retina liberates the visual purple from the rods and a photograph is formed.

The rods are concerned only with the formation and distribution of the visual purple, not with the conveyance of light impulses to the brain.

The decomposition of the visual purple by light chemically stimulates the ends of the cones (very probably through the electricity which is produced), and a visual impulse is set up which is conveyed through the optic nerve fibres to the brain. If it were possible, in a case in which the spectrum appeared of similar length and brightness to both, for a normal-sighted person and a color-blind one to exchange eyes, the normal-sighted would still see colors properly and the color-blind would still be color-blind. There are cases in which the visual purple is differently constituted and is not sensitive to certain rays at one or both ends of the spectrum. The character of the impulse set up differs according to the wave-length of the light causing it. Therefore in the impulse itself we have the physiological basis of the

sensation of light, and in the quality of the impulse the physiological basis of the sensation of color. The impulse being conveyed along the optic nerve to the brain, stimulates the visual centre, causing a sensation of light, and then passing on to the color-perceiving centre, causes a sensation of color. But though the impulses vary in character according to the wave-length of the light causing them, the color-perceiving centre is not able to discriminate between the character of adjacent impulses, the nerve cells not being sufficiently developed for the purpose. At most, seven distinct colors are seen, while others see in proportion to the development of their color-perceiving centres, only six, five, four, three, two or one. This causes color-blindness, the person seeing only two or three colors instead of the normal six, putting colors together as alike which are seen by the normal-sighted to be different. In the degree of color-blindness just preceding total, only the colors at the extremes of the spectrum are recognized as different, the remainder of the spectrum appearing grey. See, also, **Color-sense and color-blindness.**

Edriophthalmata. A section of higher crustaceans, including the simpler and more primitive forms, in which the eyes are sessile, not stalked.

Education of the blind. This subject has been considered under the various **Blind,** as well as **Blindness,** headings, beginning with p. 1116, Vol. II, of this *Encyclopedia.* The reader is especially directed to consult p. 1116, Vol. II, **Blind, Amusements and recreations of the,** as well as **Institutions and resources of the blind,** not to mention the heading **Blind, Physical education of the,** on p. 1200 of the same volume. See, also, p. 1206, under the general caption, **Blind, The.** An important section is that entitled **Alphabets and literature for the blind,** beginning with p. 249, Vol. I, of this *Encyclopedia.*

The centennial anniversary of the birth of Louis Braille, born Jan. 9, 1809, has attracted especial attention to the subjects of education and occupation for the blind. In his paper on Louis Braille and the intellectual achievements of the blind, Skrainka (*Am. Jour. of Ophth.,* p. 131, 1910), has traced the development within the last one hundred and twenty-five years of the method of reading by touch, and the growth of the literature open to those who have mastered the method of Braille. In the Paris library there are now over 25,000 volumes printed in Braille. Keller claims that the largest collection of books for the blind in America is to be found at Cincinnati, and he mentions three magazines—the *Ziegler Magazine,* the *Milwaukee Medical Review* and the *Christian Record.* It is unfortunate that a modification of the Braille system, which is at best a doubtful improvement, has

been extensively used in this country under the name of "New York Point." The intellectual achievements of the blind have been reviewed by Villey (*Revue des Deux Mondes,* Feb. 1, 1910), himself blind from four and one-half years, and the author of a valuable literary treatise on the essays of Montaigne.

In the better institutions for the education of the blind, Bishop (*Ophthalmology,* p. 71, 1910) finds that although the effort is made to teach each pupil something practical that he can do with his hands, care is taken to preserve such special talents as he may possess. Sommer (*Centralbl. f. Augenh.,* p. 317, 1910), reviewing the professional opportunities for those who have become blind, considers medicine and natural science closed to them, although the blind physician might practise massage or take up special work in the correction of speech defects. He overlooks the possibilities for specializing on diseases of the chest, that has been so strikingly developed for himself by Babcock, of Chicago. In law, philosophy and theology, Sommer finds wider opportunities open to the blind. Fox urges the special fitness of the blind to practise massage as an occupation, on account of their superior development of the sense of touch. He points out that great assistance could be given by the medical profession in opening to them this avenue of employment. Little (*Lancet,* ii, p. 1129, 1910), enters a vigorous protest against the action of a certain railroad, requiring each blind person to sign a special agreement to protect the company from damages for injury, and undertaking to provide for himself a guide for entering and leaving the railway carriage. Instead of increasing the difficulties, Little thinks that special traveling facilities should be afforded the blind, by reduced fares, as has been very commonly the custom in the United States.

Education of the ophthalmologist. See **Pedagogy.**

Eel's blood. The irritant, not to say toxic, effects of this agent have been many times reported. Among them Takashima (*Ophthalmic Year-Book,* p, 106, 1913) has carried out experiments to determine the effect of eels' blood on the conjunctiva of animals, and concludes that by simple instillation into the conjunctival sac it produces very slight injury to the epithelium or to the subconjunctival tissues. When applied to the conjunctiva where the epithelium has been injured it excites an inflammation which cannot be looked on as harmless. The grade of the inflammation is moreover dependent on the degree of absorption of the toxin.

Pöllot and Rallson have noted the occurrence of acute conjunctivitis after contact with the blood of an eel. In two cases observed by Steindorff (*Ophthalmic Review,* p. 319, October, 1911) in which the con-

tamination of the conjunctiva occurred when an eel was being cut up, there was very severe reaction. In one of the cases this set in instantly, in the other after the lapse of a few minutes. After a few days all acute symptoms passed off, though in one of the cases there was for a time a fine corneal haze: in one, accommodative asthenopia remained for a considerable time. Steindorff experimented with cats, rabbits, and guinea-pigs, endeavoring to produce reaction by introducing eel's blood, but without result. See, also, **Toxic amblyopia.**

Eel, The eye of the. THE COMMON EEL. ANGUILLA ROSTRATA. Relatively little is known about the eyes of that important animal the eel. A recent and authentic account of this interesting fish is given in the *Geographic Magazine* for October, 1913. According to this authority the habits of the eel at the time of spawning are entirely unknown. Whether the eggs are laid in deep water, in intermediate depths, or at the surface is as yet only a matter of surmise. It is established, however, that eggs are deposited outside of the 1,000-meter curve (that is to say, the eggs are never deposited in water less than 1,000 meters deep), and that they hatch at or near the surface, where they are carried by their natural buoyancy.

Just what becomes of the eels after spawning is not known. The conger eel, a strictly marine species, undergoes a general degeneration or jellification of its tissues after the spawning act, and it is supposed that the common eel meets with the same fate.

Larval eels have been collected all the way across the North Atlantic, from 25° to 45° north latitude. Much new material of a very interesting character was obtained in 1910 by Sir John Murray and Dr. Johan Hjort during their notable cruise in the Norwegian government steamer Michael Sars. The larval eels, or *leptocephali*, as they are scientifically known, frequent the surface waters, and may be caught in large, fine meshed tow nets. They possess very feeble swimming powers, and it is evident that their movements are controlled largely by tides and currents. The smallest specimens are found in mid-ocean south of the Azores, which is the spawning ground for the European eel and probably also for the American eel. It is not easy to understand how the American eel, in the course of its metamorphosis, reaches the shores of the United States and Canada, but it is clear that the gulf stream carries the European species to the coasts of western Europe. As the coasts of the continents are approached, the larvæ average larger and larger; none are ever found near land that are as small as all of those taken in the Sargasso sea.

Some eels remain in the lower parts of the streams and move back and forth in the bays and estuaries, and others press on to the head-

waters, often surmounting obstructions that would be impassable for other fish, and remain there until full maturity is attained.

In the fall the eels which have been living in the fresh waters and have attained their full growth undergo peculiar changes. The *eyes* in the males become nearly twice the normal size, and both sexes lose their dirty yellow-green color and become silvery. Such eels migrate downstream, traveling mostly at night, and eventually reach the sea, where all trace of them is lost. Their behavior in the sea, the depths at which they swim, their rate of travel, and whether in scattered bodies or in compact schools, are some of the still obscure phases in the eel's life.

The next evidence of these eels is met with on the high seas, far from land, in the form of their young progeny. The larval eel is such a very different-looking creature from the adult that no person not properly instructed could by any possibility recognize it. It is compressed laterally to the thinness of a visiting card; it has a small head, *large eyes,* formidable, but apparently non-functional, teeth that project forward and laterally; and the body is transparent throughout, the fish being practically invisible except for its glistening black eyes.

The larval eel, known as the *leptocephalus,* undergoes an extraordinary metamorphosis. It remains at sea for about one year, during which time it attains a length of three inches. Its larval state has then reached its climax, and in its subsequent growth for a time the eel actually becomes smaller! There is a gradual change in form from the ribbon-like to the cylindrical, a shortening of the body and of the intestine, and a gradual assumption of the eel-like appearance.

Fresh water has a great attraction for the young eels, and as soon as they reach the coasts, to which they are wafted by currents and winds, they seek fresh-water streams and begin to ascend them. When they first arrive they have little pigment in their skin, but they quickly acquire a brownish color, and by the time they arrive far upstream they have become quite dark.

Efedrina. (It.) Ephedrin.

Effective aperture. WORKING APERTURE. That part of the aperture of the lens actually used to obtain the image.

Effective rays. In *optics,* the rays that are utilized in their passage through a lens whose aperture is the base of a cone of light, or ray-bundle, having its vertex at a point of the object in the *object-space,* or at a conjugate point of the image in the *image-space.* As the degree of perfection of the image depends upon the ray-inclinations to the axis, and on the heights above or below the axis where the rays intersect the lens-surfaces, etc., it is necessary to limit the extent of the

object that is to be reproduced in the image; wherefore, an *aperture-stop* (see Vol. I, p. 533, of this *Encyclopedia*) is used to admit only those bundles of *effective rays* that are actually required to produce the perfected image. See also **Slope-angle, Entrance-pupil** and **Exit-pupil.**—(C. F. P.)

Efferent. Carrying or leading out of; said of nerves, vessels, or ducts which extend from an organ; as, for example, efferent nerves, efferent vessels, etc.

Effleuveation. Treating malignant and other tumors by the high-frequency current. See **Electrocoagulation.**

Egal. (F.) Equal.

Egaré. (F.) Expressing a state of suffering consequent upon an external cause; generally said of the countenance and eyes of the sick.

Egg tester. A simple optical instrument for determining the transparency of eggs.

Egg, The, in ophthalmology. The film or inner membrane of the hen's egg has been employed in operative ophthalmic surgery. For example, Coover and Black advises its use to prevent adhesions following lime burns and other injuries of the conjunctival sac. A fatty oil is also obtained by expression from the yolks of fresh eggs. Its chief ophthalmic use is, abroad, as a popular remedy for the removal of corneal opacities.

Henderson (*New York Med. Jour.*, Feb. 1, p. 261, 1913) relates his own experience of a toxic amblyopia arising from the ingestion of lightly-cooked eggs. The first attack occurred at the age of fourteen years. The symptoms were those of acute migraine with contralateral blindness. Subsequent attacks occurred without blindness. Since the age of twenty-three the attacks have always come on in a definite manner when he was in the best of health. The ocular symptoms were the too bright appearance of objects, followed by an inability to read. Later the migraine would set in. Hard-boiled eggs proved innocuous.

Egout. (F.) A sewer. The drainage or issue of an ulcer.

Egout nasal. (F.) The nasal orifice of the lachrymal duct.

Egypt, History of ophthalmology in. Our earliest account of ancient Egyptian ophthalmology is also our fullest and best. It is found in a document known, from the name of its discoverer as the papyrus Ebers. See **Ebers, Georg Moritz.**

Some of the more important diseases and the remedies therefor, as given in this ancient manuscript, are as follows:

1. For "Blood in the Eyes," which meant, probably, either congestion of the conjunctiva or subconjunctival ecchymosis (hyphema) were used verdigris, antimony, and powdered wood.

2. For "Tear-Eyes" (epiphora) were employed incense, boiled papyrus, acacia gum, antimony and water.

3. For "Dimness of Sight" (cataract, corneal opacities, and possibly other conditions) the Egyptians recommended in the early stages, swamp water; later, compresses of antimony and honey. A favorite prescription was honey mixed with excrement from a child.

4. For "Blear Eyes" (trachoma) equal parts of verdigris and onions were mixed together and laid on. Various sorts of eye-water (collyria) were also employed. Trachoma was then, as now, in Egypt, a terrible and wide-spread curse.

5. For "Pain in the Eye" an ointment was employed consisting of antimony and charcoal.

6. For "Narrowing of the Pupils" frequent poulticing with a solution of saltpeter and ebony-shavings.

7. For "Stone in the Eye" (by which is meant, no doubt, concretions in the meibomian glands) antimony, vermillion (red lead) plumbagin and natron.

8. For "The White-Becoming" (leucoma and, possibly, cataract) the brain of a tortoise mixed with honey.

9. For "Turning of the Eyes" (strabismus) equal parts of tortoise brain rubbed up with oriental spices.

10. For "Bade" (chemosis) genuine antimony, washed in the milk of a woman who has borne a male child.

11. For "Pus in the Eye," of clay, honey and ricinus leaves, each one ro. (A "ro"=0.0141 liter.)

12. For "The Mounting of Water in the Eye" (probably cataract) genuine lapis lazuli, verdigris, crocodile dung, frankincense and milk. "Mix these, and apply them to the eyes."

13. For "The Driving Away of a Swelling on the Nose" (dacryocystitis). Antimony, powdered wood, myrrh and dried honey. Rub into the eyes for four days. "Take note of this, for it is surely the right application."

14. For "The Curving of Hairs into the Eye" (trichiasis, distichiasis, entropion) myrrh, lizard-blood and bat-blood. "Pull out the hairs first; then apply this to the eye, in order that it may be rendered sound."

In the period covered by the papyrus Ebers, according to the testimony of that document itself, there were only three kinds of doctors—doctors properly so-called, surgeons, and magicians. There were no specialists at all. In the time of Herodotus, however (5th century B. C.), matters had, in this respect at least, been very greatly altered. Thus, Herodotus himself, "The art of medicine is thus divided among

them: each physician applies himself to one disease only, and not more. All places abound in physicians; some physicians are for the eyes, others for the head, others for the teeth, others for the parts about the belly, and others for internal disorders."—*Euterpe,* 84.

Herodotus has also preserved an interesting anecdote concerning the greatest two ophthalmologists of Egypt in the century preceding his own—Pentammon and Nebenchari. Cambyses, son of Cyrus, king of Persia, finding that his mother, Kassandane, was blind, sent to Amasis, king of Egypt, beseeching him to dispatch to her aid the greatest of Egyptian oculists, whoever that might be. Amasis sent to her Nebenchari.

This oculist, on arriving in Persia, found his royal patient afflicted with senile cataract. For some reason, however, he hesitated to perform an operation, until one day, happening to hear that his king, Amasis, had also gone blind from the same affection, and that he had been successfully operated on by Nebenchari's great rival, Pentammon, the timorous Nebenchari took heart, operated (by couching) and restored to Kassandane her sight. This procedure, then called "cutting the skin that covers the pupil of the eye," is said to have been invented by Nebenchari.

War between Persia and Egypt seems to have grown out of this oculistic incident. At all events, Herodotus (*Thalia,* III, 1) holds the following language: "Against this Amasis, Cambyses, son of Cyrus, made war, leading with him both others, his own subjects, and of the Grecians, Ionians and Aeonians. The cause of the war was this: Cambyses, having sent a herald into Egypt, demanded the daughter of Amasis; and he made this demand at the suggestion of an Egyptian physician, who out of spite served Amasis in this manner, because, having selected him out of all the physicians in Egypt, and torn him from his wife and children, he had sent him as a present to the Persians, when Cyrus, having sent to Amasis, required of him the best oculist in Egypt. The Egyptian, therefore, having this spite against him, urged on Cambyses by his suggestions, bidding him demand the daughter of Amasis, in order that if he should comply he might be grieved, or, if he refused, he might incur the hatred of Cambyses. But Amasis, dreading the power of the Persians, and being alarmed, knew not whether to give or to deny; for he was well aware that Cambyses purposed to take her, not as his wife, but his mistress. Having considered these things, he did as follows: There was a daughter of Apries, the former king, very tall and beautiful, the only survivor of the family; her name was Nitetis. This damsel, Amasis, having adorned with cloth of gold, sent to Persia as his own daughter. After a time, when

Cambyses saluted her, addressing her by her father's name, the damsel said to him, 'O King, you do not perceive that you have been imposed upon by Amasis, who, having dressed me in rich attire, sent me to you, presenting me as his own daughter; whereas, in truth, I am the daughter of Apries, whom he, though he was his own master, put to death after he had incited the Egyptians to revolt.' These words in this accusation induced Cambyses, the son of Cyrus, being greatly enraged, to invade Egypt."

After the founding of Alexandria, the ophthalmology of Egypt was, as to that city and possibly as to other strongly Hellenizing portions of the land, precisely that of Greece. During the Roman occupation, it became, of course, Greco-Roman. Outside the more strongly Hellenizing portions of the land, however, the ancient indigenous ophthalmic science persisted, and, no doubt, remained about the same as we have seen it in the super-ancient papyrus Ebers.

Then came the Mohammedan invasion and, in 640 A. D., the burning of the Alexandrian library by the Mohammedan general, Amrou. This put an end, for the time at least, to Greco-Roman medicine in Egypt. When, however, the fierce Arabians had come to know the value of Greco-Roman learning, and had as eagerly mastered it as, before, they had been intent on stamping it out of existence, they then not merely restored the learning of the ancients (ophthalmology, of course, included) to the portions of Egypt in which that learning had formerly existed, but they gave it absolute dominion throughout the whole of the country; the native Egyptian medicine was no more.

Of all the Mohammedan writers on the eye, the greatest by far was Ali ben Isa *(q. v.)* whose "Memorandum-Book for Oculists" (*circa* A. D. 1040) remained, in Egypt, the greatest authority on the eye until the last few decades—during which, as a matter of course, Mohammedan science has been supplanted to a very great extent by the science of modern Europe.

The war against ophthalmia—that ancient curse of Egypt—has, since 1903, been carried on with a very great deal of vigor and with considerable success. In that year, "A sum of £E41,000 was placed at the disposal of Lord Cromer, then British Agent in Egypt, for the relief of sufferers from eye diseases by the liberality of Lord Cassel." Traveling hospitals, consisting of a number of Indian tents, have, since that date, been able to visit most of the larger towns in Egypt. Under the efficient management of Dr. A. F. MacCallan, enormous good has been accomplished. However, the task is almost endless, for, according to an article by MacCallan himself, "out of 43,668 patients examined

during 1912, 6,939 persons were found to be blind in one or both eyes —that is, nearly 16 per cent.''—(T. H. S.)

Egyptian ophthalmia. A form of conjunctivitis, nearly always trachoma *(q. v.)*, characterized by the unrestricted formation of follicles, producing permanent granular masses.

Ehrlich's theory. An immunity theory. See Vol. II, p. 857, of this *Encyclopedia.*

Eibe. (G.) Ovum.

Eidoptometry. (Obs.) The science and art, or the act, of measuring visual acuity. The word is illogically formed (literally, it means *measurement of the special eye,* or *special eye measuring*) and, therefore, its use had better be avoided.

Eidoscope. A form of kaleidoscope.

Eierschwamm. (G.) Poisonous mushroom.

Eierstock. (G.) Ovary.

Eigelbrändchen. (G.) Chalazion.

Eilamides. (L.) The meninges of the brain.

Eiloid. Having a coil-like structure (said of certain tumors).

Einathmung. (G.) Inhalation. Inspiration.

Einäugig. (G.) Monophthalmic. One-eyed. Cyclopic.

Einäugige Binde. (G.) A bandage for one eye.

Einäugigkeit. (G.) Cyclopia.

Einbettung. (G.) EINBETTEN. The process of imbedding a microscopic object.

Einfach. (G.) Simple.

Einfache Farben. (G.) Simple colors.

Einfächerig. (G.) Unilocular.

Einfall. (G.) Incidence.

Einfallsebene. (G.) The plane of incidence.

Einfallsloth. (G.) The perpendicular to a reflecting or refracting surface at the point of incidence.

Einfallspunkt. (G.) The point at which an incident ray strikes a reflecting or refracting surface.

Einfallsstrahl. (G.) Incident ray.

Einfallswinkel. (G.) Angle of incidence.

Einfettung. (G.) Inunction.

Einführung. (G.) Insertion. Introduction.

Eingang. (G.) Entrance.

Eingangsöffnung. (G.) An aperture of entrance. Opening.

Eingebogene Augenwimpern. (G.) Incurved lashes, as in trichiasis or entropion.

Eingefallen. (G.) Sunken; hollow (said of the cheek or eyes).

Eingekeilt. (G.) Impacted.
Eingekrümmt. (G.) Bent inward.
Eingeschlossen. (G.) Incarcerated; encysted.
Eingewebt. (G.) Interwoven; interlaced.
Eingriff. (G.) Any surgical procedure.
Einheit. (G.) Unity; a unit.
Einkehrung der Augenlider. (G.) Inversion of the eyelids. Entropion.
Einklemmen. (G.) The process of inclosing a microscopic specimen for purposes of section between two pieces of tissue which can be cut readily, such as cork, elderpith, etc.
Einleitung. (G.) Introduction.
Einpflanzung. (G.) An implantation, a setting in, as in plastic operations.
Einpolig. (G.) Unipolar.
Einreibung. (G.) Inunction. Embrocation.
Einsauger. (G.) A body that absorbs light and heat.
Einschielen. (G.) Convergent strabismus.
Einschlag. (G.) Injury; wound.
Einschlagen. (G.) To dress, envelop or bandage; also to strike (said of lightning).
Einschmierkur. (G.) A course of treatment by inunction.
Einschneiden. (G.) To incise; also an incision.
Einsehen. (G.) That state of the faculty of sight in which only one image is perceived of an object looked at with both eyes.
Einspritzen. (G.) To inject; to syringe.
Einstellen. (G.) To focus.
Einstell-loupe. (G.) Focusing magnifier.
Einstellschraube. (G.) Focusing screw.
Einstich. (G.) Puncture.
Eintauchung. (G.) Immersion.
Eintrufelung. (G.) Instillation; dropping.
Eintröpfelung. (G.) Instillation. Dropping (into the eye).
Einwärts. (G.) Inward.
Einwärtszieher. (G.) An adductor muscle.
Einwirkung. (G.) Action; influence.
Einzelsehen. (G.) Simple vision.
Eis. (G.) Ice.
Eischicht. (G.) An albuminous layer.
Eisen. (G.) Iron.
Eisenartig. (G.) Ferruginous; chalybeate.
Eisenbahn. (G.) A railway.
Eisenbahnbedienstete. (G.) Railway employes.

Eisenbarth, Joh. Andreas. A Bavarian quack. Born in Bavaria in 1661, he became an itinerant oculist, rupture specialist, cutter for stone, and hare-lip operator. His patients were many, but seem not to have fared well. Eisenbarth died in 1727.—(T. H. S.)

Eisenchlorür. (G.) Ferrous chloride.

Eisenhut. (G.) A vulgar name for aconite.

Eisenjodür. (G.) Ferrous iodide.

Eisenmennige. The aniline dye known as Berlin red.

Eisenmittel. (G.) A remedy containing iron.

Eisensplitter. (G.) Fragments of iron.

Eisensplitterverletzungen. (G.) Injuries from iron fragments.

Eisensteinstaub. (G.) Iron rust.

Eisenvitriol. (G.) Ferrous sulphate.

Eisumschlag. (G.) A compress wet with ice-water; also a bag containing pounded ice, to be applied to the eye or other parts of the body.

Eiter. (G.) Pus.

Eiteransammlung. (G.) A collection of pus.

Eiterartig. (G.) Purulent, pus-like.

Eiterausfluss. (G.) A discharge of pus.

Eiterbeule. (G.) Abscess; boil; pustule.

Eiterfluss. (G.) Flow or excretion of pus.

Eitergeschwür. (G.) A purulent or suppurating ulcer.

Eiterkokken. (G.) Pyogenic cocci.

Eiterkörperchen. (G.) A pus-corpuscle.

Eiterkügelchen. (G.) A pus-corpuscle.

Eiterpfropf. (G.) The core of a boil or other suppurating area.

Eiterschale. (G.) A pus-basin.

Eiterstaar. (G.) A collection of pus in the field of the pupil; formerly supposed to be an abscess in the crystalline lens. The so-called "putrid" cataract.

Eiterung. (G.) Suppuration.

Eiterverbreitung. (G.) Metastatic suppuration; purulent metastasis.

Eiterzelle. (G.) A pus-corpuscle.

Eitrige Bindehautentzündung. (G.) Purulent conjunctivitis.

Eitrige Hornhautentzündung. (G.) Purulent keratitis.

Eitrige Thränenschlauchentzündung. (G.) Purulent dacryocystitis.

Eiweiss. (G.) The white of egg. Egg albumen.

Eiweissgifte. (G.) Albuminoid poisons.

Ekel. (G.) Nausea.

Ekl, Max August. A German ophthalmologist, concerning whom nothing at all is known, except that he wrote "Von der Thränensackfistel" (Munich, 1852).—(T. H. S.)

Ektropioniren der Lider. (G.) Eversion of the lids.

Elancement. (F.) Severe lancinating pain; a neuralgia.

Elaphia. (L.) A complaint observed chiefly in stags, but also seen in horses: characterized by general rigidity, cardiac excitement, and rolling of the eyes.

Elastic fibres. See **Elastic tissue.**

Elastic tissue. ELASTIC FIBRES. This tissue plays an important role in various normal and abnormal constituents of the ocular apparatus, and its diseases. It is only necessary to mention a few of these, such as the conjunctiva, cornea, sclerotic, lens, pinguecula, pterygium, etc.

Elaterium. This agent, the sediment of the juice of the squirting cucumber *(Ecballium elaterium)*, is well known as a drastic purgative. Its relations to ophthalmology are confined to one or two observations concerning the effects of the fresh juice, which had found its way into the eye, generally by "squirting." Moissonnier (*Clin. Ophtal.*, p. 631, 1901) gives an account of one of these accidents. Almost the same symptoms produced in this instance were also found by Gabriélides (*Arch. d'Ophtalm.*, p. 631, 1909) in another case in which the juice set up a temporary but well marked edema of the lids, with chemosis and small hemorrhages. In all probability it was the poisonous and highly irritant active principle, elaterin, that produced the local inflammation.

Elaterometer. ELATROMETER. A pressure gauge.

Elatine. (F.) Aqueous emulsion of tar.

Elayle. (F.) Ethylene.

Elderflower water. See **Sambucus.**

Electifs. (F.) In ancient medicine, specific remedies.

Elective filtration. Filtering of the serum of the blood through organic membranes, due to the fact that the power of adhesion of the capillary cavities of organic membranes to adjacent substances is greater for material charged with saline matter than for albuminoid substances mixed with the water or salts in the serum.—(Foster.)

Electrargol. According to the report (*Journ. A. M. A.*, June 6, 1914) of the Council on Pharmacy and Chemistry of the American Medical Association this drug is a colloidal solution of silver containing a small percentage of sodium arabate. It contains silver equivalent to 0.25 per cent. metallic silver (Ag).

Electrargol is claimed to be antiseptic and germicidal and non-irritating even when injected hypodermically or intravenously.

It is claimed to be useful in febrile diseases, even those which are not of a septic character. It is also said to be useful when applied

locally in inflammatory conditions, and it has been used in surgical cases.

Subcutaneously, intramuscularly or intravenously it is used in doses of from 5 to 25 cc. after being made isotonic by the addition of sodium chlorid solution.

Supplied in the form of ampules, each containing electrargol 5.0 cc. (75 minims) in the non-isotonized condition.

The package contains a solution with directions for the extemporaneous isotonization of the preparation.

Supplied for surgical use in bottles each containing electrargol 50 cc. (1.7 fluidounces) isotonized by sodium sulphate.

Electrargol is prepared by passing an electric current in the form of an arc between two silver electrodes in distilled water. It is made stable by the addition of sodium arabate, which is prepared by acting on acacia (gum arabic) with hydrochloric acid, precipitating the resulting arabic acid with alcohol and neutralizing the arabic acid with sodium carbonate.

Electrargol is an odorless, tasteless liquid, appearing transparent and reddish brown by transmitted light and opaque and gray by reflected light. The addition of potassium cyanide solution or of strong nitric acid yields a colorless transparent solution. The nitric acid solution yields a white turbidity on the addition of chlorids.

Medeiros (*La Clin. Opht.*, p. 600, 1910) claims that electrargol has a place in ocular therapeutics. He finds it a bactericide which penetrates the tissues, its solutions are stable and it is "absolutely innocuous." By its use Medeiros has observed benefit, or hopes for it, in a large number of ocular inflammations.

Tristaino (*Arch. di Ottal.*, Vol. 21, p. 137, 1913) writes on his experience in the use of the drug, both by injection and by instillation, in the Palermo clinic. He concludes that when used as a preventive electrargol allows the undertaking of operative procedures which would otherwise be unsafe; that it accelerates somewhat the process of wound healing; that in various suppurative and inflammatory processes it has a decided therapeutic efficiency, and that it does not cause pain, either when instilled or by injection, but on the contrary has a sedative effect.

Electr-Hg. A proprietary remedy marketed by *Les Laboratories Clin.* Bruno (*La Clinique Ophtal.*, March, 1913) speaks of its use in ophthalmic therapeutics and describes the product as consisting of an aqueous suspension of ultramicroscopic particles of pure mercury. It is non-toxic in ordinary doses, and easily absorbed, because of its fine division. Observations in six cases fully reported show effectiveness.

The writer never uses salvarsan in eye diseases, because of its known deleterious effect upon the optic nerve. He states that this colloidal preparation may be utilized in any form of syphilis, and it will replace calomel in eye diseases, being less inconvenient and more readily diffusible.

Electric-blindness. See **Electric ophthalmia.**

Electric cataract. Although this subject has already been discussed in Vol. II, p. 1488, of this *Encyclopedia,* it may be added here that a number of recent cases of lenticular opacities have been reported, due apparently to the electric shock or to the intensity of the electric light.

One of these is reported by Ortin (*Archivos de Oftalmologia,* Sept., 1911). Two men on mules, and another on foot, received the shock of a sudden electric discharge as they were passing a pole which supported an electric cable. The first two, with their mules, fell to the ground unconscious. On coming to, vision was at first almost absent, but gradually returned. After this, however, the vision of one of them gradually got worse, and at the end of twenty-five days scarcely amounted to perception of light and dark. The second man experienced less disturbance of vision. Three months later, at examination, the first one showed complete cataract in the left eye; the right eye had some retinal disturbances, with vision 5/10. The second man had a stellar cataract in the left eye, with which his vision was fingers at 0.75 meter; and in the right a small anterior polar cataract had reduced vision to 5/35. Operation on the worse eye of the first patient resulted in vision of 5/15 with lens. Both men were lost sight of soon after this.

Jocqs (*Clin. Ophtal.* xviii, p. 170, 1912) adds one from his own practice. He concludes that the common features of all, or most of such cases, are the late appearance of the lens opacity (from one to many months after the accident), and its appearance as a fine stippling or star-shaped figure in the anterior cortex. In six of the nine cases the cataract was unilateral.

In a case of electric cataract reported by Culbertson (*Amer. Jour. Ophth.,* v. 30, p. 257, 1913), the shock was due to lightning transmitted by the telephone receiver. The patient was a woman of 21 years. The left eye developed an intense iridocyclitis, and seven months later this eye was blind, and the right eye nearly so, from cataract. Mills (*Arch. of Ophth.,* v. 42, p. 395, 1913) reports a case in which the patient, a man of 28 years, received a current of 11,000 volts, which passed from head to foot. He was unconscious for seven hours, but the sight was only lost seven months later. The center of the anterior capsules was

most affected, showing dense irregular opacities. The left iris was adherent to the capsule at the temporal margin.

Hashimoto (*Ophthalmology*, p. 187, Oct., 1913), in a case of electric cataract, found perinuclear cataract and in the periphery and anterior surface gray dots and streaks. The current had 500 volts. He also found mydriasis, incomplete paresis of accommodation and concentric contraction of the visual field.

Electric condenser. An instrument for the accumulation or storing of electricity by its conduction from a non-insulated surface to an insulated one, as in the Leyden jar. See **Electricity.**

Electric hand-lamp. This useful little instrument is commonly employed for the examination of the eye in hospital wards, private rooms,

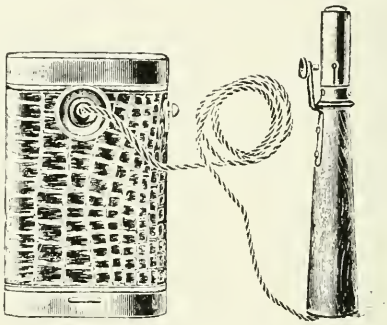

The von Gross Electric Hand Lamp.

clinics and elsewhere. The lamp of von Gross is one of the most useful. It is lighted by means of an ordinary dry battery, as shown in the illustration. "Flash" lights and electric "torches" of various sizes, with the battery forming part of the body of the instrument, are now to be had everywhere and are useful (and more convenient) instruments for the same purpose.

Electric head mirror. This instrument has been made in a variety of styles, but yet very simple in design. One of the best is the Klar-Alexander mirror. This consists of a concave mirror with a small electric light on a supporter in the center of the concavity. Two holes are cut in the sides of the mirror so that the observer's eyes follow the same line as the beam of light. A very brilliant and satisfactory illumination is secured.—(E. S. T.)

Electricity in ophthalmology. Medical electricity, in general. Faradism. Galvanism. In addition to this major heading, in which the writer presents the elements of electrical science, especially in its oculo-therapeutic relations, the reader is referred to a number of

other captions under which several additional subjects, mostly electrotherapeutic, are fully discussed. These are, chiefly, **Phototherapy,** to include those methods by which various *electric lights* are used in the treatment of ocular disease; **Cataphoresis; X rays; Diaphanoscopy** (transillumination); **Electrolysis; Electromagnet,** and various other rubrics under **Electro** and **Electric.**

Physicists agree that heat, light and electricity depend, relatively, upon different rates and forms of vibration of the universal ether,—heat representing the least frequent rate and electricity the most frequent of the three.

Fundamentally, all forms of electricity are the same. The effect of the current varies according to the apparatus employed and the method by which the current is produced. These differences show themselves in the relation of the voltage to the amperage and in the amount of these; in the direction of the current, whether in a direct course, as in the direct, galvanic, or continuous; or, in reverse directions, as in the alternating or sinusoidal; whether it is a primary current, or one induced by a primary or a static charge. Further, the frequency of the interruption of the current modifies very much its therapeutic effect.

We shall, in this section, treat briefly not only of the electrical energies used *directly* in medicine, such as the galvanic, faradic, alternating, high-frequency and static, but also of the indirect use of electricity by means of the x-ray, electric motors, massage, cautery and lamps.

FRICTIONAL OR STATIC ELECTRICITY

Franklin's theory of frictional electricity, now slightly modified, was that all bodies possess a certain amount of electricity and that friction produces, by separation, two dissimilar, simultaneous, electrical states, which he called positive and negative; and, that if various bodies be rubbed, some will be charged with positive and others with negative electricity; and, in all cases, the rubber is charged equally with, and oppositely to, the body rubbed. Further, if these objects are non-conductors, as glass, etc., the charge will remain on their surfaces. Bodies, which conduct electricity, as metals, may be electrified if they are insulated by a non-conductor such as ebonite, etc. A glass ignition rod, rubbed with flannel, is charged with positive electricity, the flannel taking a negative charge; while a rod of sealing wax rubbed with flannel is negatively electrified, the flannel becoming positively electrified.

The rubbed glass rod, held near some small bits of paper induces

a negative charge in the bits and attracts them to itself, when they are given a positive charge and repelled. The negative wax rod would electrify the papers positively, attract them, then give them a negative charge and repel them. That is to say, oppositely charged bodies attract and similarly charged bodies repel each other.

If two pith balls be suspended by non-conducting silk threads and charged + and —, by bringing in contact with the left one an electrified glass rod, and, with the right one, an electrified wax rod, the two balls will attract each other.

The *electrophorus* is not only a generator of electricity but also a carrier thereof. Suppose the lower part to consist of a sheet of ebonite grounded and the upper part a sheet of tin, attached to a non-conducting handle of ebonite or glass. To demonstrate its use, give to the ebonite sheet a — charge, by rubbing it with a cat's skin. Take the metal cover by the handle and place it on the ebonite sheet. The under side of the metal sheet will be charged + and the upper —. Touch the upper — part of the plate with the fingers and the negative charge will be neutralized by a positive current flowing from the earth through the body and hand. This will leave the + charge on the metal sheet, being bound by the attraction of the negative on the ebonite. If the cover is now lifted, the + charge is freed from the influence of the ebonite and distributes itself over the whole surface. If the cover is now touched by the finger, positive sparks appear.

The above action of the electrophorus shows that if an insulated conductor be touched while it is under the influence of a charged body, the conductor acquires a charge opposite to that of the influencing body.

A *static machine* is an electrophorus of increased efficiency; and, like it, consists of two parts, one for producing electric charges—as does the ebonite sheet—and the other for collecting them—as does the cover. The quantity of charge depends upon the amount of friction and the extent and nature of the surfaces rubbed.

The static machine illustrates the principle stated: that if a conductor is touched, while charged by induction or influence, it acquires a charge opposite to that of the influencing charge. It also illustrates reciprocal accumulation.

Imagine three insulated conductors, which we will call A., B., and C.; A. and B. being charged respectively + and —; C., a carrier, which moves to A. and receives + charge. If touched, while it is under the influence of A., it will receive a — charge and can carry it to B. If again touched, it acquires a + charge. Let it return to

A. and give up its + charge. Thus the influenced carrier transports its charge and adds it to the influencing charges, by which there is reciprocal accumulation of charge.

The action of the machine may perhaps be most readily understood by remembering that the opposite sectors on the two plates act inductively upon each other; and that a conductor, in contact with the influenced sector, carries off the free charge of the same sign as the influencing sector and leaves the charged sector of the opposite sign: e. g. + gives a — charge and — gives a + charge. Again, a current always flows through the conductor from the higher potential to the lower or neutral potential. Suppose, in the machine, some sector, as the one on the outer plate, opposite n_1, to have a very slight + potential or charge. This initial charge is probably obtained by the friction between the machine in motion and the air. Let the initial potential of the outer sector, opposite n_1, be +. By induction, it gives a — charge to the outer surface of the opposite inner sector and an equal + charge to its inner surface. The conductor carries this + charge from n_1, to the sector n_2, leaving the — charge to be carried by each inner sector, as it passes n_1, till it reaches n_3, and the collecting — comb. At the same time, the inner sectors, passing n_2, to the left till they reach n_4, and the collecting + comb. Again, the + charges of the inner sectors induce + charges on the outer sectors, which are carried by n_4 to n_3; leaving the — to be carried to n_2 and the — combs, while the n_4 brush carries + charges to n_3, which move to the left to the + combs.

Again, n_1 n_2 carries the induced + charge at n_1 to n_2 and the inner sectors collect it and carry it to the + combs; and, opposite n_4, induce a + charge which is carried to n_3; then the outer sectors carry it to the + combs. At n_4, the bound — charge is carried by the outer sectors to the — comb; and at n_1 the free — charge is carried by the inner sectors to the — comb. While this induction and conduction of charge is going on between the moving sectors when opposite the conductors, there is also a great addition to their charges by mutual induction of + and — charges between the sectors, not opposite the conductors. Evidently the upper outer sectors and the lower inner sectors carry + charges to the combs; while the inner upper and lower outer carry — charges to the opposite combs. It is understood that "inner" in the diagram is the outer surface of the front plate. The charges of the plates increase until the gain is arrested by the loss due to dissipation and leakage.

A machine with twelve plates, thirty inches in diameter, at a speed of two hundred turns a minute, gives a twelve inch spark between

the prime conductors and the enormous potential of two hundred and fifty thousand volts, while the quantity of current is only .01 ma. So great is the electro-motive force of frictional electricity, that, by rubbing an ebonite rod with a cat's skin, the writer has demonstrated a voltage of one thousand by means of an astatic voltmeter.

The resistance of the plates of a Holtz machine, at four hundred and fifty revolutions per minute, has been found to be six hundred and forty-six million ohms. This, with two hundred and fifty thousand volts would give only .4 ma.

MAGNETISM

The word magnetism takes its origin from Magnesia, a district in Asia Minor, where loadstone, a magnetic oxide of iron, was first found.

If iron filings are scattered over a piece of paper, which is held over a natural or electro-magnetic bar magnet, they will tend to arrange themselves in curved lines around the magnet. These visible lines represent invisible lines of force.

When the opposite poles, N. and S. of two magnets are held near each other, the filings, or lines of force, tend to coalesce. With like poles, N. and N. or S. and S. the filings tend to repel each other. That is to say,—Unlike poles of a magnet attract, and like poles repel each other. Magnetic lines of force have the distinguishing characteristic of moving in curved lines, while electrical energy moves in a straight line. In the use of the eye magnet, it is essential to remember that only iron can be magnetized. The magnetizable elements are called *paramagnetic*. If a magnetizable body is placed near the positive pole of a magnet, it will be magnetized by induction with a negative polarity: if placed in the field of the magnet, near its negative pole, it will receive a positive polarity.

Bodies which cannot be magnetized are called *diamagnetic*, as, notably, antimony, copper and gold, which, placed in a magnetic field, try to direct themselves east and west across the earth's magnetic lines; that is, they tend to assume a position at right angles to the exciting magnet.

A small magnetizable body, placed near a magnet of any strength, is fully saturated with magnetism, and the magnet attracts it with the same force that the body attracts the magnet. For bodies situated in the vitreous, a giant magnet is necessary. A small magnet might suffice, provided it could come in contact with the foreign body; but,

stirring up the vitreous with the tip of the magnet in the hope of a pleasant meeting with the foreign body usually results disastrously.

All magnets magnetized with a magnet or by an electric current have at least two poles. The polarity of a bar magnet can be readily ascertained by presenting one end near a magnetic needle. If the bar attracts the north end of the needle, it shows that it is the south end of the bar; if it repels the needle, it is the north end of the bar.

Induction of magnetism. As in static electricity, a charged body first induces a charge in a neutral body and then attracts it, so a magnet, held near an unmagnetized body, first induces magnetism in it and then attracts the body; and this magnetic attraction will take place across all substances that are not magnetic. Soft iron is readily magnetized and soon parts with its magnetism; while hard steel is magnetized with difficulty but remains a permanent magnet.

The *electromagnet.* For therapeutic use, the electro-magnet is made by passing a direct current through a coil of wire wound around a soft core, in which case, the core parts with its magnetism as soon as the current is turned off. Powerful magnets are made by winding a coil around each arm of a horseshoe-shaped core of soft iron, across the ends or poles of which is placed a keeper or armature.

Magnetic field. In a bar magnet, curved lines of force pass through the bar, and from the north to the south pole of the bar through the air, in a space called the field of the magnet. Around every conductor carrying an electric current, there are magnetic lines of force which encircle the conductor at right angles.

Theory of magnetism. When a magnet approaches a magnetizable body, the particles of the latter are magnetized and are thereby turned endwise in one direction.

In a glass tube, which is filled with iron filings and stroked from end to end with one pole of a magnet, the filings will arrange themselves endwise and the tube will act as a magnet. The filings may be demagnetized by shaking the tube and deranging the filings. Completely magnetized particles will then arrange themselves along the line of force.

GALVANISM

The galvanic or direct current for medical use is, usually, supplied by a direct current dynamo for street lighting. It may be supplied by the chemical action of battery cells. Where available, the street current is the most satisfactory, as it is the most convenient and most uniform; the voltage being kept unchangeable at the power-house, and, generally, at 110 to 220 volts.

Notwithstanding its almost universal use by physicians—any adverse result to the patient is extremely rare. When, on the contrary, the street lighting is produced by an alternating current dynamo, it may be transformed, for medical use, into a direct current by means of a so-called rectifier.

BATTERIES

In a chemical battery, the plates or elements should differ as much as practicable in their capacity of being acted upon by the battery fluid: hence carbon, which is not attacked, and zinc, which is readily acted upon, are generally used. The current is said to "flow," or better, to be transmitted from the source of its production, as from the zinc plate or from the dynamo, around the circuit to its source. This may be illustrated by a cell, e. g. a glass tumbler, a zinc and a carbon strip, dilute sulphuric acid, copper wire, and a galvanometer.

The chemical affinity, which is electrical, of the acid for the zinc produces zinc sulphate and an energy called voltage, a force which overcomes the resistance of the circuit and produces or tends to produce a current. Within the fluid, the zinc is the positive pole and the carbon the negative. Outside the fluid, the carbon becomes the positive pole and the zinc the negative; since, in the circuit, the current flows within from the zinc to the carbon; and, outside, it flows from the carbon to the zinc.

When the factors that enter into the production of a current are fully comprehended, the greater part of the physics of electricity is mastered. It is not easy to define in exact language the nature of these factors, and the conventional terms used seem, too often, inaccurate and confusing.

The factors are known as *voltage*, (electro-motive force, pressure or tension), *resistance* and *current*. Voltage is the force or energy, produced by chemical or physical means, which generates, or tends to generate, a current of electricity by forcing it through a resistance. Resistance is obstruction to transmission. The current signifies electricity in motion. The conventional word "flow" of a current is convenient; but electricity does not literally flow (except in liquids) any more than does heat, which is transmitted along a conductor, to the distant end. So a dynamic condition of an electric conductor is transmitted through its length.

These terms may be better understood by applying them to hydrostatics and heat. A water reservoir, a discharge pipe, and a receiving vessel will serve as an illustration. The pressure of the water is directly proportional to the height above the receiving vessel. This

pressure is analogous to electric pressure or voltage, and, other things being equal, the amount of the flow of the current of water or electricity depends upon the pressure.

Again, the degree of resistance to the flow of the water is relative to the size of the pipe—being inversely to the square of its diameter. Just so, the resistance to the flow of an electric current, through a conductor, is inversely to the square of its diameter. A cord of .1 inch diameter has four times the resistance of a cord .2 diameter: hence the former conducts one quarter the amount of current. With a given pipe, the force of the water delivered to the receiving vessel is the same at any instant of time and is equal to the pressure divided by the resistance; while the amount of water delivered is equal to the force multiplied by the time of flow. Similarly, the force or energy of a current is the same at any instant; but the amount of the current is the force multiplied by the time of flow. The unit of this energy is one ampere. The amount of the current is one ampere multiplied by one second, which equals one coulomb.

The electric units of pressure, resistance and current are respectively volt, ohm and ampere. In terms of the factors, or, to talk in a circle, a volt is the electro-motive force required, against a resistance of one ohm, to produce a current of one ampere. An ohm is the resistance required, against an electro-motive force of one volt, to produce a current of one ampere. An ampere is produced by the electro-motive force of one volt against a resistance of one ohm. The electro-motive force produced by one Daniell cell is 1.14 volts.

An ohm may be represented by the resistance of a copper wire, two hundred and fifty feet long and one twentieth of an inch in diameter. The amperage is not the rate of flow or quantity or volume of the current, as is frequently stated. It may be defined as the amount of energy which the magnetic field of the current shows in attracting a needle.

The amount, volume, quantity or rate of flow of the current is represented by the amperage multiplied by the time: that is—one ampere, multiplied by one second, equals one coulomb.

Difference of potential. If a different potential or voltage be applied to each end of a conductor, as to the prime conductors of a coil, the direction of the current will be towards the lesser potential and its energy will be the difference between the potentials.

The law which governs these three factors is called Ohm's law, and is as follows: The electro-motive force divided by the resistance is equal to the current or intensity; or, using the units of these factors, one volt divided by one ohm equals one ampere. That is, the

current varies directly as does the voltage and inversely as does the resistance. Or, in other words, the resistance remaining constant, the current increases or diminishes, as the voltage increases or diminishes: or again, with the voltage remaining the same, the current is increased by diminishing the resistance or decreased by increasing the resistance.

Having the volts and the ohms, the amperes are estimated by dividing the volts by the ohms. Having the volts and the amperes, the ohms may be determined by dividing the volts by the amperes. Having the ohms and the amperes, the volts may be determined by multiplying the ohms by the amperes.

As an aid to swift calculation, the following method may be of value:—Let the volts, ohms and amperes be represented by the numbers, respectively, 8, 4, 2. Having 8 and 4, the unknown is determined by dividing 8 by 4. Having 8 and 2, the unknown is determined by dividing 8 by 2. Having 4 and 2, the unknown number is determined by multiplying 4 by 2. This rule is invariable in the determination of the unknown volts, ohms or amperes, when any two of these factors are known.

For medical use, an ampere represents too strong a current, hence medical meters indicate a thousandth of an ampere, or a milliampere, which is briefly written ma.

What do the dynamo and battery supply? In answer to the oft repeated question of the physician, "How much current will a given battery furnish?" Neither the battery nor the dynamo supplies current. They produce voltage, from which current is derived. The current they are capable of producing with a given voltage depends upon the amount of resistance used in the circuit. If there were no external resistance, as of the body, the voltage of one cell would produce as much current as that of a hundred cells of the same voltage connected in series. By series, is meant, that each carbon of a cell in the battery is connected with the zinc of its nearest neighbor, and, to complete the circuit, the last carbon is connected with the first zinc.

Assuming a pressure of one volt and an internal resistance of ¼ ohm in each cell joined in series: One cell $= \frac{1 \text{ volt}}{.25 \text{ ohm}} = 4$ a. Four cells $= \frac{4 \text{ volts}}{1 \text{ ohm}} = 4$ a.

Joining four cells in parallel has substantially the same effect as

if all the elements of zinc and carbon were placed in one large cell, having four times the cubic capacity of the small one; and joining all the zincs together and all the carbons together is equivalent to increasing their size four times.

The difference of potential in the two large plates is the same as that between the two small plates. In the large cell, the sectional area of the fluid and plates is increased four times, therefore the resistance is reduced to one quarter that in the small cell; then $1/4 \div 4 =$ $1/16$ ohm. Hence the amperage is $= \frac{1 \text{ volt}}{1/16 \text{ ohm}} = 16$ amp.

This combination gives high amperage for cautery purposes.

In a *parallel series connection* of batteries each pair of cells has an electro-motor force of one volt. Two pairs of cells have one volt multiplied by two, equalling two volts. Each pair has also half the resistance of one cell, that is, $\frac{1}{4} \div 2 = \frac{1}{8}$ ohm and the two pairs have $\frac{1}{8}$ ohm $\times 2 = \frac{1}{4}$ ohm. The amperage in this combination is $= \frac{2 \text{ volts}}{\frac{1}{4} \text{ ohm}} = 8$ amp. It will be noted that the wattage is the same in the series, parallel and multiple connections of the cells: 1. 4 volts $\times$ 4 amp. = 16 watts. 2. 1 volt $\times$ 16 amp. = 16 watts. 3. 2 volts $\times$ 8 amp. = 16 watts. When an external resistance, such as that of a patient, is placed in the circuit, the ma. will be increased nearly in proportion to the increase in the number of cells used. Suppose the patient has a resistance of 5000 ohms, and the cell a resistance of $\frac{1}{4}$ ohm. With one cell, the current is $\frac{1 \text{ volt}}{5000.25 \text{ ohms}} = \frac{1}{5000}$ a nearly. With four cells, the current is $\frac{4 \text{ volts}}{5001 \text{ ohms}} = \frac{1}{1250}$ amperes, nearly. The internal resistance of the cell is so small that it adds little to the external resistance. As in the above case, one cell adds $\frac{1}{4}$ ohm to the 5000 and four cells add only one ohm; but the voltage is increased four times and thus yields nearly four times the current of one cell.

Conduction of a current. Resistance to a current might as well be expressed in terms of conduction. A good conductor has a low resistance and a poor conductor a high resistance. Among the metals which are good conductors, silver and copper stand at the head of the list. Copper is used in making electric coils, conducting cords

and electrodes as it is cheaper than silver and has nearly an equal conducting capacity.

The relative capacity of the metals for electric conduction very closely corresponds with their capacity for the transmission of heat.

The means of measuring a direct current with a galvanometer. When any electric current passes through a conductor, it sets up a magnetic or an electric field consisting of lines of force which surround the conductor and cut it at right angles. If an iron or steel needle be placed parallel to the conductor, it will be magnetized and tend to place itself in line with the lines of force at right angles to the conductor: the end of the needle, moving away from the direction

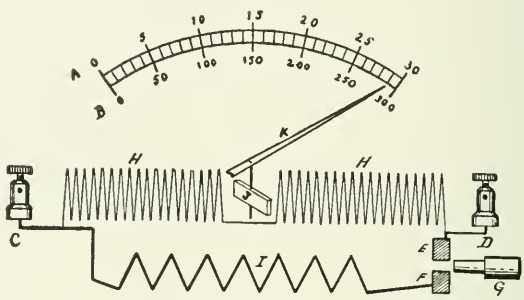

Fig. 1.

Measuring a Direct Current with the Galvanometer.

of the current in the conductor, being made the north pole and the end moving towards the conductor the south pole.

In figure 1, C. and D. represents the binding posts, into which are inserted the cords which conduct the current. If the positive cord is connected with C., and the negative with D., the current will pass through the coils at H. H. to the post D. (negative), magnetizing the needle J., moving it, and with it the pointer K., to the right along the scale from 0. to 30. A permanent magnet maintains the pointer K. of the needle J. at zero and acts as a counteracting force to the strength of the magnetic field of the coils H. H.—the strength of the current, that is of its magnetic field, being indicated by the pointer. Usually, there are two scales on the meter, one representing ten times the values of the other. The higher values are secured by shunting the current, that would otherwise pass through the meter, through a resistance coil through which nine-tenths of the current passes and allows only one-tenth to pass through the meter.

In figure 18, insert the plug G. to connect E. and F. Then suppose

the combined resistance of the coils H. H. and I. to be one ohm, of which H. H. has 9/10 and I., 1/10. The current that passes through each coil from C. to D. will be in reverse ratio to the resistance; one-tenth of the whole current passing through H. H. The patient connected at C. and D. receives the whole current carried by the two coils, which is ten times as much as passes through the meter. The current which passes through the patient is registered on the lower scale, which runs from 0 to 300 ma.

Meters of recent make are, in general, nearly accurate, but it is best to test one before measuring such small doses as are required in the treatment of the eye. The test can be made by connecting up the meter with a standard meter and comparing the result, which should not differ more than .5 of a milliampere. Special meters can be purchased not registering over 100 ma.—quite sufficient for our purpose. They are more accurate than those measuring a stronger current.

No operator should use a direct current without measuring it, any more than a physician should administer an unmeasured drug; for, with the exception of the x-ray, there is no current so likely to be harmful, if used in excess, as the direct. On the other hand, there is no current that affords so wide a range of usefulness as the direct; but it must always be regulated by consideration of the pathological condition of the patient and his susceptibility.

GALVANOMETERS AND VOLTMETERS

These two instruments are exactly alike in principle and differ only in the details of their construction and in their uses. In fact, the voltmeter is only a delicate galvanometer. If the resistance is constant in the circuit, the galvanometer can be graduated to read both amperes and volts. For instance, through a resistance of 20 ohms, giving 1 ampere of current, the voltage is 20 ohms $\times$ 1 ampere = 20 volts. Hence, every ampere or fraction thereof represents 20 volts or fraction thereof. But when the resistance is variable, it is impossible to graduate the instrument to represent the volts. If the ohmic resistance is not 20, but, say 40, and the amperage 1, the voltage will be 40 instead of 20: that is, for every ampere of current, the scale should read 40 volts—but it is graduated to read 20 volts. The galvanometer is constructed with a short, thick wire, in order to offer a low internal resistance to the flow of the current. It is always connected up in series in the circuit and measures the current in any part of it.

A galvanometer, constructed with a long, thin wire, allows only a

delicate current to pass through it, and, by the intensity of the current on its needle, measures on a scale, in volts, the pressure that produced the current.

Let the resistance of the meter be 1000 ohms. If a current of $\frac{1}{1000}$ of an ampere or 1 milliampere pass through it, the voltage must be 1 volt: $\frac{1}{1000}$ ampere $\times$ 1000 ohms = 1 volt. The terminals of the meter are connected across the circuit and the same voltage passes through the meter as in the included portion of the main circuit; for, in a divided circuit, the voltage in a branch is the same as in the main circuit. While it is well to explain the principle and application of a voltmeter, the physician has practically little use for it, as he is concerned only with the amount of the current, which he measures with the milliamperemeter.

Current controller or rheostat. Currents are controlled for medical use by a rheostat. Of these, there are two popular varieties; the graphite—least used; and the German silver coil. The graphite rheostat is less durable than the coil and has the undesirable quality of being a better conductor when heated, thereby increasing the initial current and necessitating constant regulation of the current. In the application of a definite amount of current, it is immaterial in what way it is controlled, whether by a rheostat or a current controller, so far as the amount of voltage, or the effect upon the patient is concerned.

The resistance of a given conductor to a current is inversely proportional to the area of the cross section of the conductor and directly proportional to its length; hence, the combined resistance of two conductors of equal area is one half of one of them. If any number of equal conductors be connected, separately or as one, with a source of voltage, they all receive the same amount of voltage but the current depends upon the resistance. Let each of two conductors, having 1000 ohms resistance, be connected separately with a voltage of 100,—then each delivers a current of $\frac{100 \text{ volts}}{1000 \text{ ohms}}$ = 1/10 of an ampere; or, combined, = 1/5 a. If the conductors be joined in a parallel manner, they will have double the cross area of one and give the same current as before: i. e. $\frac{100 \text{ volts}}{500 \text{ ohms}}$ = 1/5 a.

The rheotome is an instrument for making and breaking either the direct or induced current. The wall plate rheotome is a clock work arrangement, in which the speed is regulated by a pendulum or otherwise. The number of interruptions per minutes varies with the speed of the clock and the number of brushes on a revolving cylinder which are made to come in contact with one of the three springs.

THE INDUCED OR FARADIC CURRENT

This is the current produced by the small coil of the usual medical wall plate.

Faraday discovered, in 1831, that by moving a magnet near a closed circuit, an induced current would be produced in it; and also, later, that this induced current could be produced in a closed circuit when a current in a neighboring closed circuit was varied in strength, by any means.

The Faraday ring is an induction coil and the first transformer ever constructed. It consists of a ring of soft iron, around which insulated copper wire is wound, the two helices being separated by an uncovered ring. The principle of this ring is exactly that of the induction coil: and every induction coil is a transformer. The battery current produces in the coil magnetic lines which cut the loops at right angles, making them an electro-magnetic coil; the magnetic lines of which circulate through the iron ring or core and cut the secondary coil at right angles and generate a current, as shown by the galvanometer, when the battery circuit is closed or opened.

A *step-up transformer*. If the primary coil is made of 100 loops and the secondary of 5000, the electro-motive force in the secondary will be fifty times as great as that in the primary. This illustration of a step-up transformer might be reversed to show that of a step-down transformer by making 5000 loops in the primary coil and 100 in the secondary, in which case, the voltage of the secondary is $\frac{5000}{100} = 50$. This ring demonstrates the law that the ratio of the voltage in the secondary to the voltage in the primary is as the number of loops in the secondary is to the number of loops in the primary. On the contrary, the ratio of the current in the secondary is to that in the primary inversely as the ratio of the voltage in the secondary is to that in the primary: for example,—With 500 volts in the secondary and 5 in the primary, the amperage will be 5 in the secondary and 500 in the primary. The number of volts $\times$ the

number of amperes in the primary—less some loss in the transformation—is always equal to the number of volts × the number of amperes in the secondary.

The amount of voltage and amperage in the secondary is directly related to the amount of current in the primary, to the density of the magnetic field and to the frequency of the linking and unlinking of the secondary loops by the magnetic lines. The magnetic flux is equal to the magneto-motive force divided by the reluctance.

The magneto-motive force, in the secondary, upon which the voltage depends, is directly related to the current in the primary, to the frequency of making and breaking the primary circuit, or to the frequency of the revolutions of the armature of a dynamo.

In an average induction coil, giving a ten inch spark, the primary wire consists of 100 yards of copper wire, the coil diameter 264 mm., its resistance being 1/3 of an ohm. The secondary is ten miles long and has a resistance of 6500 ohms.

The direct current transformer. The apparatus used to transform continuous currents is a motor-dynamo. Two armatures are wound on one shaft, one coil receives a small current at a high pressure, driving the other which acts as a dynamo, giving a larger current at a low pressure. "The windings are proportioned to the voltages and their sectional areas to the amperes."

An alternating current transformer. Instead of producing an alternating current in an induction coil by means of making and breaking a direct current in the primary, an alternate current street dynamo may give to the primary coil of the machine an alternating current to excite the secondary coil to give out other alternating currents.

If a coil of insulated copper wire forms a circuit, and a bar magnet be rapidly inserted into or withdrawn from the hollow of the coil, transient currents are produced and the current is much the stronger at the withdrawal. If the magnet is placed in the coil and left motionless, no current is produced. Whether a primary current or a magnet is used to produce induction in a secondary coil, the induction is always caused by the invisible, magnetic lines of force of the current or magnet, which cut the loops of the secondary coil. It requires one hundred million of these lines to produce one volt, if they cut one loop of the coil in one second; or one million lines, if they cut 100 loops in one second. In practice, when an induced current is obtained by the motion of an electro-magnet electro-magnetic coil, the process is called electro-magnetic induction. When permanent magnets are used to produce the magnetic lines or "field flux" the generator is called a magneto-electric machine or simply magneto. The action of the "hand

magneto'' depends upon an arrangement by which two bobbins of wire are revolved by hand between the poles of a permanent magnet.

Direction of the induced current. A magnet is given its distinct polarity where excited by a current in a certain direction. If this magnet is withdrawn from a coil, it will excite a direct current in the coil,—that is a current in the same direction as gave the magnet its polarity. The current caused by inserting the magnet is an inverse current. If the coil is moved towards and from the magnet, the resulting current will have the same direction as when the magnet is moved towards and from the coil. The same effect is produced upon the secondary conductor or coil as when a magnet approaches a coil, that is,—the direction of the current in the secondary is opposite to that in the primary. Upon breaking the circuit, the direction of the current in the secondary is the same as that in the primary. The secondary current, produced by the opening of the primary circuit, is so much stronger than the secondary which is produced by the closing of the primary circuit, that it gives a severe shock, as compared with the feeble shock of the closing.

In the application of the secondary current to the patient, each electrode is, alternately, anode and cathode, in rapid succession. Still, the opening current is so predominant, that it is justifiable to consider that the electrode connected with it is the anode and the other the cathode. The comparative weakness of the secondary, when the primary is closed, is due to the self induction of, or extra current in, the primary, hindering the growth of its current, and thus causing the slow rise of its magnetic field or lines of force which cut the secondary coil. On the contrary in breaking or opening the primary circuit, the magnetic core of the secondary is suddenly demagnetized; and, in the process, the magnetic lines, suddenly collapsing, increase the induction current of the coil. For example, if one thousand lines cut a coil in one-fifth of a second, they produce five times as much voltage as they would in cutting the coil in one second.

CURRENT GENERATORS

The construction of the *alternating current generator* is indicated in figure 2. N. and S. are the terminals of a horseshoe permanent or of an electro-magnet; B. C. the wound armature. On the armature are two contact rings E. and D. on which two brushes, F. and G. press.

The direction of the field in the magnet is from N. through the armature to S. making B. the north pole and C. the south, repelling the armature and revolving B. C. in the direction of the arrows.

While B. is making one-half a revolution from N. to S., the current is passing from B. through the contact brush F. and the patient X. at H. In the next half revolution, the current is reversed by passing from N. to C. to E. to the contact brush G. and the patient at I.

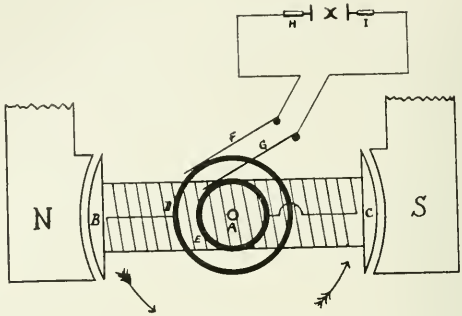

Fig. 2.

Alternating Current Generator.

Thus, at each half turn, the contact rings and the electrodes become alternately + and —. In each complete revolution, the electro-motive force rises in one half to maximum and falls to zero; then reverses, grows to a maximum and falls to zero. Each revolution is called a

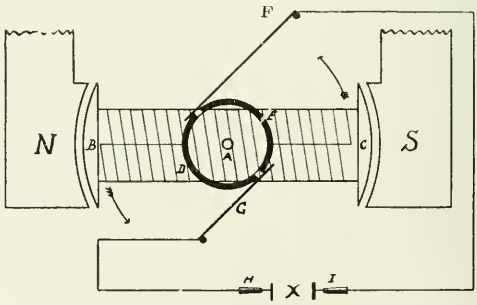

Fig. 3.

Continuous Current Generator.

period or cycle and the frequency of the alternations is twice the number of the cycles. Figure 2 demonstrates that the revolving of an armature in a magnetic field produces a change in the direction of the electro-motive force and the current at every half turn.

Continuous current generator. When the supply current is an alternating one, the best means of securing a direct current is to drive

with it a motor at one end of a shaft, at the other end of which is a direct current generator. The action of this, see figure 3, is the same as that of the alternating current generator, except that in the former the current is made to pass in one direction only by means of a divided ring D. E. called a commutator. By this means, either one

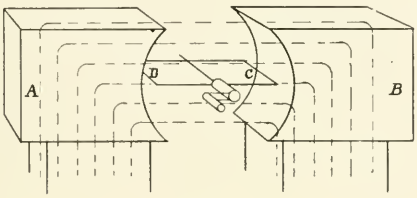

Fig. 4.

Showing Magnetic Lines of Force. (After C. H. W. Bigg.)

half D. of the ring or the other half C. of the ring is constantly in series connection with the brush F. and I. the plus side, while G. is in constant contact with the sides of the ring in contact with F.; thus there is a unidirectional current from F. through the patient to G.

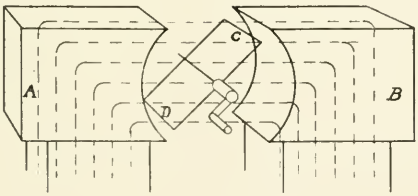

Fig. 5.

Magnetic Lines of Force.

Action of magnetic lines of force upon a field magnet. The illustrations (figures 4, 5, 6) are from C. H. W. Bigg's *First Principles of Electricity and Magnetism.* In the position shown, in fig. 4, none of the lines of magnetic flux pass through the armature coil, and, consequently, no current is induced therein. If the coil is set in motion, it successively embraces a constantly increasing number of lines of force, and a current is induced which attains its maximum when the coil is in the position shown in figure 6, and all the flux passes through the coil.

A moment's inspection of the figures will show that, at each half revolution of the coil, opposite faces are brought in front of A., and, consequently, the flux must enter the coil from one side during the first half of the revolution and from the opposite side during the remainder: the current resulting will, consequently, be of an alternating character.

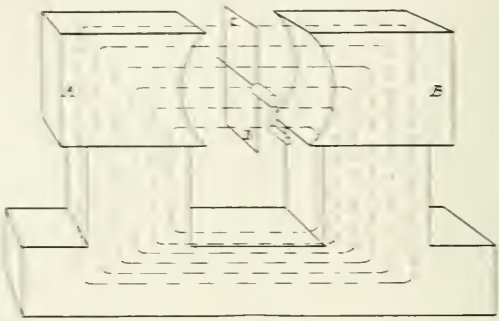

Fig. 6.

Magnetic Lines of Force.

THE SINUSOIDAL CURRENT

In any current, in which the rate of flow is not constant, a more or less regular pulsation or wave results. In the faradic coil, this wave takes the shape of a rapid rise, followed by a slower drop to a minimum value. Such sudden changes produce a current that is harsh in its effects, and, if of appreciable magnitude, productive of considerable discomfort to the patient. In order to obtain an alternating current that is free from abrupt changes, a generator of the magneto type, as indicated in figure 7, is employed.

If the armature of such a generator is rotated at a uniform rate of speed, it will move through equal angular intervals of time, and the resulting electro-motive force will follow the simple sine curve, where E. M. F. = A. sine O.; where A. is a constant, depending upon the construction of the generator, and O. represents the angular position of the armature at any given instant of time. Such a curve is an example of simple harmonic motion,—so called because the vibrations of musical notes are of this type,—and is best defined as an oscillating motion, in which the amplitude or height of the vibrations is independent of the time.

If the constant A. is known, the voltage curve may be calculated by multiplying the sines of the angles that the armature makes with

the plane of the lines of force at equal intervals of time, as it may be shown graphically, as in figure 7.

In the above diagram, if B represents a particular plane in the armature of a generator, and the armature is revolved at a uniform speed, B will be successively carried to P, Q, H, etc., in equal intervals of time. If now, we draw a horizontal line B T through the axis of rotation C, and on this line, as an ordinate, indicate the time intervals; and above and below this line, other lines which represent the position of B, when in the different angular positions, for at this time, the slope of the curve will be shown by the points at which lines perpendicular to the time and the lines showing the angles. These



Fig. 7

The Sinusoidal Current.

perpendicular lines are a graphic representation of the sines of the corresponding angles, P, H, for instance, being the sine of the angle P, C, B, and its projection on the horizontal line B T locates the point 3. The curve shows the rate of increase and diminution of the voltage that would occur if B were to be turned through a complete revolution in 1.2 seconds; the part above the line B T, indicating a positive and that below the line a negative value in the resulting current. Such a voltage curve has, probably, all the therapeutic values of the faradic current in producing muscular contractions and nerve stimulations, but, being free from abrupt changes, allows the contractions to occur in a rhythmic manner, instead of by the irregular jerks, the sudden changes of voltage that the faradic current induces.

Although the curve, shown in figure 10, is drawn to show a periodicity of 1.2 second, it may be readily seen, from an inspection of the drawing, that the height of the curve is independent of the time, and that a wave of the same height, but of a faster or slower sequence, can be obtained by the simple expedient of varying the speed of the armature. By such change, we can obtain the rapid reversals of cur-

rent that are sedative in character, or the slower rise and fall that permit of rhythmic contraction of muscles.

THE X-RAY

X-rays are composed of infinitely short transverse waves, propelled in straight diverging lines; their mass being inversely as the square of the distance. They are produced in a Crooke's tube, exhausted to a vacuum of .000,001 of the pressure of the atmosphere, which is traversed by a very high tension electric current of a Rhumkorff coil or a static machine. The tube has, at one end, a cupped cathode, and, at the opposite end, two connected anodes. The one which is in line with the cathode is the anode proper. The other terminates in a flat

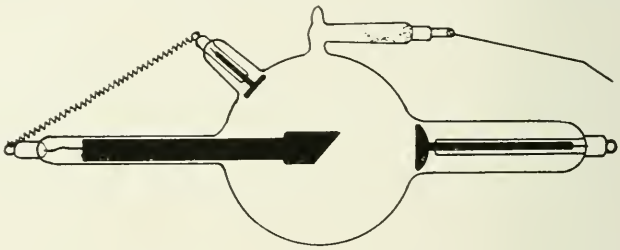

Fig. 8.

Tungsten Target Tube.

disc or target and is the anti-cathode. In connecting up the tube, the anode of the exciting machine should be connected with the anode of the tube.

Theory of the production of x-rays. It was known that only a small current could be sent through a gas by a moderate electric intensity, but, with a high intensity, a considerable current would pass. A vacuum can be produced, through which no current can be made to pass. A stream of particles (Guilleminot thinks probably hydrogen), flows from all parts of the anode end of the tube toward the cathode, receives a negative charge, is then repelled with tremendous velocity and focussed upon the anti-cathode target, where the cathode rays are "stopped and absorbed" and Roentgen rays are emitted and ejected through the wall of the tube in front of the target. Roentgen found x-rays affect a photographic plate in the same manner as light.

J. J. Thompson showed that they produce conductivity in any gas through which they pass. The rays are very similar to light rays, but they are not refracted when they pass from one medium to another of different density. They also resemble cathode rays, but they differ from them in carrying no electric charge.

ELECTRO-THERAPEUTIC APPARATUS

Here the intention is to call attention to the prevailing types of electro-therapeutic apparatus in general use rather than to advertise the product of any particular manufacturer, for, while the mechanical details may vary widely according to the individual ideas of different



Fig. 9.

Galvano Faradic Wall-Plate.

makers, the purposes for which such apparatus is intended are alike with all, and the high standard of workmanship generally prevailing is such that comparisons are unnecessary. Apparatus suitable for the uses of the ophthalmologist is to be had of any of the regular instrument supply houses, and the pages of the prominent journals contain many advertisements of other makers who are producing special apparatus of recognized worth.

If, in the selection of illustrative cuts, undue prominence seems to have been given the apparatus of certain manufacturers, it is due

to the fact that the author has described that with which he is personally familiar as being typical, not that he considers it as necessarily superior to that made by other representative makers.

THE GALVANO-FARADIC WALL-PLATE

In the usual type of wall-plate (see figures 9 and 10) the direct current of the plate is supplied by the street service. The strength



Fig. 10.
Wall-Plate.

of current required is obtained by placing in series with the patient, a rheostat. The galvanometer of the wall plate measures the current in the patient's circuit. A switch or pole changer is used to change the direction of the current as required.

The faradic coil of the wall-plate. This is a small coil, consisting of a primary coil of stout insulated copper wire of a few turns, within which is a soft iron core of parallel wires; and, around the coil and insulated from it, is a secondary coil of finer insulated copper wire of many turns. The induction in the secondary coil is produced by making and breaking the primary circuit with an automatic hammer. The

hammer, and the regulating screw, against which it presses, have platinum surfaces at the points of contact, to minimize the corrosion of the sparking discharge. The spring hammer is in the primary circuit when it is at rest against the screw. When the current is turned on, it magnetizes the core which attracts the hammer to it, removes the hammer from the screw and breaks the circuit,—thus demagnetizing the core and releasing the hammer, which then flies back to the screw, when the process is renewed.

Rheotome. The office wall-plate is usually supplied with an automatic circuit breaker or rheotome, the purpose of which is to convert the constant direct current into a pulsating direct current, which, in many of its effects, is similar to that produced by the faradic coil, but is unidirectional instead of alternating, as in the latter coil.

The high-frequency induction, or Rhumkorff coil. Except in size, this does not differ in construction from the small coil of the wall plate. The current of a Rhumkorff coil is of an alternating character, but with the negative phase much stronger than the positive. It is then possible to obtain an intermittent pulsating current of unidirection by means of a suitable commutator, or, as is usual, to introduce a spark gap in one of the lead wires. The purpose of this gap is to suppress the weaker wave by acting as a resistance to its passage. The polarity of the prime conductors of the coil is indicated as follows: The disc acts as a condenser, and, if it is the positive pole, the discharge takes place, as from all condensers of a similar shape, at the edge. When the positive charge is from the opposite small electrode, it strikes the disc at an indefinite place between its centre and circumference.

Under similar conditions of size of the prime conductors, etc., a coil demonstrates the voltage when it gives an inch spark as does the static machine.

In order to minimize the effect "at make" of reverse currents of self-induction, which would act as an impedence in the circuit and prevent the current attaining a proper maximum, a *condenser,* usually consisting of insulated sheets of tin foil, is inserted as a shunt across the terminals of the interrupter.

The Oudin d'Arsonval resonator. This is usually furnished as an attachment to the coil or static machine and consists of a coil of coarse wire of few turns wound around the base of a cylinder of wood and terminating in a coil of fine wire of a greater number of turns. The coarse wire coil, the relative length of which is adjustable, acts as an impedence coil to the discharge from a pair of Leyden jars, the rate of the discharge being controlled by a spark gap. As the jars are

charged with a sufficient force to overcome the resistance of the air gap of the rods, a spark passes between them and empties the jars. The induced charges on the outer surface of the glass of the jars are thus released and rush through the conductors to the resonator. The spark discharges consist of to-and-fro oscillations which may vary from ten thousand to tens of billions per second. The charge from the Leyden jars produces self induction in the resonator and also a resonance which should be synchronous with the vibrations of the spark gap of the jars. These vibrations once set up in the resonator tend to increase in frequency and thus add to the voltage and capacity of the coil. The vibrations of the spark gap and the resonator must be in harmony in order to get the greatest effect from the coil. The current delivered to the patient is much greater when the vibrations of the resonator are harmonious with those of the spark gap of the jars than when they are not. This can be demonstrated by the relative amount of current thrown into the circuit, proving that the effect of the current on the patient is less with inharmonious vibrations than when the current is diminished to produce harmonious vibrations.

In lieu of the resonator in circuit with the high-frequency coil, Tesla employs an induction coil of a few turns of coarse wire within a coil of fine wire of very many turns. This acts as a step-up transformer to very greatly increase the voltage of utility.

The interrupter. Three principal methods of opening and closing the circuit in the primary of the high-frequency coils are in use: the hammer, the mercury turbine and the electrolytic. The first has already been considered.

The *mercury turbine* consists of a turbine wheel revolving within a suitable case. The revolutions of the turbine operate to project a stream of mercury which makes intermittent contact with the walls of the case. The connections are such that the mercury stream is in series with the main circuit, the current in which is broken each time the mercury jet is interrupted.

Wehnelt's electrolytic interrupter consists of an anode of platinum wire, insulated, with the exception of the extreme end and a lead plate cathode; the two being immersed in sixteen per cent. of sulphuric acid in water. When a current passes from a source of twenty to one hundred volts, the platinum glows intermittently. The current sets free hydrogen, which gathers on the cathode in the cell and prevents a further passage of the current. As the bubbles of hydrogen escape into the surrounding electrolite, the current is again established. The circuit is thus made and broken very rapidly.

TRANSFORMERS

A transformer is usually an induction coil, by which a primary current of high initial electro-motive force is made to produce a secondary current of low initial electro-motive force. This is a step-down transformer. See fig. 11. A step-up transformer transforms a current of low electro-motive force into a current of high electro-motive force. The term transformer is also applied to a device by means



Fig. 11.

Step-down Transformer.

of which alternating currents are changed into continuous ones and vice versa.

SINUSOIDAL APPARATUS

In the modern type of apparatus, designed for the production of currents having a sinusoidal wave, there is little to remind one of the "shocking machine" of our fathers,—a coil of wire revolved between the poles of a permanent magnet.

About twenty years ago the designers of electrical machinery called attention to the shape of the wave as a factor in the design of apparatus and the effects of the current produced; and it is to Edison, doubtless, that the introduction of the sine wave into the domain of therapeutics is due. The first apparatus was capable of affording waves of a fixed periodicity only, later types enabled the rate to be varied and afforded currents suitable for a wide range of uses; and at present we have offered us machines in which the wave length can

not only be varied but in which two or more waves of different length and amplitude can be superimposed. See figure 12. As to the utility of superimposed currents, there may be a difference of opinion, but as to the utility of the different wave lengths, there can be no doubt, as, with a proper machine, it is possible to obtain currents of such rapid reversals that the muscle tissue cannot respond and the nervous sys



Fig. 12.

Multiplex Generator.

tem alone receives the waves so slowly that they excite rhythmic contractions of the muscles and influence metabolic processes.

As the alternating current is rapidly replacing the direct for commercial purposes, it is possible to derive the sinusoidal current direct from the mains, but, owing to the fact that such current is of a fixed periodicity, its range of usefulness is practically limited to its sedative effect; the usual rate of sixty cycles per second being too rapid for muscular effects. When, however, the rate of the particular current at the operator's disposal is satisfactory for his purpose, the only apparatus needed for its control is a rheostat. This should, preferably, be of the shunt type and inserted in the circuit in series with a

lamp of suitable capacity. The lamp is intended to act as a safety device to prevent an excessively large current entering the rheostat.

RHEOSTATS

A rheostat is an apparatus for controlling the strength of an electric current by changing the amount of resistance of the circuit. It is an indispensable part of the electrical equipment.

While many forms are on the market, the prevailing types for medical purposes are the following:

Water. In this form, now but little used, a vessel of water forms a resistance which admits of variations by raising or lowering an adjustable conductor and thus varying the length of the column of water.

Compression. This consists of an elastic, rubber container, filled with granulated carbon. The initial resistance is high, but, by compressing the carbon grains by means of a screw, they are brought into more intimate contact and more current is enabled to pass.

Wire. In this form, a wire of appropriate length forms the resistance and a movable contact allows any fractional portion to be introduced into the circuit.

Carbon. A common type of this rheostat consists of a slate base, provided with a lever, capable of revolving about a fixed axis and making contact with a carbon coated surface. In the more simple types, this coating is applied by rubbing the surface with a soft lead pencil; in others, a mixture of clay and graphite is pressed into a groove cut in the slate and is caused to adhere by baking.

Volt selecter. This name is a misnomer, but it seems destined to remain for some time. What is really meant is a current controller, and it affords a means of regulating the strength of the current in the patient's circuit by means of shunting off, from a main supply, a current of any desired strength. In this form, which is perhaps the most desirable when the commercial circuit is employed, a German silver or similar resistance wire of suitable length is inserted in series with the main current. By means of movable contacts, a branch circuit is formed, through which the drop in voltage and consequent current can be varied as desired.

Before the advent of commercial currents, the ordinary series rheostats were sufficient for therapeutic purposes, as the batteries were not sufficiently strong to admit of a dangerously large current. The high voltage of the commercial current, however, would necessitate so great an amount of resistance material as to render the usual types of rheostat of unwieldy size, so that, in order to render this

current available, the shunt controller is more convenient. As the purpose of a rheostat is to control the current, it is absolutely immaterial of what material it consists, so long as it will permit the necessary current to pass without becoming unduly hot, and will admit of the current being varied by regular amounts, but so evenly that the patient does not experience a shock as the lever passes from one



Fig. 13.

Combined Controller and Meter.

contact point to another. As supplied by the makers, the shunt controllers are marked with a scale of voltages, but, in actual use, such scales serve for comparative measurements only and afford absolutely no indication of the actual drop in voltage; the designers seeming to have overlooked the fact that a branch circuit operates to lower the resistance of the entire circuit.



Fig. 14.

Controller Attached to a Lamp Socket.

Figure 13 shows a combined controller and meter. An ingenious little controller is shown in figure 14 for attaching directly to a lamp socket and affords a ready means of regulating the small diagnostic lamp.

PROTECTIVE DEVICES

Aside from the use of the rheostat to control the current, other means are provided to protect both patient and apparatus from the effects of a dangerously large current. Chief among these are:

Fuses. A fuse is a short length of lead or composition wire inserted in the circuit and designed to melt and thus break the circuit if the current rises to dangerous proportions.

Automatic cut-outs. These are less in evidence than they should be. Essentially, they consist of a movable contact, held closed by means of an electro-magnet. In case the main current is broken from any cause, the contact is released and can not be again restored until the rheostat switch is brought back to zero. This prevents the shock that would occur to the patient if the circuit were broken and completed while he was under treatment.

A variety of this cut-out contains a second magnet that operates to open the circuit if the current should rise too high, but it is not yet adapted to medical uses.

Lamp rheostat. An ordinary electric lamp, in series with the main circuit, forms at once a satisfactory and inexpensive means of reducing the commercial circuit to a suitable strength for the physician's needs. In effect, it is simply a rheostat of fixed capacity, but it has the further advantage of effectually opening the circuit if it should burn out and of acting as a pilot light to show that a current is passing through the apparatus.

RECTIFIERS

In order to obtain a direct current from the commercial alternating circuit, some form of rectifying apparatus is needed. The following are the types employed in medical work:

Rotary rectifier. In this form a motor, driven by the commercial current is used to drive a miniature dynamo, which produces the current required. In some forms of this apparatus, the two windings are superimposed on the same shaft. The combined form is usually known as a motor-generator.

The *electrolytic rectifier* owes its value to the curious property possessed by certain gases and metals of conducting a current better in one direction than in the other. As ordinarily made, this rectifier consists of an aluminum and an iron plate immersed in an ammonium phosphate solution. On connecting these electrodes to an alternating circuit, the current will flow only from the iron to the aluminum; the reverse wave being suppressed—and an intermittent current results.

In actual practice, however, the action is not instantaneous and there is often a small negative wave of sufficient magnitude to affect the proper working of an x-ray tube. In order not only to reduce this to a minimum, but also to utilize the suppressed wave, the expedient is adopted of connecting four such cells in series parallel.

See figure 15. The resulting wave is then of a pulsatory character.

Meyer and others have further increased the efficiency of the appa-

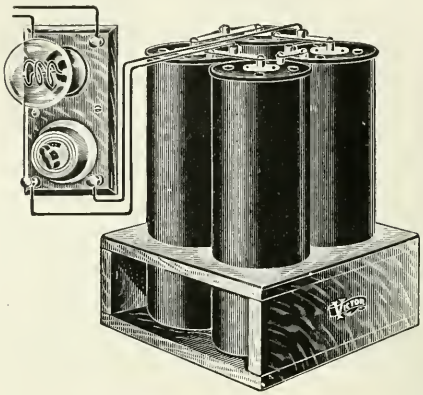

Fig. 15.

Four Cell Rectifier.



Fig. 16.

Motor Generator.

ratus by bridging a fifth cell or a condenser across the battery with the result of obtaining a current entirely free from reverse waves.

Rectifiers of the above types are not alone useful for their medical application but, when of suitable size, will serve as well for charging storage batteries for cautery or automobile purposes.

MOTORS

The electric motor is rapidly attaining an important position in the equipment of the office. In figure 16 is shown an efficient type of motor, designed to operate on the direct current. On the right hand side is shown a small pump, designed for use in producing aural massage; while, on the left, is a provision for attaching a flexible shaft for driving burrs or vibrators. A supplementary winding on the armature of this machine furnishes an alternating current for charging storage batteries or heating cautery knives and lighting

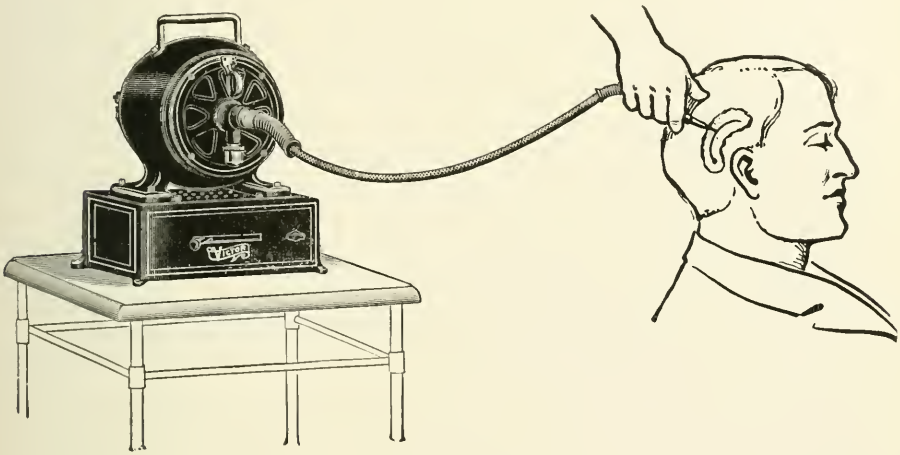

Fig. 17.

Motor as Used in Bone Surgery.

diagnostic lamps, and from it a very efficient sinusoidal current can be derived. In figure 17 is shown the motor as used in bone surgery; a flexible shaft, similar to that used on a dental engine, being used to drive the necessary drills or cutting burrs.

CHARACTERISTICS OF THE DIRECT CURRENT

The *polarity* of the direct current is constant and the current itself unidirectional. It may be interrupted by a rheotome. In paralysis, this causes stronger muscular contraction than does the uninterrupted current, but the electrolytic effect is not lessened except in amount. The amperage secured by the direct current is very high compared with the voltage used. Ten to one hundred and twenty volts applied to the body will give from two to two hundred and forty milliamperes, according to the resistance of the part.

In stating the strength of the current used, the size of the electrode is almost never mentioned; a most important omission, for the concentration of the current is directly the reverse of the area of the electrode: one of one inch square giving an intensity four times that of one two inches square.

When the intention is to secure the greatest interpolar effects on the tissues or system, this is accomplished by applying very large electrodes to the body, so as to diffuse the current over a large area, and thus avoid the painful and irritating effects which would result from condensing the same current upon a small area. Hence, abdominal electrodes, nine inches in diameter, are used in the Apostoli method of application of two hundred to two hundred and fifty milliamperes in treating uterine fibroids.

In applying the current to the eye, the writer prefers an electrode, single or binocular, two inches in diameter, of sponge-covered copper, over which is placed absorbent cotton at each treatment. A soda solution, on the electrode, will lessen the resistance to the current and not corrode the copper, as would chloride of sodium. Eye cups, containing water or a salt solution .06 per cent., make excellent electrodes, when it is desired to secure the greater effect of the current upon the cornea, by opening the lids, rather than by applying the electrode to the closed lids, as is usual. There is not so much irritation in a very sensitive cornea when the cup is used, as when a metal electrode is applied directly to the eye.

In opacity of the cornea, for example, a metal electrode (negative) with a current of one milliampere may be applied for one minute to a quiet eye without any reaction. By means of a cup, an irritable cornea may be treated with one milliampere of current with much less irritation, if any, than by the application of a metal electrode.

When the direct current is applied, in treating opacity of the vitreous, etc., the writer has abandoned the use of the cups, though they are excellent electrodes, because the contour of many orbits allows the water to escape. In treating the eye the indifferent electrode oval, two and a half by three and a half inches in size, is applied over the nucha, the eye and neck electrodes being held in position by attaching to them elastic bands with tongueless buckles and buckling each firmly.

In optic atrophy, it may be better to apply the direct current in the manner Erb does; but, of late, the writer has used only the alternating or sinusoidal current in the disease. Erb first applies electrodes to the temples for a time, then reverses the polarity of the current and continues by applying the negative to the lids and the positive

to the nucha; and, finally, the negative over the superior cervical ganglion and the positive on the nucha. Of these three the first is the most important, still, the galvanization of the sympathetic nerve has so marked an influence on the eye, it deserves also a trial. Moreover, a variety of methods may secure a more faithful attendance of the patient,—an important factor in his relief. While it is usual for a daily treatment, given for a month, to decide whether a patient can be benefited, it does not follow that a patient, unrelieved by a month's treatment, may not improve in two or three months.

Polarity of the current. In treating the eye, the cathode should, usually, be made the active pole, on account of its stimulating, liquefying and other polar effects; while, the anode is made use of when its sedative, coagulative and other polar effects are required in headache, neuralgia, and in super-vascular conditions.

Strength of current. When patients are very susceptible, and in cases which require the sedative effect of the current, the dosage should be small,—as two to seven ma. to the eye for five to seven minutes.

Duration of current and frequency of the treatment. It is customary to recommend very short treatments, to be given seldom,—twice to thrice weekly, at first,—then at longer and longer intervals.

Unless the convenience of the patient demands this, it is a waste of time, better treat them daily, and, as a rule, for twenty minutes, for a month: and, then, perhaps, give them a short rest at monthly intervals. Possibly longer seances might be still better, but, judging from the nervous symptoms produced in some patients by the trial of it the above time is wisest. When the case covers a long period of time, it is wise to completely intermit treatment occasionally.

After testing the tolerance of the patient, there seems no more reason, in most cases, for the common practice of lessening the frequency of electrical treatment,—except with the x-ray,—than there would be in prescribing an alterative or tonic drug once or twice a week instead of three times a day. In chronic cases, the writer's practice is to give treatments, with any form of electricity, daily.

THE EFFECT OF THE ELECTRIC CURRENT UPON THE EYE

Holmgren discovered, in 1881, that light, falling upon the eye, is transformed, in the retina, into an electric current. This demonstrates that a perception of light, light flashes or phosphenes may be produced by stimulating the retina with an electric current. Roosa, Loring, Hackley and others have observed that both the retinal veins and arteries are enlarged by galvanic stimulation; and Würdemann

observes that this increase in size is still more marked after vibratory massage than it is after electrical stimulation and asserts that the latter does not reach further than the papilla. The dizziness, cerebral hemorrhage and therapeutic effects on the brain, produced by a current, sufficiently demonstrate that the current does reach the brain. If it were not so, optic atrophy, which, most frequently, originates extraocularly and is a descending process, would very rarely be relieved. Experience has, fortunately, shown that sixty-six per cent

Fig. 18.

Portable Galvanic Controller. Meter. Pole Changer. Rheostat.

of these cases have been improved; and others have demonstrated it in fifty per cent. of cases.

A few neurologists deny that these cases are benefited and say that, at any rate, the benefit is only temporary. It is true that, in certain cases, there is a tendency to deterioration, but any initial improvement argues favorably for still greater possibilities by a repetition of the treatment.

THE APPLICATION AND THERAPEUTIC EFFECT OF THE GALVANIC CURRENT

When it is desired to administer to the patient the effect of the anode or cathode, the respective electrode is placed as nearly as practicable to the affected part and this is called the active electrode;

while the other is the indifferent or dispersing electrode and is usually much the larger one. The direction of the current, through the patient connected in the circuit, is always from A. the anode to B. the cathode. With moderate dosage, it is immaterial on what part of the body this latter electrode is placed. If a definite milliamperage is desired, say 5, and the electrodes are placed far from each other, it will be necessary to use a much higher voltage in order to overcome the resistance than if the electrodes are placed near each other. The therapeutic result will be the same in either case and the degree of sensation of the patient is usually the same, though there are a few exceptions. For instance, in the application of electrolysis with a single needle, with the indifferent electrode necessarily at a distance, the course of the current includes so large a distribution of the nervous system that it gives rise to uncomfortable sensations, such as dizziness or even syncope and pain; while, in the use of a bipolar needle, the current is limited almost to the region between the needles.

The writer believes that a given current, say 5 ma., produced by high voltage against a high resistance, would be more painful than the same current produced by a low voltage with a low resistance. It has been shown that a high voltage with a given current causes more pain than the same intensity of current produced by a low voltage.

The writer has also demonstrated that when 100 volts were applied to five students, of 5000 ohms resistance each, joined in the circuit and subjected thus to a current of 4 ma., each felt the same sensation as when one alone had applied to him 20 volts, with his resistance of 5000 ohms, giving the same current of 4 ma.

With an initial supply voltage of 100, each individual in the group uses up 20 volts; the same amount as each individual singly—and, consequently, receives the same milliamperage.

The fallacy of supposing that a high voltage, per se, produces more pain than a low voltage is due to the supposition that the voltage is the same throughout the circuit—which is incorrect, for no account is taken of the drop in voltage. That is,—the voltage is used up by every resistance it meets with and in direct proportion to the amount of resistance. To illustrate this:—Let the dynamo furnish 100 volts and each resistance, 1, 2, 3, 4, 5, persons or otherwise, be 5000 ohms each, the current will be $\frac{100 \text{ volts}}{5 \times 5000 \text{ ohms}} = \frac{1}{250}$ a.

$= \frac{250}{1000} = 4$ ma. in any part of the circuit.

Each of the equal five resistances of 5000 ohms will consume 1/5 of the total voltage or 20 volts: that is No. 1 will use up 20 volts, leaving 80; No. 2 uses 20 volts, leaving 60; No. 3 uses 20, leaving 40; No. 4 uses 20, leaving 20; and No. 5 using 20 leaves zero at the negative terminal of the dynamo.

The connecting wires have so little resistance as to be neglible in the calculation.

If the initial voltage were the same in all parts of the circuit, each individual would have 100 volts and a resistance of 5000 ohms, consequently 20 ma. of current, instead of 4. Further, it is urged that at least the individual nearest the source of supply receives 100 volts. True, a hundred volts are supplied to him, but his sensation depends upon the current he receives, which depends upon the amount of voltage he uses up, which is 20.

THE TESLA APPARATUS

The Tesla coil is now in such general use that the principle of its action merits a brief description.

The apparatus devised by Tesla for the production of currents of extremely high tension consists essentially of an initial source of supply capable of giving a current of ten to thirty thousand volts; a mechanical interrupter of very rapid action; a condenser and a transformer of special design to still further raise the potential of the current. It is to this transformer to which the special name of Tesla coil is usually applied.

The particular features of the Tesla coil are two concentric solenoids, the relative windings of which are proportioned to the initial current voltage and the voltage desired. On account of the residual magnetism preventing a rapid change in the lines of force, an iron core is not used; but, instead, the diameters of the coils are such as to oppose the least resistance to an aerial path for these lines.

For moderate voltages of medical coils, air is used as the dielectric; and oil, when operating at high voltage. The reason a liquid is used in place of a solid dialetric is in order to prevent a spark passing from one coil to the other.

For medical purposes, small coils of the Tesla type are in use in connection with the static machine or x-ray coil to increase the frequencies of these machines and they are often supplied as complete equipments when high-frequency currents alone are required. Most, if not all, of the portable high-frequency machines are of the Tesla type and consist of an interrupter, a step-up transformer, a Tesla high-frequency transformer and the necessary condensers.

PHYSIOLOGICAL EFFECTS OF FARADISM

The action of the faradic current upon the central nervous system and distant organs is slight compared with that of the direct current, and the muscular contractions it produces are painful, as compared with those caused by the sinusoidal. The negative pole stimulates the sensory and motor nerves much more strongly than does the positive.

Debitat attributes the results to the local gymnastic action on the muscles, which increases muscle growth; and cites twenty treatments, of four minutes each, as increasing the weight of the femoral muscle of an animal fifty per cent., while prolonged application diminished weight, tetanized the muscles,—and, when extreme, resulted in atrophy. The tetanized muscle, when fatigued, relaxes. When the interruptions of the current exceed 10,000 per minute, the muscle is tetanized, and no longer responds to the current.

A healthy muscle contracts more readily under a faradic current than under a galvanic. In paralysis, contraction of a muscle is more readily effected by an interrupted galvanic than by a faradic current. Beard and Rockwell explain this as follows:—Muscular fibre, in disease, undergoes degeneration that makes it incapable of responding to the electric influence as rapidly as in health. Now the interruptions of the faradic current are exceedingly rapid, and they do not give the diseased muscle sufficient time to contract under its influence. The interruptions of galvanism may be made slowly, and, therefore, give the muscles time to contract.

In healthy muscles, the interruptions of the galvanic current are not made as rapidly as is necessary to bring out their full contraction; while the interruptions of the faradic current are exceedingly rapid, though no more so than the healthy muscle requires. The power of the galvanic is probably also due to its greater chemical properties; and, this, in turn, to its longer continuance of action. Trousseau caused an elevation of temperature of 4.4° C. by a treatment of ten minutes.

The stimulation, by faradism, of the voluntary and vaso-motor muscular fibres, doubtless increases the circulation, and, thereby, produces metabolic and tonic effects.

Physiological effects of the high frequency current. With the high frequency current, the patient is unconscious of any sensation or muscular contraction, the vibrations of the current being too high (above 10,000 per second) to induce sensory or motor reaction. D'Arsonval, by passing a current through a saline solution in a cylinder and find-

ing it as strong at the centre as at the periphery, demonstrated that the current does pass through the body of the patient. The trophic changes produced by the coil are greater than those produced by the static machine. (Guilleminot.) This is probably due to the greater amperage of the coil, to which ionization is proportional.



Fig. 19.

Combination Portable Englemann High Tension, the Faradic and the Galvanic —With an Automatic Rheotome—To Operate with the Direct Current.

Administered by means of the auto-condensation chair or couch, the patient receives a current of great potency without the slightest discomfort. The spark light kills all kinds of bacteria on the surface in a few minutes. The head breeze is a current of electrified air molecules. It has a very sedative action and relieves pain. The zinc plate of the couch is one coating of a condenser, the cushion is the insulator or dialectric and the patient the other coating. Local sparking causes muscular contraction, rise of blood pressure, and anemia, followed by relaxation, fall of pressure and hyperemia. D'Arsonval

says "The carbonic acid of respiration is increased one hundred per cent. and heat doubled by this current."

The weight of oxygen absorbed in the respiratory exchanges is greater than the carbonic acid eliminated,—hence, there is an increase of body weight. The ozonation of the oxygen renders it the more absorbable by the red-blood cells. D'Arsonval's experiments have shown that the amount of heat given off by the body is nearly doubled and that the current augments the quantity of urine, urea, uric acid and urine salts, and that this increase continues for several days; at the same time, there is a decrease of the non-oxidized sulphur compounds.

For treatment of eyes, head and neck, the writer has chiefly used vacuum electrodes, connected with the top of the resonator. In neuritis and neuralgia, ocular pain and headache, only the slightest fluorescence of the tube should be produced, by placing the rheostat low on the resonator, and regulating the spark-gap of the jars, while the electrode is held in place by the patient. Treatments are given daily for ten or fifteen minutes.

There is no drug or electric modality that is so certainly and so highly efficacious, in cases of this character, as is this high frequency application. Both the general and the local treatment are usually given in sequence, at the same seance, if both are indicated.

Dosage of the high-frequency current. There appears to be no limit to the tolerance of this current, if the interruptions be sufficiently high. Tesla, with his body in the circuit, lighted ten sixteen candle-power lamps, which require five amperes of current. On the contrary, with one third of an ampere, a galvanic current may kill a man.

THE COIL VERSUS THE STATIC MACHINE

For the past ten years the writer has urged the superiority of the coil, for every purpose of which the static machine is capable. The coil occupies relatively little space, requires little care, works well in all weather, and, unlike its fickle predecessor, is constant in its polarity. It also furnishes sufficient amperage to charge the electric chair or couch. The greater utility of the coil in radiography is unquestioned and it also produces greater trophic effects,—which are probably due to its higher amperage. The static machine has the advantage that any motive power can be used to run it when electrical power is not available. Treatment by the auto-condensation couch gives more rapid results than by the auto-conduction cage, which is rarely used in America.

Observations show that the virulence of toxins within the body is diminished by the use of the high-frequency current. Microbes are probably not killed, although they are inhibited and grow less rapidly.

The changes in metabolism and the increase of nutrition are probably largely due to the stimulating effect of the high vibrations, which are communicated to the trophic nerves.

Adolph Henriques, of New Orleans, writing on the *Physiological Action of High-Frequency Currents*, says: The end of the resonator is connected with a metallic electrode, usually pointed. If we project long sparks upon the skin for a prolonged time, a blister is produced, and finally, a slough is formed. If sparking occurs upon the surface of a wound, there is a discharge of serum very quickly. In two to four days, the serum thickens and becomes purulent during the elimination of the slough—if there is any. A spark of several millimeters is rapidly anesthetic; sparking at two to three centimeters, is very painful.

Effects of effluve or waves. The intensity of action of the effluve is much less marked than that caused by sparking. An aigrette or number of points is used instead of a single point. The skin and blood pressure regain their normal tone, usually in several hours, after alternating dilatation and contraction of the vessels.

Effect of condenser electrodes. These are usually of glass, within which is a cylinder of metal, acting as the internal coating of a Leyden jar. The skin represents the other coating. By induction, small sparks strike the skin. Their effect is similar to that of the effluve, but can be applied with more precision.

Direct contact with metal electrodes or variously shaped vacuum tubes. They act similarly to, but less powerfully than, the effluve. They cause vascular contraction, which is shortly followed by a hyperemia.

The therapeutic effects of the sinusoidal current. The reversal of the sinusoidal wave is so rapid that the current is practically continuous. Slow alternations of the current produce greater ionization than when they are rapid.

Guilleminot believes the ionic changes in the tissues, produced by the sinusoidal current, are comparable with those of the galvanic. The writer believes on account of the greater clinical results obtained by the sinusoidal current, as compared with the direct, in the same patient, that the ionization is greater in the sinusoidal: if we may assume the results are due to ionization.

The effect of the sinusoidal current upon the nerves of special sense. The response of a nerve to stimulation is manifested by the

character of its function. The stimulation of a motor nerve is manifested by muscular contraction. The stimulation of the optic tract is shown by the resulting light sensation—or phosphenes. The sinusoidal current, compared with others, appears to have a specially stimulating effect upon the nerves of special sense. It may be that a greater nerve vibration is produced by the rapid alternation of the electric energy.

The writer has not been able to produce light flashes with the faradic, high-frequency or static current, or with the x-ray or mechanical vibrator. The galvanic current produces, when constant, but especially when interrupted, a moderate intermittent flash, with a painful sensation. This does not compare with the constant, brilliant, variegated mosaic, painless flash produced by the sinusoidal, with the same voltage. He also believes that the alternating current stimulates more the vaso-motor circulation and, therefore, the nutrition of nerve tracts. For the above reasons, as well as for its electrolytic effect, he has used no other current since 1901 in cases of primary or secondary atrophy of the optic nerve. In a pretty extensive search of the literature of the last quarter of a century, he does not find any reference to the use of the sinusoidal current in the treatment of diseases of the eye or ear.

The stimulation of the nerve centres is due to ready conduction of the current, by the nerve fibres, to the nutritive vessels of the neurilemma and to the trophic centre,—the cell body, (neuron). Thus nerve nutrition is promoted by increased vascularity and direct cell stimulation. The functional specialization of a nerve fibre depends only upon its connection with a nerve centre. Whereas the stimulation of vibratory massage is limited to the nerve terminals, or, at most, to the nerve fibres, an electrical current stimulates the nerve centres also.

In the application of the sinusoidal current to the eyes, the writer uses the same electrodes as when treating with the direct current. The voltage tolerated by the patient at the initial treatment is a fair guide to the amount required for subsequent treatment.

The relation of magnetism to therapeutics. The consensus of opinion is that magnetism has no perceptible effect upon the organism. Scheppegrell says: "The effects of magnetism in therapeutics have been investigated by Peterson and Kennelly, who have, recently, tried it with an exceedingly strong field, and have come to the conclusion that 'the human organism is in no way, appreciably, affected by the most powerful magnets known to science.' A. E. Dolbear, of Boston, however, holds that it is not proved that magnetism is with-

out any effect on the human body, but believes that the experiments, which have been made, simply show that magnetism, unlike electricity, does not produce the mechanical and chemical changes necessary to be appreciated by the subject.''



Fig. 20.

X-Ray, Galvanic, Faradic and Sinusoidal Combination Machine.

The writer thinks that it will yet be demonstrated that magnetism has very appreciable, vital and beneficial effects upon the human body. Two effects are inseparable from every manifestation of electricity,—heat and magnetism. The effect of the heat product, in the application of electricity to the body, is palpably manifest. If

magnetic lines can induce the secondary currents which we use in the faradic wall plate, in the high-frequency and sinusoidal apparatus, it would seem only reasonable that the human body in conducting a current, should be affected by the magnetic lines given off by the current within the tissues. Many effects of the current upon the tissues are known, and it may yet be shown that magnetic lines have a large share in producing those effects.

THE X-RAY AS A THERAPEUTIC AGENT

The Roentgen ray is a stimulant, which, in moderation, causes hyperemia; and, in excess, produces necrosis. The greatest effect of the radiation is at the terminus of the penetration of the ray. The body cells are supposed to absorb the rays and fluoresce, then chemical reaction follows. Radiation increases cell growth, leucocytosis and phagocytosis. It causes the degeneration and absorption of such low resisting tissues as epithelioma, sarcoma, etc., while the higher resistance of normal tissue protects it from untoward effects.

C. E. Ochsner and others observe that exposures to x-ray at first greatly increase the vascularity of the tissues, while, under extended treatment, these become ischemic, brittle, and bleed much more freely than does normal tissue.

The factors which should govern the *dosage* of this agent are:—1. The vacuum of the tube. 2. The degree of fluorescence of the tube. 3. The distance of the patient from the tube. 4. The duration and frequency of the treatment. 5. The depth of the tissue to be treated. 6. The effects produced by the treatment.

1. The most practical and convenient way to measure the dosage, or intensity of the tube, is to measure the distance through which it forces a spark between the prime conductors of the machine. The higher the vacuum of a tube the greater is its resistance. Hence, the stronger is the current needed to overcome the resistance and the greater is the energy of the tube. A tube is low when it forces a spark from one to three inches only between the prime conductors of the machine; medium when a spark is forced from three to five inches; and high when the distance is above five inches.

2. Grubbe, alone, seems to regard this factor. He recommends a barely discernible light in the tube. When a brilliant light is reached, it will not be intensified by a large increase of the voltage; hence, the constancy of the dosage can be best secured with a faint light.

3. It is a good working rule to place the patient from one to two inches farther from the surface of the tube than the greatest distance which the tube can force a spark across the spark gap.

4. Three to ten minutes with the coil, or five to twelve with the static machine—when the raying is constant. With interrupted flashing, (Cook's method), we are in the habit of giving from five to twelve minutes treatment, during which, the tube is active only half the time. The frequency of the treatment should lessen progressively at first, daily, for one or two weeks; then, tri-weekly, etc.—as the effect is cumulative.

5. The greater the depth of the tissue to be treated, the higher must be the vacuum of the tube,—and this is indicated by the length of the spark gap. The gap may be two inches for the treatment of the lids and surface of the globe, and from three to five for intraocular and orbital treatment. The vacuum of the tube can be maintained only by placing the wire automatic regulator just beyond its sparking distance from the cathode of the tube. In use, the vacuum tends to rise, on account of the dissipation of the contents of the tube either in or through its wall, or upon the surface of the electrodes. When the rise of vacuum increases so high as to prevent the current passing through the main tube, it passes through the auxiliary tube to the tip of the regulator. This regulating discharge passes through a bunch of mica discs in the accessory tube,—heats them and liberates occluded gas which flows through the main tube, lowers its vacuum and again the current passes through it.

The vacuum can also be lowered, as desired, by connecting the cathode cord with the regulating wire and the anode cord with the anode of the tube. The vacuum is raised by connecting the anode cord with the platinum coil which is in the auxiliary chamber and which is heated, and absorbs the air in the tube.

A good focus tube should concentrate the cathode rays upon the centre of the target producing a dull spot when in action and it should be possible to raise its vacuum in five to ten minutes, and lower it in a few seconds. It should be made of glass that is free from lead. The presence of lead interferes with the transmission of the x-rays and hence, in order to interfere the least with the transmission, it is necessary to make the tube thinner and more fragile than is desirable.

6. If itching, burning, redness, swelling, pigmentation, blanching or loosening of the hairs appears, discontinue the raying until these symptoms disappear, unless dermatitis is desired.

Notwithstanding the many applications for the regulation of x-ray dosage, most operators depend upon the length of the spark gap of the exciting machine.

ELECTRIC TREATMENT OF DISEASES OF THE EYES

Blepharitis marginalis. In severe cases, the writer uses the x-ray and prefers it to other treatment. Second in efficiency he would consider the 500 c. p. lamp.

Freund and Schift obtained cures with a few exposures to a hard tube. Fox had uniformly excellent results with a high-frequency

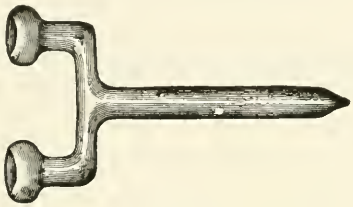

Fig. 21.

Binocular High-Frequency Vacuum Electrode.

glass vacuum electrode applied directly to the lids. He tested this treatment in one hundred cases. The electrode should be applied before the current is turned on, in order to prevent sparking, and the treatment should be continued for five to fifteen minutes daily.

Hordeolum. In several cases, Allen found that the x-ray effected a rapid disappearance of the stye.



Fig. 22.

Electrolytic Needle with Lens.

In the early stage of a stye, the writer has succeeded most effectively in aborting the process, in one or two days, by exposing the lids once or twice daily, for fifteen minutes to a 500 c. p. lamp.

Distichiasis. The removal of a displaced cilia is best accomplished by the use of an electrolysis needle. Operators differ slightly in their methods, but the following is the one the writer prefers. He wears a pair of glasses + 6.00 added to the strength of his own correction and combined with prism of 3°, base in for each eye.

A bulbous-pointed Hayes steel needle, half an inch long, is attached

to the negative pole and inserted one-eighth of an inch by the side of the hair shaft, for twenty to thirty seconds. Using a current of one ma., this will permanently destroy the growth of three-fourths of the hairs treated. Repeat the needling if the hair does not drop out readily when the forceps is used. If it is desired to prevent the pain of the operation, a two per cent. solution of cocaine in adrenalin (1 in 1,000) may be injected hypodermically along the margin of the lid.

Fig. 23.
Needle-Holder with Interrupter.

If the lids are inverted, this procedure is not applicable as it will be necessary first to correct the position of the lid by surgical operation. See, also, **Electrolysis,** in this *Encyclopedia.*

Alopecia of the eyelids. For this affection the writer has used the sinusoidal current to the lids for ten minutes tri-weekly. After four months decided improvement was seen.

Fig. 24.
Binocular Electrode.

Ectropion and entropion. See these headings in this *Encyclopedia.*

If *blepharospasm* is not relieved by correction of the refractive error, the writer treats it with either the sinusoidal current or by the application of the interrupted, direct current to the lids.

Nictitation. Positive galvanism, with a current of 3 ma. applied to the lids is very effective.

Paralysis of the orbicularis is best treated by the application of the direct, interrupted or sinusoidal current.

Eczema of the eyelids. The writer has found the application of the 500 c. p. lamp to the lids at twelve inches, for twenty minutes

tri-weekly, in sufficient intensity to produce dermatitis, effect a normal condition, usually in four seances.

Herpes ophthalmicus. For this intractable condition the positive galvanic current offers one of the most effective means of treatment.

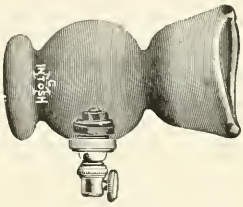

Fig. 25.

Eye Cup Electrode for Direct Current.

Nevus. This condition is variously treated by electrolysis (q. v.), the electro-cautery, the high candle power lamp and carbonic acid snow. In mild cases the light or snow is perhaps the more desirable.

Blastomycosis. The best cure for this singular disease of the skin



Fig. 26.

Multiple Electrolytic Needle.

of the eyelids, instances of which have so far been met with almost exclusively in Chicago, appears to be the local application of x-rays and massive doses of potassium iodide.

Cysts. In serous cysts, introduce the negative needle, with a cur-



Fig. 27.

Multiple Needle Holder.

rent of 5 ma., from five to ten minutes. Repeat if necessary. In large cysts a bipolar needle is preferable.

Xanthelasma. The galvanic current with either a single or double needle is recommended as the most simple and effective means of treatment.

In electrolysis of xanthoma always turn on the current slowly, increasing to maximum gradually, so as to avoid unnecessary pain.

Acute catarrhal conjunctivitis. Several cases of acute catarrhal conjunctivitis, treated by exposure to a 500 c. p. incandescent lamp, recovered in an unusually short period of four or five days; even the first treatment having afforded marked relief.

The patient lies on a couch, the face protected by a towel or asbestos paper. The eyes, open or closed, are exposed one foot from the lamp, for ten to twenty minutes. When the heat becomes unpleasant, the patient intercepts the light for a few moments with a fan.

This action of the electric lamp well illustrates the beneficial effect of the radiant energy of the incandescent lamp in an infectious disease, for, notwithstanding the statement that the supra-violet or actinic rays are filtered out or absorbed by the glass of the globe, a considerable quantity of supra-violet and other actinic rays in the spectrum penetrate the glass—sufficient to produce bactericidal effects.

A 50 c. p. incandescent lamp, held near the eye, may produce equally good results in conjunctivitis and other superficial diseases.

Chronic palpebral conjunctivitis. This may be treated either with a glass vacuum high-frequency electrode or by cupric electrolysis.

Phlyctenular conjunctivitis. This disease may be successfully treated either with the high-candle power lamp or the x-ray.

Ophthalmia neonatorum. Gonorrheal ophthalmia. These diseases have yielded to the use of sulphate of zinc on the positive electrode, and to applications of the 500 c. p. lamp.

Vernal catarrh. The x-ray treatment of this inveterate disease has proved successful in the hands both of Frank Allport and of the writer.

Tuberculosis of the lids. In all tubercular affections of the eye the x-ray appears to be more nearly a specific than any other remedial agent.

Pterygium tenuis. Horace Starkey obtained excellent results with the positive needle in several cases, using 2 ma., and repeating it. The needle is thrust at right angles under the pterygium, near the cornea and again near the canthus.

Chalazion is so easily treated surgically that the author reserves the application of electrolysis to indurations that persist.

Trachoma. The first published case of trachoma, treated by x-ray in America, was reported by the writer, in the *Chicago Elec. Soc. Journal*, Jan. 3, 1903.

In thirteen cases there was only one failure; the others showed excellent results.

An *enlarged lachrymal gland* may be reduced by electrolysis, by inserting the negative needle into the ocular lobe.

Epiphora. In simple cases, look carefully for a source of reflex irritation, especially in the nose, and if there are sensitive areas apply cupric electrolysis which may suffice without treatment of the duct.

Stricture of the lachrymal passages. Recovery from epiphora is hastened by applying the negative sponge electrode to the probe introduced for the relief of stricture. See **Electrolysis.**

Lachrymal fistula. Application of an electrolytic needle or a mild cautery to the fistula is very successful.

In *pannus* either the galvano-cautery or electrolytic peritomy will give a very satisfactory result. In trachomatous pannus it is best to use the x-ray.

Keratitis parenchymatosa. One may treat this condition successively with galvanism directly to the cornea, the x-ray, and the high candle power lamp.

Hereditary syphilitic keratitis. The treatment specially indicated is the application of a solution of potassium iodide, applied directly to the eye on the negative electrode.

In the various forms of *ulceration of the cornea,* electricity affords one of the most successful means of treatment. Three modalities may be tried in succession. First, an electrolytic needle applied directly to the ulcer; second, the use of the x-ray; third, the application of the 500 c. p. lamp.

The writer's procedure in *leucoma,* one of the most intractable ocular conditions, is as follows: First, a thorough trial of dionin; then, sub-conjunctival injection of sodium saccharate. If these fail to benefit, they are followed by a negative copper electrode applied directly to the cornea and repeated daily. If this be unsuccessful, it may be supplemented by the x-ray and, later, by the high-candle power lamp. Finally, the high-frequency effluve may be directed upon the cornea.

Of all the surgical methods of treating *keratoconus,* the galvano-cautery is the most successful. Perforation of the cornea gives the most perfect results but involves a greater risk.

The treatment of *scleritis* and *episcleritis* by means of the x-ray is generally successful. The success of application of the x-ray is probably due to the fact that the deposits in these diseases are often tubercular.

Finally, Ball (*Text Book*, p. 164) believes the application of the galvanic current to be of decided value in *herpes zoster ophthalmicus.*

Diseases of the iris and of the ciliary body. These cases may also

be treated by galvanism with a fair amount of success; also by the x-ray.

Iritis. The treatment of *acute iritis* necessitates local and internal medication and the results are extremely satisfactory. The treatment of the eye by phototherapy at the same time tends to relieve the pain and greatly accelerate the recovery. In fact the high candle-power lamp not only accelerates the recovery but in some cases the lamp alone, without medication, has brought recovery more rapidly than under drug treatment.

The writer has seen the *sequelæ of specific relapsing iritis* recover satisfactorily under galvanism, when previous, lengthened medication had failed to improve.

Serous iritis is particularly amenable to the direct current, as is also iritis with hypopyon.

While cases of *atrophic choroiditis* yield very unsatisfactorily to any treatment, the sinusoidal current has in the writer's hands been quite satisfactory.

The treatment of cataract by electricity. Perhaps in no disease of the eye is opinion so decided that only surgical intervention can relieve as in the case of cataract and in no affection of the eye is the use of electricity so discredited. But the facts are these: If the vision is equal to 20/200, the fundus of the eye healthy, and the patient in good condition physically, the treatment of cataract by the direct current sometimes results in satisfactory improvement. And when this happens the opacities of the lens—even the striæ—completely disappear.

Intraocular hemorrhage. While in intraocular hemorrhage, good results may follow medicinal treatment during the first three months, yet when the disease has become more chronic, drugs, in the writer's experience, have proven very unsatisfactory. Galvanism, on the other hand, has given complete relief after drugs had failed.

Opacities of the vitreous, of whatever origin, are, in the early months, absorbed either by the force of nature, or, still more rapidly, by hypodermic injections of pilocarpine and the administration of mercury and iodide of potassium.

After the condition has continued for a long time the writer has found treatment by the application of the direct current to be much more effective than any medication,—the result being exceedingly satisfactory in nine-tenths of the cases. Vitreous changes indicate the use of an electrolytic current, and electrolysis is the function, par excellence, of the direct current. Hence we use the direct current.

The writer believes that the alternating current is also distinctly electrolytic, though he has not yet had the opportunity to test the subject clinically in a large number of cases. Still, in some cases in which the direct current has ceased to benefit the patient, he has secured further improvement in vision by the use of the alternating current. In the application of the direct current the negative electrode is applied to the lids and the positive to the nape of the neck, with a current of three to seven ma. for twenty minutes daily: or an alternating current to the lids and neck, with a voltage of ten to twenty-five, for twenty minutes daily. Ninety per cent. of the cases treated had gratifying results.

Retinitis pigmentosa. When we consider the pathology of advanced retinitis pigmentosa,—the retina atrophied and infiltrated with pigment, and the vessels sclerosed and narrowed—it is not remarkable that so many authors leave the subject of treatment without notice or briefly dismiss it in despairing terms. But electricity may come to the rescue and offer at least sufficient improvement to warrant every oculist giving it a trial before judging a case irremediable. The modality which has been universally used is the direct current. With it the writer formerly had some success but of recent years he has used the sinusoidal current and greatly prefers it.

The high candle-power lamp also deserves special mention in this connection.

Detachment of the retina. Of all the surgical methods of treating this always serious condition the one that appeals to the writer most favorably is double puncture of the globe by the galvano-cautery. Very recently the application of the high-frequency vacuum electrode directly to the eyes has given good results.

Retinal thrombosis. The writer has not seen in literature the suggestion to treat retinal thrombosis electrically, but he has been so fortunate as to relieve one case completely and permanently, although it was of two months' standing, by the use of galvanism.

Glioma retinæ. In case the growth has not perforated the globe, enucleation is of course to be advised, but if the patient refuses an operation the X-ray should certainly be tried; and in all cases of malignant disease the X-ray should be used as an after-treatment to prevent recurrence.

Optic atrophy, whatever its variety and origin, is universally acknowledged by oculists as one of the most hopeless conditions with which they have to deal. The consensus of opinion is that it will be followed, as a rule, by blindness.

Having followed ordinary methods of treatment faithfully for sev-

eral years without having improved the vision of a single case, the writer, some years ago, having tried the application of interrupted negative galvanism to the lids—daily for four weeks—when vision improved from 20/200 to 20/40. Since that time he has not treated a case medically. Lately he used the sinusoidal current exclusively and has had satisfactorily improved vision in sixty-six per cent. of his cases.

In 1906 he reported the result of treating, with electricity only, twenty-three eyes having optic atrophy. Of these, two had only light perception. One improved and the other acquired 20/67 vision. Out of eighteen, in which there was form perception, sixty-four per cent. were improved. Four were improved sixty to one hundred and twenty-five per cent.; two, thirty per cent.; three, five hundred per cent.; one, fifteen hundred per cent.; and two, that could only count fingers, acquired reading vision. Six did not improve.

In cases of *subacute* and *chronic glaucoma,* both galvanism and the high-frequency current have improved the condition in a good percentage of cases.

As glaucoma is associated so frequently with increased arterial tension, it is quite understandable that the high-frequency current applied to the body alone, in reducing this tension, relieves the glaucoma.

It is essential in this disease to use the negative electrode to the eye, as directed. True, the negative pole is a stimulant and not indicated generally in inflammation, but in glaucoma, even acute, the chief desideratum is to diminish the density of the ocular capsule and the tension; hence, the indication to use the negative rather than the positive pole, which, while it is a sedative, also hardens tissue and thus tends to increase intraocular tension by diminishing excretion, which, in turn, promotes inflammation.

Accommodative asthenopia. While eighty to ninety per cent. of cases of asthenopia, accompanied by refractive errors and muscular inbalance, make a satisfactory recovery by correcting the refraction and exercising the muscles with prisms, a small percentage of cases remains which is not thus relieved, and to which the application of some form of electricity gives very decided relief. The writer is in the habit of applying the direct, the alternating, or the high-frequency vacuum electrode to the lids; and treating the general condition with the high-frequency condensation couch. It is difficult to say which modality gives the most relief in the greatest number of cases.

In using the direct current, apply the positive or sedative electrode to the lids, with a current of two or three ma., for five minutes daily;

and, with the alternating current, a mild application for five or ten minutes. With the high-frequency current apply the vacuum electrode, which is connected with the top of the resonator, directly to the lids, using a current which is not unpleasantly felt.

Whether *paralysis of accommodation* be due to diphtheria or other causes, if it is not relieved by suitable medication it is best treated by interrupted galvanism or the sinusoidal current.

Oculomuscular paresis and paralysis. In the writer's opinion the relative merits of the various electrical modalities in muscular paralysis are as follows: since a paralyzed muscle may respond to an interrupted galvanic current, after it has ceased to react from faradism, and, since the latter has no effect on the nerve center, he prefers the former current; but a slow sinusoidal current is still much more effective. Electricity is probably most frequently used and less required in this disease than in almost any other eye condition, since there is a great tendency in peripheral cases to disappear spontaneously or by, for instance, such indifferent treatment as hot applications; while tabetic cases disappear and relapse uninfluenced by treatment.

Ocular headache. Probably eighty per cent. of ocular headaches are completely relieved by refractive correction; ten per cent. are partially relieved; and the remaining ten are not relieved. Of the latter twenty per cent., a considerable number may be relieved by the application of different electrical modalities: the direct, the alternating or the high-frequency current applied to the eyes—and often by the X-ray or phototherapy.

The writer has succeeded in relieving *supraorbital neuralgia* most effectively by means of the high-frequency current, the pain disappearing rapidly and permanently.

In *tobacco and alcohol amblyopia*, the withdrawal of the toxic is naturally followed by improvement in vision and is often sufficient to insure recovery. Yet it is certain that the use of electricity hastens the favorable result.

Hysterical amblyopia admits of so uncertain a prognosis—a case sometimes recovering in a very brief time, and again, at the termination of many months without any treatment—that we cannot be certain that it has been benefited with treatment, electrical or otherwise. Although it is characteristic of the disease to recover suddenly without treatment, we may fairly infer, when a case has improved gradually after the use of electricity or other medication, that the favorable condition is due to the treatment. The writer believes that the

application of electricity is one of the most satisfactory procedures we possess, and he could quote many cases in proof of this contention.

In *neurasthenia* and defective metabolism the auto-condensation couch has uniformly improved the patient and given more satisfactory results than any other course of treatment.

Malignant diseases of the eye. Epitheliomas are nearly always successfully treated by fulguration, the high candlepower lamp, the X-ray and zinc cataphoresis.

Of these methods, when the growth involves a small area, the writer prefers the last, especially as one application is usually sufficient. Fulguration is preferable to the X-ray, as it is more rapid in its results and is followed by less scarring.

As is well known, a number of cases of *sarcoma* that have not yielded to repeated extirpations have been cured by exposure to the X-ray.

Concerning the treatment of *lupus*, the same advice applies as that given for the treatment of epithelioma.

In *orbital cellulitis* of so serious degree as to indicate even enucleation, the writer has had recovery, after all other treatment had failed, by exposing the eye to the X-ray and the high candlepower lamp.—(W. F. C.)

Electric lighting. See **Illumination of private and public buildings**; also **Arc lights.** See Vol. I, p. 547, of this *Encyclopedia.*

Electric lights. See Vol. I, p. 547, of this *Encyclopedia.*

Electric ophthalmia. Under the caption **Dazzling,** Vol. V, p. 3778, of this *Encyclopedia* this subject has already been to some extent considered. Many examples of ocular lesions due to the glare of electric furnaces and other high-power lights are reported in ophthalmic literature. A typical example of the latter is given by W. E. Shahan (*Jour. Mo. State Med. Assocn.*, May, 1913), who remarks that electric ophthalmia most commonly results from exposure of the eye to naked arc lights, short circuits, particularly between iron terminals, vast stretches of snow, to a less extent by mercury vapor light where glass (not quartz) tubes are used, to a practically negligible extent by metallic filament incandescent lamps such as tungsten, tantalum, etc., and almost not at all by carbon filament incandescent and petroleum lamps. Ultra-violet light is almost completely excluded by ordinary window glass and protection from it is therefore obtained by interposing a piece of glass between the eye and source of light. If the source is especially violent, a yellow or reddish tinted glass or glass of special chemical composition, such as the euphos glass of Schanz and Stockhausen, may be used.

The symptoms begin from twelve to twenty-four hours after exposure. This is a most marked characteristic of ultra-violet light burns. The symptoms are burning, stinging and scratching of lids and conjunctiva, photophobia, lachrymation, more or less diminished visual acuity, and in several cases corneal ulceration. Shahan reports the case of a man, 42 years of age, with what appeared to be a mild, conjunctival irritation. He had been awakened by a violent stinging pain in his eyes, "as if they were full of dust." He was in acute distress from it the rest of the night and tried to get relief, without avail, from application of wet towels, weak salt water, diluted witch hazel, etc. Close examination showed no loss of conjunctival or corneal substance. But ophthalmometric examination showed the usually perfectly uniform images of the mires reflected from the corneal surface to be distorted by short, choppy irregularities just about commensurate with his lessened visual acuity. His history showed that almost exactly twelve hours previous to the onset he had been sitting on the "sand-box" on the front platform of an electric street car, when the "circuit breaker" on the ceiling of the car, about five feet from his face, emitted a sharp report and blinding flash. He thought a little dust got into his eyes, but seemed to be "all right," by the time he got off the car about five or ten minutes later, and had no trouble until he was awakened by the acute onset twelve hours later. He finally recovered entirely. See, also, page 1197, Vol. II, of this *Encyclopedia*.

As Ball (*Modern Ophthalmology*, p. 514) says, exposure to flashes of electric light, during electric welding or from the short-circuiting of the current, may produce conjunctival, corneal, and retinal changes. The same changes may be found in electricians who use a strong arc light. In a few minutes, or perhaps several hours after exposure, the patient will complain of burning pain in the eyes, photophobia, blepharospasm, swelling of the lids, and perhaps reduction in vision. The pupil is strongly contracted. These symptoms are followed by a mucopurulent conjunctival discharge. Examination may show contraction of the field of vision, the presence of a small scotoma, congestion of the retinal veins, and slight haziness of the retina. Rivers saw a case in which there was exfoliation of the corneal epithelium and retinal opacity with great reduction in visual acuity. The patient's face and eyebrows were burned.

While the prognosis is usually favorable in these cases, in the severer types of injury there may be permanent reduction in visual acuity, and pain and photophobia may be of long duration. Usually rest, the wearing of dark glasses, and the use of atropin will be followed by an early

recovery. Pain in the acute stage may be relieved by the instillation of holocain and the application of cold compresses.

Le Roux and Denaud (*Archives d'Ophtal.*, June, 1908) report the case of a healthy gendarme, who had had neither syphilis nor rheumatism. He was on night duty during a violent thunderstorm, and, after a particularly vivid flash, felt sharp pricklings in his eyes and a sensation as of a foreign body in the conjunctival sacs. Everything about him at the same time *appeared* red, and this condition persisted for some two hours. The distance of the flash is not stated; there was, however, no question of the current having traversed any part of his body, for he felt no shock.

After a few hours' sleep he awoke with intense frontal headache. The next day the eyes became red and painful and all vision was abolished. The redness developed into a most acute conjunctivitis, with great chemosis, photophobia, and blepharospasm, but no secretion. The lids were red and swollen, the globes extremely tender.

During the following days the blindness remained complete, and ophthalmoscopic examination showed that the fundus reflex was completely lost from diffuse opacity of the vitreous. The irides were congested, but the pupils could be dilated by atropin. There was slight interstitial opacity of the corneæ.

Gradually the acuteness of the inflammatory attack abated and the vitreous cleared somewhat, so that in two months' time the vision of the right eye was ⅓, of the left ½; but there was still considerable photophobia. Even after a lapse of three years there remained some vitreous haze and the vision had not further improved. The optic discs and visual fields showed no changes.

Paul Knapp (*Zeitschr. f. Augenheilk.*, May, 1913) speaking of bilateral macular affections following glaring from short-circuiting, states that in this form of electric ophthalmia, visual disturbances cannot always be detected. Deterioration of sight, nebular vision and scotoma were observed, which generally disappeared after a few days. Up to the present time only one case of marked chorioretinitis from the effect of electric light had been published, by Uhthoff. Knapp reports another case. A foreman in an aluminum factory was exposed to a short circuit of at least 150,000 candle power at a distance of about 50 cm. He perceived no electric shock, but his hair and lashes were singed. He was completely "glared" (blinded) for a while, and after the gradual return of vision he noticed a yellowish semi-oval spot whose margins glittered in rainbow colors. The next day severe burning and lachrymation, the well-known electric ophthalmia, set in and lasted for two days. Then he resumed his work, but still saw the yellow spots.

A week later he complained of metamorphopsia. Knapp, six weeks after the accident, says he found V ½, Jaeger 2 laboriously, marked metamorphopsia. Below the macula was a semi-oval chorioretinitic focus, ¾ disc diameters wide, which in every respect was identical in each eye, of dirty-yellow ground with three large pigment accumulations and numerous smaller ones, between which lay whitish and yellowish dots. There was only a slight scotoma of indistinctness for white and colors directly above the point of fixation. The treatment consisted in subconjunctival injections of a solution of salt 4 per cent and iodide of sodium 2 per cent; complete eventual recovery with V=1, and disappearance of the scotoma. Very interesting was the fact that the shape of the flame was directly photographed on the fundus. The lower half of it was completely covered, so that only its upper segment was visible, hence the semi-oval focus. The exposure lasted only for a fraction of a second, so that the eyes had no time to escape, and an "instantaneous photograph" resulted. Knapp ascribes the lesion more to the luminous than to the ultraviolet rays, because we know that the ultraviolet rays injure more the inner retinal layers, the luminous chiefly the choroid, pigment epithelium and exterior layers of the retina. The metamorphopsia probably was caused by the inflammatory reaction in the injured parts.

Eight cases of electric ophthalmia observed by Coullaud (*Arch. d'ophtal.*, p. 608, 1910) had been exposed for periods varying from a few minutes to three-quarters of an hour from one-half to two meters distance to a brilliant voltaic arc generated by a current of 550 volts from two large copper cables 84 cm. in diameter, which had been accidentally short-circuited. After a period of incubation lasting from seven and one-half to twenty hours, irritative symptoms with conjunctival congestion appeared, followed by disturbance of vision in those most exposed; the latter presented slight hyperemia of the fundus; recovery was complete in a few days. Heat rays were not an element in these cases for none experienced the slightest sensation of heat during exposure, nor were there any burns of the skin. The affection appears to have been due either to the actinic or violet and ultra-violet radiations. In Ayres' (*Am. Jour. of Ophthal.*, p. 105, 1910) case after a stroke of lightning the lids were red, swollen, and edematous, and the upper half of the cornea hazy. A month later recovery was complete. Paton (*Tr. Ophth. Soc. U. K.* xxix, p. 37, 1910) reports a case in which vision, previously good, deteriorated rapidly after exposures to the *x*-ray for lupus; the posterior polar cataract was found. Alphonse has reported an experimental study of the action of Roentgen rays on the lens.

Finally, M. F. Terrien (*La Presse Médicale*, March 6, 1912) gives a full account of the visual defects and ocular symptoms produced by electricity in general.

Electric ophthalmoscope. This important subject will be further discussed under the general heading **Ophthalmoscope** as well as under **Examination of the eye.** Here it may be said that the difficulty of keeping the pupil of the subject red with every position of the mirror and with varying distances, etc., i. e., so as "not to lose the light," largely disappears when the electric ophthalmoscope is used. The source of light is a small incandescent lamp attached to the mirror itself, which needs no reflector.

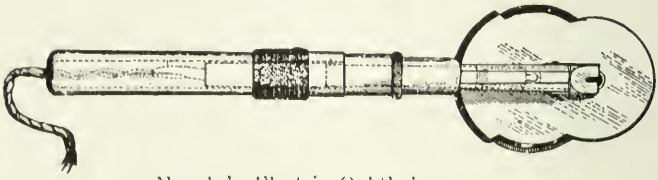

Marple's Electric Ophthalmoscope.

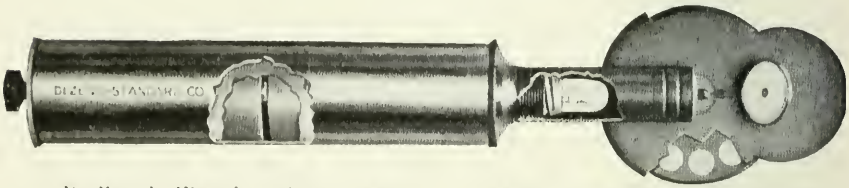

De Zeng's Electric Ophthalmoscope. The battery is carried in the handle.

The illuminating power of electricity has been adapted to several of the ordinary instruments of examination. The first to attempt it with the ophthalmoscope was Dennett, of New York. He had a small electric light placed in the handle of the ophthalmoscope and, about an inch above it, a convex lens for collecting the light rays. A concave lens was placed just below the mirror so that the rays would be thrown on the mirror properly, but this lens was found to be unnecessary and was later removed. A plane mirror was placed in front of the aperture. At this time it was necessary to use a storage battery, and this was undoubtedly one reason why the instrument was not more universally used. It was very convenient for bedside work.

The De Zeng ophthalmoscope was constructed on similar lines. A tiny incandescent light was placed in the handle, about an inch from the level of the aperture, from which the wires ran out at the end of the handle. The disc containing the lenses was placed at one side of the handle, which latter had a lens in the end so as to cast as strong

as possible a light upward, where it was received by a mirror set at an angle of 45 degrees, through which the opening for the observer was placed.

De Zeng has recently devised, after the suggestion of G. S. Crampton, a method of illuminating the electric ophthalmoscope which does away with a special battery—in which, indeed, the battery is carried in the handle of the ophthalmoscope. This instrument is shown in the figure. A tungsten lamp of 2½ volts is used, requiring but one-sixth of an ampere. Two small dry cells, of the best quality obtainable, are placed in the handle, and it is claimed by the manufacturer that these cells will give as much service as the old six-cell pocket battery.

Marple modified Dennett's ophthalmoscope by using a U-shaped mirror and adding a slide attachment to the light so that it could be moved up and down and the distance of the light from the fundus to be examined could be altered at the observer's convenience.

Marple found that in using the ordinary mirror, the light was unsatisfactory and that if he attempted to examine anything in the lower part of the fundus, there was always a horizontal line of shadow. This was eliminated by using the U-shaped mirror. He experimented with this by covering the arms of the mirror with blackened paper, and found that whenever he did so the shadow reappeared. His ophthalmoscope was originally used with a dry-cell battery or with the street current having a rheostat interposed.

The advantages of the electric ophthalmoscope are: First, the ease with which the illumination is managed. In the ordinary reflecting ophthalmoscope the angles are difficult to master and the red reflex of the fundus disappears with the slightest false move on the observer's part. It is necessary constantly to vary the angle of the instrument, the position of the observer's head, the position of the patient's eye, and the distance of the source of light. Beginners find these points very difficult, and experience is needed to overcome them. With the electric ophthalmoscope, the illumination takes care of itself. A second advantage is that there is no bright light glaring into the eye of the observer.

In using the ophthalmoscope it is necessary for the observer to relax perfectly his own accommodation, as is well known. This is much easier to do if we keep the fellow eye open, but many find the glare of the light so embarrassing that it distracts their attention and they are forced to close the fellow eye. This is particularly the case with beginners or with those who do not use the instrument constantly, but it is also true of certain more experienced ophthalmologists. With the electric ophthalmoscope the fellow eye of the observer can always be

kept open. Again, there being no question of an angle to the rays of light, it is possible to get much closer to the pupil, and a better view is obtained through a very small pupil, and a larger field through any pupil. Further, there is not nearly the extensive loss of light with the electric that there is with the old ophthalmoscope, and the image is therefore brighter. In fact, it is claimed—and the claim seems reasonable—that there is very little loss of light. Finally, the ease with which the instrument is used in any position makes it vastly superior for fundus examination of those who are ill in bed and unable to sit up in the position usually required.

There is a small disadvantage in the U-shaped mirror, in the gap at the top, which leaves a small part of the fundus slightly shadowed, but this is unimportant as a slight turn in the instrument brings this part into view.

In the indirect method, the electric ophthalmoscope works as satisfactorily as in the direct. The ophthalmoscope is held at the usual distance and the light is pushed up until the image of the flame appears on the patient's forehead as a bar of light. Then the convex lens is interposed and a good image of the fundus is obtained.—(E. S. T.)

Electric perimeter. See **Perimeter**.

Electric resistance of the eyeball. This has been studied by Hertel (Graefe's *Archiv. f. Ophth.*, LXIX, 1, 1909) on the eyes of animals. He finds that taking a globe as a whole its resistance as compared with other organs is: Eyeball, 2,492 ohms; liver, 10,904 ohms; muscle, 5,825 ohms.

The electric conductivity of the aqueous humor he found practically equal to that of the blood serum, when correction was made for difference in albuminoid content.

Electric spud and knife-needle. A very ingenious and useful instrument has been devised by two independent observers, almost at the same time, for removing foreign bodies from the cornea and for certain other uses. The first to be published was the one of R. L. Carson on May 9, 1908. It consists of a handle five inches in length through which run the wires to a tiny incandescent condensing lamp at its end. A short distance from the end of the handle is a clamp into which is fastened a spud of sufficient length and bent at such an angle as to bring its tip into the center of the circle of light thrown by the lamp. The manufacturers later modified this form by putting the lamp on the arm, and the spud on the end of the handle, where it was fixed by a screw, so that the inconvenience of working with an angular instrument was eliminated. Albert C. Snell described a similar instrument, which is shown herewith.

These instruments can be attached to a small dry-cell battery or to the lighting current controlled by a rheostat. The advantages are so obvious as scarcely to need enumeration. Everyone is familiar with the difficulties and inconveniences involved in holding the light, focusing it properly on the cornea, separating the patient's lids, and holding the instrument in the removal of foreign bodies from the cornea, with only two hands. These convenient little appliances do away with a great deal of the difficulty, and enable the surgeon to hold the lids with the fingers of one hand while the foreign body is removed by the spud held in the other. Two forms of spud are supplied—one sharp,

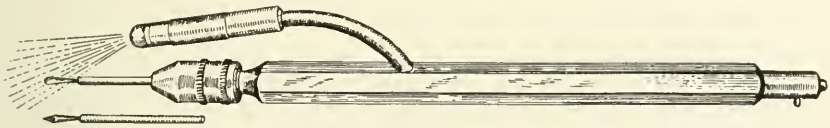

Snell's Electric Spud and Knife Needle.

the other blunt—which can be taken from the handle and sterilized. In fact, the whole handle may be boiled if necessary.

Both writers claim that the instrument can be used for needling after cataract extraction, and that it is just as convenient for that purpose as in the removal of foreign bodies.

Electro-aimant. (F.) Electro-magnet.

Electroanesthesia. Cataphoretic anesthesia. Inability to perceive the sensation made by electricity upon the skin; also local anesthesia induced by the introduction of anesthetizing substances into the tissues by means of the electric current without injury to the skin. —(Gould.)

Electro-cautery. See **Cautery, Actual,** page 1788, Vol. III, of this *Encyclopedia.*

Electro-chimique. (F.) Electro-chemical.

Electro-coagulation. Diathermy (Nagelschmidt). Destructive fulguration. W. S. Russell (*Jour. Advanced Ther.*, Jan., 1913) gives the following account of this method, which has considerable interest for ophthalmologists. Electro-coagulation is a term that has been employed by Doyen, of Paris, to designate a method in which currents of high frequency are used for destroying neoplasms by coagulation.

Nagelschmidt uses the name diathermy to indicate the same process, and also applies it to a method in which an elevation of temperature is produced in the tissues without any destructive effect.

That currents of high frequency produce an increased temperature has been known since d'Arsonval, in 1896, showed that if the current

be allowed to pass through the body there follows a decided rise of temperature in the tissue interposed between the electrodes. It remained, however, for Doyen, Nagelschmidt and other investigators to utilize this heat property in the treatment of quite a variety of diseased conditions.

The term "destructive fulguration" is sometimes applied to the ordinary high-frequency electro-cauterization employed by many surgeons and electro-therapeutists in the treatment of benign and malignant neoplasms. In this method a bipolar current, with a short spark, is utilized for "burning down" the growth. With a special apparatus a monopolar current, with long spark, as described by Rivière, may be used. The application, with various machines, of the high-frequency current, with short spark, is the method most frequently referred to as fulguration, and which is most commonly confounded with the fulguration of de Keating-Hart. It is also designated as "electro-carbonization."

Doyen had conducted a series of experiments to determine the thermal death-point of various cells, and as a result, advanced the opinion that cancer cells are much less resistant to heat than are the normal cells. By employing very sensitive thermometers, and after a number of corroborative tests, he reached the conclusion that cancer cells are destroyed by a temperature of between 50 and 55 degrees C. (122-131 degrees F.), while normal cells are resistant up to 60 degrees C. (140 degrees F.).

This claim, in the opinion of Doyen, having been established, an endeavor was made by him to find that form of heat that would meet the necessary requirement of being able to penetrate the deep tissue and at the same time to destroy the cancer cells lying therein. Hot air, superheated steam and hot water were employed, but while these agents acted most energetically upon the superficial structures, there was absolutely no effect beyond a depth of 4 to 5 millimeters, and, consequently, the use of them was abandoned.

About this time, 1907, Pozzi announced to the Academy of Medicine the use of sparks of high frequency in the treatment of superficial cancer, whereupon Doyen began the employment of this modality.

He began to study the action and effect upon cancer in deep tissues, and finally claimed that the heat produced by currents of sufficient strength causes a coagulation of the tissue and a destruction of cancer cells, even at a considerable depth, without a destruction of the normal cells at the same depth. The best results were obtained by placing the patient in contact with a metallic table connected with one extremity of the high frequency apparatus, while the other extrem-

ity was connected with the active electrode placed in an insulating handle. Later, the technic was modified, the patient being insulated in a thick rubber pad. The active electrode may be placed directly in contact with the tissue, thereby suppressing all sparks, designated by Doyen as electro-coagulation, or it may be held a distance from the part under treatment, thus allowing a shower of *very short sparks* to play upon the area under the electrode. This method is termed bipolar voltaization by Doyen. See, also, p. 3957, Vol. V of this *Encyclopedia.*

Electrodes, Ophthalmic. A large number of these devices for the application of the various forms of electricity in ophthalmic surgery

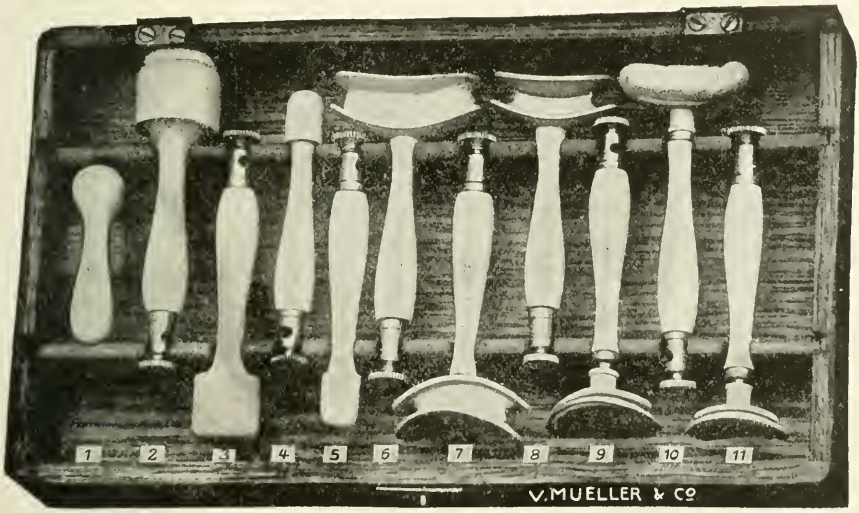

Cataphoresis Electrodes of Wirtz.

are on the market. Among them are simple instruments for the production of *electroanesthesia,* for *cataphoresis* and *electrolysis.*

Of these devices perhaps the best known are the electrodes of Wirtz. According to the inventor, these appliances are among the best for the induction of therapeutic cataphoresis. By this means many drugs may be introduced, as deeply as need be, into the ocular and orbital tissues. The cuts are self-explanatory, but it may be said that figure 1 is a small instrument for moulding the corneal electrode; figs. 2, 3, 4 and 5 are corneal electrodes; figs. 6, 7 and 8 are electrodes for the lid margins; figs. 9, 10 and 11, conjunctival electrodes. Figs. 2, 6 and 10 show the electrodes prepared for use.

The application of electrolytical electrodes demands, according to Wirtz, the right selection of the positive and negative pole; also a knowledge of the chemical composition and of the electric charge of the ions of the electrolytes is necessary. He also says that the anode drives the "cations," while the cathode introduces the "anions" into the tissues. Cations are: 1. The metal molecules of salts, such as the Na of sodium chloride, the Zn of zinc sulphide, the Cu of cuprous sulphide, etc. 2. The hydrogen of acids, such as the H of muriatic acid, etc. 3. The alkaloids.

Anions are: 1. The acid radical of salts, such as the Cl of sodium chloride, the SO_4 of sulphuric acid, the NO_3 of nitric acid, etc. 2. The hydroxyl of bases, such as the OH of sodium hydrate. 3. The organic acids.

The electrolytical solutions to be applied must be dissociated as much as possible. Solutions of ½ to 2 per cent. are most suitable.

Another important requirement for the therapeutical application of iontophoresis is the elimination of everything that influences the exchange of ions. The electrolytic solutions must be prepared with distilled water of the highest purity.

The electrode-cushion, i. e. the layers of gauze impregnated with the drugs, must be so thick that the ions at its place of contact with the metal plate cannot, during the application, penetrate into the tissues. If this be complied with and if the electrode is freshly prepared before each application, one need not have the plate of the electrode of the same metal as that contained in the electrolyte. Uniform pressure of the electrode is also required, otherwise stronger effects would arise in places of greater pressure in consequence of a better circuit, and some electrodes would even produce cauterizations.

For the local treatment of the skin and mucous membrane electrolytic electrodes are easily made.

Take 10 to 20 layers of hydrophile mull, saturated with the electrolyte, and put them evenly on the parts; then cover by an elastic metal-plate, say of tinfoil, on which an ordinary electrode is placed. The whole is fixed with a bandage. The surrounding parts are protected by some isolating material, say gutta-percha.

The *cornea-electrodes* (Fig. 1 and 2 of accompanying cut) consist of two parts, the cup *a* of celluloid and the head with the handle *b* of the same material. The cup which serves for the reception of the saturated gauze has at its top a rounded rim and in its inside a thread *d*. The head bears on its top a zinc plate *c* to which a metal pin through the handle leads, joining it to the clamp *f* of the electrode. At its out-

side the head is provided with a thread corresponding to the one in the interior of the cup.

The arrangement of the electrode for use is as follows: A small round gauze-disc consisting of from 10 to 15 layers (larger by one-half the diameter of the cup), is placed at the lower end of the cup and then pressed forward with the handle of the head through the cup till it appears in the form of a tip at the upper opening of the cup, *g*. Then the head is screwed on and the gauze saturated. The electrode is made ready for use by means of a little instrument the shape of a

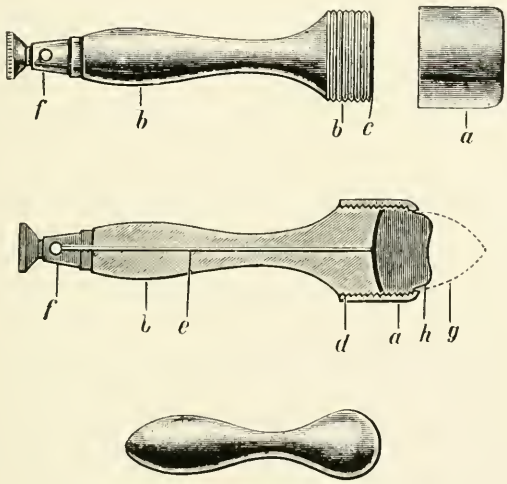

Cornea Electrodes. (Wirtz.)

pipe-filler (Fig. 3), consisting of a handle and a globular head. With this head the protruding damp gauze-cushion is then indented and moulded to the form of the cornea, *h*. Success in this moulding depends on the softness of the gauze, as well as the size and thickness of the gauze-disc.

The *conjunctival-electrodes* must be of such a kind that the eyeball is safe from the effects of the current while the conjunctiva, especially the transition folds are exposed to the current and the electrodes are enabled to adapt themselves uniformly.

The conjunctival-electrodes consist of 4 loose parts: The protecting-plate *a* for the eyeball formed concavely in conformity with the superficies of the eyeball, the metal-cup *b*, bearing the electrode, the small protecting-cup *c* for the eyelid rim, the handle *d* with screw-plug *e* and clamp *h*. The protecting cups and the handle are of celluloid. All the cups have tubular lengthening-pieces fitting into one another and of

the same material. The lengthening-piece of the protecting-cup for the eyeball is provided in its interior with a thread *f* into which the screw-plug of the handle sits.

For use the electrode is covered with gauze saturated with drugs. About 10 layers of gauze with a covering of unglazed paper are cut to the oval form of the metal plate, but a little larger and perforated in the centre; then they are drawn over the metal-plate. The projecting rim is bent inwards; the protecting cup for the eye is pressed on from the inside, the protecting lid-rim cup from above and thus the gauze fixed. The individual parts are connected with one another by the screw-plug of the handle. The latter is screwed into the thread of the protecting-plate for the eyeball till its head presses against the metal tubular shoulder of the metal plate. The electrode is now ready for use, the current can pass through the handle to the metal plate and through the electrolyte into the conjunctiva.

The surface of the gauze *g* which acts as electrifier corresponds in shape to the conjunctiva of the lids and the transitional duplicatures, the lower protecting-plate corresponds to the surface of the eyeball and the upper one to the eyelid slit, i. e., the eyelid rims. The electrode has a thickness of a few millimeters only.

Electrodes for the lid margins consist (see the cuts) of four parts joined to each other: The protecting cup for the eye, a zinc flange, a small cup and a handle with screw-clamp; cup and handle are of celluloid; the handle is again traversed by a metal rod connecting the zinc ledge with the screw-clamp. For use the zinc flange which corresponds to the eyelid rims is enveloped in gauze saturated with drugs.

When using the eye-electrodes, all the precautions mentioned above for the employment of electrolytical electrodes in general must be considered first of all. But a series of special precautionary measures is still to be added. Care is to be taken with the electrolytes to be employed on the eyes that they are not by themselves injurious at the concentration in question. Then, whenever the conjunctival-sac is treated the secretion of tears must be taken into consideration. The sac contains as electrolyte the lachrymal fluid, which on account of its principal constituent, sodium chloride, may be considered equal to a solution of sodium chloride. With regard to iontophoresis of the cornea this may be left out of consideration because only small quantities are present, but it collects in sufficient quantity at iontophoresis of the conjunctiva, partly owing to mechanical irritation due to the electrode, and partly in consequence of the very active ions employed for affections of the conjunctiva, that it has to be taken into particular consideration in order to obtain the desired effects. By a combination of the

ions of sodium which are rather indifferent to the conjunctiva, say, with the ions of zinc of the electrode, the effect will turn out to be much smaller with the same strengths of current in a given time than when pure ions of zinc are employed. This may be regulated by changing the strength of the current and the time of treatment according to the individual lachrymal secretion.

Besides the lachrymal secretion another electrolyte must be taken into consideration in the therapy of the ophthalmic ions which must always be introduced into the conjunctiva, before the electrode is

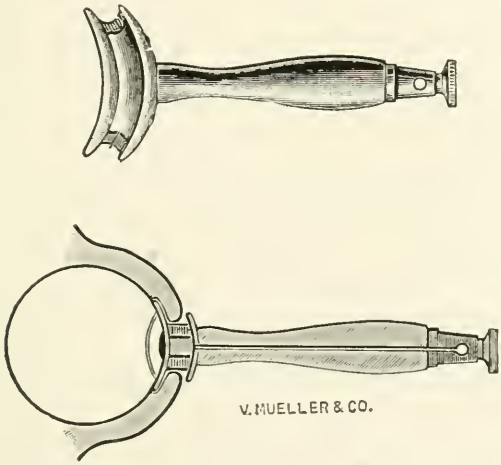

Cataphoresis Electrodes for the Orbital Margins. (Wirtz.)

used, viz., the cocaine. As will be seen below, the irons of cocaine are very active on the cornea; they are cations. If cations are driven into the eye a few minutes must elapse and the conjunctiva bag must be well rinsed out after cocainizing and before electrification. The remaining quantity of cocaine has been found to be of no further consideration.

The cornea is best treated in the following manner. The eye is anesthetized, the patient being placed on a couch. The operator sits down beside him, places the indifferent electrode in his hand and tells him to press it against the bend of the other arm. The eye to be treated is kept open by a lid-holder. Then the electrode is placed lightly on the cornea. The cornea can easily be held fast by slight pressure. With some practice one can watch the chronometer, the galvanometer and the cornea and regulate the current at the same time.

When treating small circumscribed centers of disease with electrodes III and IV the eye must sometimes be held fast with fixation forceps.

If the finest gauze has been chosen as the uppermost layer the cornea does not show injury of the epithelium after treatment with indifferent electrodes. In spite of this Wirtz, in every case, puts on a light protecting dressing for twelve hours.

The conjunctiva is best treated when the patient is seated. The introduction of the electrode is extremely easy after anesthetizing, nor is it in any way painful for the patient. The upper lid is turned up, the upper edge of the electrode is placed on the upper edge of the tarsus and the upper lid turned back on the upper folds. If the

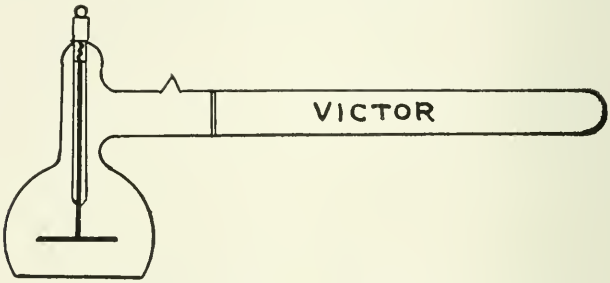

Morton's Cataphoric Electrode.

patient is now requested to look upwards, the lower half of the electrode may easily be placed behind the lower lid and into the lower cul-de-sac by bending the handle of the electrode a little more downwards. By drawing in the electrode a little, the active surface of the gauze fits smoothly and elastically to the conjunctiva of the lids and to the transitional duplicatures; thereby the bulbus behind the protecting-cup may be removed freely to every side. To conform to different sizes of the conjunctival sacs 3 sizes of this electrode were constructed.

After use the celluloid parts of the electrodes that touch any infective material must be disinfected. As celluloid will not stand sterilizing by heat, the electrodes are to be put for 1 hour into a 1 per cent solution of hydrarg. oxyzyanat., and afterwards into distilled water, where they remain till they are again used. Before using they must be rinsed in the electrolytes to be applied.

Morton's high potential, high frequency cataphoric electrode is said to secure the introduction into the living tissues of any medicament by means of the electric pressure and directional flow of high potential

current. The author states the results may also be due to anaphoric action.

Medicaments thus used may be detected quickly in the patient's saliva, blood and urine.

Soule's eye electrode is a massage cup combining high frequency and vibrator massage treatment: "There are two vacuums; a low for inflammatory, and high for nerve involvement."

See, also, page 1438, Vol. II, of this *Encyclopedia.*

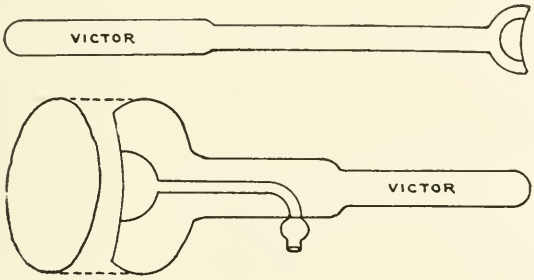

Soule's Eye Electrode.

Electro-endoscopy. Endoscopy with electrical illumination.

Electrolysis. CATAPHORESIS. ELECTROCOAGULATION. Chemical decomposition accomplished by means of electricity; in medicine, the removal (resolution of destruction) of tumors, exudates, superfluous or morbific hairs, etc., by means of electricity.

Electric decomposition of the tissues has occupied a singular position in ophthalmic surgery. It has its earnest advocates, who report excellent results from time to time, but the great majority of practitioners, from whatever cause, use it but little. And yet the apparatus is relatively simple. A continous current of 2 to 10 milliamperes is necessary, with a positive electrode fitted with a sponge, while the negative carries the needle, or whatever form of instrument may be required.

As early as 1873, electrolysis was used in general surgery, and various conditions of the eye have been treated by its means since that date. Probably the first, and certainly one of the most important uses, is the method for removal of the hair follicles. This procedure is adapted chiefly to cases where only a few hairs are to be dealt with, as in distichiasis, where the lashes grow inward toward the cornea in small groups or singly and where the greater number of the hairs are unchanged. Such conditions are found principally in local disease of the lids which, occurring near the hair follicles, diverts them from

their proper course, as in the milder forms of trachoma, certain forms of chalazia, etc. At times no cause can be assigned for the eccentric growth. Epilation is most commonly practised, but is rather productive of ultimate difficulties than otherwise, as the hairs grow constantly and are apt to become smaller and more difficult to remove in the course of time, though little less irritating to the cornea. Electrolysis offers us the only sure means of destroying the hairs without excessive scarring. Michel, in 1875, described several methods for this purpose, the final one of which is practically the method of today. In 1869 he devised a cautery which consisted of a platinum point ⅜ of an inch in length and of the thickness of a No. 8 sewing needle. This was made white-hot by the passage of an electric current and then plunged into the hair root. Considerable reaction followed, although the method was successful. His next plan was to cauterize with silver. In a small platinum cup, or silver spoon, a piece of nitrate of silver was fused and the end of a sewing needle was warmed and dipped into the silver so as to coat the needle for about ¼ of an inch. The hair follicle was then split to its base with a broad-pointed knife-needle, and after the bleeding had been stopped the needle bearing the silver was inserted into the root of the follicle and twirled around so as to thoroughly destroy the hair root. This method also was frequently followed by reaction and scarring. His final method, as described and adapted by Beard, is shown in the cut. An electric outfit capable of furnishing a current of 5 milliamperes is required. The negative electrode is furnished with a fine, sharp needle of gold or platinum; the positive, with a sponge which is kept wet with salt solution. The best means of determining whether or not the current is ready for use is to immerse the two poles in a bowl of water and gradually turn on the current until the needle throws off a stream of tiny bubbles, indicating the decomposition of the water. The apparatus is then ready for use. Beard advises that the operator wear strong convex lenses or the binocular stereoscopic loupe in order to bring the hair orifice plainly into view. The patient is placed upon the operating table and the lid is held by some suitable forceps (in the cut, the Beard forceps). The needle is then pushed down alongside of the hair until the point is well within the follicle (three to four millimetres), and the sponge electrode, wet with salt solution, is applied to the adjacent temple or to the opposite cheek. As soon as the boiling up of gas around the needle occurs, the sponge is lifted, the needle is withdrawn, and the hair is lifted out. The hair should come out easily and without any traction; if such occurs, it is a sign that the destruction of the root has been incomplete. Jourdan, of Frankfort am

Main, suggests that the needle be dipped into shellac and then a small portion of the end uncovered by scraping. This protects the sensitive skin, lessens the pain, and renders less likely the formation of punctiform scars.

Xanthelasma was first treated by electrolysis by Wende and later by Kellogg and by Leplat, of Liege, all of whom have reported good results. Pansier, of Avignon, reports satisfactory results after five

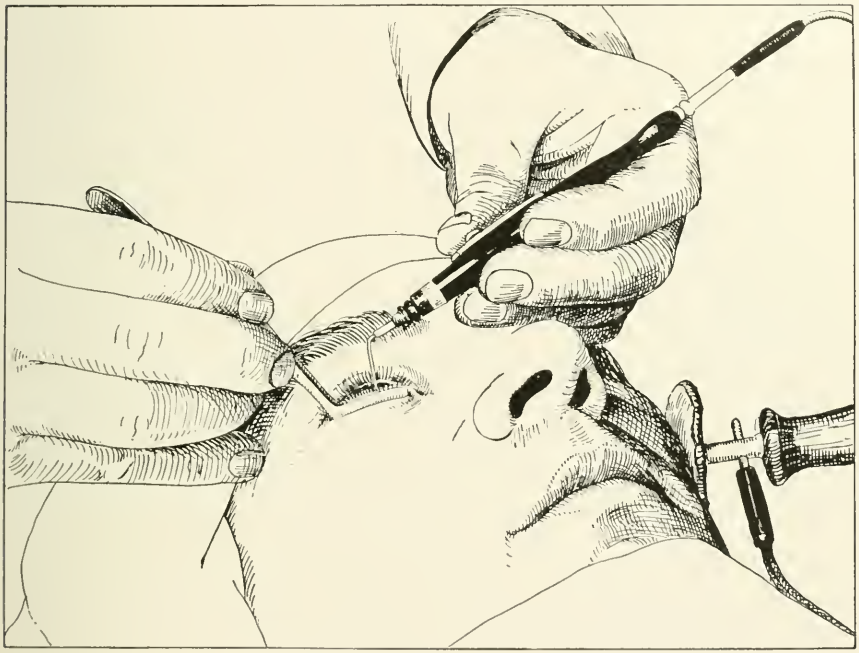

Electrolysis of the Cilia. (Beard.)

years' use of the method. He punctures the xanthelasma with the negative needle and passes a curent of 6 to 10 milliamperes through it for two or three minutes. The number of treatments varies with the case. Generally in four or five days there are only a few small nodules left. Pansier believes it is better to wait twelve or fifteen days between treatments. To diminish the pain, which, however, is not very great, he advises rubbing on, a few minutes before the treatment, an ointment of menthol, chloral hydrate, of each, 3.00; lanolin, 6.00.

Neiden reports good results from electrolysis in a case of angioma of the lid. Fuchs also indorses this method of treatment.

Electrolysis has also been used for the destruction of trachoma follicles and other conjunctival conditions, but has not found many advocates. Starkey recommends it for the treatment of pterygium.

Of real importance is the treatment of lachrymal stricture. Lagrange has advocated the method and described it in detail. A specially-shaped stylet is attached to the negative wire, while to the positive is attached a sponge or mass of cotton soaked in salt solution. The positive sponge is placed in the nostril of the same side, so that during the treatment the two poles are only about 2 cm. distant from each other. The upper part of the stylet is covered with a non-conducting material, while the lower part is bare so as to be in direct contact with the mucous membrane of the nasal duct. The intensity of the current is gradually increased up to 5 milliamperes, remains there for a few minutes, and is gradually diminished. The entire time of the passage of the current should not exceed five minutes. The proceeding is not particularly painful, and is repeated two or three times, as may be necessary. The lachrymal-nasal duct is washed out with an antiseptic solution every two days following, and "not rarely" the cure is obtained from one treatment. The action of the electric sound has the advantage of being germicidal, which makes the proceeding so much the safer. Beard commends the method and says that "the toughest strictures seem to melt like wax before the electrically charged sound."—(E. S. T.)

See, also, **Electrodes, Ophthalmic**; also Vol. II, p. 1438, of this *Encyclopedia.*

C. S. Neiswanger also explains that in cataphoresis the medicament is introduced into the tissues and circulation by means of the direct current. He further states that misleading statements have appeared in literature regarding this process, the principal one being that because the movement of a direct current is from the positive to the negative, all medicines must be placed upon the positive electrode so as to be forced or pushed along in the direction of the current.

Cataphoresis, however, is an electrolytic process, following closely the law of electrolysis, and whenever suitable medicine is placed upon either pole of a galvanic battery, that medicine is decomposed or broken up into its elements or ions. These ions, then, having an affinity for one or the other pole of the battery, the selection of the active pole would depend upon which part of the medicament we wish to use. Suppose, for instance, we have a solution of lithium citrate on one of the poles of an acting galvanic battery, the current in passing through the solution breaks it up into lithium and citric acid. The lithium or base has a strong affinity for and moves toward the

negative pole, while the citric acid has just as strong affinity for the positive. It becomes evident at once to the most casual observer, that if it is desired to utilize the lithium as the medicament it must be placed upon the positive pole because it is repelled by that pole, and, in seeking its affinity, the negative—which is on some other part of the body—it is carried deeply into the tissues, the depth depending upon the amperage employed and the length of time it is allowed to flow. If, however, the solution be placed on the positive electrode for the purpose of utilizing the lithium or base, as described above, the citric acid, having no affinity for the negative, will remain at or upon the positive electrode and not penetrate the tissues.

It is not hard to formulate a rule to govern us as to these cataphoric applications, because the substances used for this purpose are what we might call binary compounds, or those composed of a base and an acid. If it were kept in mind that all bases, whether metallic or alkaloidal, have an affinity for the negative and are repelled by the positive, and that the acid, or that which takes its place, has just as strong affinity for the positive and is repelled by the negative, then the rule would be stated as follows: If we wish to utilize the base, the medicament should be placed on the positive pole, but if it is the acid that is desired we must use it from the negative pole.

A few practical applications will serve to illustrate the rule. Suppose we are treating a case of indolent goitre and wish to utilize the resolvent properties of iodin. We will use a solution of potassium iodide—any strength—in which the potassium is the base and the iodin takes the place of the acid. It is evident that the solution must be used upon the negative pole because the iodin is repelled by that pole and taken, in a minutely subdivided and nascent state, into the enlarged gland.

In treating these cases, especially where the enlarged gland is hard, and it is desirable to gain time, the writer often uses, hypodermically, dilute Lugol's solution, which is diffused by leaving the hypodermic needle in place and using it as the negative electrode. For this purpose it is only necessary to take an all metal hypodermic syringe and solder on it a receptacle for the cord tip. Such an electrode is also valuable for the painless removal of growths, by first injecting into them a drop or so of solution of cocaine, and, without removing the needle, which is attached to the negative pole, turn on sufficient current to decompose the growth without causing the patient any appreciable pain.

We can produce the most profound local anesthesia, through the skin, by using solution of cocain cataphorically and do minor sur-

gical work, such as the removal of small growths, or the incision of an abscess, without pain to the patient.

As mentioned, electrolysis has also been successfully employed in the treatment of trachoma and in neoplasms. Lindsay Johnson (*Archives of Ophthalm.* Vol. XIX, p. 264, 1890) has devised a method of electrolysis in the former, after preliminary scarification. The details of this operation will be readily understood from the author's description as follows: The patient being placed under a general anesthetic, the upper lid is everted over the end of the vuleanite spatula, and the conjunctiva kept tightly stretched over it by means of the double hook. See the figures.

This should be inserted close to the free edge of the mucous membrane of the eyelid. The hook and spatula should now be firmly held between the finger and thumb of the left hand, while the three bladed scalpel, or "sillonneur" is taken in the right hand. This should be held tightly like a pen, and the movable guard adjusted to a distance

Hook for Holding Eyelid when Everted. (Lindsay Johnson.)

of 2 mm., 3 mm. or 4 mm. from the tip, according to the looseness of the conjunctiva, the edema of the papillæ, and the general appearance of the lid—in other words, the more succulent the mucosa, or the larger and thicker the papillæ, and the more swollen and congested the parts generally, the deeper must be the incision. The incisions are best made parellel to the edge of the lid in a gentle curve, the first incision being made close to the edge and the others following in regular succession towards the retrotarsal fold. About fifty small tufts of absorbent cotton-wool, previously dipped in an aqueous solution of boric acid or hydronaphthol 1:100, and then squeezed nearly dry, to be kept in readiness by the assistant, who should rapidly mop up the blood in the track of the sillonneur (three-bladed scalpel).

Having made a complete cut from corner to corner with the sillonneur, the next incision must be made in the track of the first, i. e., the first blade of the sillonneur must run in the groove made by the third blade of the previous cut. The cuts must be made by a finger and not by hand motion, otherwise the cuts will not reach the further side of the lid. After several cuts have been made in this way, the hook must be released and reinserted farther away from the free edge, so as to put the swollen retrotarsal fold on the stretch. The cuts are to be continued several times in this manner, and the hook is to be rein-

serted at the posterior border of the cartilage, so as to get the whole of the retrotarsal fold over the end of the spatula; by this means the whole of the conjunctiva nearly up to the bulb can be incised. The bleeding is sometimes excessive, but can always be controlled by firm pressure with the cotton pads on the conjunctiva.

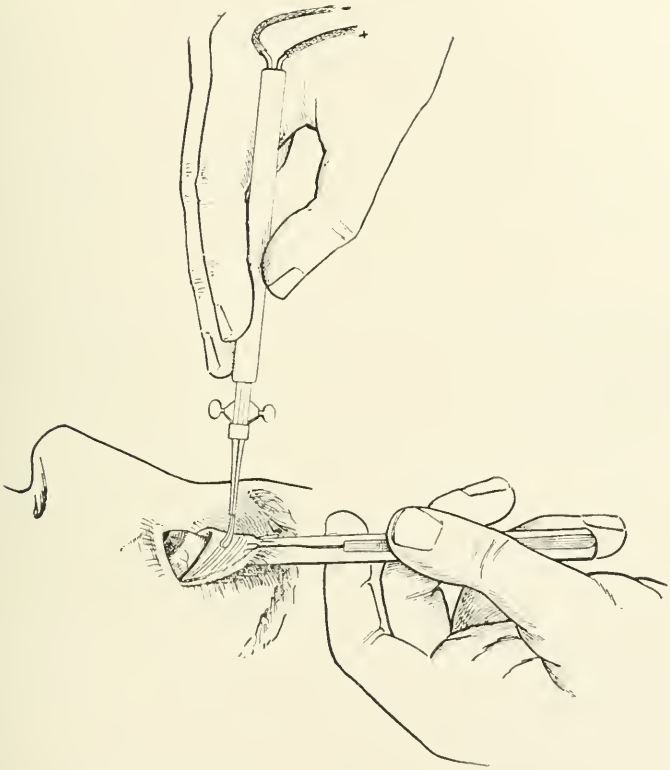

Horn or Celluloid Spatula, Laid on the Upper (or Lower) Rim of the Orbit, the Everted Lid Over it and Held by the Double Hook. (Lindsay Johnson.)

It is generally advisable to operate on both upper lids one day and both lower lids a few days later, as it is rare to find only one eye affected, and were both lids of one eye operated on the same day the inflammation set up might be excessive.

This part of the operation ought not to take more than three minutes for each lid.

Second stage. The spatula being held under the everted lid as before, and the hook reinserted in its first position near the free margin, the electrolyser (see the figures) is now connected by wires

with a battery. Johnson uses a Stöhrer's carbon and zinc battery of twenty cells. The instrument being held in the right hand, the lower edges of the two platinum blades are pressed firmly in the first two grooves made by the sillonneur and very slowly drawn along the furrows from end to end. About four or six cells (equal about thirty milliamperes) are used, and if in good working order the result will be at once seen by the thick foamy cream which rises round the blades. This is due to bubbles of hydrogen which are given off at the terminals (the platinum blades), and which, mixing with the blood and exudation, form the yellowish-looking froth. All the grooves are taken in turn, being slowly opened up along the lid from end to end.

Frequently the spatula will have to be shifted to enable the lid to be put well on the stretch and to allow of the platinum blades reaching well into the corners. The foam all the time must be rapidly



Spatula Curved so as to Rest Against the Upper Surface of the Lid.

and repeatedly sponged away, and especially from around and between the blades. This stage of the operation takes about eight or nine minutes for each lid, as the blades have to be drawn through all the furrows very slowly from the free edge of the lid to the last incision made with the knife. It will be found that the electrolytic action tends to stop the bleeding rapidly, so no fear of after hemorrhage need be entertained.

Strong electrolytic currents should be avoided. The writer finds that from four to six cells give the most satisfactory results.

Should the retrotarsal fold be very loose and much thickened, it may at this juncture be found advisable to dissect out a narrow strip of conjunctiva along the whole length of the fold. This may be hooked up by means of Galezowski's double forceps, or the ordinary fixation forceps. Unless the conjunctiva be very loose, it is best not to remove the strip of conjunctiva, or at least only to remove a very narrow one —1 mm. or 1½ mm.—else too much of the fold may be picked up, and the movements of the eye ball, if not limited, at any rate slightly disfigured by an ugly fold, when the eyes are rolled upwards. This, of course, can only happen in the case of the lower lid, as the upper one overlaps too much to render any fold visible without everting the

lid. But in the majority of cases the incisions made with the sillonneur will be found to do all that is necessary both for opening up the hiding-places of the follicles which crowd the recesses of the fold, and for cutting off the supply of blood from the vessels which help to produce the pannus. Johnson rarely finds it necessary to cut this strip away from the lower lid, and he uses it exceptionally in the case of the upper one.

Last stage of the operation. Both lids are now washed free from blood, sprinkled with a 5 per cent. cocain solution and dusted with calomel. Finally they are smeared over with an ointment made of vaseline and hydronaphthol, 1 to 800, and the eye bandaged up with thick, moistened compresses. Should the inflammation during the next twenty-four hours be at all severe, which may be judged by the swelling of the eyelids, ice compresses are applied and frequently changed.

For forty-eight hours the discharge from the lids is often considerable and many of the follicles slough out, but between the second and third day a decided change for the better sets in and the wounds rapidly heal.

Formerly it was found necessary to repeat the operation on both upper and lower lids, but by using a weaker current, and at the same time using the platinum blades more thoroughly and systematically, he found one operation quite sufficient.

As soon as the wounds have healed up he washes the lids with a hot boric lotion each day, afterwards smearing them over with vaseline or hydronaphthol ointment, 1 :800. This should be continued for at least three weeks. It is not necessary to keep the patient in bed during the treatment. Great care should be taken not to touch the cornea during the operation, as rather severe ulcers and abscesses may ensue by neglecting this precaution.

Ombini (*Gazetta Medica Italiana*, 1877) is said to have been the first to use electrolysis alone in the treatment of trachoma. The method has some very enthusiastic advocates, among whom may be mentioned Malgat (*Recueil d' Ophtal.*, Feb., 1895), Coppez (*Beilageheft zur Zeitsch. für Augenhlk.*, II, 1899, p. 78) and Myers (*The Treatment of Chronic Granulations of the Eyelids by Electrolytic Action*, 1891). See, also, **Trachoma**. The latter everts the lids and applies 4 per cent. cocain directly to the point he intends to attack. An extremely sensitive granulation is anesthetized by applying the solid drug directly to it. With a current of 1½ to 2 milliamperes, a very delicate platinum electrode is plunged into the granulation, withdrawn and the coagulated material washed away with a saturated solu-



Sillonneur, or Plough, which takes the 20 or 25 milliampere current. The terminals are two blunt platinum blades which are caused to pass slowly up and down the grooves. The electrolytic action decomposes the tissues without charring them, or only slightly, preventing the wounds from healing by first intention, thus allowing the follicles to escape with the pus.

a. Two blades open to cleanse. (Lindsay Johnson.)

Handle to Hold the Blades When They are Sharpened. (Johnson.)

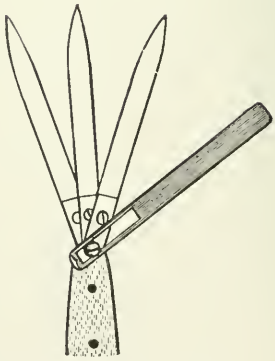

Blades Spread Apart to Clean.
(Lindsay Johnson.)

Three-bladed Knife for Making Incisions Across the Lid in Parallel Cuts, Each 1 mm. Apart. (Lindsay Johnson.)

tion of boric acid. The seances are repeated until all the granules have been similarly attacked.

Pansier (*Traité d'Electro-therapie oculaire*, 1896) has obtained improvement, but never permanent cures by this method.

Margaret A. Cleaves (*Trans. Am. Electro-Ther. Assn.*, Sept., 1903) states that thirty-seven applications of zinc electrolysis (2½ milliamperes) for two minutes at each sitting, cured a case of neglected trachoma; improvement was noticed in ten days.

Among the uses of electrolysis is that in *fistula of the cornea.* Cornwall cured such a case, in which an unfavorable prognosis had been given. The opening was situated near the corneal periphery and was so small that nearly normal tension was maintained. His procedure was as follows: The point of a jeweler's broach was bent at a right angle to the main shaft, the bent portion measuring about one millimetre in length. Under cocain anesthesia this was inserted into the fistula. The dispersing electrode was placed on the cheek. A current of the strength of ¼ milliampere was used. The bent portion of the electrode was rotated so as to describe a circle, and in this way the cornea and iris were eroded. The eye was bandaged for two days. A complete cure followed.—(J. M. B.)

Electrolysis in ocular tuberculosis will be considered under **Tuberculosis of the eye.**

Electrolysis has also been successfully employed in the treatment of *detachment of the retina.* See **Retina, Detachment of the**; in the various forms of vascular tumors of the eye, including all the varieties of *nevus* and *angioma*; in *molluscum epitheliale*; in keloid; in many palpebral skin affections and in most of the other neoplasms.

Of the new growths, *ocular cysts* have also been successfully removed by electrolysis. For example, Poissonier (*La Clinique Ophtal.*, Vol. XVII, Dec., 1911, p. 646) made use of this electrolytic procedure in a female patient, the lower part of whose iris presented a translucent tumor the size of a pea. With a small iridoplatinum needle attached to the positive pole the tumor was transfixed and a current of four milliamperes passed for two minutes. The cyst emptied itself, and the iris returned to its normal position. The next day the pain, previously constant, had disappeared, and the iris was normal. Atropin was prescribed. A week later the pain was still absent, the upper part of the pupil dilated, less in the lower part. Three months later the condition was still the same. See, also **Tumors of the eye**; **Cataphoresis,** as well as the general subject of **Electricity in ophthalmology.**

Electromagnet. As will be seen under the heading **Electricity,** this instrument is made by passing a current through a coil of insulated copper wire wound around a core of soft iron. A magnet strongly attracts iron, nickel and cobalt. Unlike poles, as N and S, attract; like poles repel each other. When an electric current passes through a wire, magnetic lines of force are always formed, which encircle the wire at right angles; and, if a magnetic needle be brought near, it will tend to place itself parallel to the lines, that is, at right angles to the current as shown in the milliampere meter.

The magnet was primarily employed in ophthalmic surgery by Dixon, in London, in 1859, although an ineffectual attempt had been made by Meyer, of Minden, as early as 1842; and there are several suggestions as to the use of the magnet for the removal of foreign

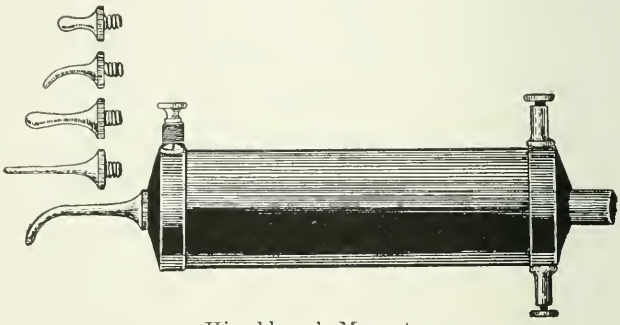

Hirschberg's Magnet.

bodies from the eye to be found in literature, the earliest of which, so far as known, is by Fabricius Hildanus in 1646. Other references are by Milhes, in 1745, Morgagni, in 1779, and by Himley, in 1843. Dixon's case had part of the blade of a pair of scissors in the vitreous, where it had been for four weeks. He used a large permanent magnet, and drew the steel close to the wall of the globe, from which point it was removed by forceps through a scleral incision. In 1874 McKeown, of Belfast, succeeded in removing a piece of steel from the vitreous and saving the eye. He used a permanent magnet eight inches long, one inch broad, and one line thick, tapering to a point at each end. He inserted the tip of the magnet into the vitreous through the scleral wound and withdrew the foreign body. The method was commended by Snell and the idea was soon taken up by many other ophthalmologists.

Hirschberg, in 1877, after some preliminary experimentation, constructed an electro-magnet consisting of a closely wrapped coil of fine, copper wire surrounding a soft iron bar, one end of which was drawn out at the point. The ends of the wire were connected with a

powerful galvanic current. This magnet, somewhat modified, has held its own and is still extensively used. It can be operated by a storage battery or in connection with the street lighting current. In connection with one zinc carbon element it will lift at its point a weight of iron of from 100 to 120 g., while with five cells as much as 575 g. can be lifted (Gruening). Several different forms of points are now constructed which are detachable and can be sterilized. This magnet has not, however, attractive force enough to influence a small foreign body unless the point is brought into direct contact with the particle, and indeed Hirschberg's original plan was to insert the tip into the interior of the globe and withdraw the foreign body on the magnet's tip.

Sulzer, in 1894, modified Hirschberg's magnet by shaping it like a horseshoe, basing his idea upon the fact that this shape gives the greatest attractive force in a permanent magnet. However, his idea has not been generally adopted.

Snell, in 1881, first published a description of his magnet, which consisted of a core of soft iron wound with copper wire, with detachable points of various shapes. It was somewhat similar to Hirschberg's.

Gruening, in 1880, described a small, permanent magnet which is at times very useful for extracting foreign bodies from the anterior chamber, or wherever they may be brought plainly into view. It consists of a number of steel rods fitted into an iron cap at each end, one of which is provided with a conical point of malleable iron. By contact with the dynamo the apparatus is made magnetic, and remains charged for about one year. The point must be brought into direct contact with the foreign body in order to exercise any attractive force.

Bradford, at about this period constructed, after considerable experimentation, a magnet consisting of a core of soft Norway iron, one-third of an inch in diameter and two and one-half inches in length. To one end of this solid cylinder was riveted a flat circular disc of the same material, one inch in diameter and one-sixteenth of an inch thick. The core was wrapped with insulated copper wire. Bradford claimed that larger magnets would offer no advantages over his model, of which the suspensive force was twenty ounces. His magnet, however, was intended to be placed in contact with the foreign body and, as he remarks, "their field is no more intense (i. e., larger magnets), and unless the foreign body is of many pounds weight they do not exert any greater force."

Hubbell, in 1884, devised a magnet of about the same size as Brad-

ford's but of greater strength. It was 3⅛ inches in length and less than ¾ inch in diameter, or 39 cm. by 17 mm. The core was not of solid iron, but was composed of small, soft iron wires twisted together around a larger central wire. The surrounding wires, or the "coil," consisted of four wires, each running from one connecting post to the tip and back again to the other connecting post. In this manner a greater attractive force was secured. It was energized by a quart, single-cell, bichromate battery. With the shortest and thickest point it would hold 31 ounces of iron.

Haab's magnet. In 1892, at the meeting of the Ophthalmological Society at Heidelberg, Haab presented his "giant" magnet, which was the most powerful form that had been produced, although the one devised by Schlosser had been manufactured a short time previously and was nearly as large as Haab's. Haab's magnet was designed to overcome the difficulty of bringing the magnet in contact with the foreign body. As is well known, the force of any electromagnet decreases rapidly as the object is removed from the center of the magnet's pole (the attraction varies inversely as the square of the distance), and this fact made it necessary to closely approximate, if not actually to touch, the tip of any of the small magnets to the foreign body. Haab's idea was to have a magnet of such strength that it would act on the foreign body, even if it should be a very small one, if the point was within an inch, or thereabouts, of the body, and thus obviate the necessity of introducing the tip into the vitreous. Indeed, his plan was to apply the magnet to the corneal center and draw the foreign body forward into the anterior chamber through the suspensory ligament of the lens, from which point it could be removed by an incision at the limbus, thus avoiding any interference with the vitreous through a scleral incision. The instrument could also be used to diagnose the presence of a foreign body. The body of the magnet is a cylinder of soft iron 10 cm. in thickness and 60 cm. in length. The cylinder is provided with a detachable conical point at each end, and is wound with a coil of copper wire at each end, the whole coil weighing 57 kilogrammes. It is supported on a wooden frame 135 cm. in height, which is on rollers, so that the position of the apparatus can be shifted at will. It is run either by a connection with a dynamo or directly from the street current of 110 volts. It is provided with a rheostat, so that the force of the current can be regulated, and has a switch so that the current can be turned on and off as required. Haab now has a switch which he controls with his foot, so that the current may be very quickly cut off should any emergency arise. The magnet, in its usual form, is set on a rotatory joint,

so that it may be turned around, and further has a joint allowing it to be tilted up and down, so that it may be easily approximated to the eye of the patient as he sits upright before it. It has also been constructed with heavy counterpoise weights, or hung on heavy chains,

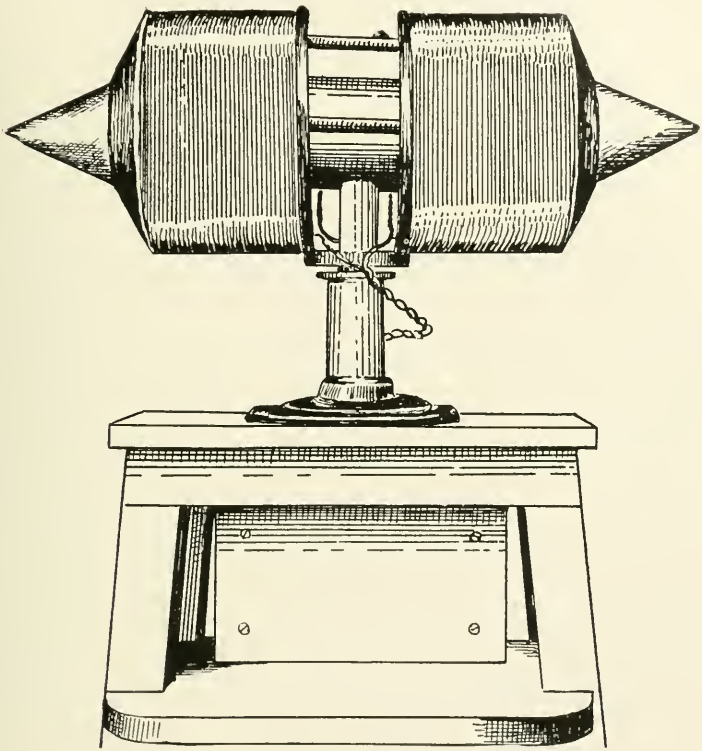

Haab's Magnet.

so that it may be used with the patient in the recumbent position on an operating table.

Schlosser's magnet was composed of a central cylinder 13 cm. long and 4 cm. in diameter, wound with a single coil of 500 turns of copper wire. It required a current of 30 volts. Later it was modified so as to be used with 110 volt current, with 20 to 30 amperes, making its force equal to Haab's model. The mounting was on an adjustable stand of wood, and a circular chin-rest was added.

Johnson, of Paterson, N. J., has devised a powerful hand magnet with internal resistance sufficient to enable it to be attached to the 110 volt current. This magnet is 7½ inches long and is wound with

single, silk-covered magnet wire, the total weight being 3 pounds, 10 ounces.

Lippincott, of Pittsburg, has also devised a magnet which is portable and more easily managed than Haab's, but is much less powerful. This magnet is 12 inches long, 2½ inches in diameter, and weighs nine pounds. It is usually suspended from the ceiling.

Mayweg has devised a magnet which is similar to that of Schlosser but has 1,000 turns of wire instead of 500, as in Schlosser's. It has a screw attachment, so that it may be easily approached to the patient's eye.

Schenkel's magnet is composed of a bar of soft iron 55 cm. in length. The poles are joined to the main bar by a sort of "ball and socket" joint, which permits free movement in any direction.

Sweet has constructed a hand magnet which he has shown by experiment to be considerably more powerful than the Hirschberg. It is 10¾ inches in length, 2½ inches in diameter, and weighs slightly over ten pounds. The core is 1½ inches in diameter, one end being rounded and the other tapped to accommodate points similar to the Hirschberg. The core, instead of being uniform in diameter, gradually tapers toward the end to which the tips are attached, being elliptical in longitudinal section, the windings of the wire at the tapered end being more numerous than at the rear portion. This method of construction was followed in the belief that there would be secured a more perfect saturation of the pole of the magnet. It is attached directly to the lighting circuit for use.

Volkmann, of Berlin, has designed a large magnet which differs materially in its construction from those already mentioned. It is composed of a very long bar of soft iron, 95 cm. in length and 5 cm. in diameter. The winding is much thicker at the end which is used for attracting the foreign body, where the diameter of the instrument is 14 cm., while at the other end the diameter is but 10 cm. This method of winding is for the purpose of concentrating the greatest magnetic force at the pole. This force being exceedingly intense and having to make a circuit to the uncovered and comparatively distant pole through a path of air, must occupy a large and elongated sphere of action of which the iron core may be said to be the center, bisecting it through its longest diameter. The circumference of this sphere of magnetic activity extends eccentrically beyond the magnetic poles, and passes close to the unwound end of the core and at an exceptionally great distance from the working pole, giving a far-reaching exhibition of attractive power at the magnet's working point. The body of the magnet is enveloped by a covering of leather and is surrounded by

a metal ring by which it is suspended, as is shown in the cut. The working pole is covered by a plate pierced in its center for the attachment of the points. There are three of these—one flat, 15 cm. in diameter, one hemispherical, and one conical. The magnet is balanced upon a rod, on the end of which is placed a movable counterpoise by means of which it can be raised or lowered at will. The suspension apparatus consists of three arms or stays which work in pivotal bearings which are screwed to the wall of the operating room.

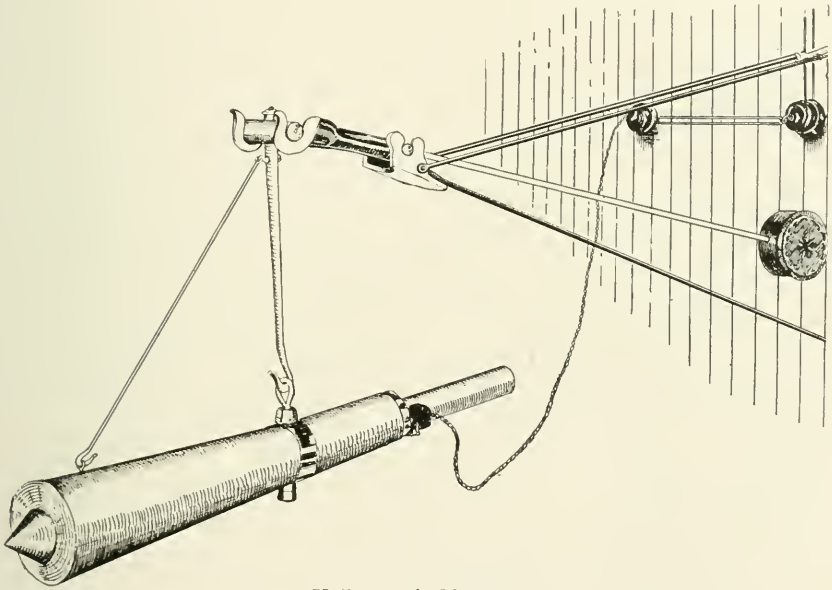

Volkmann's Magnet.

There are several sizes of these magnets, the weakest of which is for a 6 to 12 volt current, drawing 2½ amperes, while the strongest is for the 110 volt current, drawing 16 amperes.

Volkmann has modified the original form by decreasing the length of the core to 59 cm. and increasing the thickness. The core is uncovered at one end (not the "working" end) for a distance of 14 cm. The current is opened or closed by a foot interrupter. This magnet is undoubtedly a valuable instrument, although little used in America. It is enthusiastically recommended by Béal.

Mellinger has devised a magnet of peculiar shape, which is based upon the principle of solenoids or "ring-shaped" magnets. It is composed of an oval formed by a great number of turns of wire 1 mm. in diameter, which is surrounded by a broad ring of soft iron. At

Mellinger's Inner-pole Magnet, Showing Method of Use.

the lower part of the ring is a plate of ebonite upon which the hand of the operator rests. The whole is mounted upon a heavy stand, which insures steadiness. In magnets of this character the attractive force is concentrated in the line of the axis of the "ring." It follows, then, that when the patient's head is placed in the ring we have a force of great attraction at the situation of the injured eye, which is placed in the center of the ring. The operator steadies his hand on the plate of ebonite and uses a magnetized stylet to withdraw the foreign body. The ebonite plate is necessary so that the foreign body will be drawn toward the stylet, and the stylet will not be drawn into the center of the ring, towards the eye. Should the stylet prove insufficient, the ebonite plate is removed and a pole of iron in the form of a curved cone or horn is fixed to the situation of the plate, pointing directly at the injured eye. In this way a greater attractive force is secured. This latter pole is used only to detach the foreign body from a firm lodgment in the posterior part of the globe. When the foreign body presents back of the iris, the cone-shaped pole is removed and the operation is finished with the stylet, which permits of more accurate control.

Numerous other magnets have been devised, mainly on the Hirschberg and Haab plans of action, but the examples given are the more important, and it is unnecessary to reduplicate.

Comparison of the strength of large and small magnets. On account of the claims of superior excellence which have almost universally been made by the designers of magnets, some definite data of comparison in strength were early found desirable. Türk has gone over the question very carefully and has made exhaustive tests, in contrasting the Hirschberg and Haab magnets. He found in general that for splinters from 1 to 250 mg. in weight, when the splinter is in direct contact "the power of the Hirschberg magnet is but little less than that of the Haab." At 2 mm. distance from the splinter, however, the Haab magnet is from 7 to 21 times as attractive for splinters weighing 1 to 250 mg. as the Hirschberg, and the more the distance is increased the more favorable are the readings for the Haab. "Beyond 1 cm.," says Türk, "comparison is difficult, since the power of the Hirschberg magnet is so slight, but even at 2.5 cm. —approximately the sagittal diameter of the eye—the Haab magnet attracts a splinter weighing 1 mg. with 13 mg. added weight."

Barkan gives a series of tests which he performed with Hirschberg's old magnet, his later and larger size, and Haab's. He placed two particles of steel on a sheet of smooth paper and measured the

distance at which they were attracted to the magnet's point. His results were as follows:

a. Hirschberg's old magnet with chromic acid bottle element, the tip used being the finest of the set and about the same as tip No. 8, attracts particle weighing .000775 g. at ¾ cm., particle .0167 g. at ⅔ cm.

b. Hirschberg's new large magnet, with Edison current and rheostat, attracts:

	Particle .000775 g.	Particle .0167 g.
With tip 1 (largest)	at 4 cm.	at 4.5 cm.
With tip 2	at 3.015 cm.	at 4.0 cm.
With tip 9 (smallest)	at 2.25 cm.	at 2.5 cm.

c. Haab's magnet attracts particle .000775 g. at 13 cm.; particle .0167 g. at 16 cm.

Sweet tested the power of his magnet as compared with the Hirschberg and Haab magnets, and found that the Haab magnet was superior over all sizes of splinters situated 10 mm., or farther, from the magnet. When the splinter is 5 mm. distant, the drawing power of the Haab still remains greater, but the difference in power is not marked. At 2 mm. distance the advantage was with the Sweet magnet, as is shown by the following figures:

	Weight of splinter. (Grams).				
	.001	.005	.010	.020	.050
Hirschberg	.076	.275	.773	1.080	2.450
Haab	.064	3.800	5.700	11.000	25.000
Sweet	1.400	4.700	7.750	16.070	41.000

Sweet's method of measurement was to place the magnet with its long axis vertical, the splinter of steel being held in recesses in a soft piece of wood, each recess being at a measured distance from the magnet tip. The holder containing the splinter was suspended from one arm of a delicate nonmagnetic balance, the other arm carrying the weights. After the current was turned into the magnet, the weights were added until sufficient force had been added to overcome the magnet's attraction for the splinter at each given distance.

The Meyrowitz *Bulletin* (New York), gives the following comparative tests: "To obtain an exact relative comparison, we have used in this test the same method which was employed by the designer (Haab) in testing the original magnet, that is, we have attached to a piece of iron of one gram weight, a thin cord, and to the other end of this cord a receptacle in which weights are placed until the drawing capacity is exhausted. At the same time, we have interposed

between the gram weight and the point of the magnet three pieces of wood, of 3, 10, and 15 mm., respectively, and on turning on the 110 volt current the results were as follows:

Haab—

Wood 5 mm. metal 1 g. supports 337 g.
Wood 10 mm. metal 1 g. supports 173 g.
Wood 15 mm. metal 1 g. supports 105 g.

Johnson—

Wood 5 mm. metal 1 g. supports 48.5 g.
Wood 10 mm. metal 1 g. supports 20.5 g.
Wood 15 mm. metal 1 g. supports 9.5 g.

Hirschberg (with three-cell storage battery)—

Wood 5 mm. metal 1 g. supports 10.5 g.
Wood 10 mm. metal 1 g. supports 2.5 g.
Wood 15 mm. metal 1 g. no magnetic result.

Lancaster, of Boston, at the 1914 meeting of the American Medical Association, described an instrument for testing the strength of eye magnets. It consists essentially of a brass tube enclosing a spring. To one end of the spring is attached a steel bar, which serves as the test object, while at the other end there is a pin which slides along the scale as the spring is stretched, thus indicating the amount of the force used.

Taking all these results, together with the results of clinical experience, there seems to be no doubt of the great superiority of the Haab, or other large magnet, in attracting small foreign bodies at a distance of 5 mm. or more from the tip. Where the tip can be brought within 5 mm. of the foreign body, it is only necessary to use a large magnet if the particle is very small—1 mg. or less. For larger particles, or for any particle within 5 mm., the advantages of the hand magnets—Sweet's or Hirschberg's—are very great, in that they are much more easy to handle than the so-called "giant" ones.

Foreign body injuries. Before taking up the question of the magnet operation, it is necessary to speak briefly of some of the general characteristics of penetrating wounds of the eyeball with retention of a foreign body. They occur almost exclusively in workmen who, from the nature of their calling, are exposed to this kind of injury. In handling some tool which is of tempered steel, and therefore brittle, a small particle is broken off and, flying with great force, penetrates the tunics of the eye. This occurs most frequently in those who are using hammer and chisel to cut cold metal, and is naturally most frequently caused by iron or steel or some magnetizable metal—fortunately for the patient. It does, however, occur from other sub-

stances—copper, glass, shot, etc.—which, while they are important and have special bearings, are naturally not germane to the present discussion.

Copper is said by Leber to be very irritating to the tissues of the eye. Haab, on the contrary, says: "I have witnessed several cases in which copper splinters could be left in with comparatively little harm to the eye; the removal would have, at any rate, damaged the eye more than their being allowed to remain."

Alloys. At times one meets with certain alloys which decrease the magnetic power of steel to a certain degree. Sweet has investigated this question and finds that the principal ones are chromium, tungsten, nickel, and manganese. Manganese steel is considerably less magnetizable than the other forms—in fact, manganese in any considerable amount deprives steel of its magnetic properties "almost completely" (Sweet) the particles hardly more than adhere to the tip of the strongest magnet. Nickel steel is less magnetic only when large amounts of nickel are used, while the others, chromium and tungsten steel, are not markedly different from the ordinary steel.

Size and shape of foreign bodies. The size of the particles varies greatly, but it is not unusual to find them weighing as little as 5 to 10 mg. Particles of less than 2 mg. are rare, although Sweet has reported a case in which the particle measured 1½ by ¼ mm. (weight not given, but probably below 2 mg.), and Callan (discussion) said that the smallest he had ever seen weighed but 1/400 gr. (.000166 g.). Five particles selected at random, from the collection of the Manhattan Eye, Ear and Throat Hospital, measured as follows:

½x1¼ mm	0.00417 g.
1 x2 mm	0.00833 g.
2 x2 mm	0.03333 g.
2 x3 mm	0.01666 g.
2 x12 mm	0.07915 g.

and this represents about the average, as seen by the writer. Foreign bodies of 50 mg., or over, are to be classed as "large" and the contusion effects are likely to be severe.

The shape has an important bearing on both the effect and the size of the wound of entrance. Frequently the chip is a tiny sector of a sphere; at other times it is irregular; while it not infrequently happens that it is split off in the shape of a long splinter, as in the one above measuring 2x12 mm. These long splinters usually fly "end on," like an arrow, perhaps on account of air resistance, and enter the eye by a small puncture which is absolutely misleading unless one has a radiograph as a guide. It has not infrequently happened, before the

X-ray diagnosis was available, in using a "giant" magnet for diagnostic purposes, that the surgeon was surprised to find such a shaped splinter, with severe reaction to the magnet, where only a small wound of entrance could be found.

Situation. The firm outer coats of the eyeball—cornea and sclera—offer the most resistance to the entrance of a flying particle, and when once these have been penetrated, the lens alone offers any considerable obstruction. It follows, then, that by far the greater number find lodgment in the vitreous, passing easily through the comparatively spongy tissue of the iris, ciliary body, or choroid. In Sweet's series of 702 examinations there were 359 foreign bodies. Thirty-three were in the lens, 9 were in the iris or posterior chamber, 39 were in the orbit, 3 were in the lid, while 311 were in the vitreous—more than 78 per cent.

Character of the injury. If the foreign body is large, and particularly if it approaches the cubical shape, the wound of entrance, which is usually in the cornea or limbus, is more in the nature of a tear than a cut and the contusion effects are apt to be severe. There is usually considerable hemorrhage, lacerations of the uveal coat or of the lens, with perhaps detachment of the retina and prolapse of uvea or vitreous, or both, in addition to a serious wound of entrance. Infection is much more apt to occur with large particles, on account of the size and the greater degree of coolness of the body as it strikes the eye, and the shock to the eye is such that serious inflammation usually follows. Obviously these cases present very little interest to us in the present connection. The foreign body is removed through the wound of entrance by a small magnet with little difficulty, and the eye is usually lost.

In injuries by small particles, however, we have widely varying conditions which require special consideration, and in which much depends upon the technique of the removal of the particle. Small particles are apt to be sterile, or at least to have very limited powers of infection, supposedly on account of the heating which accompanies their forcible splitting from the main mass of metal. However this may be, it is no uncommon thing to find the wound of entrance closed a day after the injury, and the eye relatively free from inflammatory reaction. As is well known, the foreign body may remain encysted or surrounded by exudate, or at least adherent in its position of rest, without giving any sign of its presence for months, or even years, depending somewhat upon its location and the character of the tissue in which it lies; and to this fact is due the most complicated class of cases, i. e., cases in which the wound of entrance

has been healed for days, or even longer. In the past, before the methods of localization and removal were so well matured, the question was frequently discussed as to whether it was not wiser to allow a foreign body, that was not causing irritation, to remain, rather than risk the dangers of an operation for its removal.

A movable foreign body is always a menace, and taking into consideration the exactness of the present methods of localization and the improvements in magnet technique, the author wishes to emphatically indorse the remark of Gruening, who says: "Because of the tendency to sink and come into contact with the uvea, early extraction of freely movable bodies is advisable."

With fixed foreign bodies, lodged in some tissue which does not react to their presence, as in the retina, the question is more difficult. The dangers are those of local degeneration, at times allowing the body to become detached and movable, siderosis, and acute attacks of inflammation—even sympathetic inflammation in the fellow eye. While exceptionally these ill effects may not occur, the exceptions are few and far between, and the writer is always inclined to attempt the removal where it seems probable that the operation will not be a too formidable one.

The immediate effects of foreign body injuries, besides the entrance wound in the cornea or sclera, include wound of the iris, ciliary body, or lens, or perhaps laceration of the iris with prolapse—all in varying degrees, the severity depending on the amount of "contusion" element present in the injury. Hemorrhage is almost always present and, while infection is no less fatal than in injuries with larger particles it occurs much less frequently. However, a certain degree of plastic inflammation is the rule rather than the exception, and when the eye has escaped the immediate dangers of a penetrating wound it is no unusual thing to have a plastic irido-cyclitis come on with such severity as to lead rapidly to phthisis bulbi. If all this has been escaped, certain low degree degenerations are apt to follow as time goes on—contracting cicatrices, degeneration of the vitreous, detachment of the retina, atrophy of the globe—so that the final results are apt to bring the percentage of eyeballs saved down to a rather disappointingly low figure. Take it all in all, an injury with a foreign body in the vitreous is a very serious condition; and but few cases preserve any considerable amount of vision for long periods of time. Besides, the eye which has been wounded is in many instances a fruitful source of irritation to its fellow, even after the foreign body has been removed, during the subsequent inflammation and degeneration.

Diagnosis of the presence of a magnetic foreign body. The magnet

operation requiring detailed description is in the case of retention of a small foreign body, and what follows is written on this basis. Where a wound with a large body exists, the case is usually seen soon after the injury, the wound of entrance is still open, and all that can be done is to extract with a hand magnet with as little violence as may be. In the case of a small foreign body, where the wound of entrance is perhaps closed, the first step is to have an accurate diagnosis of the presence and size of the particle by means of the X-ray. Much stress has been laid on the time consumed by this, but it is very doubtful if the time sufficient for an X-ray examination—an hour at the most—adds materially to the gravity of the prognosis, and if we are to operate intelligently it is absolutely essential that we be correctly informed as to the location, size, shape, and general roughness of the foreign body. It has too often been demonstrated that to place the patient before a large magnet without this information is productive of some very disagreeable surprises to the surgeon. The magnet, on account of the dangers and uncertainties involved, should no longer be used as a means of diagnosis. If the foreign body should happen to be larger than has been suspected, great damage can be done by the forcible pull of the "giant" magnet. Having this information we proceed to the

Selection of the magnet. This will depend largely upon the size and location of the foreign body, although the route chosen will of necessity have some influence. Very small particles, especially if situated far back, will necessitate the use of the Haab or one of the other large magnets, while the medium or large particles should always be attacked with a small magnet first.

It is scarcely possible, as will be readily appreciated, to meet all the contingencies satisfactorily without having at one's command at least two styles of magnet—a large one, as of Haab, and a small one, as of Sweet or Hirschberg. The more gently the foreign body can be detached from the interior of the eye, the better, and it is even preferable, in the writer's opinion, to introduce a sterilized tip of a Hirschberg magnet into the vitreous, if by so doing we can extract the foreign body, than to tear the foreign body forcibly through the tissues of the eye with the large magnet. This is not to say that insertion of the tip into the vitreous is a proceeding to be advised. On the contrary, it should be avoided whenever possible (which is almost always), although it must be said that in the days when the Hirschberg magnet had to be used to explore the interior of the eye, the traumatism was undoubtedly much greater than at present when our methods of localization are exact.

If, then, we find that the foreign body is small, and especially if it lies far back in the interior of the globe, the large magnet should be selected. Haab's magnet, as before stated, is designed so that it stands upright on a framework of wood, and allows of a tilting up and down of the magnet, so as to alter its position readily. The patient then must be approached to the magnet and the operation, up to the time that the foreign body enters the anterior chamber, must be done with the patient sitting up. To meet this disadvantage, some surgeons use the magnet supported by a steel cable from a crane, with balancing counterpoise weights, so that it is carried over the operating table and the operation is done while the patient is in the recumbent position. To many surgeons, however, the writer among the number, the risk of handling an enormously heavy piece of apparatus over the patient's head and approaching it gradually to the eye seems hardly commensurate with the advantages gained. Moreover, the great disadvantage in connection with the use of the Haab magnet is the fact that as the foreign body approaches the tip the force increases enormously, just at a time when it should decrease. With the greatest possible care, the foreign body will present back of the iris with considerable force, and it is essential to be able at once to stop the dragging. Now, it is manifest that the patient, in drawing back his head as he feels the pain, will do this much more quickly than can possibly be done by an assistant at the word of command, or even by the surgeon with a foot "cut-off." If the patient is recumbent, he cannot withdraw his head at all. Again, if the patient is recumbent, when the current is cut off the foreign body is apt to slowly sink back into the vitreous, which does not happen if the patient is upright. For these reasons, it is best to follow Haab's method and operate with the patient sitting up. This is the more easily practised in that almost all these patients are workmen and bear the manipulations well. The Haab magnet is used until the foreign body has entered the anterior chamber, when, if an opening exists, the extraction may be completed. As a rule, however, it is better to place the patient in the recumbent position when the operation has reached this stage, and finish with the hand magnet of Hirschberg. If the wound of entrance is in the sclera and is still open, or if for any reason the scleral route should be chosen, the Hirschberg magnet is the better one to use, as the particle may be drawn out much more gently with the patient in the recumbent position.

The magnet operation. The eye, of course, is to be thoroughly cleansed and cocainized, the patient's head covered by a towel and steadied by an assistant, leaving the operator's hands free to manip-

ulate the lids and approach the patient's head to the tip, which is, of course, sterilized. In using the Haab magnet, several points are to be borne in mind: (1) That the attraction is directly proportional to the mass; (2) that the attraction is inversely proportional to the square of the distance; (3) that magnetization and polarization of the foreign body takes place almost immediately, or within a very short space of time.

In Haab's earlier writings he insisted upon the importance of placing the point of the magnet first over the center of the cornea, so that the foreign body would be drawn away from the ciliary body. With the knowledge that comes from the size and location of the foreign particle, our views upon this point must undergo a certain modification, and it is undoubtedly better policy to lead the particle directly in the line in which we wish it to go.

It is well, at the beginning, to say that every foreign body case must be a law unto itself, as each presents individual complications and conditions; and it may be said in general that the method of removal which is accompanied by the least traumatism is the best. If the case is seen within the first twelve hours, before the closure of the wound, and the foreign body lies near the wound, it is, of course, the best policy to extract it through the wound of entrance, even if it be in the sclera leading directly to the vitreous. Frequently the foreign body, if in the shape of a spicule, will engage in the margin of the wound, and if the force of the magnet is kept up will only be extracted with a good deal of tearing and damage. This point should be carefully watched for, and if the foreign body engages the current should at once be cut off or the patient's head moved slightly back, and then another attempt made at a slightly different angle. Kipp has suggested that under these circumstances the magnet may be reversed and the other tip used, under which circumstances the foreign body, being polarized, will reverse itself and approach the magnet with its other end. He has himself practised this manœuvre with success. It must be remembered, however, that if the spicule is a very long one, the amount of churning up of the vitreous in the course of this reversal is considerable, and it is probably best under these circumstances not to attempt the manœuvre.

The anterior chamber route. If the wound passes through the cornea and iris, or if the primary wound is healed, wherever it may be, there seems no longer any question but that the removal of the foreign body through the anterior chamber is the most desirable method to use, if possible. Many apparently brilliant results of removal by incision through the sclera into the vitreous have been observed, only to

find that a gradual detachment of the retina and total destruction of the eye supervened. The introduction of even a sterile foreign body into the vitreous is a serious blow to the nutrition of the eye, and if we add to it a retinal cicatrix, which will almost invariably undergo connective tissue proliferation and shrink, the results cannot be other than fatal to the integrity of the eye. If, then, the wound of entrance

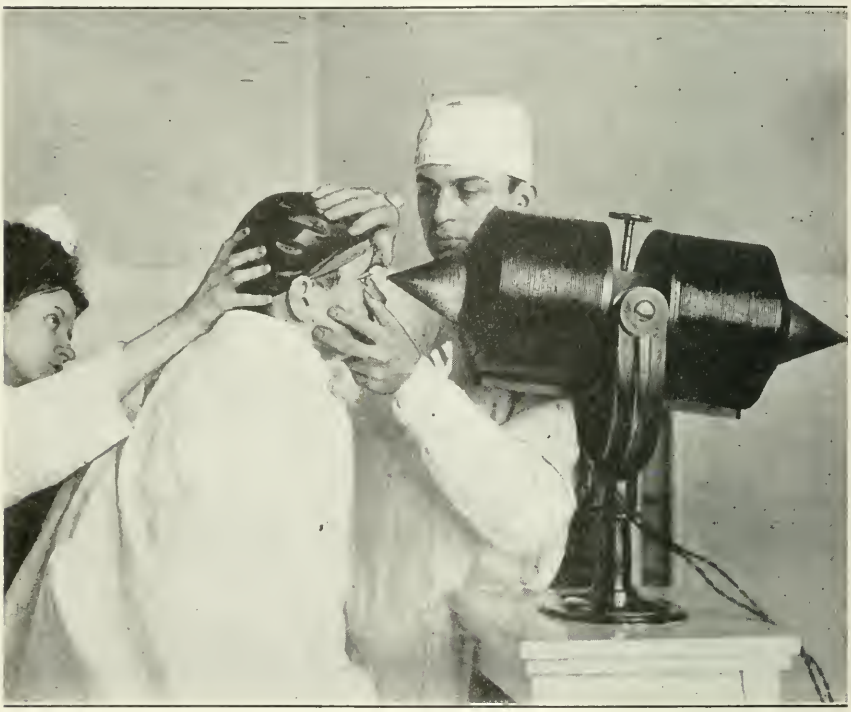

Method of Using the Haab Magnet.

is closed, our best procedure is through a limbus section with a keratome at a point opposite to the location of the foreign body, and as near as possible to any iris lacerations which may be present, so that an iridectomy, if necessary, may include these lacerations. As a rule, the incision will be downward. The patient is then approached to the end of the magnet, the operator separating the lids and instructing him to look in such a direction that the direct route from the foreign body to the magnet will pass through the zonule, and either through the iris laceration—if that be large enough—or as near as possible to the pupillary margin, if the iris is comparatively undamaged. If the

lens be not wounded, it is important to place the line of traction so that the lens will escape laceration. Frequently several attempts will have to be made before the foreign body leaves its lodgment, especially if it is far back in the eye; and if the iris is comparatively undamaged (in which case the path of the exit cannot be made in a single, unbroken straight line) the operator should carefully watch for evidence of the fact that the foreign body has reached the region of the root of the iris, this evidence being either the sensation of pain by the patient or a slight bulging forward of the tissues. Severe pain should at once be an indication for cutting off the current or withdrawing the

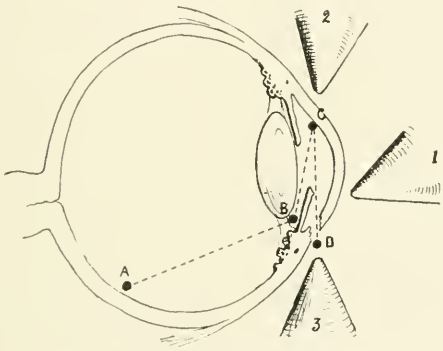

Method of Election in Removing Foreign Bodies from the Vitreous with the Magnet. (a, Primary position of the particle; b, Position behind the iris after the first application of the magnet; c, Position after the second application; d, Exit after the third application; 1, 2, and 3, first, second, and third, positions of the tip.)

patient's eye from the magnet, on account of possible damage to the ciliary body and iris—the patient being upright, he will draw back quickly. When the foreign body has passed the circumlental space—of course having perforated the zonule, which matters little—and engages the iris, it should then be coaxed upward through the pupil by altering the direction of the patient's gaze, when it may easily be extracted from the anterior chamber—either by a new application of the giant magnet or, what is undoubtedly to be preferred in some instances, by gently coaxing it out with the Hirschberg magnet. If an iridectomy be considered advisable, this can be done either at the time of the section or after the foreign body reaches the posterior part of the iris. In the former case, the procedure is much simpler.

The operation of election, then, resolves itself into three applications of the magnet, as shown in the figure. In the first, the magnet is placed below the corneal center, opposite to the foreign body, so

as to draw the foreign body into the circumlental space and between the lens and the ciliary body, so that neither is damaged. Its presence will be recognized by pain or dragging forward of the iris. The amount of dragging is a good indication of how to proceed. If the dragging is violent it is better to try a smaller magnet for the remainder of the operation. The second application of the magnet is then made over the upper part of the cornea in an oblique line, so as to conduct the foreign body into the anterior chamber through the pupil. (If the Haab magnet is used, the patient must look down). The third application then suffices to extract the foreign body from the anterior chamber.

The fact must be emphasized that although the above method is the most desirable one, and to be used whenever possible, it will be modified by the following considerations:

1. The wound of entrance is in the sclera and still open. In this case it is better to extract directly through the wound of entrance, which is afterwards closed by a conjunctival flap.

2. The iris is badly lacerated. An iridectomy is best done before the application of the magnet, which is thereby rendered much simpler.

3. The foreign body passes through the lens, leaving large masses in the anterior chamber. This is another indication of more or less weight, depending on the amount of damage done to the lens, for the iridectomy. Lens masses should only be extracted when completely isolated, and the main body of the lens should be disturbed as little as possible. It is extremely unwise to run the risk of increasing the lens swelling, and it is a good maxim in magnet operations to disturb the lens as little as possible. The reaction will probably be severe enough without any additional lens swelling. Very exceptionally the lens may be so badly broken up that the magnet may be applied directly to the corneal center and the foreign body drawn forward without reference to the lens fragments.

4. The foreign body is very large or very rough and jagged. This constitutes an absolute contraindication to the anterior chamber route, as the lens, if clear, may be injured, or the particle may become entangled in the ciliary body and cause serious injury before it can be withdrawn, if, indeed, it does not become firmly fixed. It is better in such cases to choose the scleral route and chance the consequences of the retinal injury.

Difficulties in the operation. 1. The foreign body may be so far back and so small that only feeble power can be exerted. In this case it is better to persist in the application of the magnet over the cornea until convinced that it is useless. This can be determined only

after numerous applications, for very feeble attraction will sometimes dislodge the particle only after five or six, or even more, applications. It is also good practice to put the patient in the correct position and then turn the current off and on a number of times, so that the particle is acted upon by a series of jerks. Frequently after this manœuvre we shall be rewarded by finding that the foreign body has reached the posterior surface of the iris—as shown by pain or bulging of the iris—when the patient is allowed to withdraw his head from the magnet, which he will usually do at once. No time should be lost in the succeeding application, so that the particle will not fall back, and herein lies the advantage of having the incision made before the magnet is applied. The only disadvantage is that if we fail to remove the foreign body we have made a useless incision, but in such cases the condition of the eye is so serious that it may be doubted if the incision makes it much worse. Of course, a useless incision is to be avoided, but if we weigh the probabilities carefully we shall not often fall into this error. If the corneal application fails to dislodge the foreign body the point should be placed in the lower cul-de-sac at a point as near as possible to the foreign body, having the patient look up, and then when the bulging shows that the particle is near the tip, the magnet should be carefully withdrawn and applied over the cornea as before. It is a great mistake to hold the magnet near and sweep it up to the wound without withdrawing it, as in that case the ciliary body will surely be damaged to a greater or less degree—to say nothing of the retina.

2. The foreign body is in the form of a long spicule, and entangled in the ciliary body or iris. In this case a smaller magnet should be used at different angles, so as to dislodge it, and any increase of the pain should be the signal for immediate withdrawal of the magnet. If the foreign body becomes so firmly entangled in the iris that it cannot be removed, an iridectomy should be done. Entanglement in the ciliary body usually means rapid destruction of the eye through hemorrhage or inflammation.

3. The foreign body is surrounded by new-formed tissue which holds it firmly in position. In this case we shall have the history of the injury a week or more preceding, and though the skiagram shows the particle, the application of the magnet is not attended by pain. It is well to remember that these conditions may obtain even when the foreign body lies on the ciliary body. Enucleation is almost invariably necessary—if not at once, very shortly—nor is it wise to wait long, on account of the danger of sympathetic inflammation.

Various expedients have been devised to meet this difficulty, of which

the most direct is to cut down upon the body through the sclera and place the pole of the Haab magnet as near as possible to the body, although for this purpose the Sweet magnet is probably a better instrument.

Risley advises this method in its entirety, in every case—that is, after exact localization with the X-ray, he incises the sclera as near as possible to the location of the foreign body and then inserts the point of the Hirschberg magnet between the lips of the wound and withdraws the foreign body. Leartus Connor reported the use of a strabismus hook for this emergency which was connected with the end of a giant magnet and then inserted into the wound so as to be brought into contact with the foreign body. The writer practised this manœuvre as early as 1897, and it is undoubtedly effective, but is, after all, only making the best of a very bad matter, and the results are not particularly pleasing. Jackson describes two cases in which he used a pair of scissors in the same way. The scissors were introduced into the wound, and the pole of the magnet was placed in contact with the joint. Four or five short snips were then made so as to free the foreign body, and the scissors were withdrawn, bringing the foreign body with them. This was done in each case with good results. Lang uses a steel spatula, connected with the Haab magnet by a flexible cable, to complete the removal of the foreign body after it has entered the anterior chamber.

The great disadvantage with all these devices is that any kind of "extension point" removes the working point from the center of the magnet's activity and thus enormously decreases the magnet's power. These "extension points" must be brought into direct contact with the foreign body to be at all effective.

The scleral route. Many ophthalmologists believe that it is always simpler and better to remove a foreign body, which lies in the vitreous, by a scleral incision. In fact, this was the oldest method, and was used by McKeown and also by Hirschberg, although they introduced the tip of the magnet into the vitreous and searched in various directions for the foreign body. This was productive of much disturbance in the nutrition of the vitreous, and was strongly condemned by Haab in his earlier writings—in fact, the "giant" magnets were all devised so that the foreign body could be brought into the anterior chamber, and the vitreous disturbed as little as possible. With the development of more accurate methods of X-ray localization, however, it became possible to incise the sclera so close to the foreign body that the tip of a hand magnet had only to be inserted between the lips of the scleral wound to secure the particle, and entrance into

the vitreous was not necessary. Risley advocated this procedure in the discussion of Haab's paper at the meeting of the Ophthalmological Section of the American Medical Association in 1902, and published the above mentioned paper in the September following.

De Schweinitz, three years later, reported twenty-six cases of foreign body injury and strongly advocated the method, which he believed simpler and safer than the anterior chamber route.

The operation is at present performed as follows: After accurate X-ray localization of the foreign body, the patient is placed upon the operating table and the eye prepared as for any important globe operation. Cocaine anesthesia is usually sufficient, though at times ether narcosis may be better. The conjunctiva is first incised in the location of the foreign body and the sclera bared, avoiding as much as possible the recti muscles. Then an incision over the foreign body is made directly through the sclera, choroid, and retina, as cautiously as possible and in a meridional direction—that is, parallel to the recti muscles, as suggested by Risley—for the reason that such wounds bleed less than those which cut across the choroidal vessels, and gape less, on account of the fact that the pull of the recti muscles does not open them. The tip of a magnet—one of the small magnets, Sweet's or Hirschberg's—is inserted between the lips of the wound, and usually the particle can be withdrawn with ease. Should the foreign body fail to come away, the magnet must be inserted with great care, so as to come as closely in contact with the particle as possible. Afterward the wound is closed with a catgut suture, the conjunctival flap brought over it so as to close it firmly, and the operation is done. J. Herbert Fisher inserts two episcleral stitches, cuts between, and has an assistant hold them during the operation, after which they are tied.

Comparison of the two routes. At the present time, in the United States, a decided difference of opinion exists as to which is the better method to be chosen in cases where the wound of entrance has become firmly closed. The advantage of the scleral route is mainly in the ease with which the removal of the particle is accomplished, and the consequent lack of traumatism to the eye. Its advocates lay great stress on the dangers of entangling the foreign body in the ciliary body, the undesirability of a second excursion of the particle through the vitreous, the dangers of further wounding the lens, and finally, the violence apt to be done the eye by the use of the "giant" magnet. Its disadvantages are: the danger of infection by exposure of the vitreous, the great probability of a certain amount of choroidal hemorrhage, and, finally, the liability of subsequent retinal detachment

and degeneration of the globe through the interference with the vitreous and the presence of the retinal cicatrix.

The anterior route is more difficult, technically, but is undoubtedly safer if the magnet is properly used. The wound in the limbus heals with less disturbance and no subsequent dangers, the dangers of infection are much less, and danger of retinal detachment is in a great measure avoided. As to the wounding of the surrounding structures by the magnet operation—this is almost always the result of improper technique. With a knowledge of the size and location of the particle, it should be possible to bring it forward with the Haab magnet without damage to the surrounding structures. It is not always possible to avoid an iridectomy, but this is not a serious matter. It should, of course, be said that a very large or very rough foreign body should not be dealt with by the anterior chamber operation, for it is manifestly impossible to avoid entanglements in this case, but as most foreign bodies are small and smooth, it follows that the anterior chamber route is almost always available. The advocates of the scleral route deny the greater liability of retinal detachment, but this is against all our knowledge of the pathology of retinal wounds. It must be remembered that it is difficult to follow up this class of patients for very long periods, and convincing statistics are lacking on both sides. The writer is certain, however, that enough cases have been observed by competent authorities to make it obvious that detachment occurs more frequently than is generally supposed, though it probably comes on very slowly and only after a lapse of months, or even years in certain instances. Snell says that "we know from the interesting investigations of Parsons that in the healing of sclerotic wounds the injurious effects are observed in the underlying tissues for some distance around. Experience, therefore, has led me to believe that in many instances the anterior route should be selected."

In the discussion of Haab's paper this question was touched upon. Haab believed in interfering with the vitreous as little as possible. Knapp has seen a case in which, three or four months after the scleral operation, detachment had occurred, and thought a scleral incision should be avoided. Holt had observed a series of cases, but had not seen detachment. Hiram Woods had seen a case of detachment six weeks after a scleral operation. Sweet spoke of 57 cases reported to the American Ophthalmological Society in 1901. A large number of these had been watched for a considerable time after the magnet operation. Three cases of detachment occurred. The Hirschberg magnet had been employed.

Results of magnet operations. In dismissing the subject, it may be

as well to give some of the principal statistics of the results obtained, although it must be remembered that most of the successful results of foreign bodies removed from the vitreous are open to question as to the length of time the eye will last without further degeneration. An injury to the vitreous by penetration of a foreign body is a very serious matter, the full consequences of which do not manifest themselves in a month or a year after recovery from the immediate effects. Cases leave us with floating opacities, ciliary or retinal cicatrices, plastic membranes in the ciliary region, etc., which are but too apt to undergo further degeneration. However, the question is assuming much more favorable proportions with the improvements in X-ray localization and magnet technique, which latter is undoubtedly of the greatest importance. The greatest difficulty at present is our almost total lack of knowledge of therapeutic measures connected with the vitreous, with which to supplement surgical procedures. The failures in this class of cases are certainly discouragingly numerous as compared with the "successes."

Haab, in 1902, reported 165 cases of foreign body in the globe. The entrance was corneal in 133; scleral in 17; the operation failed in 23; was successful in 141 (86 per cent.). The eye was removed because of purulent inflammation in 39 cases; because of lingering cyclitis in 9. Nineteen sightless eyes were preserved. In 71, the eye could be used or could be made use of, through a cataract operation; and 51 of these 71 healed with "good sight."

Béal, in 1908, gives the following series of "vitreous cases:"

Results unknown	2	
Atrophy of globe	3	17.64 per cent.
Enucleations	6	35.28 per cent.
Quantitative perception	3	17.64 per cent.
Good vision	2	11.76 per cent.
Feeble vision	2	11.76 per cent.
	18	

Hürzeler, in 1894, 313 cases:

Extraction successful	64.85 per cent.
Some vision saved	22.04 per cent.
Enucleation or phthisis	50.00 per cent.
Globe preserved	17.24 per cent.

Hildebrand, 322 cases; 80 in anterior segment:

Suppuration in	16.25 per cent.
Good results	83.75 per cent.

248 in posterior segment:

Of these, extraction was possible in 174. 70.16 per cent.

Of these 174:

Phthisis	13.00	per cent.
Enucleation	15.00	per cent.
Some vision in	36.00	per cent.
Globe preserved in	16.00	per cent.

Hildebrand, in 1891, second series. Sixty-six cases, 51 in the vitreous. Extraction was possible in 38:

Enucleation	2	5.26	per cent.
Phthisis	7	18.42	per cent.
Globe saved	7	18.42	per cent.
Good vision	16	42.10	per cent.
Light perception	6	15.78	per cent.
	38		

Coppez, in 1890. Thirty-three bodies in the vitreous. Twenty-eight extracted:

Vision, two-thirds	1	3.57	per cent.
Light perception	2	7.14	per cent.
Globe saved	5	17.85	per cent.
Enucleation	20	71.42	per cent.
	28		

Mayweg, in 1902. Seventy-two foreign bodies in the posterior segment:

Enucleation	12.40	per cent.
Globe preserved	36.03	per cent.
Counting fingers	15.17	per cent.
Good vision	36.40	per cent.

Sweet, in 1909: 157 cases of foreign body in eyeball or orbit operated on by various surgeons of the Will's Hospital. Of these, 25 were in the orbit and 20 were in the lens, iris, and anterior chamber, leaving 112 in the posterior segment. Eighty-six of these results of steel in vitreous are given, having been observed for more than six months in every case:

Vision=6/12 or better	24
Vision=less than 6/12	62
	86

Sweet has recently, 1913, reported his fourth series of 280 instances of ocular injury—in 185 of which the foreign substance was found to be lodged in the eyeball or orbit. The body was situated in the

Lens	7 times
Iris	2 times
Ciliary region	19 times
Equator	51 times
Posterior pole	73 times
Orbit	83 times
No foreign body shown by X-ray	95 times

Visual results:

½ or better	20
½ to 1/10	16
Fingers	5
Light perception	32
Complete blindness, with retention of the eyeball	5
Phthisis bulbi	7
Enucleation	65

Snell, in 1905, gives his statistics from 1896 to 1903:

Foreign body in vitreous or retina, 64 cases (out of 3,018 patients), "Good and permanent vision," 36 (56 per cent).

Vision=½ to 1 (out of the 36) 23

One-third were operated on with a small magnet; two-thirds with hand and giant magnet together.

Bull, 1910, reports the post-operative history of 18 vitreous cases:

Removal successful	17
Phthisis bulbi	6
Sympathetic ophthalmia	8
Enucleation	10

"Permanent useful vision was not gained in a single case."

Callan, 1910, reports 22 vitreous cases:

Total loss	6
20/20	1
20/30	2
20/50	1
20/70	1
20/100	1
"Good vision"	1
Occluded pupil	2
Thickened capsule	1
No report	6
	22

—(E. S. T.)

Max Dalmer (*Zeitschr. f. Augenheilk.*, p. 552, Vol. 29, June, 1913) calls attention to the occasional failure of the electro-magnet in extracting pieces of steel whose presence in the ocular structures has been demonstrated by the sideroscope or X-ray apparatus. He says that this may be due to the fact either that the piece of iron lies outside of the eyeball in the orbit or skin of the forehead or cheek; that the foreign body is fixed tight in the globe, in its walls, ciliary body, or in exudates, or that the magnetic properties of the foreign body are in disproportion to its size.

Dalmer also reports three cases of perforating injuries with the site of the foreign body (iron ore), in the anterior chamber, lens and vitreous. In all of these the sideroscope registered positively, whereas attempts at extraction with both the giant and hand magnets were futile. The weights of the metallic bodies were 10, 6 and 120 mgr., respectively. In two cases the fragments were removed with forceps and spoon, in the third instance enucleation was performed. Later, the bodies removed were tested with the sideroscope and the magnet. The sideroscope showed in each instance marked deviation; but the large magnet attracted them for a distance of less than 1 cm. only, and it required force to detach them from it. Since Dalmer found no statements in ophthalmological literature as to the behavior of iron ore to the sideroscope and large magnet, he examined the more important iron ores with regard to this question. He then made experiments with pigs and living rabbits, into whose eyes several kinds of iron ore were introduced and the reaction to the sideroscope and the large magnet tested. The strongest reaction was given by magnetic iron ore; iron pyrites being attracted at from ½ to 1 cm. Iron silicate was not attracted at all.

Electrooptics. That department of physics which deals with the optic phenomena of electric light.

Electrophthalmcyclope. An instrument invented by Noischewski for enabling the blind to perceive light by the senses of temperature and position. It consists of a small camera obscura with its posterior wall composed of three layers—one of fine metallic gauze, then a plate of selenium, and finally a brush-like arrangement of gold wires in immediate contact with the skin when the instrument is fixed to the middle of the forehead. Rays of light falling into it excite a thermo-electric current, which is at once perceived through the glabellar nerve-filaments as an impression of heat. The degree of heat is increased by the approach and diminished by the recession of a luminous object, and the sensation moves on the forehead according to the motion of the object from right to left, etc.—(Foster.)

Electropuncturation. ELECTRO-PUNCTURE. Electrolysis of any portion of the body by means of a needle-electrode passed into the tissues.

Electrothermograph. An instrument invented by Dujardin to indicate the thermal variations in different organs of the body. It consists of a couple composed of iron and an amalgam of copper, zinc and nickel, one end of which is placed on the organ, and the other connected with an apparatus for keeping it at a constant temperature. The deviations of the needle of a galvanometer placed in the circuit are registered by means of photography.

Elefantiasi delle palpebre. (It.) Elephantiasis of the lids.

Elektrische Reizung des Auges. (G.) Electric irritation of the eye.

Element. In optics, one part of a symmetrical whole; for example, a lens.

Elementary focal plane. See **Focal.**

Elephantiasis, Ocular relations of. There are several varieties of this disease, most of which may affect the lid skin. Among these so-called *solid edema of the lids, elephantiasis arabum, elephantiasis lymphangiodes, elephantiasis neuromatodes, elephantiasis phlebectatica,* and even various benign tumors of the lids have been included under this title.

The term *solid edema of the lids* or *symmetrical elephantiasis* is applied to a condition in which there is enormous enlargement of the eyelids, particularly of the lower lid. The swelling, which is often so great as to conceal the palpebral fissure, is soft and elastic, pits on pressure, is of a dusky, reddish-brown color, without evidences of inflammation and without involvement of other parts of the body. In the majority of cases the disease has followed attacks of erysipelas. Some of the cases have terminated in tuberculosis of the conjunctiva. The nature of the disease is obscure. It is supposed to be a recurrent lymphangitis. Various methods of treatment—nitrate of silver, collodion, pressure, fomentations, multiple punctures, and excision—have been tried without permanent benefit.

W. A. Pusey (*Archiv. f. Dermat. u. Syph.* Bd. CXI) remarks that:

"Sir Jonathan Hutchinson in 1883 described under the names elephantoid hypertrophy or solid edema of the face a symmetrical enlargement of the soft tissues of the face following repeated attacks of erysipelas. He recognized it as an elephantiasis, and clearly pointed out its dependence upon lymphatic obstruction. Subsequently he published reports of several other cases.

"Elephantiasis of parts of the face, especially of the upper lip, is, of course, a well recognized lesion, and many works on dermatology indicate the occurrence in rare cases of an elephantiasis of the whole face

following repeated attacks of erysipelas. Nevertheless, that knowledge of Hutchinson's solid edema, or symmetrical enlargement of the face from elephantiasis, is not general is indicated by the facts that occasional cases of the condition repeatedly fail of recognition and other cases are now and again reported without clear appreciation of their character.

"There is nothing essential to add to Hutchinson's original accounts of the condition. The patients give a history of repeated attacks of

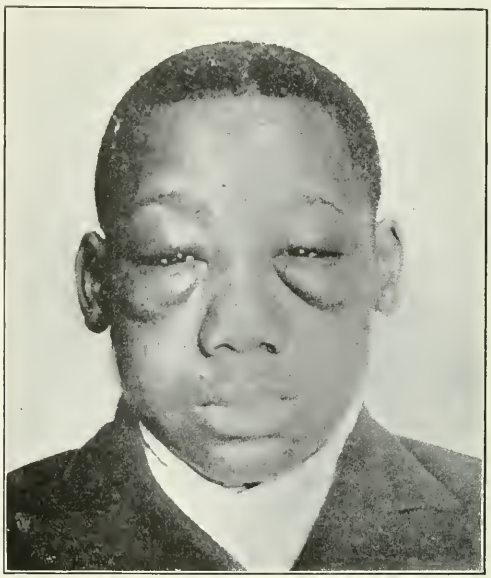

Symmetrical Elephantiasis of the Lids. (Pusey.)

erysipelas, or of a less acute recurring reticular lymphangitis of the face. In some of these cases the attacks are frank acute attacks of erysipelas with high temperature and acute febrile symptoms that confine the patient to his bed. In others the attacks are less typical; there is an erysipelas-like local reaction, but little pyrexia or prostration. Following these attacks there is gradual symmetrical enlargement of the soft tissues of the face. There may be evidence of a persistent subacute inflammatory process, with a diffuse pale erythema; but after years this may disappear leaving a permanent normal-colored thickening of the tissues. I know of no case in which there was macroscopic hyperplasia of the epidermis. The enlargement of the tissues is of course not due to a serous edema, the tissues are of normal consistence, and there is no pitting on pressure.

"Adam has pointed out that the condition may affect the mucous membranes as well as the skin; that it is probably the cause of some cases of solid edema of the larynx and pharynx, and that it must be added, as a cause of solid edema of the larynx, to syphilis, tuberculosis, and cancer.

"The condition is probably always associated with a focus of infection on a mucous surface, Adam believes most frequently near a mucous orifice. In all of my cases it was associated with lesions in the nose.

"In the case shown in the figure, a negro boy 18 years old, it had followed innumerable attacks of erysipelas with severe systemic symptoms which had recurred during many years; there was an extensive hypertrophy of the intranasal mucosa with numerous foci of infection from which streptococci and staphylococci were recovered.

"The most important matter in treatment undoubtedly is to get rid of the source of the reinfections, and to that end the discovery and treatment of the lesions of the mucous membranes, particularly in the nose, are necessary. The strengthening of the patient's resistance is of course desirable. Hutchinson recommended for this purpose 'the liberal use of tonics, and especially of iron.' Of course bacterial vaccines suggest themselves. Weaver and Tunnicliffe have had a brilliant result in one case, in which vaccines killed by heat had failed, by the use of an autogenous streptococcus vaccine rendered sterile by galactose solution."

Elephantiasis arabum is a rare disease which sometimes involves the eyelids. It may be divided into two classes: (1) the tropical endemic type, which is due to filaria sanguinis hominis; and (2) the sporadic type, which is attributed to a variety of causes, all of which produce blocking of the lymph-channels. Thus, it follows oft-recurring attacks of erysipelas. In the case reported by Walzberg hypertrophy of the left upper eyelid was present at birth. Attacks of inflammation preceded increased growth. The eyeball was displaced, the eye was amaurotic, and the cornea was hazy. The mass was successfully operated upon by Koenig. The pathologic changes in elephantiasis of the lids are an hypertrophy of the skin, particularly of the subcutaneous connective tissue, and dilation of the lymph-spaces, which are blocked, thus leading to lymphatic edema. The treatment consists in massage and surgical measures.—(J. M. B.)

According to Parsons (*Pathology of the Eye*, p. 12), in both *elephantiasis lymphangiodes* and *elephantiasis arabum* the condition is due to lymph stasis. Several cases have been collected by Becker. The changes are chiefly in the subcutaneous tissue, which is enormously

hypertrophied from increase of fibrous tissue, mostly in bands or networks, other parts being gelatinous, with soft, fine fibres, and many nuclei and cells. The blood vessels and lymphatics are enormously enlarged, and the muscles show fibro-fatty changes. The epidermis is also proliferated.

Allied to elephantiasis are the cases of chronic edema which are occasionally met with. Their pathology is obscure, and the tissues have seldom been submitted to microscopic examination. In a case following erysipelas, Rombolotti found edema of the subepithelial tissues, with dilatation of the lymph spaces. There was some round-celled infiltration, and marked hyperplasia of the fixed-tissue elements. The dilatation of the lymph spaces was less marked than in Polignani's case.

The upper lid is a favorite situation for *elephantiasis neuromatodes* or *neuro-fibromatosis*. Cases have been reported by Billroth, Burns, etc. There is the characteristic hypertrophy of the nerves, and also a condition of lymph stasis and fibromatosis of the subcutaneous tissues. The condition of the lid in the case reported by Rockliffe was as follows:

The upper lid was enormously swollen, the increase in tissue being principally upon the posterior or conjunctival side, resulting in marked ectropion. This increase of growth consisted of masses of convolluted nerves covered by inflamed conjunctiva. The nerves were generally smaller than those in the major orbital part of the growth, but showed similar hypertrophy of the endo-and peri-neurium. The nerve-fibres, stained by Weigert's method, showed comparatively little change. The other tissues of the lid exhibited more edema and congestion, great dilatation of the subdermal lymphatics being a marked feature.

Finally, Wilbrand (*System of Diseases of the Eye*, Vol. II, p. 277) says that a case of elephantiasis has been responsible for hemiopia—the result of pressure upon the chiasma.

Of benign tumors of the lids simulating elephantiasis, a case of slowly progressive neurofibroma studied by Rohmer (*Ophth. Rev.*, XXX, p. 360, 1912) was reported by Gross in 1882 under the title *Elphantiasis of the Eyelids*. The patient came under Rohmer's observation in 1905, and post-mortem study followed death from pneumonia fifteen days after excision of part of the growth. In 1881 the swelling involved the right eyelids and temporal region. It remained stationary in size until about 1897, and reached its final volume about four years later. At the time of operation the patient was much enfeebled. An enormous swelling occupied the whole of the right temporo-parietal region, extending upward nearly to the middle line of

the scalp, backward almost to the occiput, downward 2 cm. behind the ear, and in front of the ear to 2 cm. or 3 cm. from the free edge of the lower jaw. The cheek was involved almost to the lips, leaving intact only a space about 2 cm. wide toward the nose. The eyelids were greatly enlarged, and immobile. Examination of the skull showed the right frontal bone to be riddled with small openings, collected in groups measuring 15 to 18 mm. in diameter. The fronto-parietal suture was widely opened.

Roessler (*Klin. Monatsb. f. Augenh.*, September, 1912) described a case of swelling of the left upper lid which microscopically presented the picture of pachydermia (elephantiasis) lymphangiectatica. The patient, a young man of 18, had had a slight pustular infection over the left zygoma three years before, followed by an infection of the parotid on the same side. A blow over the parotid was a factor in producing the infection. The gland was repeatedly incised. The infection was followed by the lid swelling, which persisted for nearly three years, when Roessler excised a portion of the upper lid so that the patient regained sufficient control to raise the lid border to the middle of the cornea. Up to the time of the excision the upper lid was immovable.

Wützold (*Ophthalmic Review*, p. 192, June, 1913) has described a case of elephantiasis phlebectatica in a boy of 14, who in his eighth year had suffered from extremely severe swelling of the right ear; soon thereafter he complained of swelling of the eyelids, this gradually increasing in the course of a year till the doughy mass involved all the tissues above nose and lips. Around the eyes the tissue was, at date of exhibition, hard and cicatricial. There was no history either of ulcers or of lupus. The bony margins of the orbit were thickened and made coarser from involvement of the periosteum: the orbicularis oris was much infiltrated and at the angles of the mouth were hard nodules the size of a cherry; the veins of the whole face were greatly distended. The origin of the condition was quite uncertain.

Elephantiasis oculi. (L.) An obsolete term for extreme exophthalmia.

Elettrolisi. (It.) Electrolysis.

Elévateur de la paupière supérieure. (F.) The levator palpebræ superioris.

Elévateur de la pupille. (F.) The rectus superior muscle.

Elévateur de l'œil. (F.) The rectus superior oculi.

Elevator. A great variety of these useful instruments is described and depicted under various captions in this *Encyclopedia*. Under this heading a few examples are figured.

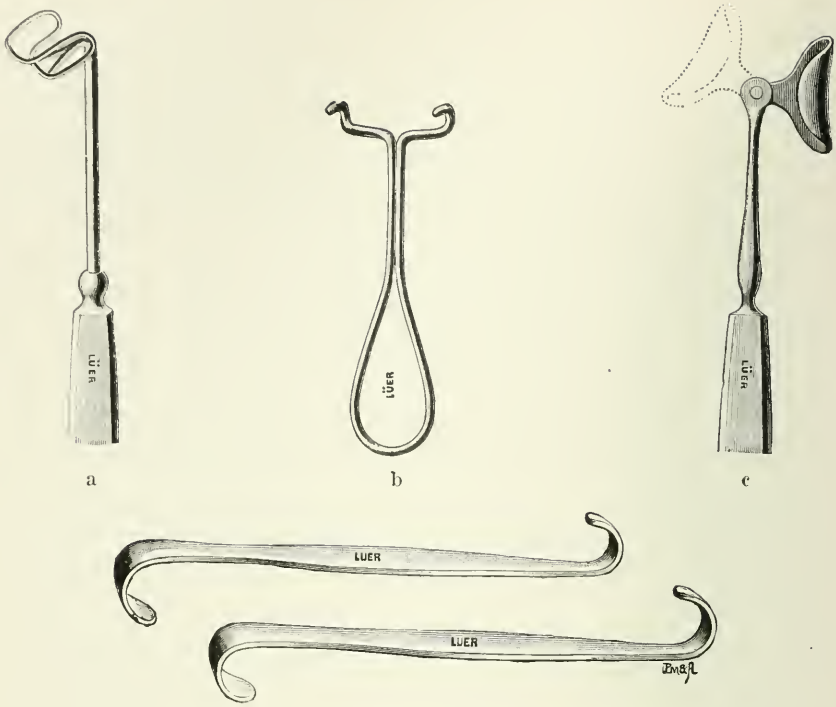

a, Wire Lid Elevator; b, Nicati's Hook Elevator for the Eyelid; c, Abadie's Articulated Elevator; d, Set of Simple Elevators for Operations on the Lachrymal Sac.

Elévure. (F.) Pimple. Blotch.

Elisabethinerkugeln. (G.) A poisonous cosmetic containing chalk, alum, camphor and 37 per cent. of white lead. Mueller (*Wien. klin. Wochenschr.*, 1895, No. 25) describes a case in which the use of this face powder produced the usual form of saturnine, optic neuritis with other signs of lead poisoning, and the permanent reduction of vision to finger counting.

Ellaby, Charlotte Louisa. An Anglo-Indian surgeon, who was born in 1854. Having spent many years in India, she returned to England in order to become an ophthalmologist exclusively. In 1890 she was appointed the first ophthalmic surgeon to the New Hospital for Women, in the Euston Road, London—the eye department of which she had in fact organized. She died in 1909, after a long period of ill health.—(T. H. S.)

Ellébore. (F.), n. Hellebore.

Elliott, John. An English apothecary and physician, of a slight importance in ophthalmology because of his "Experiments and Observations on Light and Colors, etc." Born at Chard, Somerset, in 1747, he became at first an apothecary, but later received the degree of Doctor in Medicine. He starved himself to death in jail, where he lay awaiting trial for the murder of his wife.—(T. H. S.)

Elliot's operation. Simple trephining of the sclero-cornea for the relief of glaucoma. See **Glaucoma.**

Ellipsoid. A solid whose surface is generated through rotation of an ellipse upon one of its axes. See also **Astigmatism.**

Elliptically polarized light. Light wherein the ether particles vibrate in elliptic paths.

Ellipticity. A geometrical expression, often applied to the cornea, i. e., the quality of being elliptic. It is a term also commonly used to describe the figure of the earth, that is, the difference between the polar and equatorial radii.

Elliptoid. Somewhat resembling an ellipse.

Elode. (F.) Prevailing in marshy districts. Malarial.

Eloigné. (F.) Remote. Distant. Removed.

Elongation des nerfs. (F.) Nerve-stretching.

El-Rasi. See **Ar-Razi.**

Ely, Edward Talbot. A well-known New York ophthalmologist. He was born at Rochester, N. Y., Oct. 2, 1850, the youngest son of Dr. W. W. Ely. He graduated at Rochester University in 1871, and at the College of Physicians and Surgeons, New York, in 1874. When he had served in the Presbyterian and Charity Hospitals for some time, he became associated with Dr. D. B. St. John Roosa.

He became Assistant Surgeon to the Manhattan Eye and Ear Hospital, Surgeon to the Charity Hospital, and Associate Professor of Ophthalmology and Otology in the New York Post-Graduate School of Medicine. In 1878 he became a Member of the American Ophthalmological Society. He wrote no book, but contributed numerous ophthalmologic articles to various journals.

He married, in 1882, Miss Emma L. Weber, of New York.

In Oct., 1882, he suffered a severe attack of hemoptysis. At Colorado Springs, Colo., his health became much better, but, in a very few months, a chronic abscess appeared in his left hip, and, returning to his native town, Rochester, he died there Apr. 12, 1885.—(T. H. S.)

Email. (F.) Enamel.

Embarin. This agent is a salicyl-sulphate of mercury and sodium, and it has recently had some advocates of its use in luetic affections. It is used by subconjunctival injection in much the same way as other

mercurials are employed. Rudolf Rauch (Graefe's *Archiv f. Ophthal.*, Vol. 88, p. 184, 1914) and R. Possek (*Berl. Klin. Woch.*, Vol. 51, p. 303) have given this method an extended trial and recommend it in syphilitic diseases of the eye. The former authority advises an injection every two days (into the gluteal muscle) until, at most, twenty treatments have been administered. He reports several cases of parenchymatous keratitis in which one-half to one cc. was administered with excellent results and very little local or general irritation.

Embedding. The fixation of a specimen in a medium firm enough to hold it intact during the cutting of sections for microscopic examination. For example Pollock (*Ophthal. Review*, Sept., 1908) discusses the advantages of paraffin as compared to celloidin in the preparation of an eye for microscopical examination as follows: Paraffin holds all the parts together so that there is no fear of getting them disturbed after cutting, just as celloidin does. The method of fixing is, however, important, for if the lens and sclera are rendered too hard and brittle it may be impossible to obtain good sections. If the examination of the lens in patients over 30 is not important, the writer removes the portion in the half eye used for sections in order to save the edge of the razors. If the eye is kept too long in the paraffin bath a certain amount of distortion may occur. With regard to sections "being disturbed after cutting," this is largely a matter of technic and gentleness of touch; but a method of avoiding all risk is described. The removal of the paraffin from the sections takes scarcely more than three minutes, and as it is done by placing the slide with section in a tube of xylol, no trouble is entailed. The manipulation of cut sections is a simple matter, even when they curl up. Paraffin sections can be kept for an indefinite time between layers of paper, and paraffin blocks are more easily stored in permanent form than celloidin. Paraffin sections may be cut of extreme thinness. This agent is unsurpassed by any other method for obtaining serial sections. Pollock describes his method of procedure which has given him the greatest satisfaction, describing the fixing, staining, cutting and mounting of sections and the method of preserving half eyes.

Embolic panophthalmitis. See **Metastatic panophthalmitis**; as well as **Choroiditis, Suppurative.**

Embolism. This is the condition in which a blood-vessel, particularly an artery, is wholly or partially occluded by a plug (embolus), including the consequences of such occlusion. The best examples of the process as it occurs in the human eye are seen in obstruction of the central artery of the retina. See, for example, Vol. III, page 1955 of this *Encyclopedia.*

Embolism, Air. Stargardt (*Jour. A. M. A.*, p. 2277, Dec. 20, 1913) proposes the ophthalmoscopic examination as a means of recognizing air embolism of the systemic vessels in puzzling cases of collapse. Experimenting on the ape and the rabbit, he found that the presence of air can be detected in the retinal arteries almost immediately after it is injected into the carotid. Bubbles and short columns of air shot through the vessels, and in one or two seconds the artery became completely filled with air. At the same time the arteries were strongly contracted and the optic disc becomes snow-white. The veins disappeared in a similar manner and a net-work of fine, white lines appeared. In about four minutes the appearance of the fundus became normal, and hyperemia of the disc followed. The choroidal vessels are difficult to observe in the ape, but air in them caused yellowish spots in the fundus. In the rabbit the choroidal vessels became quite white or a pale yellow.

Embolism, Cerebral. According to W. B. Cadwalader (*Jour. Amer. Med. Assn.*, p. 2248, 1912) and other authorities, unilateral optic atrophy sometimes results from this disease. According to D'Orsay Hecht, (Wood's *System of Ophthalmic Therapeutics*, p. 305) the *treatment* of this condition is much the same as that of cerebral hemorrhage except that depletory methods by venesection or free purgation are absolutely contraindicated. Emboli are not removable. Rapidly acting stimulants, such as camphor, strychnine or ammonium carbonate, are of cardinal service in strengthening the heart's action and establishing as quickly as possible a strong collateral circulation. If this be not the aim from the first, irreparable softening of brain tissue must follow. If convulsions appear, chloral hydrate in doses of fifteen grains every hour may be given, but it is unsafe to give more than three consecutive doses. The onset and late symptoms are treated expectantly by rational measures of rest and diet.

Embolism of the central retinal artery. Retinal embolism. Retinal obstruction. An embolus may lodge in the arteria centralis retinæ or in one of its branches. The disease comes generally without pain and without premonitory signs, although Schöbl claimed that transient obscuration of the visual field, or transitory blindness, are frequent premonitory phenomena. The initial symptom is sudden and complete blindness, if the central trunk is obstructed; sudden partial blindness, if the embolus passes into a branch of the central vessel. In the latter event the visual field is correspondingly limited. Complete blindness existing for several minutes or hours, if the embolus is lodged in the central artery, may be followed by a loosening of the plug, which then lodges in an arterial branch. Vision will then be

restored except in the area of the visual field which corresponds to the part which the branch supplies. If examined immediately after the accident, the ophthalmoscope will show complete absence of blood from a part of or the whole retina, depending upon the location of the plug. The arteries are either completely lost to view or much diminished in size. The optic papilla is whitish or yellowish. The veins are contracted, but may show irregular distensions toward the periphery of the retina. The veins sometimes present an intermittent flow of blood with or without pressure. Pressure upon the eye, by increasing intra-ocular tension, may cause a flow of blood, but there is usually complete absence of pulsation, venous or arterial, on pressure. Coagulated blood may be found in the small arteries, particularly in the macular vessels. The entire fundus is white except for the presence, in the macular region, of a cherry-red spot. This spot has been attributed to hemorrhage, but it is now generally believed that it is simply the natural color of the fovea made prominent by contrast with the white fundus. In a few hours the retina shows opacity due to edema. It becomes of a whitish, yellowish-gray, or greenish color except for the cherry-red spot at the macula. In rare cases of embolism the red spot may be absent; in the black races it has been observed as a black spot. Later on in the history of the case the retinal picture is that of atrophy. The arteries are extremely small, the veins are narrow and straight, the optic disc is white or of a dirty-grayish color, and there is perivasculitis and retinal degeneration. Such an eye will be blind; the pupil will be dilated and fixed and the media clear. In a few of the recorded cases of complete embolism a small sector of the visual field has been preserved. In such cases cilioretinal arteries were present.

An embolus of the central artery lodges usually immediately behind the lamina cribrosa, at a point where the vessel is contracted and makes a turn to ascend to the papilla. Here the embolus becomes organized. In Marple's case a thrombus was found behind the embolus; the optic nerve was atrophic, the intervaginal space was dilated, and apparently there was a vaginitis. Retinal changes have been found by Elschnig and Marple, whose cases were studied in laboratories seven weeks after the onset of the disease. The inner layers of the retina—layer of nerve-fibres and ganglion-cells—are the first to become atrophic.

The *cause of embolism of the central retinal artery* is to be sought in lesions of the heart and arteries. Of 125 cases tabulated by Fischer, 70 per cent. showed valvular lesions, recent endocarditis, arteriosclerosis, syphilitic endarteritis, or aneurism. In 30 per cent. no

adequate cause could be found, but it is safe to assume that in one-half of these cases cardiac or vascular lesions existed without giving rise to physical signs. Age is not a factor, the disease being found in the young as well as in the old. A few cases of embolism of the central retinal artery occurring in chorea have been recorded by Swanzy, Benson, Thomas, and others. Embolism also occurs in Bright's disease, and has been seen during pregnancy. Multiple emboli of septic character due to post-partum pyemia are occasionally seen. In such cases, according to Galezowski, the left eye is more often affected than the right, but both may be involved. Septic emboli produce panophthalmitis, and usually cause death. In some cases presenting the clinical signs of embolism, without discoverable cardiac lesions, it is possible that the true condition is a hemorrhage into the optic nerve-sheath. The blindness is sometimes preceded by daily attacks of epistaxis, as in cases reported by Jessup and Collins.

That embolism of the central retina artery does not more frequently occur is doubtless due to the anatomic fact that the ophthalmic artery branches from the internal carotid at almost a right angle, and that the arteria centralis retinæ is given off from the ophthalmic, or from one of its larger branches, in turn in much the same way. Hence, a clot leaving a cardiac valve is much more likely to continue its course in the large vessel and lodge in the brain than to enter a branch given off in this manner. If an embolus gains access to the ophthalmic artery, it is much more likely to traverse the lachrymal, supra-orbital, nasofrontal, and their terminal vessels (the ciliary arteries) than the retinal artery. It is probable that embolism of the ciliary arteries is a more common affection than has been supposed; however, owing to free anastomoses, plugging of one of these vessels is not followed by such disastrous effects as follow embolism of the central artery.

The ophthalmoscopic picture described above is pathognomonic of a stoppage of the retinal circulation, but this may be due either to embolism, thrombosis, or hemorrhage into the sheath of the optic nerve. Except the embolus is lodged in a branch of the central vessel, differentiation between these conditions may be difficult or impossible. Another lesion which obscures the diagnosis is thrombosis of the central vein at a point where it can press on and occlude the adjacent artery. According to Priestley Smith, arterial thrombosis can be distinguished from embolism by a history of transient failure of sight, resembling the permanent attack in its onset. Simultaneous failure of the other eye favors the diagnosis of thrombosis.

Prognosis is very unfavorable. It rarely happens that the plug becomes displaced spontaneously or by treatment. If a branch of the

central artery is involved, there will be loss of vision in a corresponding area of the field. Septic emboli, such as are found in puerperal fever, cause panophthalmitis and often lead to death by reason of the planting of septic foci in vital parts. It is not easy to say in these cases whether the central retinal artery alone is involved; it is likely that emboli are also present in the choroidal vessels (ciliary arteries). In embolism of a branch of the central artery the formation of an anastomosis was observed by Königshöfer. If a cilioretinal vessel is present, the plugging of the central artery will not completely check the supply of blood to the retina: a limited area supplied by the cilioretinal vessel will functionate. While the prognosis in embolism is usually unfavorable, great or complete restoration of vision is possible. Cases have been reported in which vision was restored by deep massage combined with the internal use of Rochelle salts and iodid of potassium and hypodermic injections of pilocarpin.—(J. M. B.)

So far as *treatment* is concerned the embolus has been dissipated or dislodged and the retinal circulation partially or entirely restored, yet treatment in the majority of instances is without avail. Fischer, Würdemann and Casey Wood have used, with success in several instances, deep massage with the suction apparatus or the finger. The earlier this measure is tried the better, and it should be used in conjunction with inhalations of nitrite of amyl.

The Editor has published the results of iridectomy in a number of cases but he cannot say that the results were encouraging. Hypodermic injections of pilocarpine, with the internal administration of salines and potassium iodide, may be used in conjunction with massage. Recurring to the last mentioned form of treatment, the Editor is in favor of covering the lids with a little vaseline and making deep, continuous rotary and up and down movements over the globe for several minutes, intermitting them when the pressure becomes painful. This treatment should be followed for a week or ten days and not abandoned as long as the perimeter or the ophthalmoscope shows any improvement.

R. A. Fenton (Wood's *System of Ophthalmic Therapeutics,* p. 795), advises careful massage with the double suction cup and Victor electric pump (pressure releases between strokes) for the dislodgment of the thrombus or embolus. See, also, Vol. III, p. 1955, of this *Encyclopedia.*

George Coats (*Ophthalmic Review,* p. 141, May, 1912) has given an instructive abstract of the well-known paper on this subject by Rubert (*Klin. Monatsbl. f. Augenh.,* xlix. 2, p. 721, 1911), whose case is important because the globe was obtained for pathological examination at a comparatively early date after the occurrence of obstruction of the

central artery. The patient was a man aged 41, who had had a gastrostomy performed for esophageal stricture. Ten days later the left eye suddenly became blind, with the typical picture of obstruction of the central artery, and four days later he died with symptoms of cardiac failure and dyspnea. A plug was found in the artery at its division on the papilla, but not reaching so far back as the lamina cribrosa. It was composed of a compact, almost homogeneous, hyalin-looking substance, staining dark-red with eosin, and brown with v. Gieson's stain. Weigert's fibrin stain gave no result. The endothelium was proliferating slightly, and commencing to invade the periphery of the mass, but otherwise the coats of the vessel were normal and uninfiltrated. The retinal vessels were normal, the arteries narrow, the veins enlarged. The papilla was swollen and prominent, owing to serous infiltration of the tissues; the nerve fibres showed some signs of disintegration, and there were many "granule cells." Similar changes were present in the nerve fibre of the retina; the ganglion cells showed degeneration, chromatolysis, vacuolization, shrinkage, etc.; they were better preserved in the periphery than towards the posterior pole. The more external layers showed a certain amount of edema, and some changes in the nervous elements. The rod and cone and outer nuclear layers were practically normal. The fovea was free from edema. The choroid and all anterior parts of the eye were normal.

The author, probably correctly, claims this as a case of true embolism. Endarteritis was absent. As to thrombosis, the lowered blood pressure due to the patient's illness and operation might possibly have caused a marantic thrombus, but even this is unlikely to occur without slight local disease of the wall. Moreover a thrombus only four days old should show blood corpuscles and fibrin, which, however, were absent in the present instance. It is probable therefore that the obstructing mass was of older date than the blindness, and was formed in some part of the body other than the eye. The absence of prodromal obscurations and of partial recovery are also in favor of true embolism. As to the source of the embolus, nothing certain could be affirmed, as there seems to have been no complete post-mortem examination.

Much more doubtful is the author's statement that his own case, and perhaps Siegrist's are the only ones in which the embolic nature of the obstruction has been proved beyond cavil. It is difficult to know what is to be the standard, but if the presence within the central artery of a structureless, calcareous mass showing no organic connection with the walls of the vessel, which were entirely free from infiltration; together with extreme collapse, without endarteritis, of

the artery in the vicinity; the patient being the subject of severe endocarditis, with mitral disease and aortic regurgitation; and the blindness being perfectly sudden; if these are points of importance, then the occurrence of true embolism has been proved by a case reported by the reviewer. This case seems to have escaped the author's notice, but apart from this it is probable that the Zürich school, which has rendered eminent services in setting the claims of endarteritis and thrombosis on a firm basis, has carried too far its rejection of true embolus as a cause of obstruction of the central artery.

In explaining the fact that the central vessels contain blood Rubert relies on a hypothesis of Elschnig's, which states that when the arterial pressure is cut off, and the blood pressure consequently sinks below the intraocular pressure, the vessels become collapsed, and the collapse occurs first where the pressure is lowest—at the point of exit of the vein. This would account for the imprisonment of blood within the eye, but is no explanation of what really does take place—namely a restoration of the circulation. A much more probable supposition is that the renewed circulation is due to the enlargement of capillary anastomoses in the nerve and papilla.

Dealing with the retinal lesions and the cause of the retinal opacity the author finds that the changes were more extensive in his case than in Siegrist's, the only other in which an early examination has been possible. He considers that the condition is essentially an edema. Against regarding edema as other than a secondary lesion, however, there are certain objections; one would expect, for instance, to find the fluid extravasated as much (or more) from the peripheral vessels as from those at the posterior pole, and as much in the outer reticular layer—which is a favorite situation of edema—as in the nerve fibre layer. Swelling of the papilla, such as Rubert describes, is surely not a common accompaniment of obstruction of the central artery. In the present instance also the presence of granule cells and the extensive changes in the ganglion cells show that other factors are to be taken into account. That changes in the ganglion cells are capable of producing a picture closely similar to that of obstruction of the central artery is shown, as Hancock has pointed out, by the case of amaurotic family idiocy, in which the absence of edema has been repeatedly demonstrated by the examination of fresh material. Moreover, the ganglion cells are most thickly distributed precisely where the opacity is thickest, and are absent where the opacity is absent—at the fovea. The point can scarcely be settled finally by post-mortem material fixed in Kaiserling's fluid, and although the present case is

a valuable contribution to the question, further observations are desirable.

More recent observations on this important subject will be found in the *Ophthalmic Year-Book* for 1913. Among them are the following:

In his clinical study of occlusion of the retinal arteries, Kober (*Beit. z. Augenh.*, Vol. 85, p. 405) makes no attempt to distinguish between cases of embolism and those of thrombosis. But he inclines to the view that local sclero-thrombotic lesions are the common cause of closure of these vessels. His monograph is based on 60 cases seen in the Tübingen University Clinic, among 134,970 patients suffering from eye disease, or one in 2,249. In 57 of the cases but one eye was affected; in 3 both eyes were involved. In 30 of the former the obstruction occurred in the central artery. In 27 it involved one or more of the retinal branches. In the bilateral cases the central artery was always occluded. The two sexes were involved about equally, 31 men, 29 women.

With regard to the period of life at which this lesion occurs, the 33 cases of closure of the arterial trunk showed a maximum of seven in the seventh decade, with an almost equal number (6) in the third decade. Of the cases of closure of one or more branches the maximum (10) occurred between 20 and 30 years of age. When all the cases are taken together the maximum (16) occurred in the third decennial period, while only 10 occurred in the seventh decade. Of the bilateral cases one was the youngest patient, a girl of 17, suffering from mitral insufficiency, nephritis and anemia. The other two were men, aged 71 and 73 (the latter the oldest patient) both with arteriosclerosis.

As a prodromal symptom, 12 gave a history of previous temporary obscuration of vision of the affected side; and 5 had noticed such obscuration in both eyes. Kober points out that the danger of helpless blindness from bilateral occlusion is slight, only 5 per cent. of the cases. Of the 27 cases of partial involvement, the vision subsequently improved in 8. As to the general conditions with such arterial obstruction, associated heart lesions were found in 11; local arteriosclerosis of the retina in 11; general arteriosclerosis, 14. Three suffered from apoplexy, and 2 from nephritis. In 17 no general disease was discovered, and in 2 this point was not noted.

That obstruction of the central artery of the retina may be due to embolism, Coats (*Royal Lond. Oph. Hosp. Rep.*, Vol. 19, p. 45, 1913) considers proved by a case he reports. A woman who had rheumatic fever at 18 years, followed by mitral stenosis, suffered sudden loss of vision in the right eye at the age of 71; and the eye was enucleated within two months for glaucoma. Coats found in the central retinal artery at the upper level of the lamina cribrosa an unorganized cal-

carcous mass without adhesion to the vessel wall, which was normal in this situation, except for partial loss of endothelium. In front of this mass there was a thrombus, and there was partial thrombosis of the central vein. The case meets the requirements of Harms for a demonstration of the embolic nature of an obstruction. These are:

(1) Proof of lodgment of the plug in a lumen previously free; and absence of primary disease of the arterial wall. (2) The finding of a source of emboli. (3) Absence of signs pointing to thrombosis.

Coats thinks that one of Harms' cases may have been of this character; and that cases published by Schweiger, Manz and Marple were examples of true embolism. It is evident that the mass of cases of retinal arterial obstruction reported do not meet these requirements, and that they ought not to be placed under the heading embolism. In Coats' case the glaucoma was secondary to hemorrhage into and inflammation of the iris. Coats suggests that the relation of obstruction of the retinal artery to glaucoma may be through coincident vascular disease of the iris, with thrombosis of the retinal veins, while the circulation is in abeyance.

As to the cause of retinal opacity in cases of arterial obstruction; Coats argues in favor of the view that it is not retinal edema, but an ischemic necrosis. He points out that in amaurotic family idiocy disease of the ganglion cells alone produces a similar picture, without any trace of edema. In the eyes suffering from obstruction that have been examined postmortem, the evidences of edema are slight, and not greater in the central region than in the periphery. Retinal edema does not spare the fovea, as we see in renal retinitis. On the other hand the localization of ischemic necrosis of the nerve fiber and ganglionic cell layers would perfectly account for the distribution of the opacity after arterial obstruction. In a case reported by Marin Amat (*Arch. de Oft.*, Vol. 12, p. 590, 1913) the retinal opacity was found after 19 months and had not completely disappeared a year later.

A case of blindness with the appearances of retinal embolism occurring a week after induced abortion at the fifth week with severe hemorrhage is reported by Gjessing (*Klin. M. f. Augenh.*, p. 595, Nov., 1912). When seen three days after the blindness the lower quadrant of the retina appeared normal, while other portions showed the picture of arterial obstruction. In the upper field the patient could see the light of a small candle, other parts being blind. The retina cleared up and became normal, and the field extended nearly to normal limits, leaving a relative central and absolute paracentral scotoma, and vision of 1/7 within six weeks. In a case reported under the heading of

embolism by Watson (*Ophth. Rec.*, Vol. 22, p. 103, 1913) the impairment of sight was somewhat gradual. The patient had myocarditis and blood-pressure of 160 mm.

In his review of the pathology of the retinal vessels, Harms (Graefe's *Arch. f. Ophth.*, Vol. 84, p. 101, 1913) reports a study of 4 cases in which both eyes became blind from obstruction of a central retinal artery; and brings together 15 other cases from the literature. In 4 of the cases the blindness involved both eyes simultaneously, or with an interval of three minutes as reported in one of them. In three cases the interval varied from 3 to 8 days. In the remaining cases the second eye was not affected for more than two months after the first, the longest interval being ten years. These patients showed general pathologic conditions including anemia, albuminuria, arteriosclerosis, senile marasmus, increased blood-pressure, aortic and mitral insufficiencies, cardiac hypertrophy, and dyspnea, amenorrhea and epistaxis; and one ended in apoplexy twelve years after the blinding of the first eye.

As to prognosis, Harms finds that for simultaneous bilateral blindness which has lasted for days it is absolutely unfavorable. But if a patient comes with such blindness of one eye he may truthfully be told that the chances of the second eye becoming similarly affected are slight. More than 70 per cent. retain good vision in one eye to the end of life.

Knorr (*Md. Med. Jour.*, Vol. 56, p. 218, 1913) reports the case of an otherwise healthy woman, the mother of ten children, who at 48 years suffered from sudden loss of sight in the right eye; but with retention of the field from the blind spot 5 degrees beyond the point of fixation. The ophthalmoscope showed the picture of arterial obstruction, with no retinal hemorrhages. She had full vision in the retained field. She suffered right hemiplegia nine months later. The left eye continued normal for twenty months after the right was affected, when suddenly its sight became dim, objects appearing silvery then gray, and were blotted out. The blindness was complete; the ophthalmoscope showed the same condition as had been present in the right eye.

Werner (Trans. *Ophth. Soc. U. K.*, Vol. 33, p. 9, 1913) reports a case in a boy who had headaches, and suddenly became blind in the left eye. Three days later the right was similarly affected. When seen three days after this the pupils were dilated, movable. There was no light perception, and the fundus showed the nasal appearance of embolism with a few hemorrhages. The Wassermann was negative, tuberculin positive. In six weeks he had recovered vision of 6/30

and 6/24 in very limited central fields. The discs became absolutely white, the vessels small.

Embolism of the internal carotid. Obstruction of this artery rarely produces eye symptoms when it occurs on the cardiac side of the ophthalmic artery because the circle of Willis furnishes a sufficient collateral circulation. As a rule the same observation holds good of obstructions in other portions of the vessel. Even ligature of the common carotid may produce only a temporary interference with the intraocular circulation and a fleeting disturbance of vision. Indeed all of these abnormal conditions within the lumen of the carotids are of importance only because of the danger of secondary embolism and thrombosis of the ophthalmic and retinal arteries.

Embolism of the ophthalmic artery. Owing to the anatomical fact that the branches of this vessel anastomose so abundantly with arterial twigs of the internal and external carotids embolism is clinically difficult or impossible to diagnose. It is likely that, so far as eye signs are concerned, at the moment of obstruction a temporary disturbance of vision may occur, such as is seen shortly after ligature of the common or internal carotid.

Emboloid. Resembling or pertaining to an embolus.

Embolus. A plug arrested in a blood-vessel or a lymphatic and causing obstruction.

Embrocation. The application of a liquid remedy to the surface, especially by rubbing. Any liquid medicament applied by rubbing; especially a liniment.

Embryograph. A modified compound microscope originally designed by His for drawing large objects like entire embryos with a camera lucida under an amplification varying from 4 to 70 diameters. It consists of a plano-convex lens from 2 to 3 ctm., in diameter, a small photographic or a low microscopic objective, a mirror, a stage to support the objects, and an ocular combined with a camera lucida, usually of the Oberhausen form. The varying powers are obtained by changing the relative position of the parts, and, as the ocular remains constant, the size of the final image, as with single lenses, depends on the law that the size of the object and that of the image are directly as their distance from the centre of the objective.—(Foster.)

Embryology of the eye. See **Development of the human eye,** Vol. V, p. 3862, of this *Encyclopedia*, as well as the same process in the lower animals discussed under **Comparative ophthalmology,** Vol. IV, p. 2519.

Embryontoxon. Sclerophthalmos. Macula arcuata. Arcus juvenilis. As stated in Vol. I, p. 560, of this *Encyclopedia*, this is usually

a congenital opacity of the cornea, situated within the clear cornea. It is a rare condition.

G. Attias (Graefe's *Archiv. für Ophthal.*, Vol. 81, part 3, 1912), considers arcus juvenilis as a probable persistent embryontoxon, a peripheral corneal opacity sometimes observed in the cornea of the newborn. Arcus juvenilis, too, is probably not a permanent opacity. He cites five cases of arcus juvenilis, and compares this form with gerontoxon as follows: 1. Arcus senilis occurs either as a complete circle consisting of a larger upper arc and a smaller lower arc, or as a single arc which is always located above. Walter is the only writer who claims that arcus senilis first appears in the lower half of the cornea, a view perhaps the result of mistaking the juvenile arc for cases of incipient arcus senilis. The juvenile arcus seldom occurs as

Distribution of Embryontoxon. (Attias.)

a complete circle; when it does, the upper portion is the more delicate. It is usually made up of two arcs, an upper inner and a lower external portion. A medial and a lateral arc sometimes occurs. The upper arc is the smaller. When only one arc exists, it is below and may be slightly external or internal. 2. Arcus senilis is sharply differentiated only peripherally, whereas the arcus juvenilis is sharply differentiated centrally and peripherally. 3. Gerontoxon is always bilateral and equally and symmetrically distributed. The arcus juvenilis may be present in only one eye; when it occurs in both eyes, its form and extent may differ in the two eyes. 4. Oblique illumination shows that the arcus juvenilis does not penetrate the corneal tissue as deeply as the gerontoxon.

Embryoscope. A device for enabling one to observe the course of development in eggs with shells, like the hen's egg. In its simplest form it consists of a thin piece of glass cemented by paraffin or in some other way over an opening through the shell and shell membranes. The embryoscope of Gerlach consists of a perforated, saddle-shaped metallic piece or holder, which is firmly cemented to the egg-shell. The egg-shell and its membranes are then cut away inside the perforation with a trephine, and a nut containing a glass window is screwed into the perforated holder. On suitably turning the egg,

the blastoderm comes up under the window and may be studied. With this appliance the development of eggs has been followed until the 13th day of incubation. (Foster.)

Embryoscopic. Pertaining to the examination of embryos.

Emden, Jakob. A well-known German surgeon, of slight ophthalmologic importance. Born at Frankfort-on-the-Main in 1796, he received his medical degree at Göttingen, presenting as dissertation "De Raphiarcestro, Novo Instrumento ad Coremorphoseos Methodum Perficiendam." This instrument is said by Stricker to be pictured in Blasius' "*Akiurgische Abbildungen,*" Berlin, 1833, plate 17, Fig. 72-77. Emden practised for a long time at Frankfort, and was for some years physician to the Jewish hospital. He died April 13, 1860.—(T. H. S.)

Emeralopia. (It.) Hemeralopia.

Emergent ray. In *optics,* a ray of light emanating from a transparent medium at whose surface it has or may not have suffered refraction.—(C. F. P.)

Emesia. (L.) Nausea. Vomiting.

Eméticité. (F.) The property of exciting vomiting.

Emication. Flying off in small particles.

Emilia sonchifolia. A species of plant common in the East. In China the leaves are eaten raw in salads. In the East Indies the cooling juice is prescribed in inflammation of the eyes. It is used as a decoction on the Malabar coast as a febrifuge, and the juice, mixed with sugar, is employed in bowel complaints. The pure juice of the leaves is used in Travancore for night-blindness.

Eminence lobée. (F.) A name given by Baudelot to the optic lobe in fishes.

Eminence, Superciliary. That portion of the external table of the frontal bone, corresponding to the upper-inner aspect of the superior margin of the orbit, just above the eyebrow.

Eminentia magna cerebri. (L.) A name for the optic thalamus.

Emission theory of light. Corpuscular or Newtonian theory. It is now abandoned, though its terms still remain in literature and affect thought. It was supposed that the propagation of light is by an actual transfer of material particles. See **Light,** as well as **Physiological optics.**

Emissive. Emittent. Radiating, or sending out.

Emissivity. Radiating power.

Emmenes. (L.) Hyoscyamus.

Emmert, Emil. A well-known ophthalmologist of Berne, Switzerland. Born at Berne Dec. 1, 1844, he studied his profession in that place, and

received his medical degree in 1868. After a period of graduate study in Berlin, Vienna, London, and Utrecht, where those who chiefly interested him were A. v. Graefe, Arlt, Critchett and Bowman, he settled in Berne (in 1870) and there continued to practise ophthalmology and to teach that subject as privat docent, until his death in 1911.

In addition to numerous articles, and a large amount of able editorial work (rendered as collaborator) he wrote: 1. *Refractions—und Accomodationsverhältnisse des Menschlichen Auges.* 2. *Schuluntersuchungen und Schulhygiene.* 3. *Auge und Schädel.*—(T. H. S.)

Emmetrope. A person whose eyes exhibit a normal refraction. See **Emmetropia.**

Emmetropia. In this refractive condition of the eye parallel rays of light are exactly focussed on the layer of rods and cones of the retina. While this is the mathematical definition of emmetropia, it is impossible to consider the functions of the visual organ as dominated by fixed mathematical laws. Such an eye cannot be termed a "normal eye," for it may easily be abnormal or morbid and nevertheless be emmetropic. If the emmetropic eye be considered, as it scientifically should be, as a perfect visual mechanism, in which parallel rays of light are brought to a focus exactly on that part of the retina devoted to distinct vision when the eye is in a state of rest, it is doubtful that it has any existence at all. The emmetropic eye, as it is clinically seen at times, is but a temporary condition in what is known as diminishing hypermetropia—the transitional stage between hypermetropia and myopia, a refractive halt in an irritated or inflamed eye that needs treatment.

An eye is normal in which the structures are free from disease associated with undisturbing physiologic action giving as nearly a normal visual result for both near and far as possible. The size or the shape is of no consequence. If it be healthy and acting properly, it is normal.

An eye in which the principal focus falls on the retina may vary in its dimensions: the shorter the radius of curvature of the cornea or of the lens, the closer the retina would have to be to the dioptric surfaces. Conversely, the longer the radius of curvature of the cornea or lens, the farther the retina must be from the dioptric surfaces. As extremes we may have an emmetropic eye with a corneal radius of 8.04 millimetres and an axis of 24.94 millimetres, or one with a corneal radius of 6.95 millimetres and a visual axis of 20.95 millimetres. Arlt adopts a corneal curve of 7.6 millimetres and an axis of 24 millimetres as the average standard in emmetropia.

In the newborn babe the average diameter in the visual axis is

17.495 millimetres, the average horizontal diameter is 17.2 millimetres, and the average vertical diameter is 16.38 millimetres.

Theoretically, the emmetropic eye is probably the best adapted for comfort, and should always be sought for, even though it is a theoretic standpoint that cannot be gained. While it may be a broad general rule to restore the eye to a condition of emmetropia by suitable glasses, the condition artificially obtained is not always the best for the well-being of the organ. A perfect vision obtained by neutralizing lenses may be fraught with increased physiologic action that is detrimental to the disturbed physical material.

The far point (*punctum remotum*) of the emmetropic eye is at infinity (∞). The position of the near point (*punctum proximum*) varies with age and accommodation. A biconvex spheric lens placed before such an eye will reduce the vision for far, for the reason that parallel rays will then come to a point in front of the retina. To use the accommodation under such conditions will make vision worse. Rays coming from the principal focus of a convex lens will be brought to a focus on the retina. A biconcave spheric lens placed in front of an emmetropic eye will make the rays divergent and will blur far vision, except the accommodation be brought into use. With the accommodation eliminated by a cycloplegic (atropin), the emmetropic eye will have vision of 6/6 or better for far, without the aid of a glass.—(J. M. B.) See, also, **Refraction and accommodation of the eye.**

Emollients. In ophthalmic therapy soothing applications are of considerable value both as excipients for salves, collyria and oily mixtures and alone, as in burns, hyperemia and inflammations of the anterior bulbar segment. Other non-oily preparations have a similar action. Among emollients may be noted albolene, sweet oil of almonds, antipyrine, cherry-laurel water, bitter-almond water, belmontin, "cocoa" butter, carron oil, castor oil, chamomile, cod liver oil, cold cream, cosmoline, quince, euphrasia, hamamelis, hazeline, milk, petrogen, petrolatum, plantago, mucilages, especially of acacia, tragacanth and sassafras pith, starch, unguentum simplex, vaseline, vasogen and wax.

Emorragia dalle palpebre. (It.) Hemorrhage from the lids.

Emottalmo. (It.) Hemophthalmus, or bleeding into the vitreous.

Empedocles. An early Greek philosopher and speculator concerning the nature of vision and light. A native of Agrigentum, in Sicily, he lived, probably, from 490 to 430 B. C. He was the first to describe the universe as consisting of four elements: earth, air, fire and water

—a doctrine which really constitutes the basis of the so-called "humoral" pathology.

His explanation of the act of vision was this: Light consists of rays which stream out both from the eye and the object. Through the meeting of the two kinds of rays, vision occurs.—(T. H. S.)

Empfindlichkeit. (G.) Sensitiveness.

Emphlysis. A term applied by Good to a genus of exanthematous diseases that included miliaria, aphthæ, vaccinia, varicella, pemphigus, and erysipelas.

Emphragma lacrimale. An obsolete name for lachrymal fistula.

Emphyma. A tumor.

Emphysem der Augenhöhle. (G.) Emphysema of the orbit.

Emphysema of the conjunctiva. A collection of air beneath the conjunctiva. This accident results from the same causes that produce a similar condition of the lids, viz.: fracture of the nasal bones or of the walls of the frontal or ethmoidal cells, or ulceration of the bones leading to perforation of these spaces. It may result from forcible blowing of the nose. The swelling caused by emphysema is tense, elastic, and crepitates on pressure. It may accompany ecchymosis or may exist alone. The proper treatment is the application of a compress bandage.—(J. M. B.)

Emphysema of the cornea. This is an exceedingly rare condition, and few references are made to it in literature. However, C. Gallenga (*Klin. Monatsbl. f. Augenh.*, p. 150, Feb., 1911), describes a case of corneal emphysema due to traumatism.

Emphysema of the eyelids. A collection of air in the cellular tissue of the eyelids not infrequently follows a compound fracture of the nasal bones or an operation upon the lachrymal canal. In either case, the patient, by blowing the nose, forces air into the cellular tissue. There is pain, sudden and great swelling of the lid, and air-tumefaction. Palpation gives a sense of crepitation and a peculiar soft feeling like that of a feather bed. The air comes from one or more of the adjacent cavities: the nasal fossa, ethmoidal cavity, frontal sinus, or antrum of Highmore. Emphysema may follow the operation of opening the ethmoid cells. Douglass has recorded cases in which emphysema of the upper lid followed an attempt to blow secretions from the nose, in patients who had suffered no operation or trauma. In these cases there was probably a pathologic opening between the ethmoid cells and the orbit. The prognosis of emphysema is favorable. A compress bandage should be applied.

A case of emphysema of the lids following fracture of the inner wall of the orbit from a blow of the fist is also reported in the *Ophthalmic Record,* Vol. VIII, p. 545.

Emphysema of the orbit. EMPHYSEMA ORBITÆ. A collection of air in the meshes of the orbital tissue, generally the result of traumatism and almost always accompanied by emphysema of the lids. For example, four cases of air emphysema of orbit, lids and ocular conjunctiva observed within a short time are reported by Salus (*Practical Medicine Series,* p. 54, 1910). In three of these the mesial orbital wall was injured, in the fourth the lower.

He believes emphysema to be due to communication with the ethmoidal cells after lesions of their orbital wall, the lamina papyracea; with the nasal cavity in fractures of the lachrymal bone; the frontal and maxillary sinus with their recessus in the orbital walls. By his experiments on human heads in the Anatomical Institute, the writer proved that the lamina papyracea is the place of predilection for indirect fractures in traumatism of the orbital walls. He therefore thinks that the traumatic emphysema with intact eyeball can, in general, occur only by indirect fractures.

C. S. Bull (*System of Diseases of the Eye,* Vol. III, p. 20) says that orbital emphysema is an important aid in enabling us to diagnose direct fracture of the inner wall of the orbit, whether involving the ethmoid, the lachrymal, or the nasal bones. It should not, however, be ignored that a communication between the orbit and certain air-spaces in the skull may also be caused by a fracture or dislocation of the inferior or superior orbital walls, opening, on the one hand, into the maxillary sinus, and on the other into the frontal sinus, although both communicate indirectly with the sinuses of the nose and ethmoid cells.

Emphysema of the orbit is usually associated with a similar condition of the eyelids. The extravasated air generally comes from the ethmoid cells. The first symptom here is exophthalmos, which is increased by forced expiration. The protrusion of the eye is accompanied by some displacement and by some limitation in motility, as a result of the mechanical obstruction. The exophthalmos diminishes under direct pressure upon the eyeball backward. The cause is commonly a severe injury which has fractured the orbital wall directly or indirectly, and usually the inner wall, and which has at the same time ruptured or torn through the periosteum. Any forced expiration will immediately drive the air through the fracture into the orbital tissue, and even in ordinary respiration some air is certain to pass into the orbit. In the cases reported, where emphysema of the orbit occurred during violent coughing or sneezing, without any preceding injury, the probable explanation is that some loss of continuity of the

bony wall had always existed, and the first unusually violent expiratory effort produced the emphysema.

The *prognosis* is always good, and the *treatment* consists in the careful avoidance of any violent expiration and the application of a light pressure-bandage.

Empirical. Empiristic. Empiric. Derived from experience only, or from experiment only; depending upon or derived from the observation of phenomena.

Empiricism. Empirism. The empirical or purely experimental method. The practice of an empiric or charlatan, not based on scientific data.

Empiricism in ophthalmic practice. See **Charlatan**; as well as **History of ophthalmology.**

Employees, soldiers and sailors, Examination of the eyes of. See **Eyes, Examination of in commerce and public service.**

Empoisonnement. (F.) Poisoning.

Empreinte. (F.) Ridge or margin. A rough surface on a bone for the attachment of muscles.

Empyema. A collection of pus in a natural closed cavity, e. g., in the antrum of Highmore. The name was anciently used by Hippocrates to signify a suppuration; by Galen to mean an internal abscess. The ophthalmic relations of empyema of the neighboring cavities are fully discussed in Vol III, p. 1810, of this *Encyclopedia.* They are also considered under a number of headings beginning with **Empyema.**

Empyema of the frontal sinus. This subject, including the rhinological and ocular treatment, is discussed under the caption **Cavities, Neighboring, Ocular relations of.**

In a case operated upon by Knapp (*Arch. of Ophth.*, March, 1909), the bony cerebral wall of the frontal sinus was absent, the thickened membrane lining the cavity being directly adherent to the dura. The anterior bony wall was also greatly thinned, consisting in places of only the vitreous plate.

Empyema of the malar antrum. A collection of pus or muco-pus in the maxillary antrum is well known to be a cause of eye symptoms. For a discussion of this subject the reader is referred to Vol. III, p. 1810 of this *Encyclopedia,* **Cavities, Neighboring, Ocular relations of.**

Empyema of the orbit. Pus may form in the orbital cavity as a result of direct infection, as in cellulitis of various origins, or from the inruption of purulent collections from the neighboring cavities. The treatment of such cases resolves itself mainly into the removal of the

cause, with prompt operation on the diseased sinuses. See Vol. III, p. 1810, of this *Encyclopedia.*

Empyema of the sphenoidal sinuses. This subject in its ophthalmic relations is discussed in Vol. III, p. 1810, of this *Encyclopedia.* It may be added that a typical example of a serious case is described in the *Ophthalmic Record,* Vol. VI, p. 346, in which the symptoms were chiefly marked exophthalmus and divergence of the eye on the affected side. There was also extensive edema of the face and neck. Death followed and the autopsy disclosed a hitherto unrecognized empyema of the right sphenoidal sinus.

Empyesis oculi. (L.) An obsolete synonym of hypopyon.

Emulsa. See **Emulsions.**

Emulsions. EMULSA. EMULSIONES. In *photography,* a term applied to a mechanical mixture of a sensitive salt of silver very finely divided.

In *pharmacology,* emulsions are liquid preparations in which oils or resins are suspended in water by means of a mucilaginous substance. Acacia, mucilage of acacia, mucilage of tragacanth and yolk of eggs are the substances most frequently employed, although solutions of potassa and of pancreatin aid in the emulsification of oils and often enter into the formulæ for emulsions. Schnaudigel (*Münch. Med. Wochenschr.* LVIII, p. 164) describes the use in ophthalmology of the well known "bacillary emulsion," Koch. See **Tuberculin.**

Enallochrome. (F.) Bicolorin. A white powder, from the bark of *Esculus hippocastanum,* employed as a test, like fluorescein.

Encanthis. (L.) A small tumor or excrescence growing from the inner angle of the eye. This term is also applied to a simple, inflammatory hypertrophy of the caruncle. It is sometimes attended by infection and swelling of the sebaceous glands, and may lead to suppuration, in which case the small abscess should be opened. See, also, Vol. II, p. 1432, of this *Encyclopedia.*

Encanthis benigna. (L.) A simple inflammatory swelling of the caruncle, which usually starts from the plica semilunaris. It is common in all acute cases of catarrhal conjunctivitis.

Encanthis calculosa. (L.) The formation of masses of concretion in the glands of the caruncle, causing irritation and swelling of the caruncle.

Encanthis carcinomatosa. (L.) Cancerous degeneration or disease of the lachrymal caruncle and the surrounding tissues at the internal canthus.

Encanthis fungosa. (L.) Cancerous degeneration or disease of the lachrymal caruncle.

Encanthis inflammatoria. (L.) A simple inflammatory swelling of the caruncle, which usually starts from the plica semilunaris. It is common in all acute cases of catarrhal conjunctivitis.

Encanthis maligna. (L.) Malignant degeneration or disease of the lachrymal caruncle.

Encanthis scirrhosa. (L.) Same as **Encanthis carcinomatosa.**

Encanthoschisis. By this term Hirsch (*Klin. Monatsbl. für Augenheilk.*, July, 1912) designates a splitting of the caruncle which he saw in two individuals, and suggests the term as descriptive of the anomaly. He believes that the widely accepted theory of Van Duyse, according to which congenital defects about the lids are due to amniotic strands which cross the vicinity of the eyes and become entangled about the lids, probably explains this interesting and apparently rare condition.

Encausis. (L.) Burning, cauterization.

Encephalitis. ACUTE HEMORRHAGIC ENCEPHALITIS. POLIOENCEPHALITIS SUPERIOR AND INFERIOR. According to D'Orsay Hecht (Wood's *System of Ophthalmic Therapeutics*, p. 305) this is an acute inflammatory process, quite invariably of infectious origin, occurring mostly in children, but in adults as well, and confined, as a rule, to a single small area in the brain, perhaps pin-point in size, or multiple and disseminated. Whether of the acute hemorrhagic variety affecting children, or in the alcoholic type of Wernicke, occurring in adults, a partial or complete ophthalmoplegia is the symptom of first importance, and optic neuritis is often noted.

There can be no rational prevention since the acute infections, toxemias and exanthemata overtake the patient suddenly and are not amenable to abortive measures. Timely abstinence is good advice, when chronic alcoholism is the cause.

The *treatment* during the acute febrile stage is entirely symptomatic, with the same regard shown for absolute quiet, rest, elevation of the head, as obtains in brain hemorrhage.

Cerebral irritability, restlessness and headache are best relieved by the ice-cap, cool sponges or small doses of phenacetine, quinine or the salicylates. Active catharsis is desirable from the very time of onset. The use of unguentum Credé (grs. xv to ʒi) seems indicated in these cases, and is surely worthy of trial. Collargol, another colloidal silver preparation, has received both attention and acknowledgment in this disease. It may be given per rectum in solution or intravenously 3 to 5 c.c. of a 2 per cent. solution for as many consecutive doses as there is demand. The injection is painless and its effect is good. For the delirium, which is likely to be marked and sometimes associated with convulsions, morphine, opium and the milder somnifa-

cients, such as veronal, trional, sulphonal and chloralamid, are indicated. In adults suffering from the alcoholic type, the best combatant of delirium, especially in young, robust individuals with marked motor restlessness, is hyoscine hydrobromate, gr. 1-150 to gr. 1-50, given hypodermatically, and the writer has frequently seen its narcotic effect greatly enhanced by the addition of morphine sulphate, gr. ⅛ to gr. ¼. It must not be repeated often and its failure to act at all in some cases must be understood. Opium should be given only as a last resort, and not at all when arterio-sclerosis is noted. Alcoholic stimulation in these cases should not be entirely withdrawn, and general stimulants are of use as urgent symptoms arise.

The convalescence calls for such general measures as are serviceable in apoplexy. Electricity is of use in the chronic stage. It has been customary to advocate mercurial inunctions and iodides for the remaining focal symptoms, but their administration is of very doubtful value.

Encephalocele. CEPHALOCELE. This is the term applied by Berlin to cysts invading the orbit secondarily. These tumors are located at the root of the nose and extend to the orbit, nasal cavities, or brow. As a rule they are present at the nasal side of the orbit, and are transparent and fluctuating. Evacuation of a cephalocele is often sufficient to cure it, provided the cystic cavity is afterwards irrigated with an antiseptic, astringent lotion.

Encephalocele is really a prolapse, or hernia, of the meninges with cerebro-spinal fluid contents, including brain-substance prolapsing within the meningeal sac through an opening in the skull wall. The bony defect is generally in the line of a suture. It may involve the junction of the ethmoid and the frontal bone, the tumor then presenting at the upper-inner orbital angle. Very rarely a posterior orbital meningocele, or encephalocele, presents near the apex of the orbit. Its diagnosis without exploratory operation is impossible. The following points must be observed: Meningocele and encephalocele are often reducible, and after reduction the bony margin of the aperture through which they came can be felt. Pulsation and hemic sounds can be elicited. The size and tension of these protrusions are variable, depending upon varying blood-pressure within the cranium. A dermoid cyst will present none of these phenomena. A meningocele may become constricted and its neck obliterated, leaving a complete cyst with cerebral fluid contents within the orbit.

Although Berlin in 1880 (Wood's *System of Ophthalmic Operations,* Vol. 1, p. 844) placed these tumors of the orbit among inoperable growths, yet improvement in the technique, and particularly the observance of aseptic precautions, have brought surgical intervention

in their behalf within the province of the operator. We are mostly interested in sincipital tumors and the removal of the whole sac with its contents has been recommended by Bergmann.

Naso-orbital encephaloceles, including encephalocele and hydrencephalocele, are the commonest variety with which the ophthalmologist has to deal, although the prognosis in both instances is by no means encouraging.

In dealing with small encephaloceles an incision is made through the skin and muscular coverings at the most prominent part of the tumor, or if that is undesirable owing to degenerative changes, the opening may be made elsewhere. The sac is generally of a transparent, scar-like quality and is often the seat of vascular changes, like a telangiectatic angioma. The meningeal coverings are wanting in some cases so that the tumor is in direct contact with the brain substances.

The encephalocele is, as a rule, easily separated from the surrounding tissues back to its pedicle which, after ligation with catgut, is cut through close to the bony foramen, the tumor removed, the skin wound sutured and an antiseptic dressing applied.

Large-sized encephaloceles require an extensive procedure. Two semi-circular skin flaps are fashioned at the base of the tumor to cover the defect caused by its removal. These are turned back, the pedicle exposed and cut off 2 or 3 cm. from the bone. The borders of the sac are stitched to the opening in the cranial cavity and it is often necessary to reinforce this covering by a second one. In this operation protruding brain matter involved in the tumor should be removed with it.

Elschnig remarks that the operation is contra-indicated in abnormally small skulls—"frog-head:" in marked hydrocephalus, and in complications with other malformations that threaten the life of the child.

An instructive case of fibro-gliomatous encephalocele is described by Comninos (*Arch. d'Ophtal.*, XXXI, p. 177, 1911).

Encéphalo-oculaire. (F.) Pertaining to the brain and to the eye.

Encephalopathy, Lead. Saturnism. Lead poisoning affecting the brain or other portions of the nervous apparatus. See **Toxic amblyopia.**

Encephaloscopy. Cranioscopy. Cerebroscopy. The art or process of examining the brain, as by examining the fundus oculi, by applying a differential calorimeter, X-ray, etc.

Enchondroma. Cartilaginous tumor. Chondroma. New growths composed partly or wholly of cartilage occasionally affect the eye; among them enchondroma of the lids occurs as one of the rarest

neoplasms. The commonest form is that affecting the orbit, a brief account of which will be found under the heading **Chrondoma of the orbit.** See, also, a more complete account under **Tumors of the eye.**

Enchymatism. Instillation; infusion.

Encolor. To color.

Encre. (F.) Ink.

Endanastomose. (G.) A terminal anastomosis.

Endangium. The intima or lining coat of a blood-vessel.

Endartère. (F.) The internal coat of an artery; the intima.

Endarteritis. Inflammation of the intima, or innermost coat of an artery. The *acute form* is rare, and only occurs in the aorta and the larger arteries. Ulceration is very rarely present. The *chronic form*, also named *atheroma*, and *arteritis deformans*, is a peculiar change or degeneration occurring in the arterial coats of the aged, and is preceded by a fatty degeneration of the tissues of the arteries. Syphilis is supposed to play an important part in the production of this condition. The immediate cause, however, is mechanical irritation due to the force of the circulation. The fatty débris and the cholesterin that are formed during the degenerative process accumulate in spaces beneath the intima and constitute the so-called *atheromatous abscesses.*

The so-called *atheromatous ulcer* is formed by one of these abscesses breaking through the intima. The sequelæ of *atheromatous degeneration* are very grave. Aneurysm, thrombosis, embolism, and apoplexy frequently result, and hence the ultimate prognosis is bad. (Gould.) See, also, **Arteriosclerosis**, p. 612, Vol. I of this *Encyclopedia.*

Endarteritis deformans. A term applied to arteriosclerosis, often to the cerebral form of the disease. Hecht (Wood's *System of Ophthalmic Therapeutics*, p. 299) says of this serious affection, which is sometimes responsible for ocular lesions, that an endarteritis may cause thrombosis and embolism and finally, by dilatation and weakness of the vessel wall, rupture and hemorrhage. In either instance disintegration of brain tissue ensues, with corresponding arrest of cerebral function.

The visual apparatus is not exempt from the influence of atheromatous changes and sclerotic processes occurring in the brain. The optic chiasm and optic nerve undergo changes evidenced clinically in hemianopsia and atrophy. In some cases of general arterio-sclerosis the ophthalmoscope reveals sclerotic changes on the retinal arteries. Pupillary anomalies are observed.

Arterio-sclerosis, when more or less general, lends itself to treatment with difficulty unless the many irritative conditions underlying

and responsible for the vascular changes are well taken into account. Interstitial nephritis, diabetes, the various diatheses, of which gout, rheumatism and arthritis are the most important, the acute infectious diseases, infections and poisoning from lead, should receive early and proper treatment, and so delay the appearance of arterial changes.

Since chronic alcoholism is said to cause twenty-five per cent. of the cases, spirits or alcohol in any form should be used in greatest moderation, or, better still, absolutely interdicted. As one writer has aptly put it, "Could we ensure everybody against excessive bodily and mental strain, we should go far to obviate arterial changes and their allies, concomitants and results." All observers are agreed in emphasizing the dangers of the "strenuous life" as causative of vascular change and disturbance, and yet much, if not all, such advice is met by the laymen with stolid indifference and utter disregard. The demands of modern methods of business and living are naturally opposed to the forms of restraint and reserve encouraged by the doctrinaires of the simple life. Moderation in all things, food, drink, work and play, is observed in the breach but not in the practice, and little is to be gained for the patient by the insistence of preventive measures until our modern institutions of industry and society shall have undergone some radical and far-reaching reforms. Suffice it to say that in the reduction of excesses of all kinds we have the first solution of prophylaxis against inelastic arteries and insufficient vascularity of the body tissues.

A person suffering from beginning endarteritis should be made to understand and value the importance of regular habits of living. Moderate exercise is desirable, but never to a point of fatigue, profuse sweating or cardiac palpitation. Walking and golf are probably the most desirable of the outdoor activities, to be supplemented by morning and evening indoor calisthenics. Gymnastics are too active, and by that same token tennis and rowing are to be interdicted. Every sudden exertion, even when not violent, should be guarded against. Obesity, whenever a factor, requires special instruction as to exercise, while localized massage to the abdomen or other parts should prove of additional value. The cold morning plunge, attended as it invariably is with sudden shock to the circulation, is to be avoided, and the hot bath as well. Tepid bathing in water ranging from 92 to 98 degrees Fahr., is desirable. The special Nauheim baths are indicated except where there is reason to believe that the cerebral vessels are badly sclerosed and the blood pressure is low.

A diet should be prescribed in accordance with the needs of the individual. The food should be simple, nonirritating, easily digested,

nutritious and taken in such amount and at such regular intervals as to preclude gastro-intestinal fermentation and distress. There has been some question as to the admission of nitrogenous values in the dietary. A vegetarian meal, with white meats, is preferred, but red meats are to be occasionally allowed. Eggs are permitted, and milk taken daily in large quantities, as recommended by Huchard, has found favor with Oppenheim and others. Condiments and strong coffee are harmful and should be dispensed with.

The feasibility of a routine administration of iodides as first advocated by Huchard, although questioned by some authorities, has, on the whole, met with favor. That iodine preparations materially influence endarteritis of other than luetic origin is doubted, and yet there are those who continue to be impressed by their action on any and all exudative and connective tissue processes. Hence the use of potassium or sodium iodide in small doses for a protracted period of time in every case of arterio-sclerosis. Huchard has advised doses of from fifteen to forty-five grains, given daily for twenty days, to be followed after a free interval of ten days by appropriate doses of nitroglycerine. When atheromatous degeneration is of known syphilitic origin, there can be little or no question as to the expediency of an early and thorough exhibition of the iodides in some form.

The nitrites (sodium nitrite in solution, gr. ½ to the teaspoonful) taken after meals more or less continuously have proven efficient in relieving high arterial tension. In more urgent instances nitroglycerine or its derivatives may be administered in doses of from gr. 1-100 to gr. 1-50, three to four times daily. Erythroltetranitrite (Merck.), in pill or tablet form (gr. ½ to gr. 1) is said to be more prolonged in its effect than nitroglycerine.

Cardiac tonics are directly injurious, and therefore contraindicated. Morphine in small doses is a valuable nerve sedative and cardiant.

Due observance of these precautionary and palliative measures should check the tendency of sclerosed vessels to progress to the point of obliteration or rupture.

Endarteritis productiva. A synonym of arterioselerosis (q. v.), often applied to the cerebral form.

Endartery. (G.) A term applied by Cohnheim to an arteriole that terminates directly in capillaries without anastomosing with other arterioles. A well-known example of these vessels is found in the terminal branches of the central retinal artery.

Endast. (G.) A terminal branch.

End-bulb. According to Foster this term is generally applied to the expanded termination of a sensory nerve; an ovoid or mulberry-

shaped body with a central core (composed mostly of nucleated corpuscles and a connective-tissue sheath) in which a medullated nerve-fibre has a knob-shaped termination. The end-bulbs are considered intermediate between the Pacinian and the tactile corpuscles. They have been found in various parts of the body, and have been named from their form (e. g., spherical or cylindrical end-bulbs) or from their situation (e. g., corneal, articular, or tendon end-bulbs).

Endeixis. A symptom; sign; indication of disease.

Endermie. (F.) The introduction of medicinal substances through the skin by absorption.

Endigung. (G.) A termination; ending.

Endocarditis. Lesions of the endocardium may be a cause of embolic processes of the intraocular vessels. Other eye diseases may have the same etiology. For example: Falconer (*Quart. Jour. Med.*, p. 217, Jan., 1911) reports five cases of septic endocarditis in all of which there was definite optic neuritis in the two eyes, where an examination of both eyes was possible. In only one were there signs of gross brain lesion. In four there were repeated retinal hemorrhages. The case in which they were not noted was one examined four days before death. In the absence of autopsy it was impossible to state that there was no local cause for the optic neuritis, but there appeared to be nothing to suggest it. The significance of the ocular findings lies in the hint that they give that the condition is more serious than may be at first apparent.

Endocular. Intraocular.

Endodiascopy. Bouchacourt's (1898) method of exploration characterized by the introduction of a Crookes tube into a natural body-cavity in order to obtain either a skiagraph or a skiascope. (Gould.)

Endogenous ophthalmitis. This is a term sometimes applied to metastatic choroiditis. See p. 2146, Vol. III, of this *Encyclopedia*.

Endomersion objective. A combination of lenses in contact with one another, the central element being a liquid.

Endometritis, Ocular relations of. This disease, especially the markedly septic variety, has been quoted as an occasional focus of endogenous ocular infection.

Endophthalmitis. Intraocular inflammation.

End-organ. The special structure in which nerve-fibres terminate at the periphery, e. g., the red-, blue- and green-sensitive end-organs of the retina.

Endormie. (F.) Datura stramonium.

Endoscope. Entoscope. An instrument for the optical examination of a body-cavity through its natural outlet.

Endothelioma of the ocular apparatus. This malignant neoplasm of the sarcoma type generally affects the orbital tissues, although there are few ocular organs that are exempt from its ravages. Parsons, in describing these tumors of the eyelids, says that they "start in the endothelium of the blood or lymphatic vessels. There can be no doubt that such tumors form an important class, and, when typical, are not difficult to differentiate from other sarcomata or from epitheliomata. On the other hand, endothelial proliferation is common in many tumors and granulomata, whilst the endothelium in many endotheliomata is said to so alter that the cells become spindle-shaped, asteroid, etc., and they cannot be distinguished from embryonic connective-tissue cells. How far this is true may be held open to doubt in the present state of knowledge. I consider that the term endothelioma is useful where the origin from endothelium can be demonstrated or is reasonably probable; but where great metaplasia, or change in the form of the cells, is supposed to have occurred, resulting in atypical forms, I think the term is better avoided, the growths being called sarcomata, according to the old nomenclature. Only a false idea of certitude is arrived at by dogmatic nomenclature, and the effect is to retard precise knowledge. Hinsberg considered four out of eight epitheliomata of the lid to be endotheliomata, and Ginsberg three out of six; these are probably examples of enthusiasm outrunning discretion."

Of endothelioma of the orbit Kuffler (*Bericht der Oph. Gesell,* 1911) remarks on the scantiness of authoritative pronouncements on the nature of endothelioma.

He remarks a connective tissue stroma consisting of homogeneous fibres, in places undergoing hyaline degeneration; enclosed in the stroma are masses of cells, some of them irregular, others arranged in star-like fashion or as a network of anastomosing columns with sinus-like enlargements at the junctions. Where a muscle is invaded by the tumor the spaces between the muscle fibres are occupied by a single or double layer of flattened cells forming a fine network around them and at a later stage involving their degeneration. Fatty tissue shows a similar method of invasion. Whether these cell columns are derived from the endothelial lining of the lymph spaces, or whether they advance from a primary focus into pre-formed spaces, must be left an open question, but in either case the mode of growth is in contrast with the compact advance of a carcinoma or sarcoma. The forms of the cells themselves are various. In the cell columns just mentioned the inner layers are often flat, the external ones more cubical. In the irregular masses of cells spindle cells, round cells and

all kinds of intermediate forms are found. In several places epithelium-like cells are arranged in concentric layers but nowhere are there any horny cells or prickle cells.

The writer considers that the most probable source of his tumor was the dura mater in the region of the optic canal and supra-orbital fissure. As characteristic marks of endothelioma he puts the following. Malignity of the tumor along with small tendency to metastasis and strong tendency to local recurrence. Polymorphism of the tumor elements. Apparent connection of the tumor cells with the endothelium or perithelium of blood or lymph vessels, or with the lining of lymph spaces. An alveolar or tubular structure. Hyaline degeneration. Concentrically arranged epithelioid cells without horny cells or prickle cells.

The whole subject of endothelioma of the eye will be completely treated under the major heading **Tumors of the ocular apparatus.**

Endothelium. This term was applied in 1866 by His to a single layer of flattened cells joined edge to edge to form a covering for the free surface of serous membranes, for the cavities of the heart and blood-vessels, and, in general, for any free surface excluded from contact with air, the anterior chamber, for example. See **Cornea.**

End-pieces. The parts to which the temples are attached in rimless spectacle mountings; they include the straps which are really a part of them.

End-plate. The termination of a motor nerve-fibre in a striated muscular fibre.

Enduit. (F.) Coating: layer.

Endurcissement. (F.) Hardening.

En echelle. (F.) Disposed like the steps of a ladder.

Enelpidis collyrium. (L.) An ancient collyrium containing castor, lycium, nard, opium, saffron, myrrh, aloes, copper scale, calamine, antimony, juice of acacia and gum.

Energy and the eye. Perhaps no subject in physiological optics has been more misunderstood and less thoroughly studied than the actual effect of radiations received by the eye. A great deal of labor, in no small degree useless, has been expended on the subject without reaching conclusions of final value. The weak point of investigation has nearly always been the utter absence of any quantitative data. An experimenter finds that some kind of energy, heat energy, strictly luminous energy or ultra-violet energy, does or does not produce certain effects on the eye, and immediately proclaims the fact entirely regardless of the actual quantity of energy responsible for the result or lack of it.

M. Luckiesh (*Electrical World*, Oct. 25, 1913) takes up the question of the possible effect on the eye of the absorption of energy, chiefly other than luminous. With most artificial illuminants, at least those giving continuous spectra, by far the greater part of the radiation is in the infra-red invisible portion of the spectrum. Hence the possible effect of infra-red radiation and its absorption by the media of the eye may have importance.

An often-quoted statement of C. P. Steinmetz as to the importance of energy effect of this sort has served to direct attention to the subject, although as a matter of fact there is not one bit of practical experimental evidence one way or the other connecting this energy effect with eye-strain or irritation. The cause of the ordinary eye-strain in poor natural or artificial illumination is very far from being really understood. Nevertheless, Steinmetz's suggestion is worth attention, and the actual absorption of radiant energy by the media of the eye is a very desirable thing to know. This Luckiesh has given us in a measure of the absorption of the media, considered as water, for the total radiation received from radiators at different temperatures. The chief seat of absorption is shown to be in the cornea, this being the first layer encountered and consequently in obedience to the general laws of absorption producing the maximum effect. Not only does the cornea absorb a large amount of the incident energy in general, but it also has a strongly selective absorption for the extreme ultra-violet, cutting off entirely rays below 300 $\mu\mu$. in wave length. Most of the remaining ultra-violet is cut off by the lens, but the whole ultra-violet factor in the luminous sources considered by Luckiesh is practically rather small. The radiation is absorbed largely by the cornea, but this superficial layer, of course, is cooled with exceptional readiness, so that in a degree it is self-protected. If the whole effect of radiation on the eye were expressible in terms of this absorption by the media, one could very readily figure out in any given case the actual incidence of energy in ergs per second per square cm. and get a very satisfactory measure of the amount of energy effect with which one has to deal.

Recent investigations have shown it to be highly probable that the general energy radiation, rather than any specific kind of radiation, is responsible for some ocular troubles which have been noticed, especially glass-blower's cataract, in an earlier state of knowledge ascribed to ultra-violet radiation. Luckiesh's figures, however, show that the total amount of energy received from this particular source in bodies, like molten glass, at rather low temperature must be very

small and that the cornea cuts off a large proportion even of the heat radiation.

The two points which Luckiesh's investigation does not throw light upon, and which may be justification for Steinmetz's statement, are that the concentration of energy, owing to the refraction of the media, increases very rapidly from the front to the back of the eye. Perhaps three-quarters of the total refraction is at the surface of the cornea, so that there is some concentration at the front of the lens, more still at its back, and most of all on the retina, where the pigmentation insures the absorption of practically all radiation that reaches it. Hence there may be discomfort or even damage, as in eclipse-blindness, produced under strong general radiation even in spite of the large absorption of the superficial layers. Incidentally it should be mentioned that in dealing with solar radiation at an equivalent temperature of about 6000 deg. the point of maximum intensity is no longer in the infra-red or in the part of the spectrum vulgarly supposed to be the seat of heat radiation, but in the region of the blue, so that for this particular source any distinction between visible radiation in general and heat radiation becomes utterly lacking in significance.

Burge (*Journ. A. M. A.*, Dec. 19, 1913) summarizes his observation as follows: Radiation from a quartz mercury vapor lamp which is sufficiently intense to coagulate egg albumin, egg globulin, vitellin, serum albumin and serum globulin in one hour does not coagulate the protein of the normal lens or of the vitreous or aqueous humors, and hence does not affect the transparency of these structures after a continuous exposure of 100 hours. The region of the ultra-violet spectrum effective in coagulating the egg-white lies between 265 and 302 microns. The region most effective lies around 265 microns.

The lens protein can be modified by solutions of calcium chlorid, magnesium chlorid, sodium silicate or dextrose too weak of themselves to affect the transparency of the lens so that ultra-violet radiation can precipitate the modified lens protein and hence produce opacity of the lens. The effective region in case of modification of calcium chlorid is from 265 to 302 microns inclusive. The most effective region lies around 265 microns. Analyses of senile cataractous human lenses show that calcium, magnesium, and, in lenses from India, silicates are greatly increased in this type of cataract. The assumption is made that the accumulation of these substances modifies the lens protein in such a way that the short waves of the spectrum can precipitate the protein, thus producing opacity or cataract. In the case of diabetic cataract the accumulation of sugar in the liquids of the body so modifies the lens

protein that the short waves of the spectrum can produce opacity, hence the prevalence of cataract in this disease.

The above named substances, which so alter the lens protein that the short waves can precipitate it, at the same time decrease the fluorescence of the lens. This suggests that there may be some relation between this latter property and the great resistance of the normal lens protein to ultra-violet radiation. In looking for the cause of cataract it would seem that at least two factors are to be considered, the one, a modification of the lens protein, and the other, radiation of short wave lengths by which this modified protein can be coagulated. Radiation from the infra-red, or the visible region of the spectrum cannot coagulate either the modified or the unmodified lens protein provided the coagulation due to heat be excluded.

Enfance. (F.) Childhood.

Enfisema. (It.) Emphysema.

Enflammé. (F.) Inflamed.

Enflé. (F.) Inflated; swollen.

Enflure. (F.) Inflation; tumefaction.

En froid. (F.) In the unheated condition.

Engainé. (F.) Enclosed in a sheath.

Enge. (G.) Stenosis; also a contracted part.

Engelmann, Theodor Wilhelm. Born at Leipsic, Nov. 14, 1843, he studied from 1861-67 at Jena, Leipsic, Heidelberg and Göttingen. Returning to Leipsic in 1867, he there received his medical degree, presenting as his thesis "Ueber die Hornhaut des Auges." He settled at once in Utrecht, where he became assistant to Donders at the Utrecht Physiologic Laboratory. Soon thereafter (Mar. 20, 1871) he became docent, at the Utrecht University, and later, full professor —a position which he held till his death, which occurred in 1909.

He wrote a large number of articles on physiologic subjects, in which he paid considerable attention to the physiology of the eye. —(T. H. S.)

England, Laws of, relating to ophthalmology. See **Legal relations of ophthalmology.**

English convention of signs. See **Convention of signs.**

Engoué. (F.) Obstructed; choked up.

Engyscope. ENGISCOPE. A reflecting microscope.

Enhydric. ENHYDROUS. Containing water.

Enixanthos. As its name implies, this is a smoky-yellow tinted glass dating from 1906 and manufactured in Germany. It resembles the Hallauer glass and used like it for making colored protectives.

Enoftalmo. (It.) Enophthalmos.

Eno, Henry Clay. A well-known American ophthalmologist. Born in New York City, Oct. 12, 1840, son of Amos Richards Eno and Lucy Jane Phelps, he received his medical degree at the College of Physicians and Surgeons in the City of New York in 1864. Settling in New York City as ophthalmologist and oto-laryngologist, he soon had a large private practice and was for some years attending surgeon at the New York Eye and Ear Infirmary.

He married, Oct. 19, 1869, Cornelia Lane, daughter of George W. Lane, of New York City. She died May 2, 1907.

Henry Clay Eno.

Dr. Eno was a small, lean man, who wore no beard but a mustache, of a fair complexion and with brown eyes and hair. His manner was quietly humorous. He read widely, and was a good all-round scholar. He was a well-known collector of rare books, and was interested, as he himself was often heard to say, in almost everything except politics and religion.

Dr. Eno died at his home in New York City, July 16, 1914, aged 74.—(T. H. S.)

Enophthalmia. Retraction of the eyeball in the orbit.

Enophthalmin. Oxytolnylmethylvinyldiacetonalkamin hydrochlorate. A substance closely allied to eucain; it is used as a mydriatic in 2 to 5 per cent. solution.

Enophthalmos. ENOPHTHALMUS. A condition (generally due to traumatism) in which the eye is less prominent than normal. This "sinking of the eye" may occasionally be due to causes other than injury. It may, for example, be an idiopathic affection proceeding from a lesion of the cervical portion of the sympathetic nerve. Atrophy of the orbital cellular tissue with loss of fat, loss of water due to cholera (von Graefe), and abscess of the orbit are also causes. The extent of enophthalmos may be judged by comparing the diseased with the sound side.

When enophthalmus is caused by trauma it is followed by absorption of the orbital fat. There are recognized the tropho-neurotic, cicatricial, and mechanical forms of *traumatic enophthalmos.*

The tropho-neurotic type occurs after blows from large objects upon the margins of the orbit or the skull, which cause a sinking of the bulb into the orbit; also from tropho-neurotic absorption of the retro-bulbar orbital fat following lesions of the nerve trunks or the centers. Cicatricial enophthalmos is caused by periostitis of the orbit, causing contraction of the connective tissues and of the orbital fat. Through inflammatory processes in the orbit with cicatricial contraction, Tenon's capsule and the globe become more or less atrophic.

Mechanical enophthalmus is due to a fracture of the orbital walls causing depression down and back. In tropho-neurotic enophthalmus the bulb loses its motility and the sight is lost.

Most of these cases are caused by blows from large objects upon the orbital walls, usually above, sometimes on one side, which produce fracture of the bones. The cause of the condition is a rupture of Tenon's capsule, or the thickened bands of this, known as the check ligaments, and as this contains smooth muscular fibers which are innervated by the sympathetic, a peripheral or central lesion of this would cause relaxation of the smooth muscular fibers of the check ligaments and also atrophy and absorption of the orbital cellular tissue which permits the eye to sink backward, according to the theory of Beer.

When there is no gross depressed fracture, the most rational explanation is that of absorption of orbital fat, due to pressure, incident to the violent cellulitis, confined, as it is, within an inelastic bony cavity. Immediately upon subsidence of the intraorbital swelling, the loss of fatty cushion becomes manifest and the eye recedes. Nieden says:—"The relationship of the cellulitis to the traumatism varies. There is usually a wound of the lids or a fracture of the orbit, either direct or indirect. Doubtless a hematoma frequently plays an important rôle."

The patient comes with the explanation that some time before, as

a rule several weeks, the eye had become smaller than the other, following a contusion in the region of the eye. Ordinarily a scar may be observed, usually upon the eyebrow, and it is sometimes painful to pressure. The upper lid droops and is not so convex. The retro-tarsal depression is deeper and the lid opening is not so large as on the other side. Upon examination the eyeball is usually found to be of normal size, the space between the orbit and the bulb is enlarged. The appearance of the patient is as if he were wearing an artificial eye. As a rule the globe has full movement and vision. Binocular vision as a rule remains, except in cases where there is paralysis or fracture of the skull. The movement of the eyeball, especially upwards and downwards, seems to be greater. Tension of the eye and the fundus is usually normal. The subjective symptoms in some cases are those of a foreign body in the eye, more often of anesthesia of the injured side of the nose, cheeks and lips, caused by rupture of the infra-orbital nerve and infraction of the floor of the orbit.

The *differential diagnosis* is to be made from neurotic atrophy of half of the face, which gives a picture similar to that of traumatic enophthalmus, phthisis bulbi or microphthalmus, for the eye is normal in size but has an abnormally deeper location.

The prognosis is that further sinking of the eyeball will occur, in many cases, with loss of sight. In others the visual acuity remains.

There is no treatment except that galvanism or high frequency currents may be employed to stimulate nutrition.—(H. V. W.)

Lukens (*Practical Medicine Series*, p. 169, 1907) reported a case of traumatic enophthalmos and has been able to find in the literature to date 78 examples. The writer's patient, aged 54, had been stabbed three times in the face with a knife, after which he had been thrown down stairs. On examination the same day both lids of the left eye were slightly swollen, but very prominent; the patient had no control over them. The orbital tissues were tense and there was marked exophthalmos. The upper lid presented on its external surface an incised wound of perhaps 1 cm. in length, which was agglutinated and nicely held by the sutures applied the night before. On its under surface on either side of the middle third were two transverse cuts extending up through the cul-de-sac. These latter wounds were gaping. On exposing the cornea, which was done with great difficulty, owing to enormous chemosis, it was found to be uninjured. The anterior chamber was normal or a trifle shallow, the pupil was central, round and about 2 mm. in diameter and the iris was bright. The vision was roughly taken and was greatly reduced, recognizing finger movements. There was no evidence of contusions or wounds about

the face other than the three stabs above noted. In addition to rupturing an artery, a fracture of the orbit, communicating with an accessory sinus, had been produced as evidenced by bleeding from the nose, which persisted for ten days. He was placed abed, iced cloths, boric



Lukens' Case of Traumatic Enophthalmos.

wash and atropin were used. The violent orbital disturbance was soon greatly relieved, and he left the hospital on his own responsibility at the end of two or three days.

Eventually he exhibited the following condition: The left upper eyelid drooped, nearly covering the eyeball, cicatrization had taken place at the site of the conjunctival wound, partially obliterating the

superior cul-de-sac, and the lid at the junction of its middle and outer thirds was slightly furrowed and drawn up and in, producing a tendency to entropion. The levator action of the lid was very feeble. The eyeball was dislocated 5 or 6 mm. back of its normal position and also 2 or 3 mm. below it, and the eye was rotated up about 30 degrees and out about 20 degrees. Upon palpation the eye was found to be firmly held in this position by a resistant mass extending from the eyeball to the floor of the orbit. No deep bands of cicatrization could be detected at the site of the injury in the roof of the orbit. The patient could rotate his eye about 10 degrees in the horizontal meridian and not over 5 degrees in the vertical. The pupil of the eye was about 2 mm. in diameter and responded feebly to light, and vision was 1/60 of normal. The vitreous was hazy and no fundus details were possible. The tension was normal. The vision of the uninjured eye was normal, and the pupil was the same size as that of the injured eye. He stated that the sunken condition of the eye was first noticed when the swelling subsided. A deep sulcus marked the upper tarsal margin, and the tip of the finger could be pressed between the eyeball and the orbital roof. The orbital fracture which was present in this case, if direct, was in the roof, although the fixing mass was in the floor, suggesting an indirect fracture in this location, which might also have resulted from his fall downstairs.

In Butler's (*Ophthalmoscope*, viii, p. 333, 1911) first case (congenital) the eye could be neither adducted nor abducted. The enophthalmos is explained by congenital absence of the rectus externus and internus which leaves too much room in the orbit and allows the eye to fall back. In the second case, also congenital, the eye could not be abducted beyond the middle line. The probable explanation of the enophthalmos was a rudimentary rectus externus with abnormally posterior attachment to the globe, also giving too much room and allowing the globe to fall back. In the third case, after an accident pieces of bone were removed, including part of the orbital process of the malar; the enophthalmos being due to the resulting increase in size of the orbit. Grönholm (*Zeitschr. f. Augenh.*, xxiv, p. 479, 1911) reports two cases, both caused by violent impact of the end of a ski against the orbital margins and the eye. There were various bony injuries, including in the first case displacements of the fragments from the floor of the orbit into the antrum of Highmore, and in the second a depression of the nasal wall (ethmoid). The ocular movements were markedly limited. In the first case the author explains the persistent enophthalmos as due to primary displacement of the orbital contents into the defect in the floor, and to secondary

adhesions and fixation from bleeding and traumatic reaction; in the second as mainly due to the depression in the bony wall, and in less degree to the other cause named.

In Sautter's (*Ann. of Ophth.* xix, p. 713, 1911) case the skiagraph showed fractures of the zygomatic process, the external and inferior orbital margins, and probably the floor of the orbit; as well as of the nasal orbital wall including the adjacent ethmoidal sinuses and possibly the frontal sinuses. The disturbed appearance of the nasal orbital wall suggested the possibility of depression, with hernia of the retrobulbar tissue in this region. In the absence, however, of positive signs of enlargement of the orbital cavity, or of signs pointing to a lesion of the sympathetic or of the fifth nerve, the enophthalmos may be attributed to a rupture of the check ligaments or of the supporting sheath of Tenon's capsule, or to a relaxation of these ligaments from fracture of their bony attachments, and secondarily to cicatricial tissue resulting from laceration of the soft structures within the orbit. Bourland (*Ann. d'Ocul.*, cxliii, p. 350, 1911) observed enophthalmos with mild optic neuritis seven months after a slight injury in the region of the superciliary arch. The reporter ascribes the phenomenon to inflammation and subsequent cicatricial sclerosis of the orbital tissues, slowly propagated to those parts and the optic nerve from the point of the original injury.

Hartung (*Zeitschr. f. Augenh.*, xxiii, p. 550, 1911) tabulates fourteen cases of traumatic enophthalmos among 50,000 patients in the ophthalmic clinic in Jena, while in the Leipzig clinic of 150,000 the condition was observed only four times. The predominance in the former is no doubt due to the circumstance that Jena draws its material largely from the country district, which is subject to severer injuries than that of the large cities. Of the fourteen cases six were due to kicks by a horse, and two to injuries by a cow's horn. In three the enophthalmos occurred within a week, and in the remaining eleven after months or even years.

In Chesneau's (*Ophth. Rev.*, xxix, p. 370, 1911) case marked binocular exophthalmos of ten years' duration gave place in two days to enophthalmos of one of the eyes with almost complete loss of the intra-ocular tension. The reporter believes that the sudden occurrence of the enophthalmos supports the opinion that the exophthalmos is due to a spasm of the smooth muscular elements so abundantly contained in the check ligaments of the orbital fascia: sudden relaxation of these muscular fibers from paralysis might give rise to the enophthalmos from the now unchecked contraction of the recti and other retrobulbar structures.

Lutz (*An. de Oft.*, v. 16, p. 49, 1913) reports a case of traumatic enophthalmos in a patient who a year previously had been thrown from a coach receiving injuries in the neighborhood of the left eye. At the time of the examination this eye was enophthalmic 14 mm. and was turned upward and outward. The eye could be moved only slightly upward and outward and not at all downward. Passive movements under cocain revealed marked resistance, especially to movement downward, and gave a sensation of loss of elasticity in the tissues of the globe. There were several cicatrices in the upper lid and the superior conjunctival fornix. Radiograms demonstrated a fracture of the frontal process of the superior maxilla, and a decalcification of the upper orbital rim. The orbital cavity was not increased. The ocular media and fundus were normal and vision of 4/9 was obtained by holding the upper lid out of the way and inclining the patient's head. Temporary division of all the recti muscles did not make possible free movement of the eye in any direction, from which the writer deduces that there must have been cicatricial contraction in the posterior part of the orbital cavity. Persistent use of fibrolysin produced no improvement. Rübel's (*Klin. M. f. Augenh.*, Feb., 1913, p. 227) patient, a man of 67, highly emaciated and with marked loss of orbital adipose tissue, had an enophthalmos of 3 to 4 mm. on retracting the eyelids.

Birch-Hirschfeld and Meltzer (*Arch. of Ophth.*, XL, p. 180, 1912) review the sixty-six cases of traumatic enophthalmos in the literature, and add four cases from the Leipzig clinic. All of the cases developed within varying lengths of time after trauma, but this cannot be accepted as the cause. No uniform pathogenesis could be found. The authors review all of the theories advanced to explain the cause of this disease, or rather anomaly, but reject all as not satisfying the questions presented. However, they do not offer any new theory. Gradle presented a case of enophthalmos in a 3 months old baby, which at the time of birth was supposed to have a discharge from the eyes. The possibility of the condition being the result of intra-uterine inflammation was discussed.

Finally, Eversbusch (*Klin. Monatsbl. f. Augenheilk.*, May-June, 1911) reports a case of enophthalmos, occurring in a twenty-eight-year-old man, due to the excessive exertion and strain incurred in trying to guide a heavily laden wheelbarrow on a wager over a circular course. The patient experienced intense pain immediately upon completing his task, having a sensation as though something had been torn in back of his eye. On the same day the patient noticed that the left eye was much deeper in the orbit than its fellow. The pain

recurred to a lesser degree off and on for a number of days. Somewhat later it was noticed that he had a compressible swelling of the lower lid after bending forward or upon compressing the jugular vein, disappearing in the normal position.

The author concludes that the enophthalmos is largely due to rupture of the fasciculi attaching the ocular muscles and perhaps the capsule of Tenon to the periosteum of the orbit. The varix he thinks is due to the lack of valves in the orbital veins, allowing them to overstretch when subjected to greatly obstructed blood circulation. See, also, **Injuries of the eye.**

Enoptomacy. In *optics,* examination by means of a mirror, as in observations made by the ophthalmoscope and skiascope.

Enorthotrope. THAUMATROPE. ZŒTROPE. ZŒPRAXISCOPE. PHENAKISTOSCOPE. An apparatus for the exhibition of figures apparently in motion, due to effects of visual persistence.

Enostosis. A variety of new osseous product consequent on periostitis.

Enroulé. (F.) Rolled up on itself; twisted.

Ensemble. (F.) The whole; the totality.

Ensor, Henry Collen. Born at Cardiff, Wales, the son of a solicitor. He received his medical education at Guy's Hospital, London. At the latter institution he was for some time ophthalmic clinical assistant. He became an M. R. C. S. and an L. S. A. in 1885. After a brief period spent as Resident Surgical Officer of the Birmingham and Midland Eye Hospital, he settled in his native town as ophthalmologist. He soon became ophthalmic surgeon to the Cardiff Infirmary, and, in 1887, was made a member of the Ophthalmological Society of the United Kingdom.

He died at Cardiff, Aug. 23, 1910, after undergoing a surgical operation for nasal obstruction.—(T. H. S.)

Enstalaxis. (L.) (Obs.) Instillation.

Entankyloblepharitis. (L.) Obs. Entankyloblepharon with blepharitis.

Entankyloblepharon. (L.) (Obs.) Adhesion of the eyelids to the surface of the eyeball.

Entblinden. (G.) To regain the power of sight.

Ente. (F.) A graft. Grafting.

Entère. (F.) Mucous membrane.

Enteroscope. A name given by Leiter to an instrument for illuminating the intestinal cavity by means of an electric light, for purposes of examination.

Entfärbt. (G.) Colorless.

Entfärbung. (G.) Discoloration.

Entfederung. (G.) Deplumation.

Entire collyria. Collyria which are used in the same form in which they were made, instead of being reduced to powder or diluted.

Entochoroidea. The inner lining of the choroid membrane of the eye, made up mainly of capillaries.

Entocornea. A synonym of Descemet's membrane.

Entoderm. One of the three primary germ-layers of the embryo. See **Development of the eye.**

Entomarginal. Internal and near the margin.

Entophthalmia. (Obs.) Inflammation of the internal parts of the eyeball.

Entoptic. Pertaining to the interior or internal parts of the eye.

Entoptic phenomena. ENTOPTIC APPEARANCES. Visual phenomena caused by peculiarities or imperfections of internal parts of the eye,

Entoptic Striæ Produced by Winking the Eyelids. (After George Bull.)

e. g., *muscæ volitantes,* as seen by the eye containing them. Tscherning (*Physiologic Optics,* p. 147) remarks that when "we approach a luminous point, the circle of diffusion to which it gives rise increases in size. At the moment when the luminous point is at the anterior focus of the eye, the rays are parallel after refraction, and the circle of diffusion is the size of the pupil; on approaching nearer to it, the circle still increases. In these circumstances we observe entoptic phenomena, that is to say, shadows which the corpuscles situated in the refracting media of the eye project on the retina. If, instead of a point, we use a larger luminous source, the cone of the shadow becomes too short to reach to the retina, except the object is very near the latter. Another way of observing entoptic phenomena consists in placing ourselves at a great distance and observing the luminous point through a strong convex lens. In this case the displacements of the shadows take place in the direction contrary to that which we are going to point out later. Among the entoptic observations I shall cite

the following: The luminous spot is limited by the shadow of the border of the iris; we can thus study, therefore, the irregularities of the latter. The pupillary contraction is very well observed on opening or covering the other eye.

We very frequently see small circles the centers of which are bright, and which have an apparent motion from above downwards, depending on the winking of the eyelids. They are produced by small specks on the anterior surface of the cornea, and which move in a contrary direction.

On winking the eyes we produce transverse striæ, due probably to the wrinkles of the epithelial layer. If we wink for some time, for example when keeping one eyelid closed while working with a microscope, or as artists frequently do in order to obtain a better idea of the



Incipient Cataract, Seen Entoptically. (After Darier.)

entire impression of a landscape, we can produce striæ which last for several hours and give rise to a very marked diplopia of the horizontal lines. George Bull especially has studied this question; according to him the phenomena are specially pronounced after reading for a long time in the horizontal position, and give rise to a peculiar annoyance which he has named tarsal asthenopia.

On winking the eyelids while looking at a distant luminous point, we observe long striæ which run upwards and downwards from the point. These striæ are due to the layer of tears which is in the conjunctival sac, and which, near the border of the eyelids, assumes the form of a prism with a concave surface. This prism deflects the rays which meet it, and, as its surface is concave, the parts placed near the border of the eyelid act as a stronger prism, which causes greater deflection of the rays: it is for this reason that we see a stria and not simply a second image of the luminous point. The upper eyelid deflects the rays upwards; it produces, therefore, the striæ which we see directed downwards. In fact, if we lower a screen placed near the

eye, it is the stria directed downwards which disappears first. This phenomenon is not, properly speaking, an entoptic phenomenon.

If we rub the eye, the luminous spot presents a speckled appearance, due to irregularities of the cornea; this appearance soon disappears.

We sometimes observe small round discs, sometimes bright and surrounded with a black border, sometimes dark with a bright border, proceeding from the crystalline lens. We frequently see also the star figure of the crystalline lens, sometimes bright, sometimes dark, with somewhat more luminous borders. The crystalline opacities are outlined in the spot with great distinctness. An intelligent patient can thus follow step by step the development of his cataract.

(After George Bull.)

After Helmholtz.

Speckled Appearance of the Entoptic Field Produced by Rubbing the Cornea.

Nearly every one sees objects situated in the vitreous body; they become partly visible without further aid by simply looking at the sky, that is when they are very near the retina. They are sometimes mobile, sometimes fixed, but presenting in the latter case an apparent motion. If, for example, the shadow is seen a little above the point of fixation, the patient looks a little higher in order to fix it; but as the shadow is always seen above the point of fixation, it continues to direct the visual line higher; and the shadow always flees before the look, for which reason the name *muscæ volitantes* has been given to this phenomenon. To make certain whether the motion is apparent or real, we can look at the sky through a window, on which we select a mark in order to assure fixation; after having made a rapid movement with the look, we fix this point. If the corpuscle is fixed, it should then remain motionless, but most frequently we see it descend slowly which indicates that the corpuscle really ascends."

J. Burdon-Cooper (*Ophthalmic Review*, Dec., 1908) finds that muscæ can be satisfactorily studied in the field obtained by using a low power

objective in the microscope and placing a high power objective upside down on top of the eye piece. With the ordinary condenser and diaphragm the illumination of this field can be adjusted to give the greatest distinctness of the shadows studied. A more simple but very serviceable device may be obtained by fusing the end of a capillary

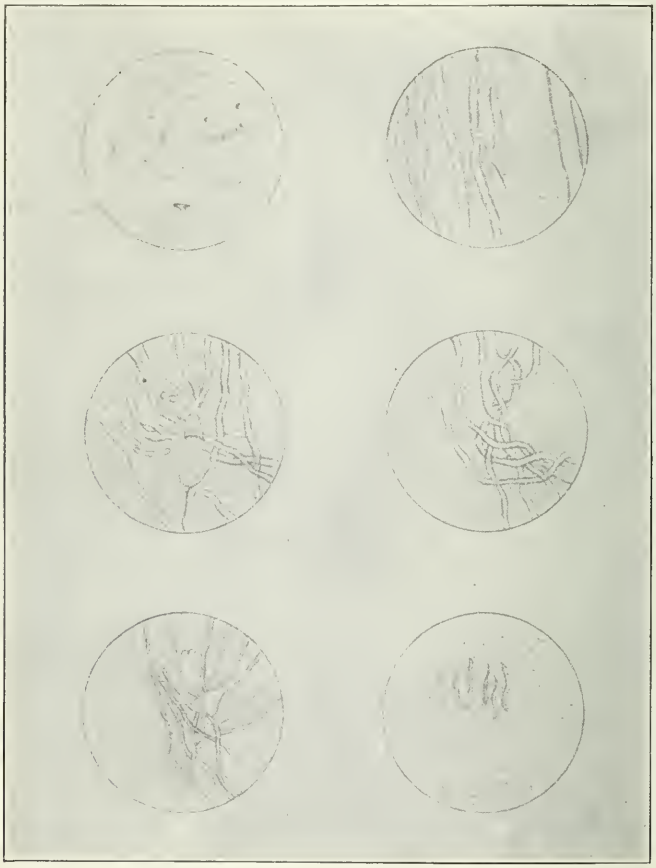

Entoptic Figures. (Burdon-Cooper.)

glass tube until it forms a small glass sphere. All but the sphere can be blackened with smoke to avoid annoying streaks of light. Studying the entoptic appearances by this means the strings of beads commonly regarded as fixed in the vitreous have a movement which Burdon-Cooper thinks argues for a lymph space existing between the retina and hyaloid membrane. Certain double contoured or "tubular" shadows are suggested to be due to folds in that membrane. Some of

these folds appear to be immediately behind the crystalline lens. A number of these folds apparently terminating around an opening are supposed to indicate the anterior end of the hyaloid canal. By lying supine, with the light directly above, he has been able to see the whole circumference of this opening. He also thinks he has detected the posterior end of the canal, considerably larger than the anterior.

Ohlemann (*Ann. of Ophth.*, p. 131, January, 1909) reports a case of exophthalmic goitre in which the patient perceived a circular phosphene, like a radiating corona, which was ascribed to mechanical irritation of the retina. It was seen at night, at the height of disease, when the tension on the eyeball was greatest.

Entoptics. Entoptoscopy. The science of phenomena interior to the eye.

Entoptische Erscheinungen. (G.) Entoptic phenomena.

Entoptoscope. This little optical instrument was invented by Barrett who applied to it the principle of the pin-hole device of Listing. The



Entoptoscope. (Tscherning.) *a*, planchette of wood; *b*, rod; *c*, copper plate, perforated; *d*, thread.

patient looks at the sky through a minute opening in the appliance and is able, at his leisure, to study the form and watch the variations

of opacities seen in his own lens and vitreous. Tscherning (*Physiologic Optics*, p. 150) has constructed a small entoptoscope (see the figure) which consists of a small plate of wood which the observer takes between his teeth. On the plate is fixed a rod which carries a plate of copper having the form of the segment of a sphere. In the middle is pierced a very fine opening, (1/10 mm.), which is on a level with the eye. In the concavity of the cap are stretched two threads, one horizontal and one vertical, placed in the form of a cross and forming cords with the cap. When one takes the instrument between the teeth and looks towards the sky one sees the entoptic field occupied by the cross, which is greatly enlarged. We select a point in the cross as a fixation point. The position of the cross is thus invariably dependent on that of the head; if therefore, in given circumstances, we observe a displacement of the cross in the entoptic field, it is because it is the latter, that is to say the eye, which suffers the displacement. We can thus prove that the eye is slightly displaced, a little upwards when we wink the eyelids, a little downwards when we open the eye very widely. When we lean the head to one side the eye undergoes a slight displacement in the direction of the weight, etc. The phenomena are especially striking when we instil eserine, because the field is then very small. The displacement of the cross may then reach a fourth or a third of the entire extent of the field.

Entoptoscopy. The subjective observation of intraocular shadows and objects. The perception of circumscribed shadows of opaque particles in the dioptric media of one's own eye or of the blood-vessels of one's own retina.

Entorbital. Situated on the inner portion of the orbit or of orbital lobe of the brain or internally to its orbital fissure.

Entoretina. The innermost layer of the retina.

Entorse. (F.) Strain; twist.

Entoscope. See **Endoscope.**

Entozoa of the human eye. See **Parasites, Ocular.**

Entrance, Optic. A name for the optic papilla or disc.

Entrance-port. In *optics*, the image of the annular diaphragm that is formed by that part of the optical system which lies in front of the diaphragm or aperture-stop (q. v.).

Entrance-pupil. In *optics*, an aperture-stop (q. v.) that is effective in the object-space and conjugate to the exit-pupil in the image-space of an optical system. Together they are images of each other and constitute a pair of *virtual stops* (as distinguished from actual or material stops) that limit and are the measures of the apertures of the ray-bundles in the object-space and the image-space. A material

stop of the same size and in the same position as the stop image at the entrance-pupil will limit the aperture of the ray-bundles to the same extent as a material stop whose size and position are equal to the stop-image at the exit-pupil; and either of them or both together, so far as this effect is concerned, would be precisely equivalent to an actual stop placed between the front and rear components of the optical system. The latter Abbe termed the iris of the optical system, and in connection with it developed the theory respecting the aforesaid pupils.

The pupil of the eye is the contractile aperture of the iris whose image produced by the cornea and the aqueous humor lies in front of the eye (as can be seen by looking directly into it), so that only rays that are directed towards this image can enter the eye through the iris opening.—(C. F. P.)

Entre-croisement. (F.) The reciprocal passage of fibres in general, and more especially of the nerve tubes from one side of the median line to the other; as in the decussation of optic nerve fibres.

Entrefer. (F.) Airspace.

Entrichiasis. (L.) A synonym of trichiasis.

Entrichoma. (L.) An old name for the tarsus and the ciliary edge of the eyelid with the cilia.

Entropia. A turning inward.

Entropion (trichiasis). Entropium. Incurved or inverted lids. As it is clinically impossible to separate trichiasis from entropion these two subjects are here treated in one section. See, also, the major heading, **Cilia, Misplaced**; as well as **Trachoma** and **Trichiasis**; and **Distichiasis.**

Entropion is an exaggerated degree of trichiasis with this difference, that whereas in trichiasis the free border of the lid remains in its normal position, in entropion the free border is turned inward toward the eyeball. There are two varieties, *entropion spasticum* and *entropion cicatriciale.*

Normally the plane of the free border of the upper lid faces downward, that of the lower lid upward. The posterior margin is sharp, almost a right angle. Any cause that operates to change the curvature of the lid plates, so as to force the free border inward, will bring about entropion. One such cause is spasm of the orbicularis, particularly of those muscle bundles that lie near the palpebral fissure. This gives rise to the form known as spastic entropion.

The bundle of orbicularis fibers surrounding the palpebral fissure presents a curve whose concavity is directed toward this fissure. Furthermore, by reason of its position over the surface of the eyeball,

this bundle has a curvature whose concavity is backward. In forcible contraction of this bundle, as in spasm, it is plain that the edge of the lid, to which the muscle is so firmly attached, tends to assume the position of the chord of the arc of these curvatures, and as a result is turned inward. This occurs more readily if the edge of the lid has lost the support of the eyeball: hence spastic entropion is frequently seen after enucleation, if the patient does not wear an artificial eye.

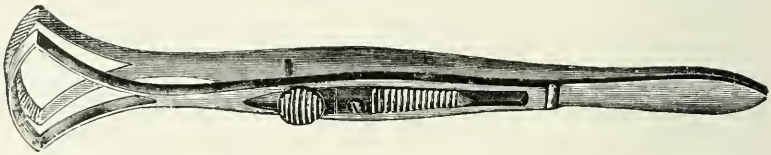

Desmarres' Lid Forceps for Entropium.

Again, if the tissues of the lids are much relaxed, the skin very distensible and the contents of the orbit shrunken, the conditions are favorable for spastic entropion. Hence, we see it more frequently in old people and particularly in the lower lid, the tarsal plate of which gives it less firmness than that of the upper lid. Because of the firmness of the tarsal plate in that organ spastic entropion rarely affects the upper lid.

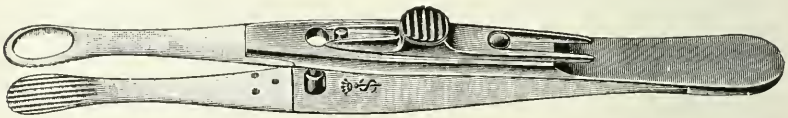

Falta's Lid Forceps for Entropium.

The disease is observed in the blepharospasm of children, in blepharophimosis, and is frequently caused by long-continued, firm bandaging of the eyes of elderly persons whose skin is flabby, as after cataract operations.

The *cicatricial form of entropion* is the result of distortion of the tarsal plate by the contraction of cicatricial tissue that has formed in it and in the conjunctiva covering it. Such cicatrization is usually the result of long-continued trachoma; or it may follow burns, pemphigus or diphtheria of the eyelids or conjunctiva.

The contraction of the scar tissue "buckles" the tarsus so that its under surface is much more concave than normal, and in chronic cases of trachoma presents a distinct furrow parallel to the free border. Corresponding to this furrow there may be on the anterior surface of

the tarsus a distinct ridge. Because of the bowing inwards of the tarsus the posterior margin of the free border is pressed against the cornea and by constant attrition is rounded or beveled. As a result of the continued irritation of the cornea by the border of the lids, and it may be by the cilia, a certain degree of blepharospasm is excited which aggravates the trouble by adding the spastic to the cicatricial form. In the severest forms the lid may be so incurved that the lashes rest on the eyeball, as they do in typical cases of trichiasis or spastic entropion.

It will be seen that in trichiasis there is no distortion of the lid plate, except possibly around the hair follicles on the free border and, therefore, no real entropion, while in cicatricial entropion there may be trichiasis in addition to the deformity of the tarsus. In deciding

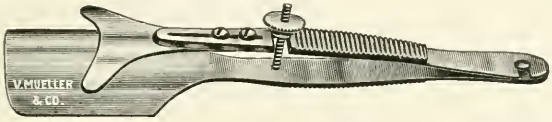

Black's Entropium Forceps.

upon the operative treatment of trichiasis and entropion, these various features should be borne in mind, and the operation must be varied to suit the individual case. If the spastic feature predominates, this must receive especial attention, while if trichiasis is the marked feature, without the more severe cicatricial entropion, certain other operations will be applicable.

Inasmuch, therefore, as trichiasis and entropion so frequently coexist, and as the latter is to be regarded as a variety of the former, it is expedient to consider their *treatment*, and especially their operative treatment, together.

OPERATIVE TREATMENT OF ENTROPION AND TRICHIASIS.

As has been said, spastic entropion usually affects the lower lid and occurs in elderly people with relaxed, flabby skin, and in those in whom the support of the lower lid is partly lost, as from shrunken orbital tissue. It frequently occurs in such persons as a result of continuous bandaging of the eyes, and in these cases is usually relieved by discontinuing the bandage. If for any reason this cannot be done, it may be necessary to use mechanical or even operative measures to correct the difficulty.

Temporary relief may in some cases be obtained by the use of adhesive plaster. The end of a strip of adhesive plaster, half an inch or

more in width, may be applied to the lid just below the cilia, then enough traction is made to slightly evert the lid and about two or three inches of the strip is made to adhere to the cheek. The moisture of the tears will usually make this a temporary expedient, and the strip may have to be reapplied with each dressing.

One may employ strips of gauze stuck to the skin with flexible collodion, which makes a more efficient dressing than the adhesive plaster. One end of a strip of gauze is applied to the lid as was the adhesive, and made to adhere by painting it with collodion. After this has dried, the necessary amount of traction can be made to evert the lid and then the whole strip, two or three inches long, can be made to adhere to the cheek. That the eye should be carefully protected from the ether in the collodion scarcely needs mention.

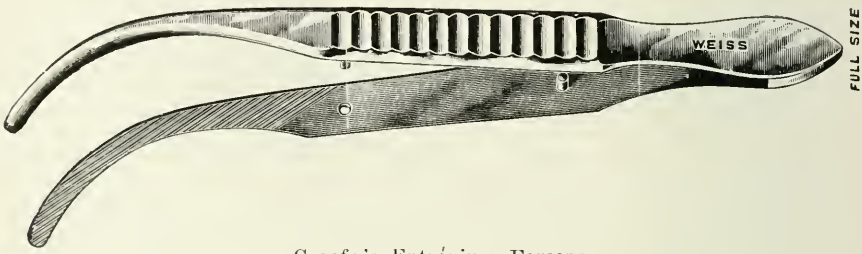

Graefe's Entrópium Forceps.

If these measures are not sufficient to keep the lid from turning inward, recourse must be had to sutures placed in the lid, and allowed to remain until the necessity of keeping a bandage on the eye has passed.

Gaillard-Arlt suture. According to Arlt *(Handbuch der gesam. Augenheilk.*, Graefe-Saemisch, Vol. III, p. 457, 1874), the method of shortening and everting the lid by means of a suture was first suggested by Wardrop.

Gaillard (*Bulletins de la soc. méd. de Poictiers*, 1844) carried out the idea by introducing the sutures into the lid in the following manner. The needle entered the skin of the lid not far from the inner angle of the eye and slightly beneath the lashes. It passed downward beneath the fibres of the orbicularis and emerged about 2 cm. lower down. A similar suture was placed near the outer angle of the lid. The sutures were firmly tied and allowed to cut themselves out. The resulting linear scars were expected to produce a more or less lasting result.

Arlt modified this procedure and the Gaillard-Arlt suture is applied in the following way. (See the illustration). Two sutures, each

armed with two needles, are used. Holding a fold of skin of the lower lid between the finger and thumb, one of the needles is passed into the skin about 3 or 4 mm. from the lid border, at the junction of the inner and middle thirds of the lid, and made to emerge at the outer side of the fold. The other needle on the same suture is then passed in a similar direction, entering the skin about 3 mm. from the point of entrance of the first and emerging the same distance from the point of exit of the first. The points of exit should be not less than 15 mm. below the points of entrance of the sutures. The other

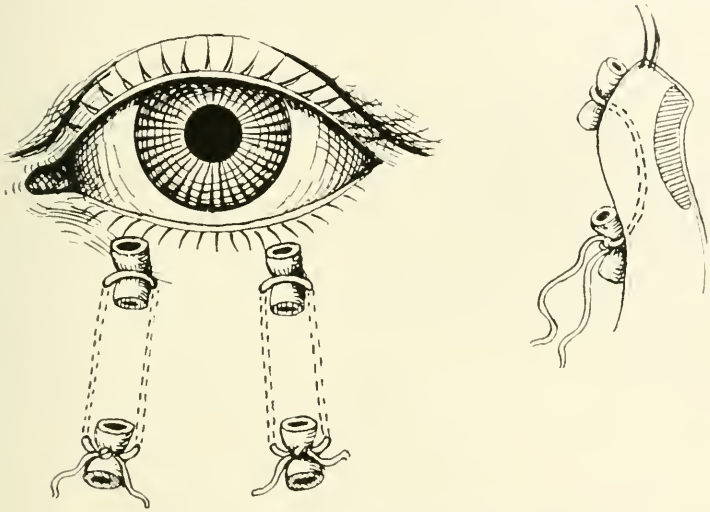

Gaillard-Arlt Suture for Spastic Entropion.

surture is passed in a similar manner, at the junction of the middle and outer thirds of the lid. There are thus formed two loops on the skin, a few millimeters from the lid border, the threads passing below the fibers of the orbicularis. The sutures are tied over small rolls of gauze or pieces of tubing, and a small roll of the same is also inserted beneath each loop, to prevent it cutting into the skin. When tightening and tying the sutures, slight pressure is made against the tarsus with a probe, to facilitate the eversion of the lid. The sutures are usually removed after two or three days. The result is a temporary one, but it may be sufficient to relieve the condition until the dressings that were the cause of the trouble can be removed. If suppuration should occur along the track of the sutures, the resulting strands of scar tissue might produce a more or less permanent effect. This effect was formerly sought, but other operations may be done that are more efficient when a permanent effect is desired.

Snellen's suture for entropion. The eyelid may be held with the fingers or seized at the free border with a pair of forceps. A pair of T-forceps is also suitable for this purpose. One needle of a double-armed suture is then passed from the fornix of the conjunctiva directly through the lid and at right angles to it. It is then made to re-enter the skin at the point of exit and is passed upwards beneath the skin to within a few millimeters of the eyelash border. The second needle on the suture enters the fornix about 4 mm. from the entrance of the first, passes through the lid, enters beneath the skin and emerges at the free border about 4 mm. from the point of exit

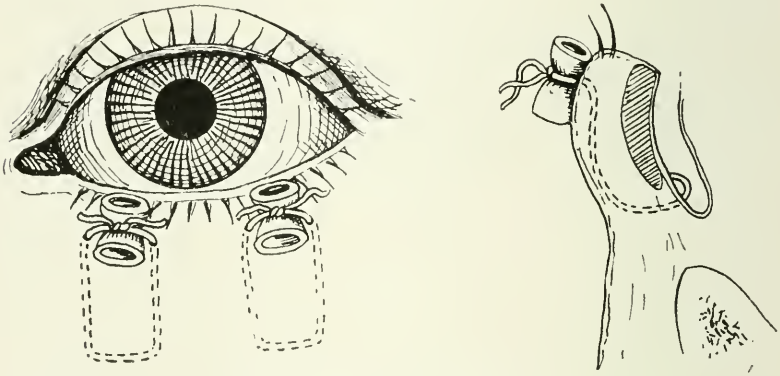

Snellen's Suture for Entropion.

of the first. The ends of the thread are then tied over a small roll of gauze or piece of small tubing. Two or three looped sutures may be applied at equal intervals, and the effect, when they are tied, is to turn out the lid border; for the point of fixed support is the tarso-orbital fascia near the orbital margin, and tightening the suture tends to straighten the arc formed by the line of the suture. A bandage may be applied and the sutures removed at the end of three or four days.

Gillet de Grandmont (*Bull. de la Soc. d'Ophtal. de Paris,* I, 1889), modifies the suture of Snellen by passing it directly from the inferior conjunctival cul-de-sac to the lid border without having it emerge through the skin. A double-armed suture similar to the Snellen is used, and the points of entrance in the cul-de-sac are about 4mm. apart. The sutures are tied over a roll as in the case of the Snellen suture.

Boeckmann (*Norsk Magazin f. Laegevidensk,* 1880, Vol. XI) uses loop sutures in spastic entropion in the following manner: The

needles of a double-armed suture of silk or catgut are passed entirely through the lid from the conjunctival side, the point of entrance is just below the tarsus for the lower lid and slightly above the tarsus for the upper lid. The points of emergence of the suture in the skin are nearer the edge of the lid than the points of entrance. He uses one suture for spastic entropion of the lower lid; three for the upper. The sutures are tied tightly without any roll and are removed after four or five days.

Allport (*Amer. Journ. of Ophth.*, March, 1888, p. 78), practises about the same procedure as described by Boeckmann for spastic entropion, passing three loop sutures through the lid at the level of the convex border of the tarsus and tying them tightly, thus fixing the fibers of the orbicularis to the tarsus at these points.

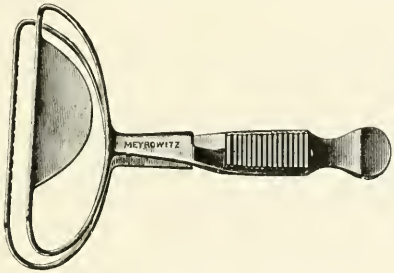

Post's Entropion Forceps.

Dransart (*Journal d'Oculistique du nord de la France*, Feb., 1890, p. 69), has used the suture of Gillet de Grandmont successfully in entropion of the upper lid and has found it effectual in cicatricial entropion of the lower lid.

It will be seen that all of these suture operations act by exerting tension upon the skin from a fixed point of support which is in the tarso-orbital fascia, and that the nearer the suture emerges to the free border, the greater will be its power to effect eversion of the lid. Furthermore, the effect of the operation will be temporary unless the suture remains long enough to allow cicatricial bands to form along its track.

Montgomery (*Chicago Med. Journ. and Examiner*, 1886) passed a single suture the length of the tarsus of the lower lid, parallel to the lid border and about 4 or 5 mm. from the line of cilia. The needle entered at a point near the external commissure, passed beneath the muscle and along the tarsus, to emerge at a point 4 or 5 mm. below the punctum lachrymale. The suture was tied directly over the skin, and, if a temporary result was desired, was removed at the end of 4

or 5 days, or, if a more permanent result was to be obtained, it was allowed to cut its way out, thus producing a linear scar giving a similar result to that obtained by cauterization.

Cauterization, in one form or another, has been used for the correction of entropion since the time of the ancient Egyptians who are said to have burned the lids with red-hot, gold plates, to destroy the cilia and produce cicatrices. The Arabian physicians of the XIth and XIIth centuries used the red-hot iron for the same purpose.

More recent operators (Galezowski, Trousseau, Terrien) have substituted the thermo-cautery or galvano-cautery and have practised much the same procedure as their predecessors. Either with the fingers or with a lid clamp (one blade of which is inserted in the conjunctival sac) a fold of the palpebral skin is raised, and with a small

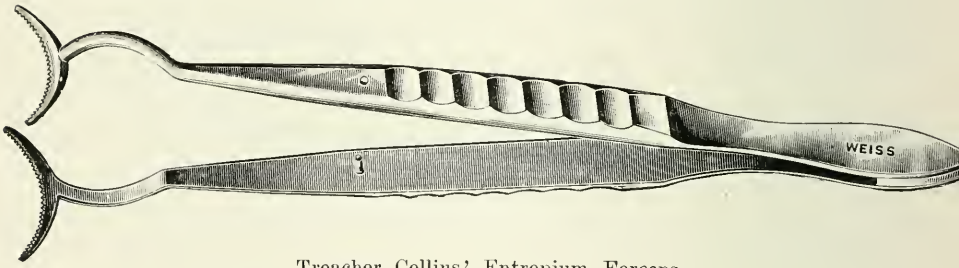

Treacher Collins' Entropium Forceps.

blade of the cautery a line is traced, 3 or 4 mm. from the eyelash border, along the whole length of the lid. The tissues along this line are burned through to the tarsus. General anesthesia may be required.

Ziegler (*Journ. Amer. Med. Assoc.*, 1909, Vol. LIII, p. 183), obtains good results in entropion of a spastic form by a somewhat similar procedure. The lid is held in the author's special lid clamp, the distal edge of which is straight. At a distance of 4mm. from the free border, the short point of a galvano-cautery is passed through the skin and into the tarsus. Several such cauterized punctures are made 4 mm. from each other along the same line. Infiltration anesthesia, or slightly freezing the skin with a spray of ethyl chlorid may be sufficient, but in many cases ether or chloroform narcosis is necessary. The author also employs the same method in ectropion, the line of punctures then being made on the conjunctival surface.

Chemical caustics have also been used for producing cicatricial contraction of the skin in these cases. Quadri and Helling employed sulphuric acid; Vienna paste has been recommended, and Theobald (*Amer. Journ. of Ophthal.*, Oct., 1898, p. 295) advocates, for senile

entropion of the lower lid with relaxed tissues, the use of caustic potash. With a finely-pointed crayon of potassium hydrate he makes an eschar 3 or 4 mm. wide, parallel with the lid margin and extending the length of the tarsus. The crayon is drawn back and forth several times over this area, care being taken not to get nearer than 3 mm. to the lid border. When the skin has been destroyed and the deeper tissues assume a brownish color, the action of the caustic should be stopped by applying acetic acid diluted one-half. A simple dressing is all that is required. If the first application proves insufficient it may be repeated.

Correction of entropion by excision of skin near the border of the lid. Operations of this class have been practised since the earliest

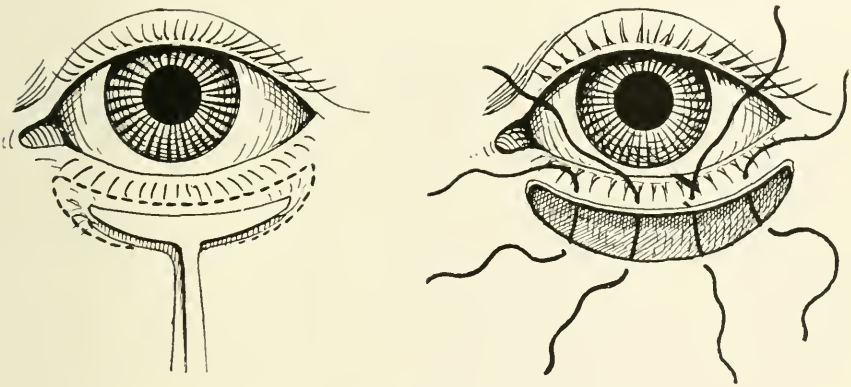

Operation for Spastic Senile Entropion.

times. Celsus advised this method, and Paulus Ægineta is said to have devised a special lid forceps, possibly somewhat like the modern T-forceps, with which to seize the piece of skin before excising it.

In many of these operations the fibers of the orbicularis are included in the piece excised, and without doubt a part of the good effect is due to this, the sphincter action of the orbicularis being in this way temporarily checked. Some of them are combined with canthotomy or canthoplasty, whereby their effect is increased. A simple, but very effective operation of this class, the origin of which probably dates back to antiquity, is excision of a horizontal fold of skin, with, possibly, some fibers of the orbicularis, parallel to the lid border.

With a T-forceps a horizontal fold of skin of the lower lid is seized, the amount included in the grasp of the forceps being just enough to produce the desired amount of eversion of the lid, the forceps being so placed that the upper incision will fall about 3mm. beneath the

line of the cilia. The incision is made with an ordinary scalpel, or the skin may be transfixed by a Beer's knife along the line to be cut, the back resting on the lid. This incision, extending nearly the length of the lid, is joined at either end by a slightly curved one below this. The skin and muscle fibers are removed and the lips of the wound brought together with three or four sutures. (See accompanying

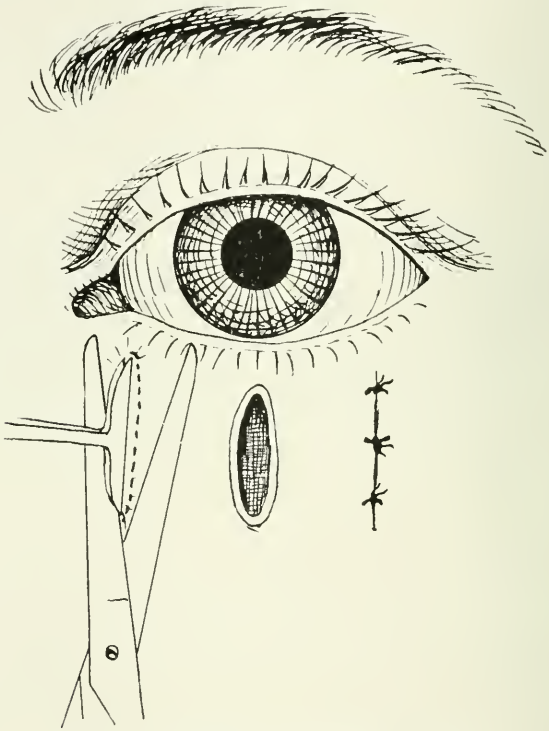

Janson's Operation for Spastic Entropion.

figure). Care must be taken that too much tissue is not removed, lest an ectropion follow. The amount to be taken must be measured by pinching up a fold either with the T-forceps or with small toothed forceps. The resulting scar is slight and not very noticeable. This operation is applicable in senile entropion associated with considerable redundancy of skin.

The operation of Janson (Desmarres' *Traité des Maladies des Yeux*, 1847, Vol. I, p. 497) (see the figure) is a revival of an ancient operation and consists in cutting out of the lower lid one or more oval pieces of skin. A fold of integument at right angles to the free border

of the lid is seized with a pair of T-forceps and excised with scissors. The lips of the wound are then approximated with sutures. Two or three such cuts are made according to the degree of the entropion. The chief disadvantage of this method is that the degree of eversion cannot be accurately determined. Moreover, vertical scars are unsightly and may cause a subsequent ectropion by their contraction.

Busch (*Archiv. f. Ophth.*, Vol. I, Pt. 2, p. 107), in 1858, proposed an operation of merit, not only for spastic entropion but for certain cases of mild cicatricial entropion of the lower lids. A canthotomy of about 1 cm. in length is first done. From the ends of this incision two incisions downward are made to include a triangular piece of skin, which is then excised. The closure of the triangular gap in the skin with sutures, horizontally placed, everts the lid.

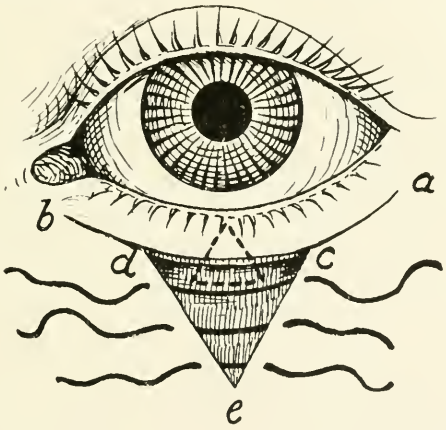

Graefe's Operation for Entropion.

Incision from a to b. Converging incision from c to e and d to e. Triangular piece of skin removed. The dotted triangle indicates where the piece of tarsus is excised. Sutures as indicated.

Goldzieher (*Klin. Monatsbl. f. Augenh.*, 1908, Vol. XLVI, p. 426) has adapted this operation for cases of purely spastic senile entropion by omitting the canthotomy (which it must be conceded is a useful feature) and removing a triangle of skin about 5 mm. from the outer angle of the lids. The base of the triangle is about 2 cm. in length with its apex pointing downward and inward toward the cheek. The skin is excised and the sutures are placed so as to exert traction downward and outward.

Graefe's operation for entropion spasticum. This operation (*Archiv. f. Ophth.*, 1864, Vol. X, Pt. 2, p. 221) consists in a removal of a triangular piece of skin from the lower lid in the following manner.

An incision is made about 3 mm. from the lid border extending nearly the entire length of the lid. At the junction of the middle and outer thirds of this incision two others are made converging downwards, of such length as to mark out an equilateral triangle (see the diagram). The skin composing this triangle is then dissected off, and the skin at b and c is undermined. The lateral borders of the gap are then approximated with sutures. A couple of fine stitches may be used to close the horizontal cut. If the first incision has been properly made, 3 mm. from the lid border, the upper suture will pass over the inferior border of the tarsus and by shortening the tissues of the lid at this point, press the inferior border of the tarsus backward and thus turn the superior border forward. This action may be aided by placing a small roll of gauze on this point, to be held in place by the dressing. The sutures may be removed in three or four days. Before applying the sutures, the upper skin flap may, if desired, be slightly dissected back with scissors and the attached fibers of the orbicularis removed. In cases of cicatricial entropion Graefe advocated the same procedure with the additional removal of a triangular piece of the tarsus as indicated by the dotted lines in the figure. The objection to the method is the vertical scar that is left, but aside from this it remains one of the valuable methods for the correction of the trouble.

Entropion operation of Panas. Panas (*Maladies des Yeux,* Vol. II, p. 155) proposed the following modification of excision of the skin, which may also include excision of some of the fibers of the orbicularis, for the relief of entropion of the lower lid (see figure). At each extremity of the lid, beginning 3 mm. below the free border, a vertical incision is made through the skin 1 cm. in length. The lower extremities are joined by an incision through the skin. The flap thus marked out is dissected away from the underlying tissue up to the free border of the lid. By making traction downward on this flap, one can now determine how much tissue along its lower border it is necessary to remove in order to produce the required eversion of the lashes. One may also excise some of the fibers of the orbicularis lying just beneath the free border of the lid. Sutures are placed, as indicated in the cut, to close the wound. The resulting scar is not considerable, and is largely concealed by the natural folds of the skin.

Correction of entropion by excision of a bundle of muscle fibers near the lid border. It will be seen that many operations designed to correct entropion by the removal of a strip of skin, combine with this the *removal of some fibers of the orbicularis,* to check the spastic action of this muscle. Indeed, it seems probable that a certain amount of the good effect produced is the result of such muscular excision, and the

same might be said of the operation by cauterization, which also destroys some of the muscle bundles and thus limits, for a time at least, the sphincter action of the orbicularis. This is an important feature of some of the best operations for entropion, whether of the spastic or cicatricial variety, for even in the latter variety, owing to the constant irritation of the eye, there is usually more or less spasm of the muscle, and the removal of a portion of it tends to check the spasm. This principle will be referred to in operations to be later described.

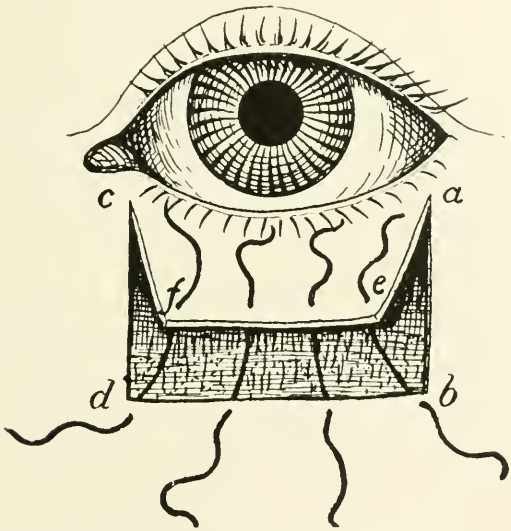

Panas' Operation for Senile Spastic Entropion.

Vertical incisions are made from a to b and c to d, and a connecting horizontal incision from b to d. The flap a, e, f, c, is dissected up to the free border, and then sufficiently shortened to produce the desired result. Sutures are then placed at the points indicated.

Correction of entropion by section of the fibers of the orbicularis at the lateral raphe. What was said above applies equally well here. The division of the outer canthus as in canthotomy and canthoplasty involves cutting the fibers of the orbicularis that attach them to the lateral raphe. When *canthoplasty is used as an aid to operations for entropion* one should snip, with pointed scissors introduced into the wound, the fibers of the ligament above and below.

CORRECTION OF FAULTY POSITIONS OF THE CILIA.

Removal of the cilia in trichiasis. When trichiasis is limited to a small part of the lid, or when a few of the cilia are misplaced and,

turning inward, irritate the eyeball, they should be removed either by epilation or, better, by electrolysis. The misplaced hairs are sometimes so fine and so light colored that a careful search with good illumination and the aid of a lens is necessary to discover them. If epilation is practised the hair is seized near its base with cilia forceps and gently drawn (not jerked) in the direction of the shaft. Cilia forceps as manufactured by most instrument makers are ordinarily very imperfect, and many of them are quite useless for the purpose for which they are intended. The opposing surfaces at the ends of the blades should come into perfect apposition, otherwise fine hairs will not be caught. In selecting such an instrument one should subject it to the test of holding it up to a light with the blades closed, and noting whether any light can be seen between the apposed surfaces at the ends of the blades. Too frequently it will be found that the surfaces come into actual contact at one small point only.

Even after proper epilation, however, it is only a matter of time until the hairs grow again, so that it is much better to destroy the hair follicles by means of electrolysis.

Electrolytic epilation. It is best to place the patient in a recumbent posture and in a good light; oblique illumination should be used if the light is artificial. The operation is rather painful, so that if a number of hairs are to be removed at one treatment it is best to inject into the edge of the lid a drop or two of a 1 per cent. cocaine solution, in addition to cocainizing the conjunctiva. This will make less painful the application of some kind of lid clamp, or the lid spatula of Jaeger, which will be useful to give good support to the lid.

A very fine needle, or a fine drill such as is used by jewelers, is mounted in a suitable handle that can be connected with the negative pole of a galvanic battery, which should be provided with a rheostat and a galvanometer. A wet sponge electrode connected with the positive pole is applied to the neck or cheek of the patient.

If the operator is in doubt as to the polarity of the current he can easily determine it by immersing two metallic electrodes in a glass of water, and noting that when the current is turned on, a greater number of bubbles of gas (hydrogen) accumulate around the negative pole, than around the positive (oxygen).

The operator should use a binocular loupe (such as Jackson's or Berger's) in order to pass the needle accurately along the shaft of the hair into its follicle. When the needle has been thus passed into the follicle to a depth of 2 mm. to 3 mm. and the sponge electrode has been applied to the cheek, the current is turned on and controlled by the rheostat until the galvanometer shows a current of 0.5 to 1 milliam-

pere. Electrolytic action is shown by the bubbles of gas that accumulate around the needle and hair shaft. When this has been continued for nearly half a minute, the current is gently turned off and the needle withdrawn. The dead hair can then be easily extracted with the cilia forceps. If any resistance is encountered in extracting it, it is evidence that the electrolysis around the hair root is not complete, either because the current was not applied long enough or, more probably, because the needle was not accurately placed in the follicle. Considerable care is necessary in thus epilating the very fine hairs that are so frequently the cause of great annoyance, but the result amply repays the effort.

Complete removal of the cilia border in trichiasis. The operation of "scalping the lids" is one that is now rarely performed, although in extremely obstinate cases it may be practised. Naturally, it is more to be avoided on the upper than the lower lid, for the lashes of the upper lid are more essential to protection of the eye than those of the lower. It was probably suggested by the practice of the ancients of completely destroying the hair follicles by a hot iron. The method that is usually followed is that suggested by Flarer.

Flarer's operation. Either a horn plate, such as Jaeger's lid spatula, or a broad lid-clamp is placed beneath the lid, to hold it firmly and give support. With either a keratome or a narrow scalpel, such as a Graefe cataract knife, an incision is made along the whole length of the free border of the lid, splitting it into two layers. In making this incision the gray line is followed that lies between the openings of the Meibomian glands and the row of cilia. In cases where the posterior margin is rounded off, and the row of cilia is more or less distorted, this gray line is not well defined, and then the operator in making this intermarginal incision must take care that all the cilia lie in front of it. The incision thus passes into the loose connective tissue that separates the orbicularis from the tarsus, and should extend in depth about 3mm., or beyond the depth of the hair follicles.

An incision is then made in the skin, parallel to and about 3 mm. from the free border, and at each extremity of this another curved cut is made meeting the ends of the intermarginal incision. This strip, containing the cilia, is easily dissected off. Care should be taken that all the roots of the hairs are removed. Any black points that remain should be dissected out with scissors. The raw surface, which heals by granulation in a few days, may be covered with a moist boric acid dressing.

The disadvantages of this method are obvious. It causes an unsightly appearance, removes structures important for the protection

of the eyeball and in cases where entropion is a marked feature leaves a harsh scar at the lid border that often irritates the eyeball as much as did the hairs. It has received an important modification by Stellwag, which is applicable to cases in which trichiasis, rather than entropion, is the dominant feature of the case.

Flarer-Stellwag operation for trichiasis. The operation (*Allegemeine Wiener med. Zeitg.*, 1883, Nr. 49) (see the figure) is performed in every respect like the one just described, with this addition. After



Flarer-Stellwag Operation for Entropion.

The cilia border is removed by splitting the lid margin along the gray line, and then making an incision 3 mm. from the free border. The flap thus excised is then reversed.

the strip of tissue bearing the cilia has been removed, it is placed in warm normal-salt solution (0.5 per cent.) until the bleeding of the raw surface at the edge of the lid is checked. The narrow flap is then placed in a reversed position on the raw surface (i. e., what was the temporal end of the strip is placed at the nasal end of the denuded area), and is gently fitted into position. A very fine stitch at either end may or may not be necessary. The little flap is sprinkled thickly with iodoform powder, and the wound is then covered with rubber tissue, or silk protective, that has been smeared over with vaseline. Over this the dressing is placed. Both eyes should be bandaged for two days to prevent, as far as possible, movement of the lids. The

dressings may be changed every day after this. The lashes in the strip usually fall out, but if the flap is retained as it usually is, the lid border although bald, does not present the disfiguring and irritating scar surface that it would, after the scalping process.

Naturally, this method is more applicable to cases in which the whole row of eyelashes is symmetrically turned inward than in those where the hairs are straggling, some of them pointing inwards and many of them outwards.

Correction of faulty positions of the cilia by displacement of the cilia border. Operations of this group attempt to displace or transplant the cilia border in such a way that the lashes will not come in contact with the eyeball.

Attempts to correct trichiasis in this manner were probably made by the older physicians, and, it is said that the operation, presently to be described as that of Jaesche-Arlt, is identical with the one described by Paulus Ægineta in the seventh century.

In most of the operations of this class, in addition to transplanting the cilia-bearing zone away from the free border of the lid, there is introduced the plastic feature of covering the denuded area with skin or mucous membrane, in the attempt to prevent as far as possible the formation of scar tissue on the free border.

Operation of Jaesche-Arlt. An intermarginal incision, similar to that described in the Flarer method is made along the whole length of the lid, following the gray line on the free border. (Graefe-Saemisch, *Handbuch der ges. Augenh.*, 1st Ed., Vol. III, p. 447.) This incision should be 3 or 4 mm. in depth, and should be so placed that all the lashes will be in the anterior layer which is separated from the tarsus. A fold of skin is next removed from the anterior surface of the lid in the following manner. An incision is made in the skin parallel to the free border and about 4 mm. from it; above this and joining it at each end, there is made a curved incision through the skin, which marks out a crescentic area of skin that at its widest part at the middle of the lid is about 8 mm. This crescentic piece of skin is then dissected off with blunt-pointed scissors or scalpel, care being taken not to buttonhole it, and not to remove the subjacent fibers. The gap produced by the excision of this piece of skin is then closed by five or six sutures. Arlt recommends that, in placing them, the needle first pass through the skin of the upper edge of the cilia flap, then include some of the orbicularis fibers over the tarsus and, finally, the skin of the upper lip of the wound. The sutures are not cut off, but are drawn upwards to cause the cilia border to take its new position higher up on the tarsus, and are

secured to the forehead over the brow by an adhesive strip. The raw surface below the cilia border is allowed to heal by granulation. This objectionable feature is overcome by the plastic modification suggested by Waldhauer (*Klin. Monatsbl. f. Augenh.*, 1883, XXI, p. 432), of placing the excised strip of skin on the raw border, and the operation is usually practised now with this valuable modification. After excising the strip of skin, which should be as thin as possible, it is

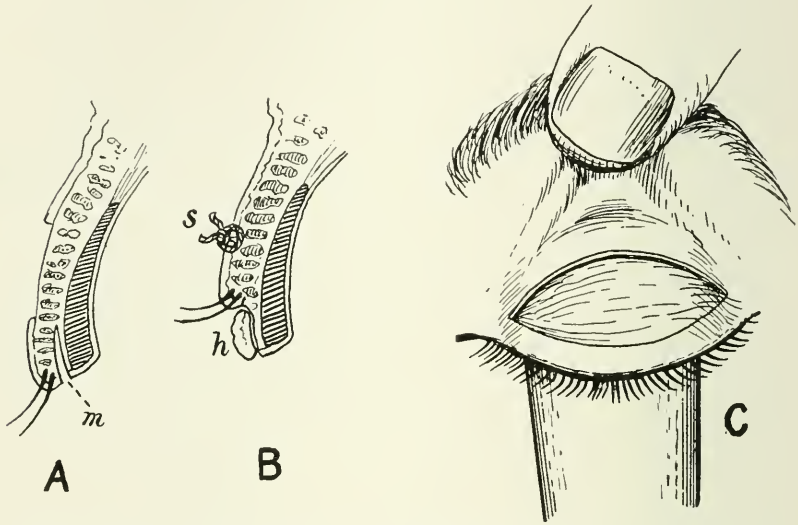

Transplantation of the Bed of Hair Follicles by the Method of Jaesche-Arlt.
A. Cutaneous incision and incision in the intermarginal line, m.
B. After tying the cutaneous sutures, s, and implanting the piece of skin, h.
C. Front view after excision of the skin has been done, with the horn plate inserted.

placed in warm 0.5 per cent. NaCl solution until the wound in the skin has been closed, as described, and the bleeding at the border of the lid has been completely checked. It can then be placed in position on the raw border of the lid, and if necessary trimmed a little, to make it fit exactly. This trimming should be done with scissors, only after the flap is in position and held by an assistant. In most cases sutures are unnecessary, but possibly a fine one may be placed at each end and one in the middle, if the flap is not nicely apposed.

Care should be taken not to excise too wide a piece of skin lest ectropion result. To avoid this, before making the skin incision, the operator should estimate the amount required by pinching up a fold of skin and noting the effect on the lid border.

As in all cases of transplantation of skin flaps, strips of rubber

tissue or oiled silk should be placed over the wounds before applying the dressing. The wound should be dressed each day, and at the end of the second day traction on the sutures may be released. The wound should have healed sufficiently by the fourth or fifth day to allow the removal of the sutures. Should the flap slough, it will be necessary to cover the granulating area with a piece of hairless skin taken from behind the ear, or with a piece of mucous membrane from the inner surface of the lip.

The Jaesche-Arlt operation, with the important modification of Waldhauer, may be practised either upon the upper or lower lid. It is more applicable in cases of partial or complete trichiasis in which there is no marked distortion or incurving of the tarsus. It has no power to correct the latter condition, because the sutures have no fixed point of support, and in such cases one must have recourse to some tarso-plastic operation.

Graefe (*Archiv. f. Ophthal.*, Vol. X, 2, p. 221), observing that the misplaced cilia at the extremities of the lid were not controlled by this method, modified it in the following manner. At each end of the intermarginal incision vertical incisions were made through skin and muscle, so that the whole cilia border could slide upward. There was then excised from the upper lid an oval piece of skin of such a size that the closure of the resulting gap would draw up the detached lid border, or loop sutures were placed and tied over rolls, to remain a few days until the lid border had become fixed in its position. The new border was then allowed to heal by granulation.

DeWecker (*Klin. Monatsbl. f. Augenh.*, 1879, p. 141) recommended, as a modification of the Jaesche-Arlt method, making first a canthoplasty; then, after an intermarginal incision, holding back the detached cilia border by the application of 3 or 4 Gaillard sutures. He allowed the border to granulate. The procedure of Bauchon (*Annales d'Oculistique*, 1879, Vol. 81) was very similar to that of de Wecker.

Landolt's operation for the relief of trichiasis. Landolt (*Arch. d'Ophtal.*, Vol. X, 1890, p. 1) changed the position of the cilia in the following rather complicated and ingenious manner. The margin of the lid was split along the gray line, as in the Jaesche-Arlt method, but the incision was made much deeper, so that all the tissues were separated from the anterior face of the tarsus. This dissection of the lid into two layers is done with scalpel and scissors. An incision (see the figure) is then made from one angle of the lid to the other, parallel to and about 3 mm. from the lid border, through the anterior layer to the tarsus. There is thus formed a bridge of tissue that includes the cilia border.

The eyelashes are then cut off quite short, and this bridge of tissue is made to glide under the upper flap, which has been undermined, by means of two loop sutures which, placed at proper places in the bridge flap, pass under the upper flap and the skin, and emerge from the skin at the eyebrow. Enough traction is made on these sutures to bury completely the cilia border under the upper flap, the lower edge of which comes down by its own weight, aided by a little traction, to form the border of the lid. The sutures are tied around a roll of gauze. After healing has taken place, and the bridge is attached in its new

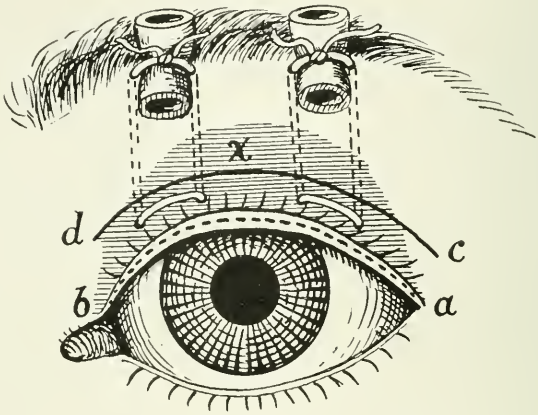

Landolt's Operation for Trichiasis.

The lid is split along the border shown by the dotted line, a, b, and all the tissues separated from the tarsus up to or above its superior border, indicated in the cut by the shaded portion. An incision, c, d, is then made 3 mm. from the lid border, and this bridge of tissue, a, b, c, d, containing the cilia, is drawn up under the upper flap x, by loop sutures, as shown in the figure. The lower edger of the flap, x, then comes down to form the border of the lid.

position to the tarsus, the sutures are removed. Another operation is done later, to liberate the eyelashes. This procedure consists in making an incision about 1 mm. from the new palpebral border, parallel to it, through which the cilia may escape.

Oettingen (*Dorpater Med. Zeitschr.*, 1871, Vol. XI, Pt. 1, p. 45), through a deep intermarginal incision, separated the anterior layer of the lid from the tarsus up to its superior border, so that the cilia zone could be drawn upward and fixed to a new position on the tarsus by means of sutures which were passed through the skin near the lashes and into the tarsus near its superior border.

The operation of Kostomiris (*Wiener Med. Presse*, 1880), was done in much the same manner.

Treatment of the free border of the lid by implantation of skin. It was soon discovered that the margino-plastic principle was necessary to prevent the cicatrix at the lid border from drawing the cilia back into their old faulty position, and, so, in the evolution of operations for trichiasis and entropion this principle came to be used more and more. The first to make use of it was Spencer Watson (*Med. Times and Gazette,* Vol. XLIX., 1874; *Trans. Oph. Soc. U. K.,* Vol. XIV., p. 17), whose operation marks a distinct advance in the treatment of trichiasis. He devised an operation for complete and another for partial trichiasis which will be described somewhat at length, because of its influence upon later operations of this class.

Operation of Spencer Watson for complete trichiasis. An intermarginal incision is made, in the gray line mentioned, from one extremity of the lid to the other, about 3 or 4 mm. in depth, splitting the lid into two layers, exactly as in the operation of Jaesche-Arlt. An incision of the same length is then made, about 4 mm. from the cilia border and parallel with it, that extends through skin and muscle to the tarsus. By loosening this there is formed a bridge of tissue, a, b, c, d, containing all the structures of the lid border lying in front of the tarsus (see the illustration). A third curved incision is then made through the skin and muscle of the lid, beginning about 6 mm. from one end of the skin incision, c, d, and meeting it about 6 mm. from the other end, e, f. This curved incision should pass through all the structures to, but not into, the tarsus. There is thus marked out by these two skin incisions an island of skin, c, d, e, f. The tissues above this island are then lightly dissected back, so as to form a raw area into which is to fit the bridge bearing the cilia. The parts are then transposed so that the bridge of tissue is placed in the gap above the island, where it may be secured by fine sutures, while the lower edge of the island is drawn down where it may be secured by two or three fine sutures. The usual moist dressing is applied and the sutures may be removed in a few days. This operation is a distinct improvement over the Jaesche-Arlt procedure in that no raw surface is left to granulate, and it removes the faulty cilia a safe distance from the eyeball. In this respect, however, it has no advantage over the Waldhauer modification of the Arlt operation, which was probably suggested by it. The fine hairs on the island of skin that is brought down to the lid border, may, if there is continuing entropion, turn inwards and irritate the eye. Like the preceding operations it is not sufficient when there is marked incurving of the tarsus.

The fact that in many cases of entropion and trichiasis the deformity exists at one or other end of the lid suggested to Watson (*Royal Lond.*

Ophthal. Hosp. Rep., Vol. VII, 1873, p. 440) an operation for partial trichiasis, based on the same principle.

Operation of Spencer Watson for partial trichiasis. An intermarginal incision is made along the gray line from the outer angle of the

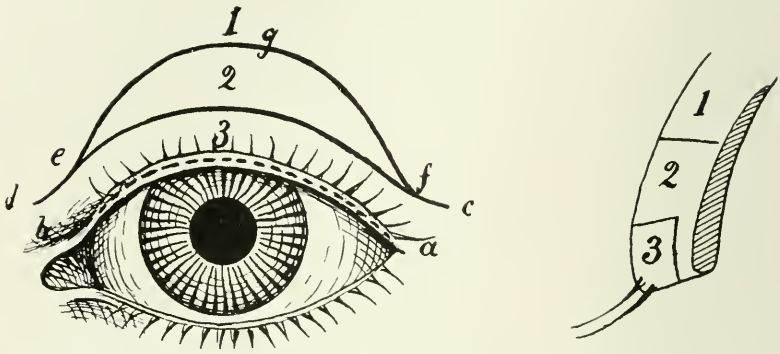

Spencer Watson's Operation for Complete Trichiasis. First Stage.

Incision made through the skin to the tarsus along the line e. d. Lid margin split along the grey line from a to b, and bridge of skin, 3. Dissected up from the tarsus. Incision along the line, e, g, f, to the tarsus inclosing the island of skin, 2. (After Grimsdale and Brewerton.)

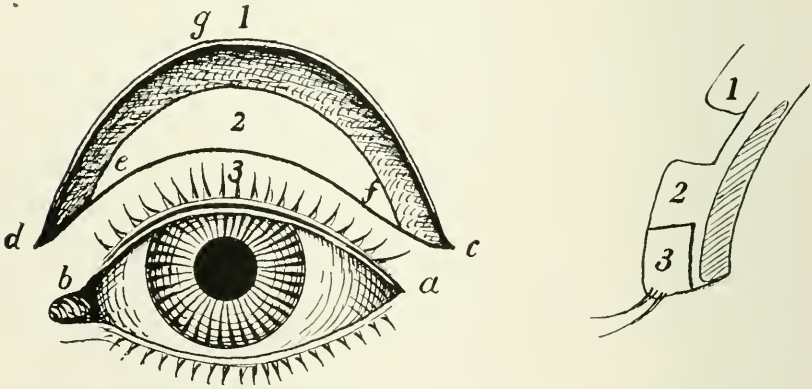

Spencer Watson's Operation for Complete Trichiasis. Second Stage.

Tissues above the island, 2, are lightly dissected back, given a raw area, c, d, e, f, g, into which the bridge of skin from the edge of the lid is to be placed. (After Grimsdale and Brewerton.)

lid to a point 1 or 2 mm. beyond where the lashes are misplaced, so as to include all the offending zone. At the outer angle this incision passes into the skin 1 or 2 mm., makes a sharp turn and then continues with an incision that runs parallel to the free border about 3 or 4 mm.

from it. It then extends up to a point corresponding to the intermarginal incision. At this point, with a sharp turn, the incision is made toward the temple about 4 mm. above the preceding one. There are thus marked out two narrow, tongue-shaped flaps, the lower being the

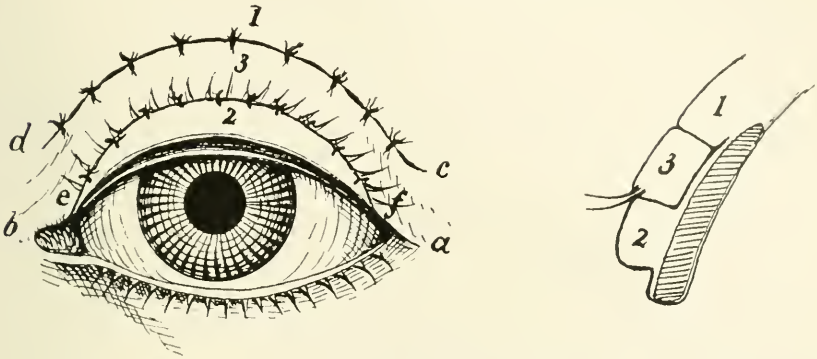

Spencer Watson's Operation for Complete Trichiasis. Third Stage.

Bridge of skin bearing the eyelashes, a, b, c, d, placed in the gap. The island, 2, brought down to help cover the denuded margin of the tarsus. (After Grimsdale and Brewerton.)

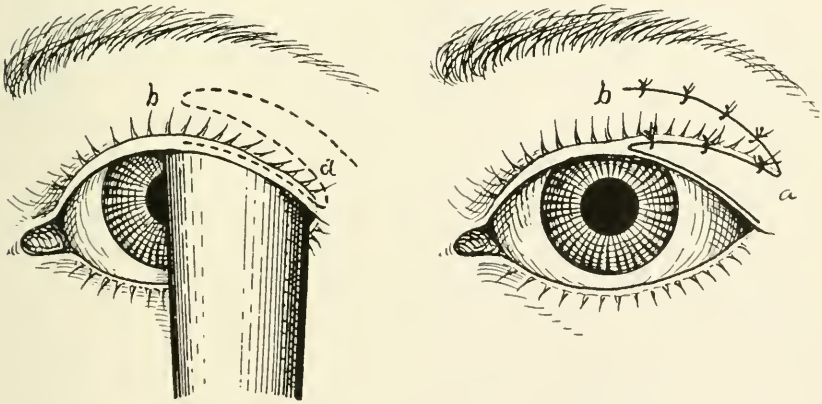

Spencer Watson's Operation for Partial Trichiasis.

A. Incision through the gray line separating the flap, b, bearing the eyelashes. a Upper flap.
B. Position of flaps when transposed. (After Czermak.)

cilia border with its attached base toward the center of the lid, the upper of skin, with its attached base toward the temple. The incisions should be so made that the tongue-shaped flaps will be somewhat longer than the intermarginal incision to allow for shrinkage. The

narrow, pedunculated flaps are then completely dissected from the underlying tissue, care being taken that the upper one includes only skin without the muscle fibers, while the lower one contains all the misplaced cilia. The flaps are then transposed so that the apex of the upper flap (see the figure) will take a position on the edge of the lid at the central end of the intermarginal incision and its lower border will form the border of the lid. The lower flap will take its place with the apex at the temporal end of the upper incision and the row of lashes in contact with the upper edge of flap a. The span of each flap can be united to the skin at the angle, where it is to rest, with a

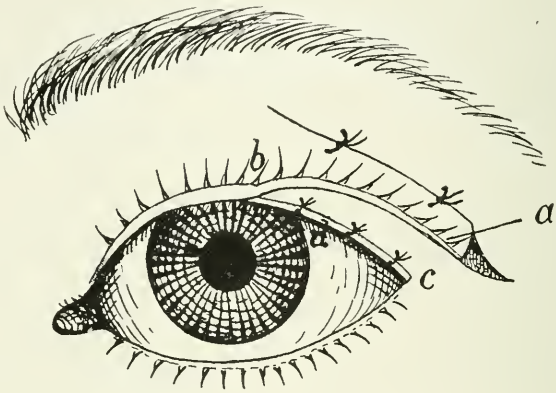

Operation of Nicati for Trichiasis.

The lid border, a, b, is planted into a new position. The skin has been drawn down to form the new border, c, d.

very fine suture, and a few fine sutures can be placed along the line of each flap, although not many, for the flaps are very delicate. None is required at the lid border. The handling of the narrow flaps is facilitated by placing the suture in the end of each before it is dissected off. Rubber tissue is placed over the wound and the usual moist dressing is applied.

The principle involved in Spencer Watson's method was followed by numerous operators, who make use of pedunculated flaps of skin or mucous membrane to fill in the gap after displacing the cilia border.

Nicati (*Marseille Médicale*, 1879, p. 99; also *Archiv. d'Ophtalmologie*, 1883, p. 395) practised a method almost identical with that of Spencer Watson for partial trichiasis, applicable to cases in which the lashes are misplaced at the palpebral extremities. (See the figure). To this he gave the name "margino-plasty." It is performed by splitting that portion of the lid border that is affected, making an

incision parallel to the lid border in part of its course and then directing it slightly upward to make a large base that will insure the viability of the flap. This flap, with its base toward the center of the lid and containing the cilia border, is then dissected up, while the lower edge of the skin just above it is drawn down to form the lid border. Then another cut is made in the skin surface at a suitable place to form a gap into which to plant the cilia border and to secure it with a few sutures.

Gayet (*Annales d'Oculistique*, 1882, Vol. 87, p. 27) observing that the long skin flaps made by the Spencer Watson operation were liable to necrosis, advised that the flaps include all the tissues down to the

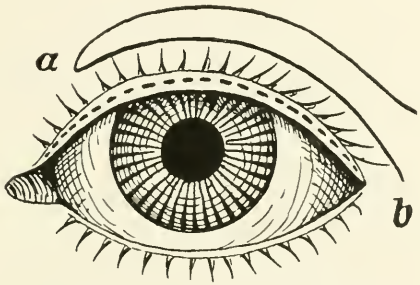

Operation of Gayet for Trichiasis.

The flap, a, b, composed of all tissues down to the tarsus is dissected up and placed in the gap made by splitting the lid along the margin and retracting the cilia border. It is held in place by a few sutures.

tarsus. After freely splitting the lid, he placed in the gap a long narrow, pedunculated flap, with a base, as large as possible, outward. This flap was taken from the lid 2 or 3 mm. above the lid border.

Dianoux (*Annales d'Oculistique*, 1882, Vol. 88, p. 132) under the name *autoplastie palpébrale*, suggested a method very similar to Spencer Watson's. He split the lid freely and made a bridge of the cilia border by an incision parallel to the free border and about 4 mm. from it. Above this incision and parallel to it another incision was made, and this was undermined so that a second bridge, of integument alone, was made. (See the illustrations). These bridges were then transposed so that the lower edge of the upper one came to the border of the lid. When the flaps were healed in place, the one forming the lid border was freed by an incision at each end.

True and Villard (*Annales d'Oculistique*, 1904, Vol. 131, p. 439) make use of a pedunculated flap for curving the lid border, essentially as accomplished in the Spencer Watson operation.

The introduction of pedunculated flaps to restore the lid border, after suitably displacing the zone of cilia, marks a distinct advance in the treatment of trichiasis, although it does not correct the deformity of the tarsus incident to the contraction of cicatricial issue on its conjunctival surface. Furthermore, it is open to the objection that in many instances the fine hairs on the skin flap come in contact with the eyeball and cause irritation, especially if the contraction of the lid continues.

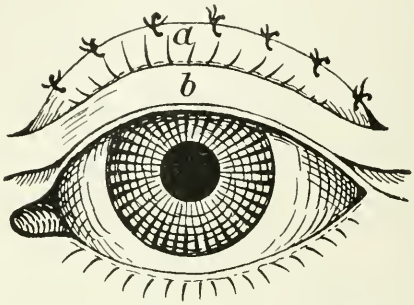

Operation of Dianoux for Entropion. First Stage.

The lid border is split along the gray line. An incision, 3 mm. above the lashes, forms the bridge, a. Another bridge of integument, b, is made by an incision 3 mm. higher.

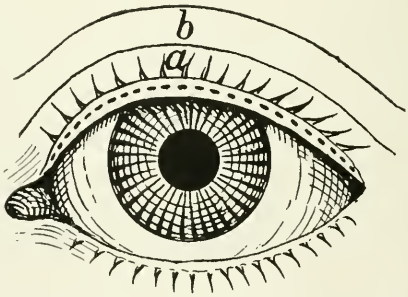

Operation of Dianoux for Entropion. Final stage. Transposition of flaps a and b.

Again, it is urged as a disadvantage of this method that the skin epithelium on the new lid border is harsh and irritating to the eyeball in those cases in which the inversion of the lid margin recurs in cicatricial entropion. Hence, it is not applicable to such cases, unless at the same time the deformity of the tarsus is corrected by some plastic procedure.

To overcome the objection of the irritating effect of the skin flap on the eyeball, Van Millingen (*Archives d'Ophtal.*, 1888, Vol. VIII,

p. 60; also *Centralbl. f. prak. Augenh.*, July, 1889, p. 193) was the first to propose and practise the use of mucous flaps to restore the lid border. He urged, also, as a further reason for their use, the marked atrophy and contraction of the conjunctiva in cases of cicatricial entropion, such as occur in the course of trachoma, the very cases in which lid border operations are most essential, because of the rounding off of the posterior margin of the free border, from shrinking and attrition.

TREATMENT OF THE FREE BORDER OF THE LID BY IMPLANTATION OF FLAPS OF MUCOUS MEMBRANE.

Van Millingen's operation for entropion. The lid is split deeply by making an intermarginal incision along the gray line that includes

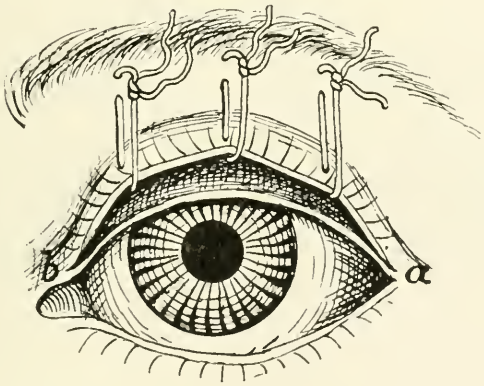

Operation of Van Millingen for Entropion.

The wound in the edge of the lid, a, b, is made to gape widely with sutures; into it is placed the flap of mucous membrane.

all the affected zone. To make this wound gape widely, sutures are placed in the edge of the wound formed by the cilia border and then attached to the skin just beneath the eyebrow. (See figure). With scalpel and scissors a flap of mucous membrane is cut from the inner surface of the lip, about 4 mm. wide and of sufficient length to fill the gap in the margin of the lid. This is done after the bleeding has entirely stopped. No sutures are used to hold the mucous graft in place, as it adheres to the raw surface and is usually retained. Care should be taken in cutting such a mucous graft, that it does not include the submucous fat. If such is the case, it should be trimmed off with scissors before it is inserted into the lid. The tension sutures are to remain for two or three days. Van Millingen emphasizes the impor-

tance of a liberal flap, and wide separation of the lips of the wound at the lid margin.

Gifford (*The Oph. Record*, Dec., 1897, p. 640) has invented a useful clamp that much facilitates the excision of mucous grafts in these and similar operations.

Entropion operation of Mutermilch. This is a useful modification (*Annales d'Oculistique*, Vol. 125, 1901, p. 5) of the operation of Van Millingen and is designed to insure the fixation of the mucous flap. The lid is split as before described and, at each end of the cut in the

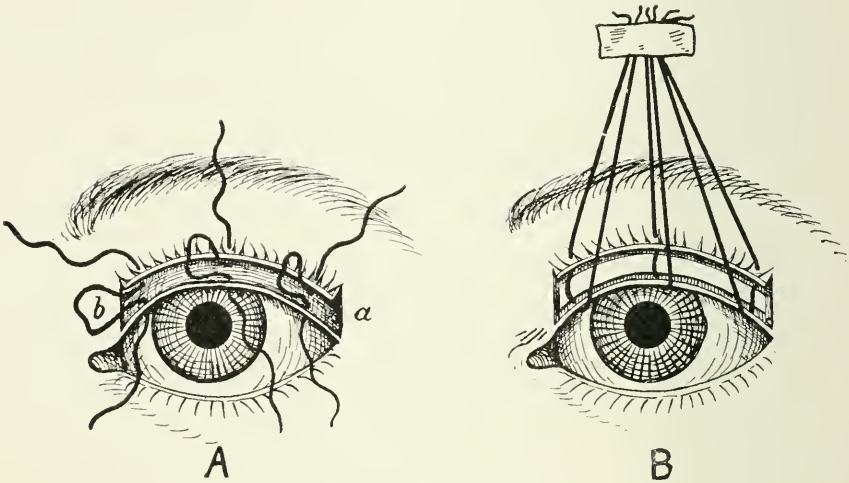

Operation of Mutermilch for Entropion.

A. a, b, Wound in the lid margin made by intermarginal and lateral incisions. Sutures are placed in the lips of the wound to form loops into which the mucous graft is placed.

B. Mucous graft held in position in the intermarginal wound.

margin of the lid, a vertical incision through the cilia border is made so that the extremities of the wound will be as wide as the middle. Three fine sutures are then placed through the edges of the wound in such a way that loops span the gap (see the figures), and into these loops the strip of mucous membrane is placed. Drawing upon the upper end of each suture presses the graft into position and holds it. The sutures are then knotted and fixed to the skin above the brow by collodion or a piece of adhesive. All bleeding should have stopped before the graft is put in place. A moist aseptic dressing should be placed over the eye and the sutures need not be removed for three or four days.

Story (*Ophthalmic Review,* Vol. IV, p. 72) advocates the use of a mucous graft in operation for entropion, and recommends that it be secured in position in the following manner: A knot is tied in a suture a few inches from its distal end, and with a fine needle the suture is then passed through the end of the mucous flap from without inwards, so that the knot will come against the mucous surface. A similar knotted suture is then passed through the other end of the mucous flap in the same way. These sutures may be passed through the ends of the flap before it is completely detached from the lip. When it is removed it can be easily handled with the help of these sutures; and all the fat should be dissected away from its raw surface.

The needles are then passed into the bottom of the wound at each end of the lid incision. They emerge from the skin a short distance from the cilia border. By the help of the knots which rest against the mucous surface, the flap can now be drawn into position in the intermarginal gap, and the sutures can be gently tied, care being taken to keep the traction on the upper end, so that the flap will not be displaced. Story advises one to place other fine sutures along the edge of the flap.

Benson also favors suturing the mucous flap in position, and prefers to leave the clamp on the lid until this is accomplished. The bleeding that follows its removal can be checked by gentle pressure for a time with a piece of moist gauze. He reports 128 cases of entropion, satisfactorily operated on by this method.

Correction of distortion and incurving of the tarsus. One of the most important facts to consider in the treatment of trichiasis and entropion, particularly in those cases that occur as a result of trachoma, is the changes that take place in the tarsus. In the early stages of the disease the tarsus may be thickened and enlarged from cell infiltration, but gradually this decreases as new cicatricial tissue is formed and the tarsus becomes smaller and deformed because of the contraction of the scar tissue, until in certain advanced cases it is markedly atrophied. The tarsus becomes changed in shape, its under surface is more concave and its anterior surface more convex—conditions aided by the shrinkage of the conjunctiva. This cicatricial change, if it involves the cilia border, causes distortion of the hair follicles, and so trichiasis results. As a consequence of the continued rubbing of the posterior margin of the free border against the eyeball, this sharp margin becomes rounded or beveled, and the free border with its oily surface, to which impalpable dust adheres, is constantly rubbing against the cornea. Even if the lashes do not touch the eyeball there is great irritation of the eye in such cases, probably because of the fine par-

ticles of dust that adhere to the edge of the lid and are rubbed against the sensitive cornea. In such cases no operation is sufficient that does not correct this incurving of the tarsus, by turning out the free border of the lid. Some operations of the class about to be considered aim to correct the deformity of the tarsus by means of tension sutures that have a fixed point of support, and in this class might be included some of the suture operations of Snellen, Boeckmann and others, although their results are rather temporary, and they are applicable more to spastic than to cicatricial entropion. A large number however, accomplish the result with section or partial excision of the tarsus itself, and this method, combined with tension sutures, furnishes a most efficacious means of treating cicatricial entropion.

Correction of incurving of the tarsus by tension sutures. The operation of Hotz (*Archiv. f. Augenh.*, IX, 1880, p. 68; also *Klin. Monatsbl. f. Augenh.*, 1880, XVIII, p. 149) is one of the best types of operation with tension sutures, and when combined with excision of a wedge-shaped strip from the anterior face of the tarsus, as this author later advocated, forms one of the best operations known.

The Hotz operation for entropion and trichiasis. A lid clamp or the horn plate of Jaeger may be used, but Hotz himself used neither, making downward tension of the lid by grasping the cilia with finger and thumb and cutting down directly to the tarsus. General anesthesia may be necessary, but if the clamp is used, local anesthesia is usually sufficient. (See the illustration.) A curved incision, parallel to the superior border of the tarsus and a few millimeters below it (for the upper lid) is made through skin and muscle down to the tarsus, beginning 2 mm. above the inner angle and ending 2 mm. above the outer angle of the lid. For the lower lid this incision is made parallel to the lid border and 2 or 4 mm. from it, because of the narrow tarsus. The upper and lower flaps are then separated from the tarsus by blunt dissection, so that the whole lid plate is exposed to view except at the lid border, where the dissection is stopped as soon as the black points of the eyelash follicles are encountered. The next step, an important one, is to dissect off the muscle bundles from the inner side of the lower flap. This is best done, with least risk of puncturing the skin, if the assistant seizes the skin at the edge of the flap with a fine-toothed forceps and gently stretches it at right angles to the tarsus, while the operator grasps the bundle of muscle fibers with toothed forceps and dissects them off with delicate blunt-pointed scissors. If muscle fibers overlap the upper border of the tarsus, these should also be excised. If the clamp is used, it should be removed at this stage, and the bleeding checked. Sutures, three or four, according to the size of the wound,

are placed in the following manner: The lower skin flap is pierced 2 mm. from its edge, the needle is then passed through the upper border of the tarsus to emerge through the fascia attached to it, and finally comes out through the edge of the upper flap, not, however, including any muscle fibers. Passing the suture through the upper border of the tarsus is much facilitated if the operator pick up the tarsus with the point of the needle so that he can grasp the edge of it near the point that he wishes to transfix. Tying the sutures brings the lower

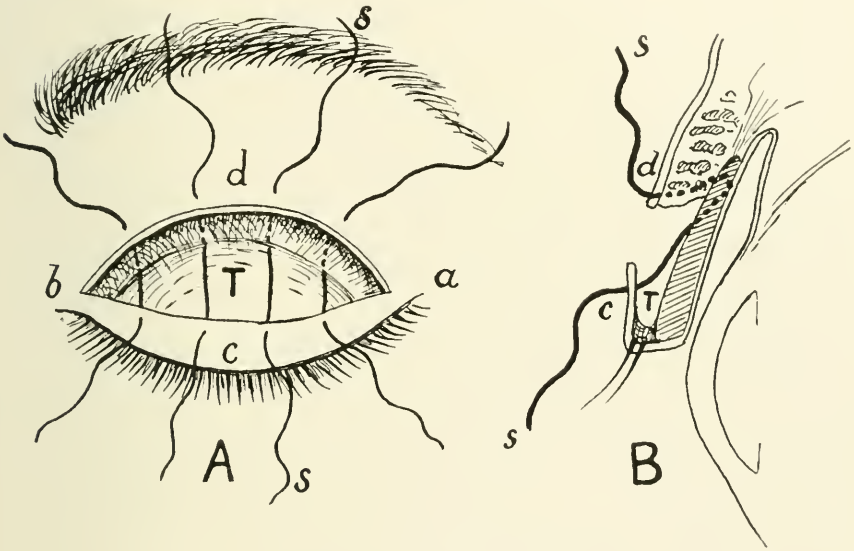

The Hotz Operation for Entropion.

A. Incision, a, b, being separated, exposes the face of the tarsus, 1.
B. Muscle dissected from the lower skin flap, c; Sutures, s, pass through the lower skin flap, upper edge of the tarsus and fascia, T, and come out through the edge of the upper skin flap, d.

skin flap in contact with the surface of the tarsus, where it becomes fixed, and at the same time closes the wound. Care should be taken that the lips of the wound are well coapted. The tension exerted by the lower flap, from its fixed point of support at the upper edge of the tarsus, turns out the edge of the lid. A moist dressing is used, and the sutures may be removed at the end of the third or fourth day. Hotz in a later communication (*Klin. Monatsbl. f. Augenh.*, 1888, Vol. LVI, p. 98) combined with his operation excision of a wedge-shaped strip of the tarsus near the lid border in extreme cases of entropion, and at the present day, the operation is frequently made with this modification.

Anagnostakis (*Annales d'Oculistique,* 1857, XXXVIII, p. 5) was probably the first to call attention to the principle contained in the Hotz operation, viz., attaching the cilia border to the upper margin of the tarsus by means of a skin flap.

He made the incision nearer (about 3 mm.) the lid border, by which the everting effect is considerably increased, and also excised the muscle fibers from the anterior surface of the tarsus. With sutures he then united the lower skin flap to the upper border of the tarsus.

Warlomont (*Annales d'Oculistique,* 1874, Vol. 71, p. 221), following the same idea, made an incision parallel to the lid margin, cut away the muscle bundles and sewed the lower skin flap to the fascia above the tarsus.

Pagensteeher (*Archiv. für Ophthal.,* Vol. XXXVI, 4, p. 265) modified the operation of Hotz by passing the sutures in such a way that the tendon of the levator was advanced, and the skin of the lid was given an attachment to it. An incision, parallel to the lid border, and about 1½ mm. below the upper border of the tarsus was made, exposing the tarsus. The lower flap was then carefully separated from the tarsus and drawn down, the upper lip of the wound, with all the muscle fibers, was retracted upward, so as to expose the upper margin of the tarsus and the expansion of the levator tendon.

In placing the sutures, the needle passes through the lower flap, about 1 mm. from the cilia border. The operator then seizes the tendon of the levator immediately above the superior tarsal margin with a toothed forceps and passes the needle through the upper margin of the tarsus and through the fold of tendon and fascia in the grasp of the forceps. The needle is then passed through muscle and skin of the upper lip of the wound, some distance from its edge. Sutures on either side of the middle one are then passed in the same manner. Care must be taken in tying the sutures that the edges of the wound are well coapted.

This operation of Pagenstecher not only tends to withdraw the cilia from the eyeball, because of drawing up the lower skin flap, but also tends to raise the whole lid by shortening somewhat the tendon of the levator, which is included in the suture. It is thus beneficial in correcting the slight ptosis which is so frequently present in cases of entropion from trachoma. The same may be said of the operation of Hotz, Anagnostakis and Warlomont, although to a less degree. One should remember, therefore, that, by placing the suture so as to include both the superior border of the tarsus and a fold of the tarso-orbital fascia, together with the tendon of the levator, not only the entropion will be corrected, but the ptosis as well.

CORRECTION OF DISTORTION AND INCURVING OF THE TARSUS BY SECTION OR PARTIAL EXCISION OF IT OR A COMBINATION OF THIS WITH SUTURES. TARSOPLASTY.

Operations of this class mark a distinct improvement in the treatment of cicatricial entropion, especially in cases where the tarsus is thickened and incurved. The objection that by excision of a piece of the tarsus, the lid is shortened is not valid in most cases, inasmuch as the amount usually removed, a strip at most 2 or 3 mm. wide, cannot effect shortening to any serious extent. Furthermore, in just the cases where it is indicated, there is frequently a mild degree of ptosis, so that the slight shortening that might result would be more beneficial than otherwise.

The criticism that section or resection of the tarsus disturbs the Meibomian glands, or even destroys them, is hardly a reasonable one, for in the class of cases in which this treatment is applicable, the glands are probably to a great extent atrophied or obliterated owing to the contraction of the tarsus, as pointed out by Hotz.

Entropion operation of Burow. (*Berlin Klin. Wochenschr.*, June, 1873, p. 295.) The upper lid is everted, and with a round, pointed scalpel an incision, about 3 mm. from the free border and parallel to it, is made from one end of the tarsus to the other. This cut extends in depth through the tarsus and the muscular layer to the skin. Thus the cilia border falls away from the eyeball, and in some cases Burow found the incision alone was sufficient to benefit the condition. In more severe cases of entropion, he found it necessary to remove a flap of skin from the anterior surface of the lid, the necessary amount to produce the required eversion of the lid border being determined by picking up a fold with the forceps and then incising it with scissors and scalpel. Three or more sutures then close this anterior wound, and the gap in the tarsus is left to granulate.

Gifford (*Ophthalmic Record*, July, 1903, p. 327) suggested filling in the wound in the tarsus with a flap of mucous membrane taken from the lip, a procedure that he later abandoned.

Maher (*Archives of Ophthalmology*, July, 1897, p. 340) reports success in sixty cases by a similar procedure, in which he fixes a mucous flap from the lip into the gap in the tarsus by sutures that pass through it to the outer surface of the lid.

Ammon (*Encyclopédie franç. d'Optal.*, Vol. IX, p. 174) also made an incision through the tarsus and tissues of the lid from the conjunctival side.

Operation of Green for entropion. (*Trans. Amer. Ophth. Soc.*, 1880,

Vol. III, p. 167.) This operation is intended by its author for those cases of cicatricial entropion, occurring in trachoma, in which there is marked incurving and a furrow on the conjunctival side of the tarsus. It is done in three stages: First stage. The upper lid is held firmly everted with the fingers. With a round-pointed scalpel an incision, parallel to and 2 mm. from the row of openings of the Meibomian glands, is made through the tarsus, in extreme cases extending from near the inner to the outer canthus. This incision (see

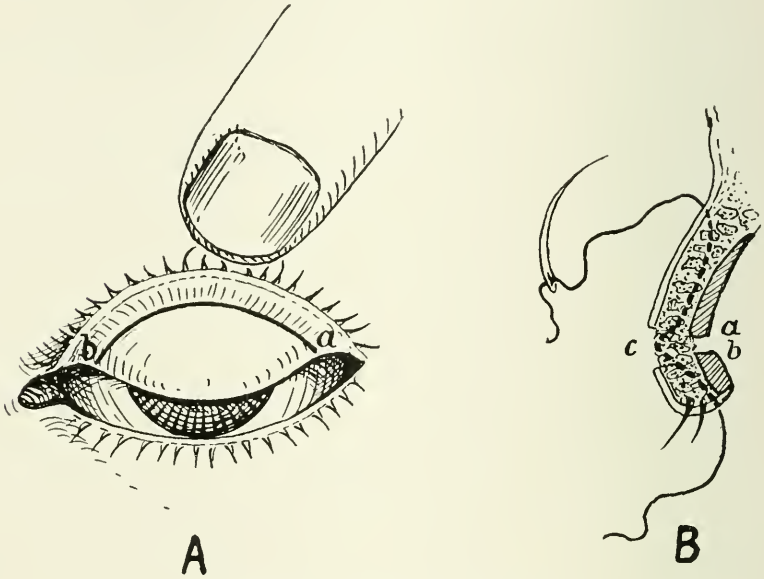

Operation of Green for Entropion.

A. The upper lid is everted and an incision is made through the tarsus, 2 mm. from the lid margin; from a to b.

B. Needle with a suture is passed behind the row of cilia out through the lower border of the skin wound, c, on the anterior surface of the lid; reintroduced and passed deeply, grazing the tarsus, to emerge 1 cm. above the skin wound. Tying closes the wound and everts the lid border.

figure) is carried through the entire thickness of the tarsus, but does not extend into the muscular layer, as in the operation of Burow. Second stage. The lid is then replaced, and a strip of skin, not exceeding 2 mm. in width, is excised from the anterior surface of the lid. The lower border of the strip should be about 1½ mm. from the line of the eyelashes, and the tissue removed should be only skin and connective tissue, leaving the muscle intact. Third stage. Fine silk sutures, armed with small curved needles, are passed as follows: A

needle is introduced at the edge of the lid, just behind the row of eyelashes, and brought out just within the wound in the skin. The needle is then reintroduced into the upper border of the skin wound, passed deeply backward and upward to graze the anterior face of the tarsus, and brought out 1 cm. or more above the point of entrance. Three such sutures are passed and, when tied, not only strongly evert the cilia border, but close the skin wound. The sutures are removed after a day or two. The lashes are held in the everted position by collodion applied to them until the widely-gaping wound in the tarsus has nearly healed, as it does by granulation.

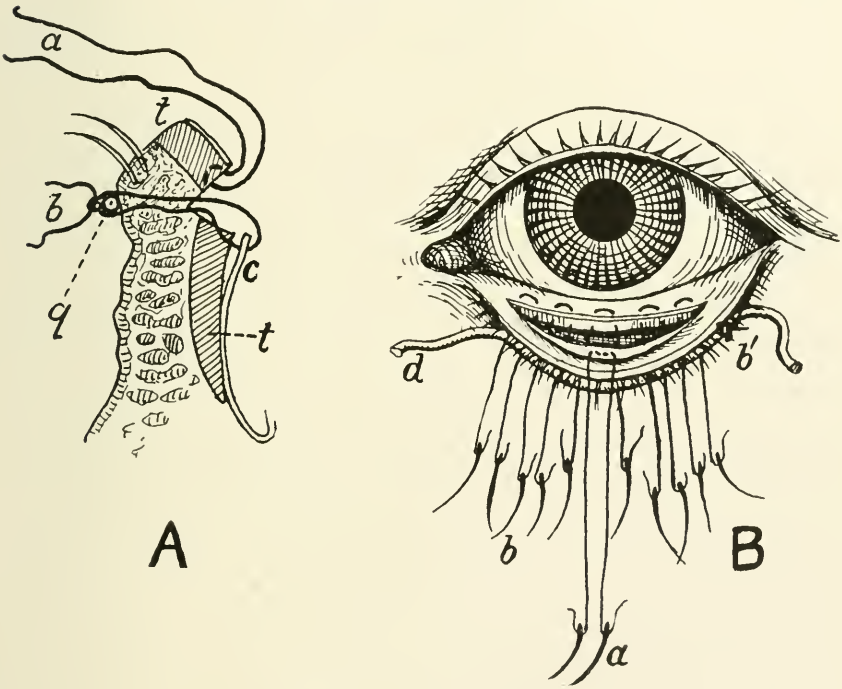

Operation of Ewing for Entropion.

A. Diagram illustrating placing the sutures in the lower lid.
a, Traction stitch to cause the cut in the tarsus to gape widely.
b, Loop suture passing through the edge of the conjuctival flap, c, then through the lip of the tarsal wound, the bottom of the tarsal wound emerging behind the lashes, to be tied around a catgut quill. t, Tarsus.
B. Showing the sutures in place on the lower lid. a, Traction stitch. b, Loop sutures through the conjunctiva and the tarsal wound, to be tied over a strand of catgut, d.

Ewing (*Trans. American Ophth. Soc.*, Vol. IX, p. 15; also *Ophthal. Record*, October, 1907, p. 490, and January, 1908, p. 6. See, also, *Bull. Med. Dep. Washington Univ.*, Vol. V, No. 4; Vol. VI, No. 1)

modifies this operation in an important way, endeavoring to partially fill in the gap in the tarsus by means of conjunctiva. Beginning at the posterior margin of the free border of the lid, he dissects back the conjunctiva from the tarsus to a distance of 4 or 5 mm. along the whole length of the lid. [This seems to be a detail of some difficulty, because of the intimate relation of the tarsus and conjunctiva]. Retracting the conjunctival flap, he makes an incision through the tarsus exactly as in the Green operation. To aid the assistant in strongly everting the cilia border during the placing of the sutures, he introduces a temporary stitch in the cut surface of the tarsus, so that traction on it will cause the tarsal wound to gape widely (see figure). For the upper lid, seven or eight fine, double-armed loop sutures are then introduced; for the lower four or five suffice. The needles are first passed about 2 mm. apart, through the edge of the conjunctival flap which was dissected back; then through the bottom of the wound, back of the tarsus bearing the cilia, to emerge on the skin just back of the cilia. For convenience in removing the sutures and to prevent them from cutting too deeply into the skin, all the stitches are tied over a fairly large No. 12 strand of catgut placed along the edge of the lid, thus making a kind of quill suture. Tightening the sutures draws the conjunctiva into the wound and strongly everts the edge of the lid.

The eye is dressed in the usual way, and sutures may be left in place for five or six days if suppuration does not occur. On the second day the lashes are held back over the quill sutures by collodion.

Entropion operation of Williams. (*Liverpool Medico-Chirurgical Journal,* 1882.) The lid is everted and an incision is made through the tarsus from end to end, about 4 mm. from the lid border, as in the Green operation, the cut not extending into the muscular layer. A needle, with suture attached, is passed from the conjunctival side through the tarsus and lid below the tarsal incision, emerging from the skin just above the eyelashes. (See figure.) It is then reintroduced a short distance above, to take a firm hold on the tarsus above the line of tarsal incision and withdrawn again through the skin. Three or four such sutures are passed at equal intervals, and the loops are tied over a small roll of adhesive or tubing. Tightening the sutures, of course, everts the lid border and causes the cut in the tarsus to gape. The wound surfaces are allowed to heal by granulation.

Operation of Lagleyze. Lagleyze (*Archives d'Ophtalmologie,* Dec., 1904, p. 773) of Buenos Aires practises an ingenious modification of the Burow operation, notable on account of the manner in which he places the tension sutures. (See the figure.) Five, or even six, needles,

each about 3 cm. long, are threaded on one long suture and passed through the lid in the following manner: The upper lid being held

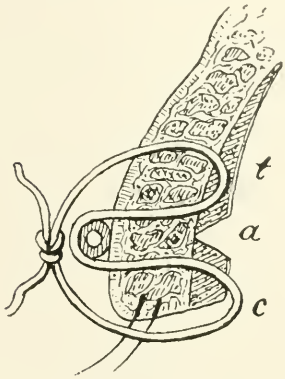

Operation of Williams for Entropion.

A suture is passed through the tarsus below the incision, a, and emerges on the skin of the lid above the eyelashes. It passes over a roll, enters the skin and takes hold of the tarsus at a point above the tarsal incision. Tightening the suture causes the cut, a, to gape and everts the lid border. (After Grimsdale and Brewerton.)

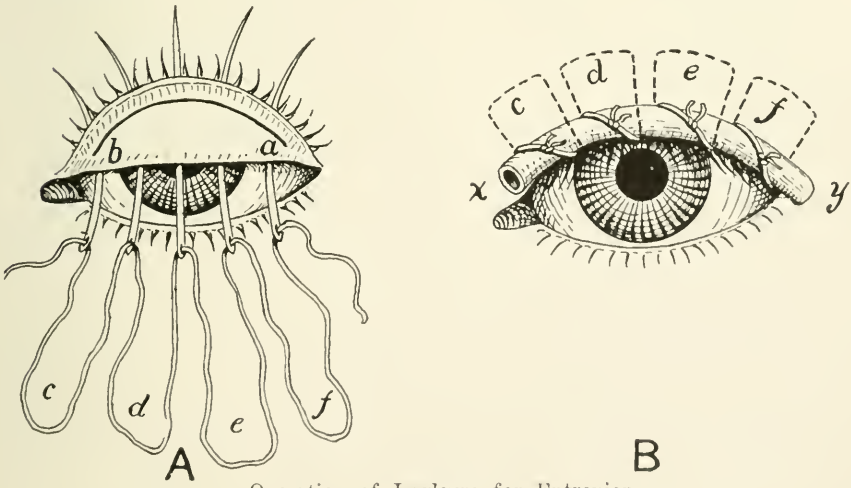

Operation of Lagleyze for Entropion.

A. Upper lid everted. Needles 3 cm. long threaded on one suture, c, d, e, f, transfix the lid, passing from the superior border of the tarsus along its anterior face to the cilia border. These form a guide for making the incision through the tarsus, a, b.

B. Sutures tied over the tubing, x, y, forming loops, c. d, e, f.

strongly everted, the middle needle on the suture enters the conjunctiva at the middle point of the superior border of the tarsus, glides

along the anterior face of the tarsus and emerges from the skin among the lashes, or at a point immediately behind them. It is allowed to remain, transfixing the lid, serving as a means of holding it in place until the other needles on the suture have been passed in a similar manner at equal distances apart, emerging from the skin at corresponding points near the row of cilia. Thus, if five needles are used, there are four loops of suture to catch the tarso-orbital fascia and levator tendon. While all the needles are in place, as shown in the figure, the operator makes an incision through the tarsus, from end to end, about 3 mm. from the lid border, and the needles serve as a guide to tell him when the incision has completely passed through the tarsus. In incomplete entropion, the length of the incision will be proportionate to the degree of the deformity, but should always extend beyond the limits of the entropion. After the incision the needles and suture are drawn through and the lid is replaced in its natural position. The thread is then cut from each needle and the ends corresponding to each loop at the superior tarsal border are tied over a small roll of gauze or tubing placed at the margin of the lid. The sutures are allowed to remain seven or eight days, and the wound in the tarsus is allowed to heal by granulation, as in the procedures previously described.

The healing by granulation of the gaping wound in the tarsus, and the inevitable development of new cicatricial tissue on its concave surface, where scar tissue is already causing contraction, would suggest a natural objection to operations of this class. Their authors, however, and many others, seem to have had excellent results from them. This objection is met by operations that aim to correct the incurving of the lid by incision or excision of a piece of the tarsus from the anterior surface.

SECTION OR PARTIAL EXCISION OF THE TARSUS FROM THE ANTERIOR SURFACE.

Streatfeild (*Royal Lond. Ophthal. Hosp. Reports*, Vol. II, p. 247) was probably the first to suggest and put into practice this principle.

Streatfeild's operation for entropion. An incision that extends the length of the lid is made about 2 mm. above the row of eyelashes and parallel to it. This incision passes through skin, connective tissue and muscle to the tarsus, 2 or 3 mm. above this and parallel to it. A second incision is made to the tarsus, joining the first at the extremities. The tissue between these incisions is then resected. Two parallel incisions, about 2 mm. apart, are then made obliquely in the tarsus through its whole length, and the wedge-shaped strip so formed is

excised. The incisions do not extend deep enough to divide the conjunctiva. Believing that a more permanent result can be obtained by a firm cicatrix, Streatfeild used no sutures to close the wound, but allowed it to heal by granulation.

The principle (excision of a wedge-shaped strip from the anterior surface of the tarsus) forms an essential feature of many of the most valuable combination forms of operation for entropion.

Snellen's operation for entropion. (*Encyclopédie française d'Ophtalmologie*, Vol. IX, p. 175.) This important modification of Streat-

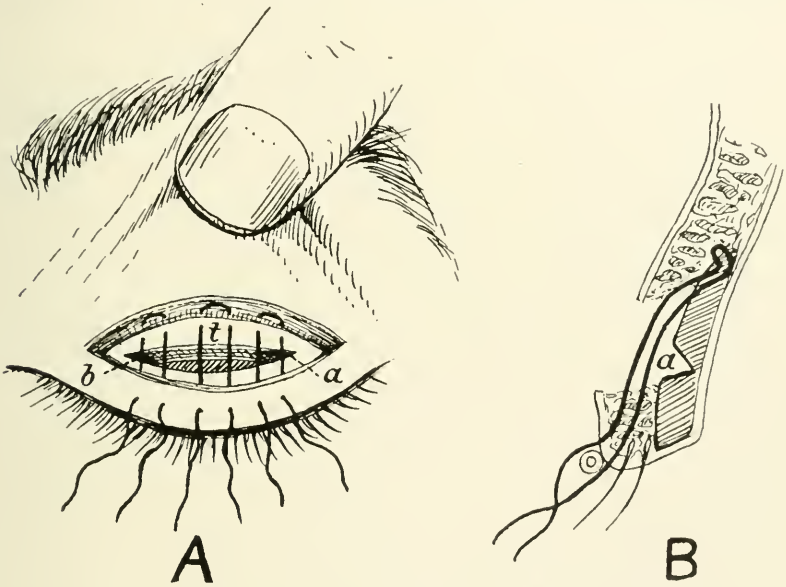

Operation of Snellen for Entropion.

A. Incision through the skin and muscle to expose the face of the tarsus, t. The wedge-shaped strip, a, b, is cut out of this. Loop sutures are passed from the superior border of the tarsus, to emerge just above the line of the cilia, to be tied around beads or a roll.

feild's principle combines the sutures of Anagnostakis with grooving of the tarsus. The lid is held in Snellen's or Knapp's lid clamp, and an incision about 2 mm. from the lid border, and parallel to it, is made the length of the lid through all the tissues down to the tarsal plate which, by light dissection, is then laid bare. Some of the muscle bundles may also be removed. A wedge-shaped strip of tarsus (see the figure), whose base corresponds to the anterior face of the tarsus, and from 1 mm. to 2 mm. in width, varying according to the degree of the incurving, is then excised from that part of the tarsus indi-

cated by a more or less marked ridge lying over a corresponding furrow on the conjunctival side. This strip may be excised most readily with a cataract knife, or with the two-bladed entropion knife. It includes the whole thickness of the tarsus, or nearly so, and extends from one end of it to the other, but some care should be used not to include the conjunctiva in the cut.

Three double armed sutures are passed (as shown in the illustration) at equal intervals as follows:: The superior border of the tarsus is seized with toothed forceps and one needle is made to transfix it; the other needle passes through the superior border about 2 mm. from the first. The needles then pass beneath the lower skin flap, grazing the tarsus, and emerge about 3 mm. apart just above the row of lashes. The sutures on either side of the middle one are passed in a similar manner, at such distances from it as to produce a symmetrical eversion of the lid border. A small glass bead is strung on the thread and the suture is tied over it; or it may be tied over a small roll of gauze or a bit of tubing. The effect of tightening the sutures is not only to evert the lid border and turn out the cilia, but also to reduce the excessive curve of the tarsus. Skin sutures may be necessary, or the sutures may be left long and secured to the forehead, which will coapt the edges of the wound fairly well. The sutures should be removed in three or four days, to prevent the beads from causing necrosis of the skin at the points of pressure.

Entropion operation of Panas. (*Maladies des Yeux,* Vol. II, p. 153; also, *Archives d'Ophtal.*, 1882, p. 208.) In this operation none of the tarsus is removed, but it is divided completely from the anterior surface, the incision including the conjunctiva. Either a wide Snellen lid clamp, or the horn plate of Jaeger, may be used; if the latter, the assistant holds it firmly against the under surface and also draws the lid downward. An incision is then made 3 mm. from the lid border, parallel to it and extending the whole length of the lid. This incision passes through skin and muscle to the tarsus, which is then laid bare by dissecting up the upper lip of the wound until the superior border of the tarsus and the levator tendon are seen; finally separating the lower lip nearly to the lid border, not disturbing the follicles of the eye lashes. It is necessary to expose the tarsus throughout its whole extent. The tarsus is then divided from one end to the other (see the cut) by an incision that includes the conjunctiva, at right angles to its surface and about 3 mm. from its free border. In cases of partial entropion a correspondingly shorter incision will suffice. Five sutures are then passed at equal intervals as follows: The needle transfixes the tendon of the levator and superior border of the tarsus, then passes behind the

muscle of the lower flap to emerge just behind the cilia on the free border (see figure). Four other sutures are passed in a similar manner; when tied they strongly evert the lashes. Care should be taken, when tying the sutures, to prevent the lower tarsal flap from riding on the upper part of the tarsus. To avoid this, and the resulting great disfigurement, Thilliez (*Encyclopédie française d'Ophtal.*, Vol. IX, p. 178) suggested that the incision should not extend continuously across the tarsus, but that a narrow strip (1 mm. or 2 mm. wide) in the middle should be spared. This narrow piece of undivided tarsus

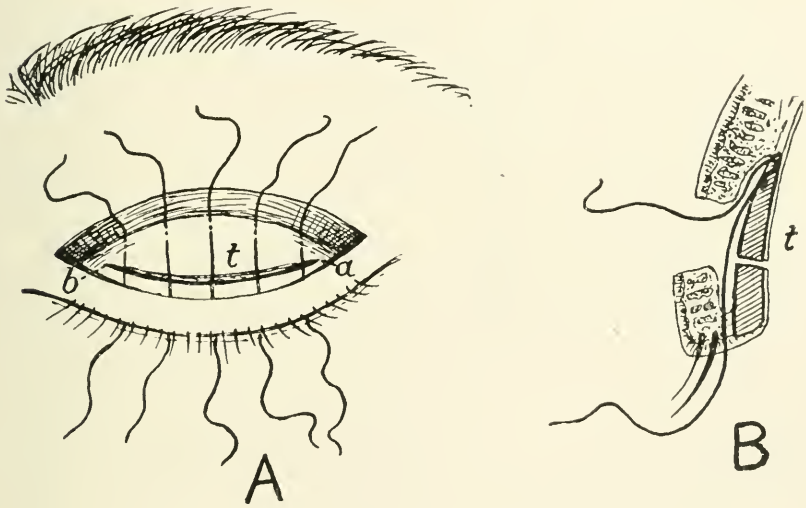

Operation of Panas for Entropion.

A. The tarsus, t, is exposed and a cut made through its entire length from a to b, including the conjunctiva. Sutures are then passed through the upper border of the tarsus and emerge at the free border of the lid just behind the lashes.
B. Diagram of a vertical section showing the position of the sutures.

would fold easily, and so would not interfere with the desired eversion of the lid.

The sutures may be left long, to be attached to the forehead above the brow with collodion or adhesive, and this coapts the edges of the skin wound so that no other sutures are required.

This operation accomplishes the bending forward of the tarsus, and holding it in this position, by the firm union of the cilia-bearing flap, to a higher point on the tarsus. However, inasmuch as the conjunctiva has been divided, the incision on the conjunctival surface of the tarsus will gape when the lid is everted, and this defect will

have to fill in with granulation tissue, exactly as in cases where the tarsus is divided from the conjunctival surface.

COMBINATION OPERATIONS FOR ENTROPION.

Recognizing that in some cases it is impossible to correct severe entropion with any single operation, many surgeons of experience have combined certain features of different operations. In most of such combinations tarsoplasty or tarsotomy figures, and an attempt is made in some of them to widen the free border of the lid by mucous or skin grafts (marginoplasty).

Knapp (*Jahresbericht f. Ophthal.*, 1895, p. 548) operated somewhat after the manner of Snellen, by excising a wedge-shaped strip from the anterior surface of the tarsus. He then split the lid border and implanted into the gap a narrow piece of skin taken from the lid or from the hairless skin behind the ear.

Pagenstecher (*Encyclopédie franç. d'Ophtal.*, Vol. IX, p. 179) combined his operation with canthoplasty, and an incision through the tarsus in cases of incurving.

Weeks (*Trans. Am. Ophthalm. Soc.*, Vol. IX, p. 18) recommends a modification of the Streatfeild and Snellen operations, and combines this with grafting into the lid border a piece of mucous membrane, after the method of Van Millingen.

Gifford (*Ophthalmic Record*, 1903, p. 325), after doing a Hotz operation, before tying the sutures, everts the lid and makes an incision through the tarsus after the manner of Burow and Green.

Beard's operation for entropion. Beard (*Ophthalmic Surgery*, 1910, p. 264), believing that in most of the severe cases of entropion resulting from trachoma an over-effect at the time of the operation is essential to prevent a recurrence of the trouble, combines many of the various principles that have been mentioned. He first does a canthotomy or canthoplasty, with free division of the raphé. He next makes a deep intermarginal incision, not in the gray line between tarsus and muscle, but splitting the tarsus itself. This may be 3 mm. in depth and long enough to receive the ample flap of mucous membrane to be provided for it. (See the figure.) He then makes a cutaneous incision, and exposes the tarsus by dissecting back the flaps and removing the bundle of orbicular muscle fibres from the lower flap, as in the Hotz operation. A wedge-shaped piece of tarsus is then excised, after the manner of Snellen. In passing the sutures he obtains an extreme eversion by following the principle of the Pagenstecher operation. After the suture passes through the lower skin flap it pierces a fold of the tarso-orbital fascia and levator ten

don that has been seized by toothed forceps, and emerges through muscle and skin of the upper flap a considerable distance above the edge of the wound. Beard accomplishes in this way not only eversion of the lid border, but correction of the slight ptosis so frequently present in these cases. Finally, the deep gap in the lid border is filled with a strip of mucous membrane, 5 or 6 mm. in width and of suitable length, cut with scissors from the inside of the lower lip. It attaches

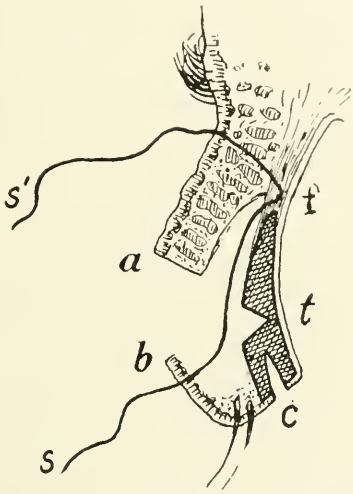

Beard's Operation for Entropion. Vertical Section.

Intermarginal incision in the tarsus at c. Skin incision, a, b. Wedge-shaped piece of tarsus excised at t. A suture, s, s, passes through the lower skin flap, then through the tarso-orbital fascia at t, and emerges through the upper flap some distance from the cut. Mucous membrane from the lip is placed in the defect in the tarsus, c.

itself without sutures. This is an adaptation of the Van Millingen operation.

The eye is covered with a thin layer of cotton wet with boric acid solution, the usual dressing applied and allowed to remain for forty-eight hours; at the first change of dressing all the sutures are removed. A similar moist dressing is reapplied every day for one week, at the end of which time the marginal graft is secure, although even after the removal of the bandages the graft should be coated with a little vaselin for several days, to prevent desiccation. The Editor can testify to the pronounced and lasting effect produced by this combination of operations in the most difficult cases, and with a few differences it is the operation he usually practises on the severer cases.

As stated by Beard, cases of entropion are frequently of a pronounced character, following a long-standing trachoma that has been neglected and has received little or no treatment. The tarsus is usually so badly affected as to require some form of tarsoplasty. The free border of the lid usually needs to be repaired by a marginoplasty, and the palpebral fissure is so much shortened as to require a canthoplasty.

Wilder's combined operation for marked and neglected forms of entropion. In such cases the following combination operation is recommended: First. Canthoplasty. In taking this step it may not be necessary to make an especially long cut, but, after the eye is cocainized and the canthus is divided with the scissors, the operator should reach into the rhomboidal wound, above and below, with a pair of fine-pointed scissors and divide freely the attachment of the orbicularis fibres to the raphé. It is to check the sphincter action of the orbicularis that a canthoplasty is made in entropion, and this may be accomplished through a small wound, if the attachment of the muscle to the raphé is divided, as well as through one of greater length. The long cut in the canthus has the disadvantage that the shortened conjunctiva cannot be brought out to fill the gap.

After the canthoplasty a Knapp or Snellen clamp is applied to the lid. If the palpebral fissure is not wide enough to admit one of sufficient size, a Warlomont clamp is used, the blade of which can be at first narrowed and then widened after its introduction. When the clamp has been fitted in the proper position it should be so held by an assistant as not to press upon the eyeball. The operator then injects about ten drops of 1 per cent. cocaine solution beneath the skin along the line of the proposed incision and dissection. In a minute or two anesthesia will be complete, and he can continue the operation.

Second. The cutaneous incision. This follows the line of the Snellen incision rather than that of the Hotz, and is made about 2 mm. to 3 mm. above the lid border and nearly parallel to it along the whole length of the lid. At its extremities it approaches slightly nearer the cilia border than in the middle, but the whole flap is narrower than in the Hotz operation. This incision extends through all the tissues to the tarsus and, as in the Snellen operation, the tarsus is laid bare by dissecting both flaps away from it.

Third. Excision of muscular fibres. All the muscle fibres attached to the lower flap are carefully excised, as well as the bundle of fibres lying immediately in front of the tarsus. This neat dissection can be done much more accurately in a bloodless field, and for this reason the clamp is to be preferred. As was pointed out by Hotz, this

feature of excision of muscle fibres lying next to the lid border is of great importance in correcting the blepharospasm.

Fourth. Excision of a wedge-shaped piece of tarsus. This step is taken after the manner of Snellen, either with a Beer's or Graefe knife, or with the double entropion knife of the author, the blades of which are adjustable. (See the figure.)

Fifth. Introduction of sutures. Before the sutures are placed the clamp is removed and the bleeding is checked. Three sutures are then placed, as in the Hotz operation, passing them first through the lower skin flap, then through the upper margin of the tarsus (including a fold of the tarso-orbital fascia, as in the Pagenstecher operation) and out through the skin (but not through the muscle) of the upper skin



Wilder's Double Adjustable Entropion Knife.

flap. By avoiding the muscle fibres when bringing the suture through the upper skin flap, these fibres are held back by the suture, so that the lower skin flap, denuded of its muscular layer, can coapt itself to the anterior face of the tarsus. Possibly a somewhat more pronounced eversion is produced by the Snellen suture (see operation of Snellen), which the author sometimes uses, but the principle is the same.

Before tying the sutures, all clots should be removed from the gap in the tarsus and from the lower skin flap, so that the lid border will turn forward as desired and there may be nothing in the wound to prevent the perfect coaptation of the lower skin flap with the tarsus.

After tying the sutures they may, before cutting them, be used as an aid to hold the lid while the operator is making the intermarginal incision, if it is thought best to use a marginal graft.

Sixth. Intermarginal graft. This may be of mucous membrane from the lip or of skin taken from behind the ear. The lid margin is divided behind the row of cilia, and into the gaping wound is placed the narrow graft, not more than 1½ or 2 mm. in width. This graft may be cut with a Graefe knife, or with the double entropion knife referred to. The sutures are then cut off and a moist dressing is ap-

plied, to be changed each day. At the end of the third or fourth day the sutures may be removed, but the dressing should be continued for a week.

The difficulty of correcting trichiasis and entropion, and securing a permanent good result is indicated by the great number of operations that have been devised for their treatment. An attempt has been made to here describe the typical operations, with their most noteworthy modifications and principles on which they are based. It would be impossible in this space to give in detail all the modifications that have been suggested, but enough have been presented to show that no one type of operation is suitable for every case. The experienced operator will select that method which, in his judgment, is most applicable to the case in hand, or will modify it to meet the exigencies of such a case. Bearing in mind the main principles underlying the typical operations, he will be able to combine them, if necessary, to produce the desired result.

If the entropion is of the spastic variety it may be relieved by one of the simple suture operations, or, at worst, by that of Hotz.

Many of the operations described produce their greatest effect on the middle of the lid, so that if the trichiasis is partial and affects particularly the inner or outer angles, an operation such as that of Spencer Watson for partial entropion would be applicable.

In severe cases, where the tarsus also is deformed or incurved, nothing short of tarsoplasty of some kind, combined with other methods, will suffice to effect a cure.—(W. H. W.).

The *Ophthalmic Year-Book* furnishes the following reviews and criticisms of various operations and procedures for the relief and cure of entropion.

Risley (*Ophthalmic Record*, p. 309, 1910) effected a complete cure of entropion of both lower lids by galvano-puncture, 3 on one lid and 4 on the other, 3 mm. apart, through the skin into the cartilage without perforating the conjunctival surface. Zeigler (*Tr. Sec. on Ophth., A. M. A.*, p. 127, 1910) employs in ectropion and entropion, a short galvano-cautery point; and a modified chalazion clamp with a straight edge, as a guide for the row of punctures. The punctures are quickly made through the cartilage, 4 mm. from the lid margin and the same distance apart. Imre insists that the skin of the lid must be permanently stretched to effect a permanent cure in spastic entropion, and the less sacrifice of skin the better. The function of the orbicular muscle should not be disturbed.

Straub (*Klin. Monatsbl. f. Augenh.*, March, p. 334, 1910) argues that the cicatricial conjunctiva in trachomatous entropion, being

decidedly less in superficial extent than normal, can no longer cover the surface of the tarsus. This deficiency must be compensated by a decrease in the size of that structure, or displacement of the adjacent structures upon the tarsus, or both. The tarsus becomes shorter and thicker, but the greater portion of the deficiency is met by dragging the fornix to the tarsal surface, and bending back the free margin of the lid, resulting in entropion. Based upon these views, Straub *extirpates the tarsus*, with asserted satisfactory results as regards both the entropion itself and the other complications of trachoma, the cause of which he believes to be the resulting greater amplitude of lid movement facilitating drainage of the sac. He lays great stress upon the proper application of the sutures and ascribes some cases of failure in his own practice to their faulty placing. Morno deals with entropion of the lower lid by making a T-shaped incision, and displacing a vertical fold downward.

In Asmus's (*Ztschr. f. Augenh.*, XXII, p. 222, 1910) case of traumatic ptosis with ectropion the ligamentum internum of the upper lid was lacerated by a horn of a goat, which also inflicted such other injuries as caused complete ptosis with prolapse of the mucous membrane. The ptosis and ectropion were relieved by Kuhnt's ectropion operation and Pagenstecher's sutures. A third intervention consisted of raising the prolapse by means of sutures passed through the same and above the brow; the sutures were anchored to the forehead by adhesive plaster. Bourgeois (*Rec. d'opht.*, p. 146, 1910) finds that the method of Terson not only gives excellent results in ectropion, but that the cutaneous flap can also be utilized for a graft when desired. Kuhnt observes that the following conditions are to be remedied in extreme blepharitis ectropion: First, the rotation of the lid outwards; second, the false position of the lashes; third, the atrophy of the orbicularis, and finally cure of the lagophthalmos so often present. To meet these indications he has devised an operation which consists first, in splitting the lower lid into 2 flaps, an anterior or skin flap and a posterior or tarso-mucous membrane flap; and, second, in the complete sliding of one over the other in the sense that the former is lifted and the latter depressed.

Since the entropion in trachoma is due to the curling up of all the tissues of the lid, from cicatricial retraction of the conjunctiva and tarsal cartilage, it is clear that any treatment which does not directly attack the causal element must be illogical and inefficacious. The essentials of the operative procedure proposed by Marin (*Archiv. de Oftalmologia*, Feb., 1912) are section of the conjunctiva and tarsal cartilage, excision of a cutaneo-muscular flap, and displacement of the

ciliary border. The first incision is made through the skin and orbicularis muscle from the punctum to the external commissure, at three millimeters from the ciliary border. The second incision is semilunar in shape, with its concavity upwards, and its ends joining those of the first incision. A flap is thus formed varying from four to six millimeters in width at the center, according to the effect which is desired. The skin and muscle included between these two incisions are completely removed. Next an incision is made on the inner aspect of the lid, passing through the entire length and thickness of the conjunctiva and tarsal cartilage at a distance of two millimeters from the posterior lip of the ciliary border. The final step is the passing of three or four sutures from the ciliary border behind the implantation of the lashes, to the inferior lip of the cutaneous wound; and the sutures are so tied as to displace the upper portion of the lid in greater or less degree, according to the correction which is desired.

E. Bonino (*Annali di Ottalm.*, 40, p. 28, 1913) proposes a combined operation intended to avoid a recurrence of trichiasis through contracture along the intermarginal line. The three principal incisions are, first, along the intermarginal line; next 3 or 4 millimeters above and parallel with this on the skin surface, and again, parallel with, and 2 or 3 millimeters higher than, the second. The ends of these are joined by vertical incisions, the upper flap is dissected free except at each end, and some fibers of the orbicularis and a wedge-shaped piece of the tarsus are resected. The upper flap being held out of the way with a strabismus hook, the edge of the flap containing the cilia is sutured to the upper margin of the corresponding wound in both skin and tarsus. The loose upper flap is then drawn down and sewn into position along the intermarginal incision.

From a study of spastic entropion Dimmer (*Klin. Monatsbl. f. Augenh.*, Sept., p. 337, 1911) concludes that in consequence of relaxed application of the skin of the lower lid to the underlying tissue, especially marked in subjects of advanced years, as also in consequence of greater mobility of the orbicularis over the tarsus, the skin of the lower lid accompanied by other well known favoring factors is thrown, through the action of the palpebral muscle (but not the marginal portion of the orbicularis) into a fold over the commissure and eventually also over the lateral commissure. This fold persists, in consequence of senile changes of the skin (diminished elasticity) also during opening of the commissure and thus causes malposition of the lid margin with inversion of the lashes and occasionally also of the tarsus itself.

For ingrowing lashes Wray (*Trans. Ophth. Soc. United Kingdom,*

XXXII, p. 161, 1912) uses the Wadsworth thermo-cautery. This has a metal bulb with a rather long, sharp point. He uses it at a dull red heat. The object is to make a strand of cicatricial tissue that will restore the normal appearance of the lid. The way the point is thrust into the tissue varies according to the effects desired. For the maximum effect the point is somewhat moved to make a fan-shaped scar, with its base in the cartilage and its apex 2½ mm. above the free margin of the lid.

Eleutheriades (*Ann. of Ophth.*, XXI, p. 356, 1912) has devised an operation for cases of entropion and trichiasis not amenable to the usual methods of treatment. He terms it *tarsoleptinsis*, signifying thinning of the tarsus. Two incisions are made, one horizontal 3 mm. above the free margin of the tarsus extending from the external commissure to the lachrymal punctum; and a second curved with the concavity downward 3 to 4 mm. above the first. These incisions meet at each extremity, thus enclosing a musculo-cutaneous elliptical flap to be dissected up. Some layers of the tarsus are next removed with a straight knife slightly curved (thinning the same). He attaches the inferior margin of the flap to the tarsus by a deep suture and with another brings together the edges of the musculo-cutaneous wound.

The treatment of senile ectropion by the excision of a longtitudinal strip of the conjunctiva and tarsus, while frequently affording excellent results, has the distinct disadvantage that it shortens the conjunctival sac. Kugel (Graefe's *Arch. f. Ophth.*, Vol. 84, p. 79, 1913) has therefore adopted the plan of shelling out the tarsal plate without sacrificing any conjunctival tissue. After injecting 2 per cent. cocain solution and instilling 4 per cent. cocain solution in the conjunctival sac, the lid is grasped in a Desmarres speculum, and an incision made through the whole length of the conjunctiva. The conjunctiva is dissected from the tarsus, and this again from the structures toward the skin. The tarsal plate is then cut away at its margins with scissors. If after removal of the speculum the lid sags away from the eyeball at any point, this is commonly because a fragment of the tarsus has been left; but if some sagging persists, even after any such remains have been disposed of, the lid will be found to adapt itself accurately in the course of a few days. The conjunctival incision is closed with three or four mattress sutures. The operation was done in twenty-five cases, and the only unsatisfactory result was in a case of conjunctival contraction resulting from trachoma, this class of cases being unsuited to the operation. The results obtained in cases of senile ectropion, whether of mild or extreme degree, are strikingly uniform.

Villard (*Ann. d'Ocul.*, Vol. 149, p. 321, 1913) gives a detailed

description of the procedure for senile ectropion suggested by Terson in 1896, which the first-named writer feels has hardly received the attention it deserves. He reports seven cases in which good results were obtained from the operation, the essential features of which are resection of a strip of the everted conjunctiva, and the removal of a triangle of skin external to the outer canthus, the base of the triangle being toward the eye.

The paper by Espinouze (*Rev. Gen. d'Opht.*, Vol. 32, p. 289, 1913) revives the operation proposed by Truc in 1897 for the same condition, and reports four cases in which it was done. Truc's method consisted of splitting the lid between the tarsus and the muscle, and advancing the external layer "en vanne" (like a sluice gate) beyond the internal layer, the two layers being sutured together in their new relationship.

For ectropion of the lower lid secondary to trachoma, MacCallan (*Ophthalmoscope*, Vol. 11, p. 538, 1913) makes a horizontal incision through the conjunctiva, 5 or 6 mm. from the lid margin, dissects out and removes the tarsal plate, and then unites the edges of the conjunctival incision by through-and-through sutures from the skin surface, at 5 mm. from the lid margin.

Goodenow (*Ophthalmology*, Vol. 9, p. 334, 1913) reports and illustrates a case of total cicatricial ectropion of the upper eyelid which was cured by means of a Wolfe graft from the skin of the arm.

Maggi (*Ann. di Ottalm.*, Vol. 42, p. 128, 1913) tabulates the technic and the results obtained in 111 cases of entropion and trichiasis treated by marginaplasty with mucous graft. In some cases the mucous graft was obtained from the mouth, and in some from the vagina. It was found that the vaginal mucosa was more prone to desquamation, and contracted more, than that from the mouth. From a study of the various operative combinations employed, and their results, the following choice of procedure is advised: If entropion is pronounced and there is moderate trichiasis, Snellen's tarsectomy may be used. If a second operation proves necessary it should consist of splitting the lid margin and grafting. For marked incurving of the tarsus and pronounced trichiasis, splitting of the lid margin should be combined with Snellen's tarsectomy and a mucous graft. For slight entropion and trichiasis, the intermarginal incision and mucous graft are sufficient. The incision and graft should also be used for trichiasis alone, or with entropion but with a soft, degenerated tarsus.

Samperi's (*Arch. di Ottalm*, Vol. 21, p. 169, 1913) article consists mainly of a review of the various operative procedures in the light of over eighty operations done in Tripoli for trichiasis and entropion. As regards trichiasis consequent on trachoma, he condemns as useless

all methods which attack the skin without including the tarsus, since in trachoma it is principally the tarsus which contracts.

The method proposed by Baslini (*Clin. Ocul.*, Vol. 12, p. 1176, 1913) for the correction of cicatricial entropion of the lower lid is a modification of that of Panas. The first incision is made through the skin and orbicularis muscle and extends the whole length of the lid, parallel with and at about 10 mm. from the ciliary margin. Two vertical incisions reach from the ends of the first to within 2 mm. of the lid margin. An intermarginal incision, 2 mm. deep, is made between the orbicularis muscle and the tarsal plate. The skin and muscle flap is dissected free from below for about a half its height. The flap is then displaced downward, and by a suture at each lateral margin is fixed in such position that the cilia are brought 2 mm. from the lid margin. A 2 mm. strip is excised from the lower border of the skin flap, transported to the raw space at the margin of the lid and fixed there by a few very fine sutures. Sutures are finally placed along the lines of the three original incisions. Two out of three of the author's cases date back six years, and the results are still perfect.

Entropion aigu. (F.) Entropion of the eyelid produced by an acute spasm of the orbicular muscle.

Entropion bulbale. (L.) Entropion of the eyelid in which the contracting process involves the tarsal and ocular conjunctiva and also the retrotarsal fold. In this case the entire lid may be inverted.

Entropion der Greise. (G.) Senile entropion.

Entropionize. To turn inward.

Entropion musculare. (L.) (Obs.) Entropion of the eyelid occurring in consequence of some irritation which affects the conjunctiva or cornea, or of some disease of the eyeball causing pain and reflex contraction of the orbicular muscle. It usually occurs in the lower lids and in advanced years.

Entropion organicum. (L.) Entropion of the eyelid caused by contraction of the lid following diphtheritic or gonorrheal conjunctivitis or a cicatricial formation.

Entropion senile. (L.) Entropion of the eyelid mainly due to old age.

Entropion, Superciliary. Incurvation of the hairs of the eyebrow into the palpebral fissure and against the conjunctiva, causing the same symptoms as are present in ordinary entropion.

Entropion tarsale. (L.) Entropion of the lid, in which the contracting or cicatricial process is mainly confined to the tarsus which is curved in upon itself; usually the result of long-continued granular conjunctivitis.

Entropion uveæ. This condition, opposed to *ectropion uveæ,* is one in which the pigment epithelium has been retracted outwards and backwards from the pupil. It can, of course, only be diagnosed post-mortem, and when it has occurred it has probably been acquired. Enslin (*Archiv f. Augenheilk.*, 51, 1905) has described a case.

Entropium. See **Entropion.**

Entscheidung. (G.) Crisis.

Entwickelung. (G.) Development; evolution.

Entwickelungsfehler. (G.) A defect of development.

Entwickelungsgang. (G.) The process of development.

Entwickelungsgeschichte. (G.) Embryology.

Entwickelungsgesetz. (G.) A law of development.

Entwickelungslehre. (G.) The doctrine of evolution.

Entwickelungsstörung. (G.) Derangement of development.

Entziehung. (G.) Withdrawal; deprivation; abstraction.

Entziehungsdiät. (G.) A restricted diet.

Entzündung. (G.) Inflammation.

Entzündung des Augenliderwinkels. (G.) Blepharitis intermarginalis.

Entzündungserreger. (G.) An exciting cause of inflammation.

Entzündungsfell. (G.) Buffy coat.

Entzündungsheerd. (G.) An inflammatory focus.

Entzündungsvorgang. (G.) An inflammatory process.

Entzündungszeitraum. (G.) A stage of inflammation.

Enucleation of the eye and its substitutes. Evisceration. Exenteration. Abscission. Mules' operation. Optico-ciliary neurotomy. Extirpation of the eye. Excision of the globe.

To avoid unnecessary repetition it has been thought wise to discuss, describe and illustrate under this heading not only the ordinary forms of bulbar enucleation but substitutes for them. As a matter of fact a statement of the reasons for choosing one of the latter in individual instances involves a discussion of the whole subject. The reader will, consequently, regard this introductory matter as a prelude to each form of eyeball excision—complete or incomplete—described and pictured under this caption.

The removal of an eyeball is a serious major operation and should be undertaken only when the surgeon is sincerely convinced of its necessity and wisdom. It should never be forgotten that the exsection of an eye not only destroys much of an individual's visual prospects, but produces a deformed and repulsive physical condition mortifying to the patient and distressing to his friends.

While eyes are frequently lost from non-traumatic causes, it never-

theless happens that the necessity for eyeball removals often follows in the wake of an accident, and inasmuch as most serious traumas occur to laborers, it transpires that a large proportion of such operations are performed upon this class of people. Almost all corporations at the present time either employ surgeons to care for their injured employees, or are protected by some form of accident insurance. It, therefore, usually happens that men with injured eyes are cared for promptly by a company surgeon, who endeavors to place the eye in the most favorable condition to be saved. This is done not only in the interests of the patient, who should be given every opportunity for ocular salvation, but also to protect the company from personal-injury litigation, as law suits or threats of law suits are extremely liable to follow all forms of bodily accidents. The laudable desire (under these circumstances) to save eyesight or at least a sightless eye, sometimes leads the surgeon into the error of endeavoring to rescue an eye that is manifestly lost at the beginning. It is difficult for the surgeon to forget that the amount of his company's legal responsibility may be based on the amount of manifest injury the patient has received, and that some portions of an eyeball saved will appear better to a jury than if a complete enucleation has been performed. Let it not be understood that the writer deprecates any reasonable effort toward ocular salvation, for this is not the case; he merely wishes to remind the surgeon that some eyes are primarily so badly damaged that any effort at their preservation is worse than useless; and, therefore, such a course is bad practice and is sometimes followed by the loss of the other eye from sympathetic ophthalmia. Instances of this nature are very liable to occur when steel fragments have been driven into the eye and have been removed by a magnet.

What eyeballs shall we remove? As a rule it is not wise to undertake the preservation of an eye into which a very large piece of steel has been driven and the ocular laceration is excessive. The magnet may remove the steel, but no useful result has then been accomplished, as almost invariably either speedy panophthalmitis develops or a protracted uveitis ensues, followed by a shrunken, painful, deformed, sightless and dangerous eye that will be, or at least should be, removed in order to afford the patient comfort and safety. Meanwhile much time has been lost and considerable useless expense incurred, and after perhaps weeks of effort the eye is then removed, a procedure which, perhaps, should have been accomplished immediately after the accident. A manifestly destroyed eye should be removed at once, disregarding all professional pride in the attempt to save the globe and all desires to placate the feelings of the patient or his friends. The patient

much more readily consents to an eyeball removal immediately after the accident than when some weeks have transpired and he still has an eye which, though shrunken, sightless, irritable and dangerous, is yet one from which he can hardly be persuaded to part. The surgeon, on the other hand, after weeks or months of effort, hesitates to acknowledge defeat by advising an eyeball enucleation and thus the patient perhaps remains possessed of an apologetic eyeball, which is a constant care and menace, and from which he should have been separated at the beginning. There can be no doubt that while the magnet has accomplished much good, and has preserved many useful eyes, it has increased the number of cases of sympathetic ophthalmia by encouraging the efforts at eyeball preservation in unsuitable cases. For this the magnet is in no way to blame, however, as the fault lies with the surgeon whose optimistic tendencies persuade him to undertake the accomplishment of an apparently unfeasible proposition.

The usefulness of an eye is confined to two considerations, viz., vision and beauty, and when, through accident or disease, both of these attributes are lost, and in addition an element of danger is added, the eye should be removed.

The best judgment of well-ripened experience is sometimes taxed in advising a course of action subsequent to an ocular trauma and it should be remembered, notwithstanding what has just been said, that many good eyes and considerable useful vision not infrequently follow the wise and conservative care of such cases. Scleral ruptures are not as unfortunate as severe injuries in the anterior portion of the eye, and a globe in which a pure scleral injury has occurred should be conservatively watched before enucleation is advised. It is frequently difficult to judge as to the advisability of eyeball removals and a decision should be reached by experience, judgment, the probability of primary infection and the extent and location of the injury, it being remembered that traumas in the ciliary region are more dangerous than those inflicted in other regions, although this statement has been called in question by several recent writers.

It sometimes becomes necessary to remove eyeballs for conditions that are practically non-traumatic in their origin, such as in the various infections, in tumors, staphyloma, hydrophthalmos, glaucoma, atrophied and irritable globes, corneal ulcerations and their sequelæ, iritis, panophthalmitis, sympathetic ophthalmia, operative infections, etc. It must not be understood that all of these conditions invariably require some form of eyeball removal, but each of these diseases may become so intense and aggravated in character as to demand the execution of some variety of this surgical procedure. Some of these conditions,

such as operative infections, traumatic panophthalmitis and corneal ulcerations (if produced from some accident such as a foreign body lodging in the cornea, etc.) should, strictly speaking, be classified as injuries.

It may be said in a general way that all eyeballs permanently bereft of vision, that are persistently inflamed, painful and irritable, should be removed. Concerning tumors, it may be said that almost all cases of intra-ocular tumors call for eyeball removal, remembering, however, that syphilitic growths can usually be dissipated by proper treatment. Orbital tumors generally demand eyeball enucleation, unless they can be removed from the side of the eye, or by some such operation as that recommended by Krönlein.

It may, then, be said, as a summary of this part of the subject, that the following conditions usually call for some form of eyeball removal.

1. Severe injuries (especially involving the ciliary region) where good judgment dictates the operation.
2. Unremovable, intraocular foreign bodies.
3. Suppurative panophthalmitis.
4. Blind eyes producing sympathetic irritation, or sympathetic ophthalmia in any stage.
5. Eyes (still retaining vision) that are beginning to produce sympathetic ophthalmia or marked sympathetic irritation. It should be remembered that where pathological processes have been transmitted before enucleation has been performed, the operation is powerless to prevent sympathetic ophthalmia. If sympathetic ophthalmia does not occur within four or five weeks after enucleation, it is unlikely to occur at all.
6. Eyes possessing intra- or extraocular malignant, tubercular or syphilitic growths that cannot be completely removed either by treatment or by operation.
7. Persistently painful or irritable stumps left after eyeball removals, where a complete enucleation has not been performed; also shrunken eyeballs that are painful and irritable.
8. Suppurating sockets intractable to other treatment.
9. All blind, persistently sensitive and irritable eyeballs.
10. Total corneal or extensive bulbar staphyloma.
11. Buphthalmos and hydrophthalmos.
12. Blind, deformed eyeballs.
13. Painful, absolute glaucoma not relieved by other procedures.
14. Profuse, painful, intractable intraocular hemorrhage. This usually proceeds either from an accident or from an operation.

15. Blind or nearly blind eyes with a dislocated lens or detached retina, where inflammation, pain and visual defects unite to make life burdensome.

16. Cranial inflammations caused by fractured orbital roofs, where the seat of trouble cannot be reached, and where life may be at stake.

It is generally conceded that little, if any, benefit results from the enucleation of a primarily diseased or injured eye after a plastic iridochoroiditis has developed in the second eye, although many surgeons believe that sympathetic ophthalmia runs a milder course and is less likely to recur if the exciting eye has been removed. Indeed, if any vision remain in the primarily affected eye, it is wiser to retain this eye, since prognosis as to eventual sight is better in it than in the secondarily affected eye. It should not be forgotten that the surest preventive against sympathetic ophthalmia is the prompt removal of really dangerous eyes, especially if vision and beauty have already been destroyed.

Enucleation and panophthalmitis. The question of the removal of an eye by enucleation during an attack of panophthalmitis is as yet unsettled. Some observers are opposed to such a procedure, while others believe it justifiable, unless the infection and swelling are most excessive. However, the writer has enucleated many eyes in the presence of various grades of panophthalmitis and has never had cause to regret it. It is a significant fact that out of 10,734 cases of simple enucleation collected from the reports of the Oph. Soc. U. K. (*Trans. Oph. Soc. of U. K.,* 1898, p. 239) there occurred only 7 cases of fatal meningitis. All of these 7 cases were instances of suppurative panophthalmitis, but it cannot be proven that the enucleation caused all the deaths; they might have occurred without operative interference, as instanced by a case reported by Webster in the *Transactions of the Medical Society of the State of New York* for 1888. Becker claimed in 1888 that only 43 cases of meningitis after enucleation had ever been placed on record. There can be no doubt that while meningitis, thrombo-phlebitis and orbital abscess may follow the enucleation of a panophthalmitic eye, the risk is exceedingly small and that many operators of large experience have never seen such a case. The writings and statistics of Andrews (*New York Medical Journal,* Dec. 29, 1888, Vol. 48, p. 701), Pooley (*Annals of Ophthal.,* 1897, p. 243), H. Knapp (Norris and Oliver, *Sys. of Dis. Eye,* Vol. 3, p. 887), Becker (*Die Universitätsaugenklinik zu Heidelberg,* 1888), Noyes (*Trans. Amer. Ophthal. Soc.,* 1888 and 1889, p. 314), Brudenell Carter, McHardy, Gunn, Panas, Dufour, Motais, Gayet and others are strong arguments in favor of the practical safety of this procedure.

The cutting of the optic nerve, however, during an enucleation which is accompanied by panophthalmitis surely opens up a pathway of infection from the eye to the brain, a surgical fact which no one can afford to ignore, and numerous instances can be found in opththalmic literature testifying to the occurrence of fatal meningitis after enucleation performed in the presence of panophthalmitis. Such instances may be found in the writings of Graefe (*Trans. Internat. Oph. Congress,* 1900), Nettleship (*Trans. Oph. Soc. of U. K.,* 1886, p. 445), Coppez, Panas (*Arch. d'Ophtal.,* Vol. 18, No. 9, 1898), Hobby (*Amer. Jour. of Ophthal.,* 1886, p. 141), Delibes (*La Clinique Ophtal.,* July 25, 1898), Risley (*Jour. Amer. Med. Assn.,* Oct. 21, 1893, p. 298), Siffre (*Annales d'Oculist,* April, 1892, p. 249), Enslin (*Arch. f. Augenheil.,* Sept., 1904), Kuwahara (*Arch. f. Augenheil.,* Sept., 1904), Higgins, Mules, Lapersonne, Meyer, Galezowski, Abadie, and others. Nettleship (*Trans. Oph. Soc. of U. K.,* 1886, Vol. 6, p. 445) and others have recorded cases of thrombosis of the cavernous sinus following enucleations. Nor is meningitis the only serious consequence that may follow enucleation during panophthalmitis, for, contrary to the belief entertained by some surgeons that sympathetic inflammation of the opposite eye does not follow panophthalmitis in the other, Ahlstrom, Schirmer (Graefe-Saemisch *Handbuch*, 1900, 23-25) and Würdemann have reported cases where this unfortunate termination has occurred. These cases seem to contradict the theory of Leber and Deutschmann (Graefe's *Arch. f. Ophthal.;* also *Arch. f. Ophthal.,* 1885, Vol. 4, p. 251) that the panophthalmitic inflammation plugs up the lymph passages and prevents germ migration, also the theory of Gifford (*Jour. Amer. Med. Assn.,* Feb. 10, 1900; also *Arch. of Ophthal.,* Vol. 15, No. 3, 1886) that the infiltration of pus corpuscles in the optic nerve lymph spaces prevents bacterial invasion of the sound eye.

When the extreme rarity (only one case in 1,596 cases at Moorfields (*Trans. Oph. Soc. of U. K.,* 1898, p. 243) of the occurrence of sympathetic ophthalmia after enucleation is considered, as compared with other forms of eyeball removal, the question may well be raised as to whether, all things considered, enucleation is not the safest operation. In most cases of both meningitis and sympathetic ophthalmia, following any form of eyeball removal, it is difficult to establish the fact of connection. The causative factor may have passed beyond the eyeball and into the connecting tract before the operation was performed, in which case the disease will occur after the operation, which will frequently be erroneously accused of precipitating the disaster. In the event of sympathetic ophthalmia occurring after an

eyeball removal, for instance, it is quite well conceded that it is only when the disease appears within from about three to four weeks after the operation that the latter should be accused of producing the sympathetic ophthalmia, and even then the guilty connection may be difficult to establish. As is well established, sympathetic ophthalmia rarely occurs in the first month after an injury, very rarely in the second and third month, most frequently in the fourth and fifth months, and then more and more rarely during the succeeding months and years of life.

It is a statement which is justified by a careful inspection of recorded cases, that a vast majority of instances of meningitis and sympathetic ophthalmia, following any form of eyeball removal, have happened in cases where there could have been a well-grounded suspicion that these diseases would have occurred if no operation whatever had been performed. It would be difficult indeed to establish the fact that any particular method of eyeball removal is especially prone to produce either meningitis or sympathetic ophthalmia, and it would be equally difficult to prove that any method is conspicuously exempt from disastrous consequences. Each operation has its friends and its foes, its advantages and disadvantages, and while some form of enucleation is performed more than any other method of operation, yet many other procedures have their places in ophthalmic surgery, and the wisest surgeon is he who can and does utilize the various operations under circumstances best adapted for their use.

Evisceration versus enucleation. Practically all the eyeball removal operations that have been devised since the Ferrall or Bonnet method have originated in a desire to lessen deformity, and avoid meningitis or sympathetic ophthalmia. It was largely, for instance, the fear of severing the optic nerve during an attack of panophthalmitis and opening an infective communication with the brain that induced the operation of evisceration. Coupled with this idea was the conviction that inasmuch as the sclera and muscles were left intact, a large, movable stump would result and that therefore a prominent, mobile, artificial eye would materially mitigate the deformity. It is still felt by many observers that evisceration is safer than enucleation in panophthalmitis, but only a few surgeons hold to the belief that it affords a better or more mobile stump than is obtained after a well-executed enucleation, especially where muscular power is retained by some method of suturing the muscles together. While the stump after evisceration is primarily movable and prominent, these qualities are ultimately largely lost, owing to the inevitable scleral atrophy and retraction of the ocular tissues into the posterior portion of the socket.

Comparative measurements of rotation as between enucleation and evisceration as compiled by Hotz, True and de Schweinitz (*Internat. Congress,* 1900), demonstrate the truth of this statement. Besides this, notwithstanding the statements of such observers as Gifford (*Trans. St. Louis Ophthal. Soc.*, 1906), Henderson (*Trans. St. Louis Ophthal. Soc.* 1906) and others, who feel that inasmuch as the optic and ciliary nerves are not cut the danger of sympathetic ophthalmia is lessened, there is an impression in ophthalmological circles that sympathetic ophthalmia is more apt to follow evisceration than enucleation. See a discussion of this important subject under **Sympathetic ophthalmia.**

Sympathetic ophthalmia after evisceration. When it occurs this deplorable result is due to failure to cleanse thoroughly the interior of the sclera of all uveal tissue. Schieck (*Bericht der Ophthal. Gesell.*, Vol. 5, 1908, p. 355), Hotz (*Internat. Oph. Congress*, 1900), Schmidt-Rimpler and others have reported instances of this kind. Such uveal shreds contain structures liable to produce sympathetic ophthalmia, and should be absolutely removed, and as this is difficult of attainment (as well as for other reasons) the operation has rather fallen into disfavor. It is a simpler operation than enucleation, especially when there is great infection, swelling and adhesion of the orbital tissues; but if great care is taken to eviscerate completely the ocular contents, and then to cauterize the scleral lining with carbolic acid, it would seem that it should be a reasonably safe and reliable procedure.

Nevertheless, de Schweinitz narrates (*Internat. Oph. Congress*, 1900) an interesting case in which he carefully eviscerated an eye, taking great pains to clean the interior of the scleral cup. He afterwards enucleated the same eye on account of a painful stump. A microscopical examination revealed uveal tissue that he had not removed. Waldispühl (*Correspondenzblätt, für Schweizer Aertze.*, Vol. 16, 1896, p. 3) records a similar case. This shows how impossible it is for even a careful and skillful operator to be sure of the thorough removal of all dangerous material. The first reports after Graefe's endorsement of evisceration were exceedingly flattering, for according to Bunge (*Mittheil, aus der Universitätsaugenklinik zu Halle*, 1887) in 1887, no case of death or sympathetic ophthalmia followed Graefe's first 240 cases. Shortly after this Schuleck lost two patients out of 36 eviscerations and since then enough unfortunate cases have been reported to cause many surgeons to fear this operation. H. Knapp practised evisceration until 1883, when he encoun-

tered a severe case of orbital cellulitis and thrombosis which caused him to practically abandon the operation.

The anesthetic to be employed in excision of the eyeball. In any form of operation for the removal of an eyeball it is best to employ a general anesthetic if possible. See **Anesthesia in ophthalmic surgery,** page 420, Vol. I of this *Encyclopedia.*

Local anesthesia may be used if the patient's physical condition is such as to render it inadvisable to administer a general anesthetic, or if he is radically opposed to ether, chloroform, etc., and is willing to be brave if a local anesthetic is used. Children are not suitable subjects for local anesthesia. Bruns (*New Orleans Med. and Surg. Jour.,* Dec., 1909) in 1909 reported that in his clinic at New Orleans local anesthesia was used altogether, except in cases of young children, or in excitable and timorous persons. In case local anesthesia is employed, any suitable drug may be used, such as cocaine, stovaine, holocaine, novocaine, the Schleich method, etc.

Cocaine was first used for enucleation by Cocks in 1884 and was afterwards recommended by A. D. Williams in 1886; by Tossiwill, Bankart, Roper and Lightfoot in 1888; by J. A. Campbell in 1889; by Jackson, Armaignac and Dunn in 1892, by Chavez in 1896, Terrien in 1906; Ellis, Langworthy and Siegrist in 1907 and others during later years.

Subconjunctival anesthesia in enucleation of the eyeball. Terrien begins his operations by producing conjunctival anesthesia and then using a sub-conjunctival injection of 1 cgm. of morphia. He then uses cocaine locally and hypodermically and proceeds to operate. When he is about to cut the optic nerve, he injects into the tissues surrounding the nerve 1 cc. of the following formula:

Hydrochlorate of cocaine	
Hydrochlorate of morphia, of each,	.01
Stovaine,	
Sodium chloride, of each	.02
Distilled water	5.00

He highly recommends this method, and says that hyperemic cases are the most painful and that in such cases holocaine acts the best.

Siegrist commences with a mixture of cocaine and adrenalin, and then injects underneath the conjunctiva and over the four recti muscles 0.75 gr. of a 2 per cent. solution of novocaine, to which some adrenalin has been added. By waiting two or three minutes after these injections he claims that a painless operation may be performed. He says that novocaine is less dangerous than cocaine and that he

injected in one case 3.0 gm. of novocaine without producing any untoward symptoms.

Weiss (*Die Ophthal. Klinik.*, June 20, 1898, p. 214) strongly urged the Schleich infiltration anesthesia for eyeball enucleations. He says that cutting of the optic nerve did not even give rise to the usual sensations of light generally observed in removing an eyeball without general anesthesia. The infiltration is made by injecting half a hypodermic syringeful of the Schleich solution beneath the conjunctiva, over the four recti muscles, and also by making deep injections near the optic nerve. For the last injection he uses Schleich's long curved needle. Edema, of course, follows which soon subsides after the operation.

Robin (*New Orleans Med. and Surg. Jour.*, December, 1907), warmly recommended a mixture of cocaine and adrenalin, and injected it deeply along each rectus muscle, using "10 drops of a mixture containing 10 drops of a 4 per cent. solution of cocaine, 10 drops of adrenalin chlorid (1/1000), and 20 drops of normal salt solution, of which 10 drops are injected about the optic nerve before severing. Total amount of cocaine injected is from ⅖ to ½ grain."

Where local anesthesia is considered advisable, the method usually prescribed is the following: A 4 per cent. solution of cocaine should first be freely dropped upon the eyeball. After local anesthesia is produced, a 1 per cent. solution of cocaine is subconjunctivally injected over the insertion of each rectus muscle, after which the circumcorneal incision and the undermining of the conjunctiva can be painlessly accomplished. The muscle tendons should then be anesthetized by injecting a few drops of a 1 per cent. solution into the capsule of Tenon, just above each tendon, directing the stream along the plane of the muscle and close to the sclera, after which the tendons can be severed from their scleral attachments. A few drops of cocaine should now be injected into the tissues directly around the optic nerve and in a few minutes the nerve can be cut without much pain.

Should it be determined to remove an eyeball, several different methods may be employed, viz., enucleation; evisceration; abscission; the insertion of an artificial vitreous within the sclera; the insertion of an artificial ball within the capsule of Tenon; the insertion of an artificial ball within the muscles and conjunctiva; and optico-ciliary neurotomy or neurectomy.

ENUCLEATION.

So far as can be ascertained the first scientific attempt at the extirpation, or enucleation, of an eyeball was made by Lange in 1555, who,

however, failed to leave a record as to his method of procedure, although he reported his experience. About the first recorded method of enucleation, or "extirpation" as it was called, was described in 1583 by George Bartisch (*Ophthalmodouleia oder Augendienst*, 1583), of Königsbrück, in Saxony. Until about 1850 eyes were extirpated practically only in such cases as cancers, tumors, fungus hematodes, etc., and the method was rarely employed under any circumstances. Bartisch passed a strong needle and thread through the eyeball and then while making traction on the thread and eyeball, passed behind the eye a sharp knife, or spoon, and scooped and cut away the globe from all its attachments. Before permanently adopting the spoon

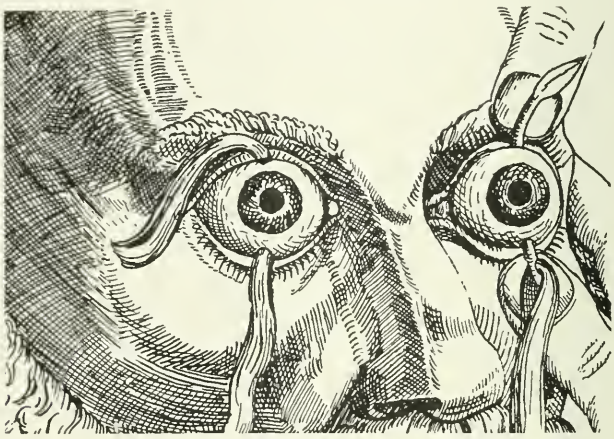

The Extirpation Method of Bartisch.

knife, however, he first experimented with a small razor-shaped knife with which he severed the eye from its orbital attachments. The operation was so dreadful that Guthrie, in his work on the eye published in 1823, mentions the fact that Bartolini endeavored to mitigate its severity by pulling out a cancerous eye by hooks, a mild procedure, followed in three days by the death of the patient in convulsions.

Some of Bartisch's followers, including Fabrici de Hilden (*Observation. Chirurg.*, 1646), who wrote on the subject in 1646, used a double-edged knife, instead of a spoon, after the conjunctiva had been separated from the bulb by what is known as a circumcorneal incision. This method was used without many variations for years until Louis proposed, according to Rowley (*Diseases of the Eye*) in 1790, as a substitute for the knife, the use of flat, blunt, curved scissors and hooked forceps.

Mackenzie, in his work published in 1830, tells of a woman who had to undergo an eyeball extirpation on account of a large orbital tumor. She was bled until she was unconscious and the eyeball cut away before she recovered.

Bickerton (*Medical Times and Gazette*, May 1, 8 and 15, 1897) says, "The severity of the operation is best shown by the rareness with which it was performed." He quotes Bowman, who says that at the Royal Ophthalmic Hospital from 1839 to 1848, although 1,419 operations were performed, only four extirpations were made. During this period 2,302 cases of injury were seen, 24 cases of "fungus of the globe" and 16 cases of tumors of the orbit. Bickerton further says that: "Up to the year 1850, then, the only operations in vogue for the relief of injured and painful blind eyes were: (a) Simple incision of globe; (b) 'Sinking of the globe,' *i. e.*, a flap of the cornea was cut away by curved scissors, a dose of laudanum administered, and a linseed meal poultice applied to the eyelids, in order to evacuate the contents of the globe. (White-Cooper, *Wounds and Injuries of the Eye*, 1859, page 57.)

"(c) 'Abscission,' *i. e.*, the removal by knife, scissors, or guillotine of a staphylomatous cornea, with suturing of the corneal margins.

"(d) Slicing off painful fungous growths, with application of nitrate of silver to the stump, a proceeding adopted in the cases of soldiers, where gunshot wounds had led to the sprouting of fungous growths from the interior of the globe, and attended with pain described as 'driving the sufferer to desperation.' (White-Cooper, *loco cit.*)

"What the proportion of sympathetic inflammation, directly consequent upon the above methods of operation—apart from the original injuries—was, it is impossible to adequately estimate!"

On account of the brutal nature of the extirpation operation it was, as has been seen, but little used for years, when Ferrall (*Dublin Jour. Med. Science*, Vol. 19, 1841, p. 335) in 1841, Bonnet (*Ann. D'Oculist.*, Vol. 5, 1841, p. 27; and Vol. 7, 1842, p. 39) in 1841 and Stoeber (Norris and Oliver's *System of Diseases of the Eye*, Vol. 3, p. 883) in 1842, proposed and executed the operation for enucleation, which has always gone under the name of Bonnet's operation, although it should properly be called Ferrall's. Even now it is used by probably a majority of surgeons, who still take advantage of much of the surgical technic proposed by Geo. Critchett (*Lancet*, Vol. II, page 386, 1851) and by White-Cooper (*Wounds and Injuries of the Eye*, 1859) in 1856.

When the eyeball seemed unusually large, either from natural or unnatural causes, the earlier operators were accustomed to slit the

external canthus until the globe could be easily delivered, an expedient which is now but rarely used.

Ferrall stumbled across his operation rather accidentally, for, having a case of enormous orbital tumor in which the globe was entirely pushed out of the socket, he merely cut the ocular muscles, optic nerve, etc., and delivered the eyeball, and being much pleased with the results, reported his experience as above noted. This article was entitled "On the Anatomy of Certain Structures in the Orbit Not Previously Described," and contained a recommendation of the operation in these words:

"The comparative safety of an operation limited by this fibrous tunic (referring to the capsule of Tenon) is obvious but an additional

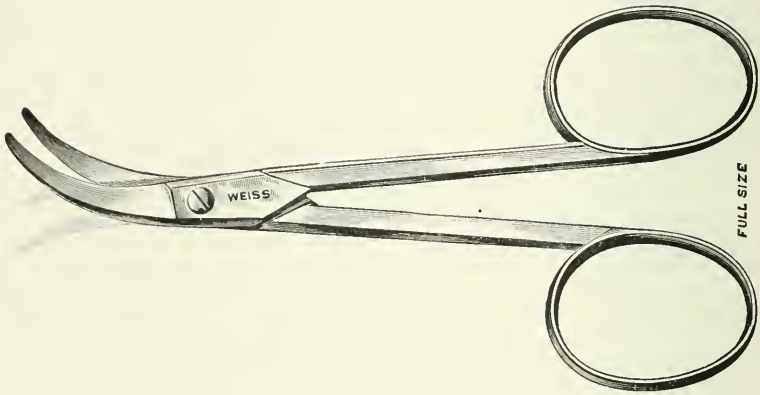

Landolt's Enucleation and Exenteration Scissors.

recommendation will be the facility of its performance. The conjunctiva being freely divided, the six tendons may be snipped across with scissors, one after another, where they emerge from the tunic. The eyeball will then be easily detached by a probe or director passed freely around it; when one step alone would remain, the division of the optic nerve."

The method was not much used, however, for some time, as the old operation of extirpation which was at about this time made less horrible by the discovery of chloroform had secured a firm hold on the profession, although in Skey's *Surgery* of 1850 (p. 623), it was said that "the use of chloroform in almost all operations on the eye is inadmissible from its well-known effects on the globe."

In narrating the early history of this operation, the work of Augustin Pritchard, of Bristol, should not be forgotten, for he, in 1850, was the first surgeon in England to extirpate an eyeball for a

non-malignant condition. He enlarged the outer commissure and scooped out the contents of the socket with a knife and scissors. He became firmly impressed with the idea of sympathetic ocular disease and advised, in the *Provincial Medical and Surgical Journal* for 1851, page 66, and for 1854, page 909, the removal of the irritating eye.

Extirpation or enucleation was, until about the year 1855, used almost exclusively in cases of malignant growths, a deep incision of the globe being used in almost all other cases where surgeons to-day advise enucleation.

In 1855 Geo. Critchett read a paper before the Hunterian Society, which was reported in the *Lancet* for 1855, in which he advocated enucleation in staphyloma, intraocular foreign bodies, symblepharon, inflamed and painful blind eyes and inflamed eyes where sympathetic ophthalmia seemed probable. This address widened the scope of this operation and placed it upon the broad foundation where it at present stands.

Choice of method in eyeball excisions. In removing all or any portion of an eyeball the method of operating is one to be carefully considered and decided by the surgeon. Every patient has a right to be deformed as little as possible by such a procedure, and to have provided for him the best and most movable stump, consistent with safety and the pathological condition present in his case. The importance of this statement, of course, varies with the age, sex, business and social position of the patient. For instance, personal appearance is of less importance in the aged and the mature laboring man than in young people or among the so-called higher classes. It is of more significance in women than in men. As every one rebels against deformity each case should accordingly be given the benefits of the best advice. And, yet, probably a majority of the eyes that are removed have been enucleated by the old-fashioned Ferrall or Bonnet method in which no effort is made to unite the muscles, conjunctiva, etc., in order to produce a prominent and movable stump upon which an artificial shell may rest and move. This method commends itself to many surgeons because it is easy and rapid, but it leaves the patient with a great, empty cup-shaped socket, which affords no support to the lids or to an artificial eye. The lids sink into the concavity when the shell is not in position, and even when it is, there is much depression, and, owing to the fact that no prominent and movable stump is present, the artificial eye stares into space, with death-like immobility. This appearance is alike mortifying to the patient and discreditable to the surgeon, and in a vast majority of cases is entirely unnecessary, as better methods of operating may generally be used, producing such

beautiful results as almost, if not quite, to abolish all disagreeable personal appearance. Of course, the old Ferrall, or Bonnet, operation is still necessary where complete exenteration of the socket for tumors, etc., is indicated, where expeditious operating is imperative, and, probably, where extensive orbital infection has occurred and free drainage is desirable, but in the majority of cases, this mutilating and deforming operation is entirely unnecessary and should be relegated to obscurity, that it may make way for better, more modern and more humane surgical procedures.

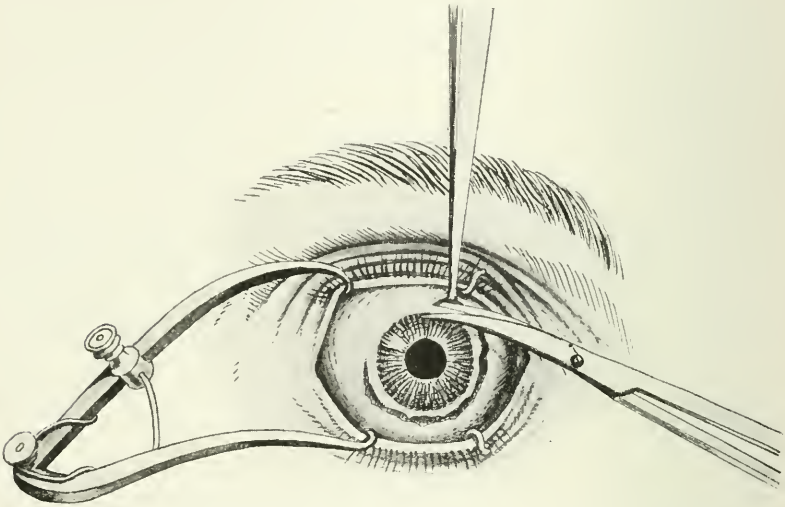

The Ferrall or Bonnet Enucleation. The speculum has been inserted and the circumcorneal incision is being made.

Preparation of the patient and surgeon for enucleation. In the operative descriptions given in this section it is assumed that all patients are properly prepared for operation by a thorough cleansing of the face, eye-brows and eye-lashes by thoroughly scrubbing the parts with soap and water; the eyeball should also be abundantly douched with sterile water and some antiseptic solution. This should be done before the patient is brought to the operating room, after which a sterile pad and bandage should be applied. The same cleansing process should be repeated after the anesthetic has been administered and just before the operation is begun. A gauze mask in which a large hole has been cut to accommodate the affected eye should be placed over the face. The operator should wear thin, well-fitting rubber gloves. A strong speculum should be inserted between the lids,

widely expanded and locked, although some surgeons prefer the use of a pair of Desmarres' retractors held by an assistant, feeling that the lids can be better and more effectually controlled by these instruments than by a speculum. These preliminaries should be accomplished in all eyeball removals, and it will not be necessary to repeat the directions each time the different procedures are described. It should also be assumed, to prevent recapitulation, that after all operations the operative area is cleansed thoroughly, that some antiseptic solution or ointment is applied, that a pad and bandage are adjusted, that the parts are inspected, cleansed and treated each day and that all sutures,

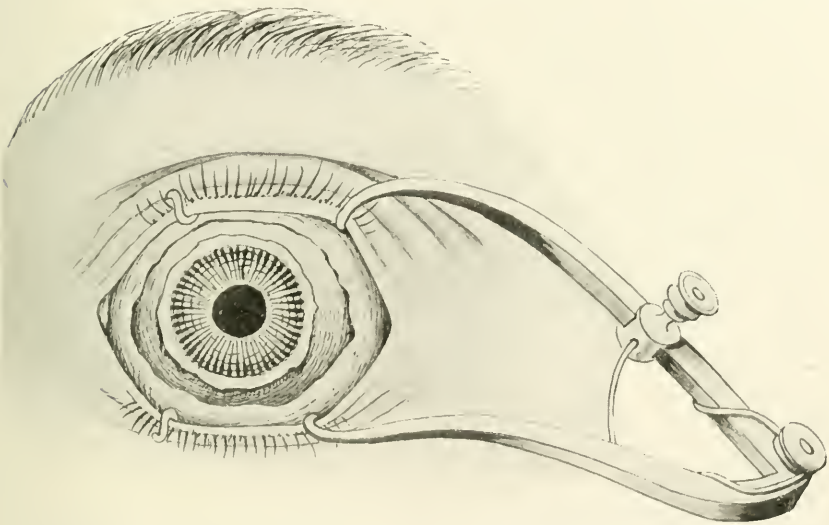

The Ferrall Enucleation Operation. The circumcorneal incision has been completed.

except those of catgut, are carefully removed within a proper period of time. For general purposes, such as conjunctival and tendon cutting, the writer does not use the small, curved, tenotomy scissors employed by most surgeons, but prefers long, curved scissors of medium weight and rounded points, as they are more convenient to handle and do not stick into the tissues. He also uses long, heavy, curved scissors for cutting the optic nerve.

The Ferrall or Bonnet operation. After the speculum has been inserted, expanded and locked, the conjunctiva should be grasped with the forceps near the sclero-corneal junction, and an opening made with the scissors. This incision should be continued all the way around the cornea, completing what is known as the "circumcorneal incision," thus freely exposing the sclera and affording easy access to the recti mus-

cles. The conjunctiva is now seized by the forceps in various places and lifted up to facilitate its thorough separation from the globe by scissors. This may be difficult of accomplishment if the tissues have become matted together by adhesive inflammation, or torn by injuries, but can be accomplished by careful and painstaking effort. The point of the scissors should be directed towards the eyeball. This position of the cutting parts minimizes the danger of hemorrhage, as the cellular and orbital tissues are very vascular, bleed easily and are readily infected. Care should be taken not to cut the sclera, as this accident is not uncommon, especially in partially collapsed globes, and greatly complicates the succeeding steps of the operation. The four recti muscles should now be separated from the eyeball and it is better to commence with the superior rectus, as the tendency is for the eye to roll upwards during anesthesia. When this muscle is cut such tendency is greatly minimized and the other tenotomies are more readily accomplished. In doing a tenotomy the overlying conjunctiva should

Brazil's Enucleation Knife.

be raised with the forceps and a strabismus hook forced underneath the tendon; the latter is then pulled forward and severed from its sclerotic attachment as close to its insertion as possible, taking great pains not to injure Tenon's capsule, as this membrane should always be conserved, if possible, to protect the soft orbital tissues and to improve the appearance and usefulness of the stump.

Some operators make use of a special knife (like the Brazil instrument pictured in the text) for severing the tendinous and other bulbar tissues.

After all the tendons have been tenotomized, the speculum should be forced into the socket, which will cause the eyeball (no longer held in position by muscles, conjunctiva, etc.), to come forward and be delivered from its orbital bed; after which the speculum may be removed or not, according to the desire of the operator. Practically the globe is now held in place only by the optic nerve.

The Terson or DeWeltz enucleation spoon should at this stage of the operation be passed into the socket, between the eyeball and the posterior walls of the socket, and the optic nerve induced to slip into the slot of the spoon. Inasmuch as the optic nerve converges from the eyeball toward the nasal side of the socket, on its way to the optic

foramen to join the optic nerve of the other eye, the nerve can be more easily found if the spoon is introduced beneath the eyeball from the nasal side, and it is usually best to insert it from this side. It can, however, be passed in from the temporal side, and it may sometimes be best to do this in case of a very large eyeball, where the space

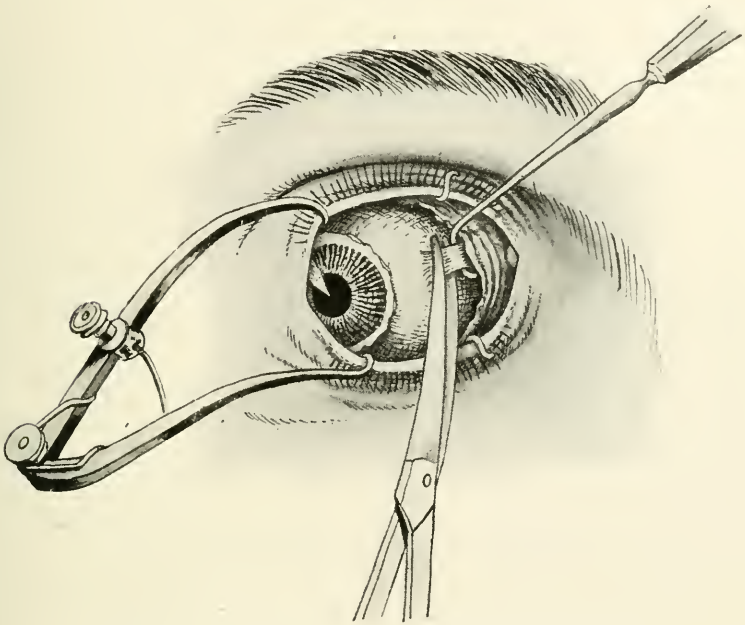

The Ferrall Enucleation. The cutting of the tendons.

between the globe and inner wall of the socket is much contracted. Some operators do not use the spoon, but lift the globe with fingers or forceps and pass the scissors underneath and sever the nerve. This may be facilitated by extreme rotation of the eyeball to one side in

Optic Nerve Hook for Use in Enucleation of the Eye (Luer).

order to bring the nerve as near to the surface as possible, when it can be more easily reached and cut. Some operators sever the nerve without dislocating the globe forward.

Geo. Suker (*Ophthal. Record*, Jan., 1902) recommends an enucleation forceps, shaped something like obstetric forceps, which can be

introduced into the socket, back of the eyeball, one blade at a time, and then locked. When the eyeball is detached, it can be withdrawn with the forceps.

Henry Joseph proposed (*Arch. d'Ophthal.*, Nov., 1904, p. 715) what he calls a "hook neurotome," something like a tonsil guillotine, which he claims can be placed around the nerve with great exactness and by means of which the nerve can be cut nearly as far back as the optic foramen.

If the spoon is used, it can be utilized to lift the eye from its orbital bed as far as possible and the strong, blunt, curved scissors should

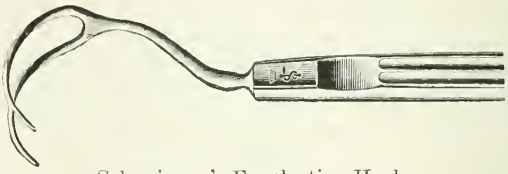

Schweigger's Enucleation Hook.

de Wecker's Enucleation Spoon.

Terson's Enucleation Spoon.

then be passed under the spoon and a search made for the optic nerve by means of the closed scissors blades. It will be felt as a strong, tense cord, especially if the spoon lifts the eyeball upwards, thus placing the nerve on a stiff tension. When found, the blades of the scissors should be opened and made to engage the nerve, which is then completely severed as far back in the socket as possible. This is especially important when there is fear of sympathetic ophthalmia; for if this disease travels along the optic nerve tissue by any form of cell-migration, the farther back the nerve is cut, the greater is the probability of getting beyond the area of pathological invasion.

While any strong, blunt, curved scissors will answer the purpose of cutting the optic nerve, those of Terson, suggested in 1905, are especially to be commended. The inner blade of these scissors is quite thick, so that when the nerve is cut the blade forces the eyeball for-

ward, which insures the division of the nerve farther back than can be done by other scissors. The hemostatic scissors of Warlomont may, also, be used for the same purpose.

The blades of the scissors should be opened just wide enough to engage the nerve; if too much expanded more or less orbital tissue, blood vessels, etc., will be cut, unwise mutilation will result and the bleeding will be needlessly profuse.

When it is desirable to remove a large section of the optic nerve, Knapp has suggested that before severing the nerve a pair of curved catch-forceps be introduced behind the eye and the nerve securely grasped. The nerve should then be cut between the forceps and the eye, the forceps left in position and the eye delivered. The nerve can then be drawn out and cut as far back as desired.

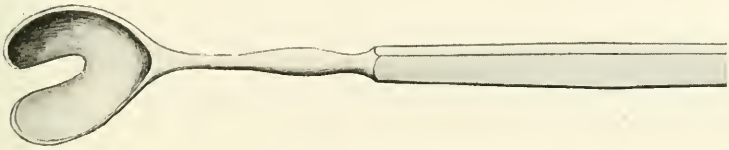

The de Weltz Enucleation Spoon.

After severing the nerve the eye should be lifted by fingers or forceps, and the oblique muscles and all connecting tissues cut away close to the globe, until the separation of the eye from the socket is complete. Care should be taken to avoid cutting into the orbital tissues as troublesome hemorrhage may follow. Do not cut through the sclera during any stage of the operation, and especially when the optic nerve is severed, an accident liable to occur during the removal of wrinkled or collapsed globes. In the event of such an accident, the opening should be sutured at once, and if a piece of the sclera is found adherent to the optic nerve after the eyeball is removed, the nerve should be picked up with forceps and divided as far back in the socket as possible.

In case of a very large eyeball, as for instance in buphthalmos, the optic nerve may frequently be better reached from the temporal side. Before the globe can be delivered, in such cases, it may be necessary to enlarge the conjunctival opening made by the circumcorneal incision, by slits into its edges, between the locations of the muscles, as suggested by Meyer, in order to produce a circular space sufficiently large to permit of the egress of the abnormally large eyeball. It may even be necessary to enlarge the palpebral aperture by slitting the external canthus, although this is very rarely necessary and should

only be done when imperatively demanded. When done, the incision should be sutured as soon as the eyeball is delivered.

Enucleation of collapsed globes. It sometimes becomes necessary to remove an eyeball that has been ruptured or lacerated and is therefore somewhat collapsed. These globes are difficult of removal, for, being more or less soft, they are hard to operate upon and present many obstacles to effecting a classical operation. In such cases a strong, curved needle armed with a strong, long, silk suture should be passed directly through both sides of the laceration and the opening securely closed. The suture should not be cut off but allowed to hang, as it serves an excellent purpose in affording a means by which the eyeball can be pulled from side to side, thus facilitating the subse-

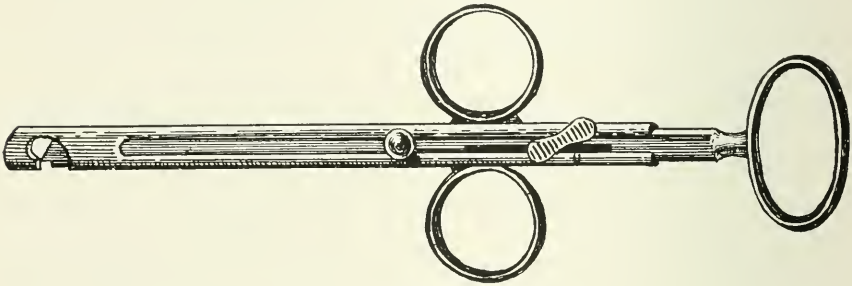

The Joseph Hook-Neurotome.

quent steps of the operation. If the eyeball is much collapsed it is advisable, before the suture is tightened into the knot, to inject it with sufficient water to force it into globular form, thus greatly aiding the surgical technique. Instead of filling the eyeball with fluid, the interior may be tightly packed with cotton gauze or wool retained by the long suture or sutures already described.

The laceration is sometimes so large that more than one suture is necessary to retain the intraocular contents, and this is also true when there is more than one laceration.

It is also advisable to use a suture where the coats of the eyeball are weakened by corneal ulceration, or by a recent operative incision as for cataract, etc. In such cases the globe is liable to rupture during enucleation, especially when the eyeball is forced from its socket, just before the nerve is cut, thus embarrassing the operator at a most inopportune time.

The idea of suturing the eyeball before enucleation was taken advantage of by Coppez (*La Clinique Ophthalm.*, 1888; abstracted in the *N. Y. Med. Record,* May 11, 1889), of Brussels, who in 1888 pro-

posed to operate upon all eyeballs in this manner. He passed a strong suture through the anterior portion of the eyeball, then knotted it and held the suture in his left hand. Traction upon the suture pulls the eyeball forward and from side to side, so that the conjunctiva, muscles, optic nerve, etc., are all cut by scissors without the use of forceps or hook. It is difficult to conceive why this method is superior to others, and it certainly possesses some disadvantages; for instance, it would destroy many valuable pathological specimens.

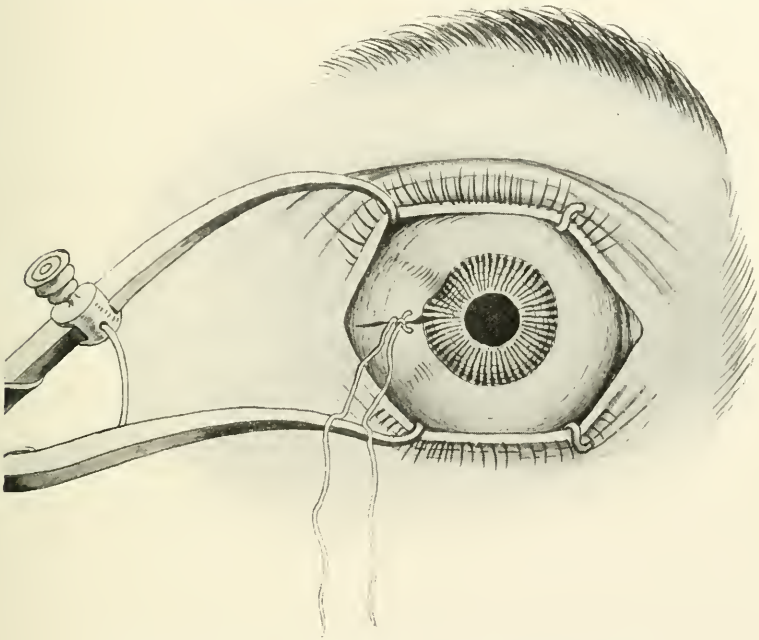

The Suturing of a Collapsing Globe During Enucleation.

After the eyeball has been enucleated it is advisable (especially where the globe has been injured by some projectile) to pass the finger into the socket and search for a foreign body, such as wood, metal, glass, etc., as sometimes such substances pass entirely through the eyeball and become deposited in the orbital tissues. Orbital tumors should also be searched for, and, if found, they should, of course, be removed. The presence of most foreign bodies in the eye or socket may be determined before operating, by the X-ray apparatus, and such skiagrams should always be insisted upon in cases involving any doubt.

Post-operative treatment of simple enucleation. After the operation the socket should be well irrigated with an antiseptic solution, and a

bandage applied. If the socket is infected it may be sprinkled with a little iodoform powder.

The socket should be dressed every day and kept thoroughly clean. Geo. R. Rohrer (Wood's *System of Ophthalmic Operations*, Vol. I, p. 562) no longer opens the lids, in non-infected eyes, at the dressings, but merely keeps the skin, lashes, etc., clean.

An artificial eye may be fitted in from two weeks to one month.

There is practically no danger from hemorrhage and it is not usually necessary to pack the cavity with gauze. Still, Robert Sattler (*Jour. Am. Med. Assn.*, Vol. 27, 1896, p. 1097) and others have had much trouble in this respect not only with "bleeders" but with non-bleeders, when almost fatal results have occurred. If troublesome hemorrhage should occur, adrenalized gauze may be packed into the cavity, or very hot water applied with cotton tampons forced into the socket. Carotid compression may be employed and even a carotid ligature may be necessary.

It should not be forgotten in this connection that cotton, sponge, etc., are easily grafted into the orbital tissue, and that if such substances are unfortunately left in the socket for even a day or two, they will very likely have to be actually cut out, a complication as embarrassing as unfortunate.

Suture of the wound margins after enucleation. Some surgeons complete the operation by bringing the conjunctiva together either with individual sutures, or a purse-string suture of catgut or silk. Others, as recommended by Bowman, search for the recti muscles and include them with the conjunctiva in the sutures, although it is difficult to find the muscles after they have been severed and allowed to retract into the socket. Würdemann made a pouch suture by weaving the needle and suture along the edge of the cut conjunctiva and Tenon's capsule. As he passes the recti tendons he picks each one up and includes it in the suture. Other operators recover the four recti muscles and suture them together with catgut and then tie the conjunctiva over the muscles with an interrupted or a purse-string suture. In the presence of orbital pus the conjunctiva and muscles should not be stitched together, as the entire cavity should be left freely open for drainage and for the prevention of deeper infection.

Allport's operation. The enucleation operation which the writer (*Medicine*, 1901) usually employs is the same as the Ferrall-Bonnet operation up to the step where the tendons are separated from the eyeball; at this juncture, instead of cutting off the tendons and allowing them to retract into the socket, the superior rectus is caught on a strabismus hook and pulled away from the eyeball. Another hook is

then passed beneath the muscle and while one hook pulls the muscle from the eyeball the other is passed backward and forward between the eyeball and muscle to free entirely the muscle from any fibers connecting the muscle and globe. The second strabismus hook is then withdrawn, leaving the first in place. One blade of a strong pair of Prince's advancement forceps is then placed between the tendon and sclera, taking the place of the remaining strabismus hook, which is

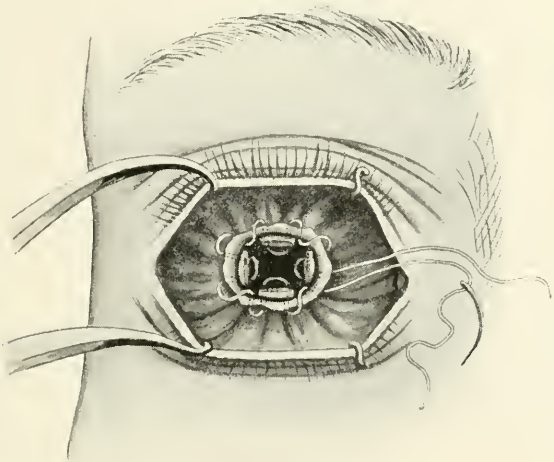

Enucleation of the Eyeball.
Würdemann's purse-string suture, including conjunctiva, capsule and tendons.

now withdrawn. The edge of the conjunctiva lying over the muscle is seized by a pair of forceps and pulled forward, together with the capsule of Tenon, and the outside blade of the Prince's forceps brought down upon them and locked. The bent ends of the forceps now contain the tendon, capsule of Tenon and overlying conjunctiva. The tendon is separated from the eyeball by scissors passed between the forceps and the sclera, being careful not to wound the latter structure.

A needle and catgut suture should now be passed by means of a needle-holder through the conjunctiva, capsule of Tenon and tendon from without inwards and then back again from within outwards. This quilts the entire mass together by means of a firm, solid stitch that will not pull out; after which the two ends of the suture are carefully laid aside so as not to interfere with the next step in the operation. The external rectus is then picked up, liberated, engaged in the Prince's forceps together with the conjunctiva and capsule of

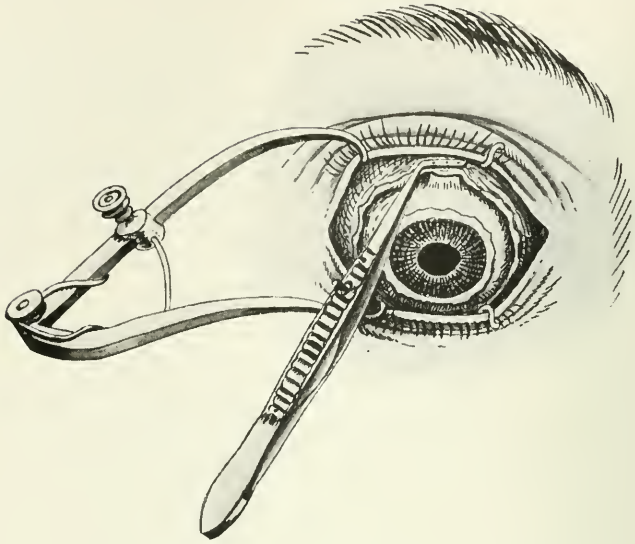

Enucleation of the Eyeball (Allport). The advancement forceps of Prince, holding within its grasp the conjunctiva, capsule of Tenon and the tendon on the superior rectus muscle.

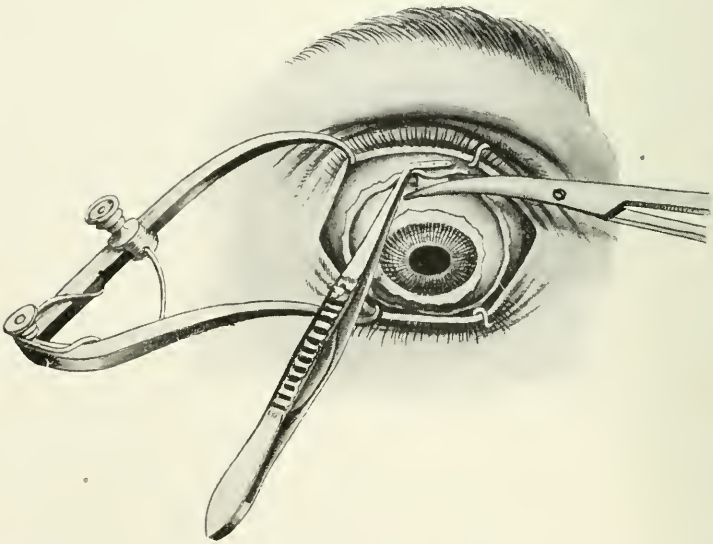

Enucleation of the Eyeball (Allport). The advancement forceps of Prince holds with its grasp the conjunctiva, capsule of Tenon and the tendon of the superior rectus muscle, while the tendon is being severed from the globe.

Tenon, cut away from the sclera, quilt-stitched with the same needle and suture, etc. The same steps are taken (in their order) with the

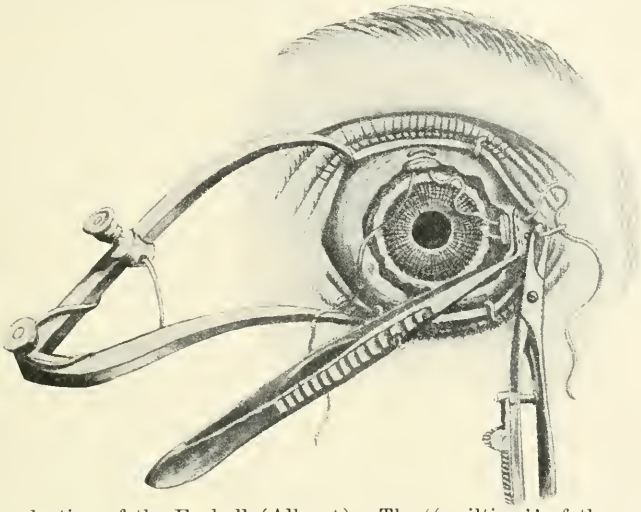

The Enucleation of the Eyeball (Allport). The "quilting" of the conjunctiva, capsule of Tenon and the tendons of the recti muscles.

The operator, of course, begins on any muscle he chooses and works around the eyeball in either direction. In the drawing, he begins with the superior rectus and proceeds to the internal rectus. Thence he passes to the inferior rectus and the external rectus.

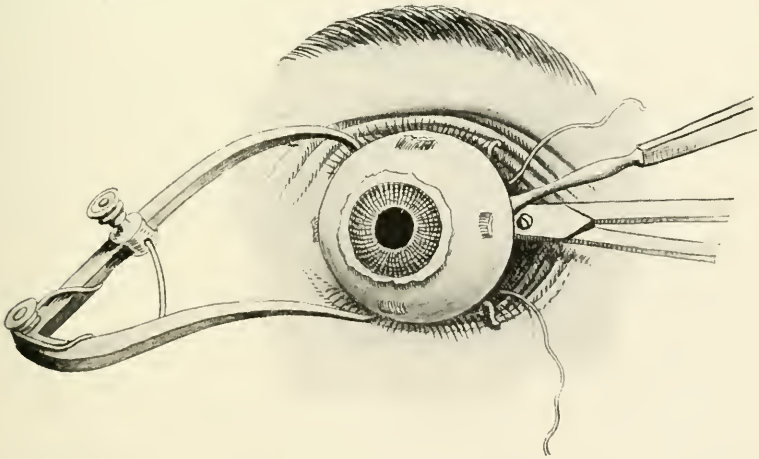

Enucleation of the Eyeball (Allport). The muscles have been severed and the eyeball forced from its socket. The two ends of the suture are laid aside and the slot of the enucleation spoon has engaged the optic nerve. The strong curved scissors are severing the optic nerve.

inferior and the internal rectus, after which the needle may be withdrawn from the suture. The purse-string suture and its two free ends

should be laid carefully aside to facilitate the subsequent steps of the operation which are exactly the same as in the Ferrall or Bonnet operation just described. The operation is completed by pulling the continuous suture containing the recti muscles, the capsule of Tenon and the conjunctiva together and tying the mass in a firm, hard knot. Great care should be exercised when the scissors are introduced to sever the optic nerve, that the suture is not cut in the process, an accident which is not at all impossible. If, however, this misfortune should occur the muscles should be painstakingly picked up and the continuous, purse-suture re-introduced as before.

The employment of this operation for fifteen years has proved its efficiency and usefulness. It forms a well-placed orbital wall which

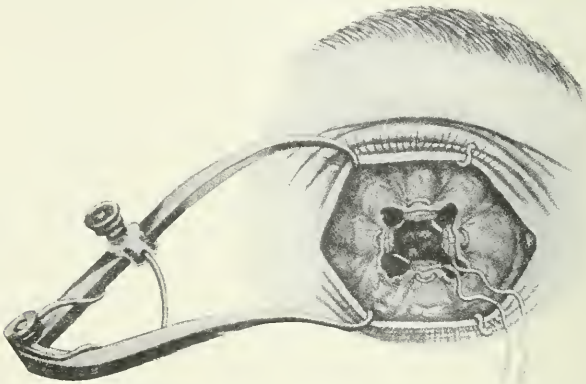

Enucleation of the Eyeball (Allport). The sutures now contain the conjunctiva, the capsule of Tenon and the four recti muscles, and are about to be tied.

prevents much sinking of the lids, and produces a freely-moving stump upon which an improved Snellen eye may rest and move in a manner that almost defies detection. The writer has had a wide experience of the Mules operation, but the cosmetic results of the procedure just described are so good that he now confines the Mules operation to selected cases, where the personal appearance of the patient is a matter of the very highest importance.

In 1879 and 1885 de Wecker (*Thérapeutique oculaire*, 1879, p. 512) suggested placing a purse-string suture through the conjunctiva, capsule and tendons, after the circum-corneal incision had been made, but before the tendons were severed. The globe was then enucleated and the suture firmly tied.

Snell (*British Med. Jour.*, Vol. 2, 1902, p. 1430) offered the plan that after the circum-corneal incision, one of the recti muscles be caught up on a strabismus hook and a suture be passed through it from side to side and tied. The suture is then passed through the

overlying conjunctiva. This end of the suture is cut long and the other short. The tendon is then severed and the other muscles similarly treated. After the eyeball is removed the lateral and, then, the

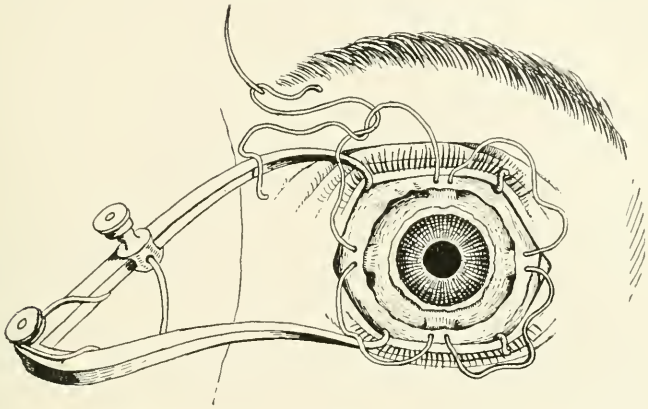

Enucleation of the Eyeball. de Wecker's purse string suture, inserted before the tendons are cut.

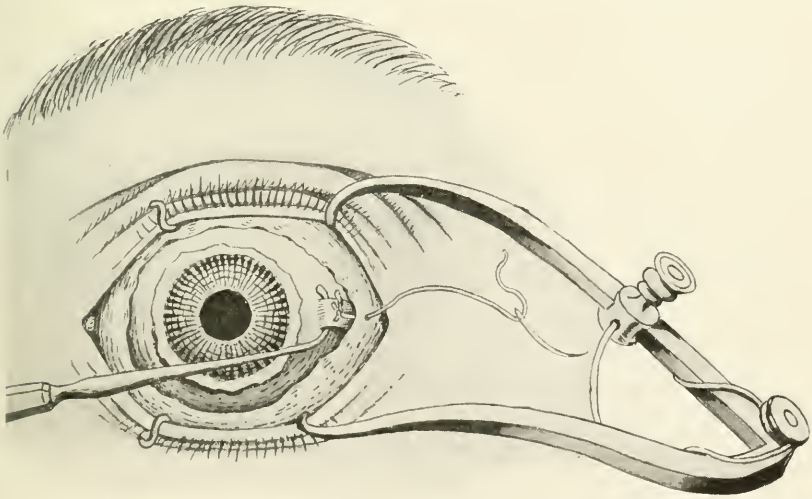

Enucleation of the Globe. The circum-corneal incision has been made, the external rectus tendon has been caught on the strabismus hook, the suture has been passed through the tendon, from side to side, and tied. One end of the suture has been cut off and the other end has been passed through the overlying conjunctiva. (Simeon Snell.)

vertical muscles are tied together with the long ends of the sutures. An additional suture in the conjunctiva, at each extremity of the wound, is usually necessary.

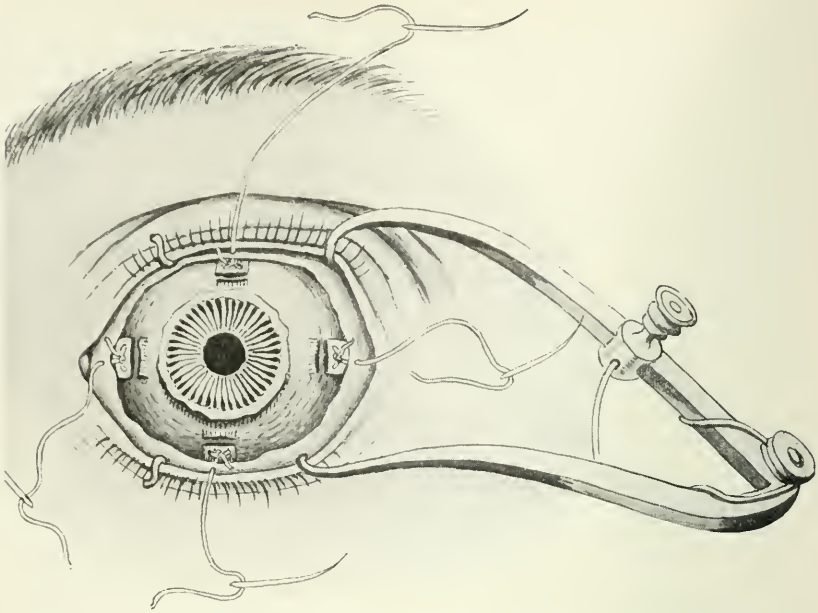

Enucleation of the Eyeball. All the muscles have been treated in the manner shown in the previous figure. (Simeon Snell.)

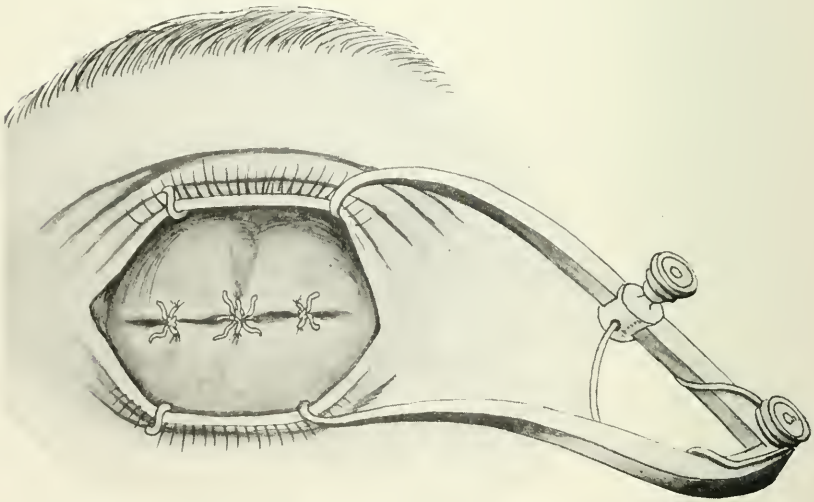

Enucleation. The sutures have all been tied together in the center, and an additional suture has been applied at each end of the wound to prevent gaping. (Simeon Snell.)

Ernest Clarke (*Lancet*, May 23, 1908), in 1902, suggested picking up the external rectus with a hook and clamping it with Prince's forceps. He then severs the tendon. The internal rectus is treated similarly. The superior and inferior recti are merely cut and not clamped. The eyeball is then removed. A catgut suture is now passed through the external rectus and the clamp removed. The same suture is passed through the capsule of Tenon and conjunctiva, and tied. The internal



Enucleation. Diagram showing the suture passed through the tendon. (Ernest Clarke.)

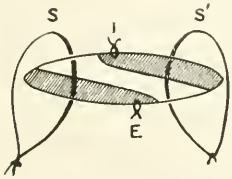

Enucleation of the Eyeball. Diagram showing the internal and external recti muscles sutured to the conjunctiva, and the entire mass brought together with other sutures. (Ernest Clarke.)

rectus is treated similarly. The upper and lower lips of the wound are brought together with silk sutures.

Suker (*Annals Ophthal. and Otol.*, Vol. 4, No. 4, 1895) suggested the following operation: "Prepare the field of operation as is your custom; divide the conjunctiva as close to the cornea as possible, dissect it as far back as permissible; do the same with the capsule of Tenon. Cut the recti muscles as close to their insertion as possible. Insert into each rectus a black silk suture at the time it is cut. This is to act as a guide. Proceed now as is customary, i. e., severing the nerve and oblique muscles. After removing the eye, take a thoroughly sterilized catgut suture and pass it through the severed end of the rectus externus and internus, which have previously been brought together by the silk suture guides.

"Now bring the superior and inferior recti down and pass a catgut suture through them. Finally, suture the four together and remove the silk guides. Thoroughly irrigate your cavity with sterilized water. At the last bring the conjunctiva from above and below over the muscle stump and suture same with a continuous suture, but be sure you fasten it to the muscle stump. Leave only a small part unsutured at either canthal end of the conjunctiva as a provisional drainage opening.

"You will, if everything acts properly, have union by first intention and the result will be an excellent prominent stump upon which an artificial eye will fit exceedingly well. This stump permits of much freer movement of the shell than any other, and then, too, it does

away, more or less, with the extreme sunken appearance of the socket after an enucleation. You are also apt to preserve a much better caruncle than is obtained by the other operations."

In 1895 Würdemann suggested an operation very similar to that of Suker.

H. Schmidt (*Klin. Mon. f. Augenheil.*, Nov., 1896, p. 383) suggested that each rectus tendon be secured by a catgut suture. He makes an opening in the overlying conjunctiva into which the divided tendon is fastened. The conjunctiva is then brought together with a continuous suture.

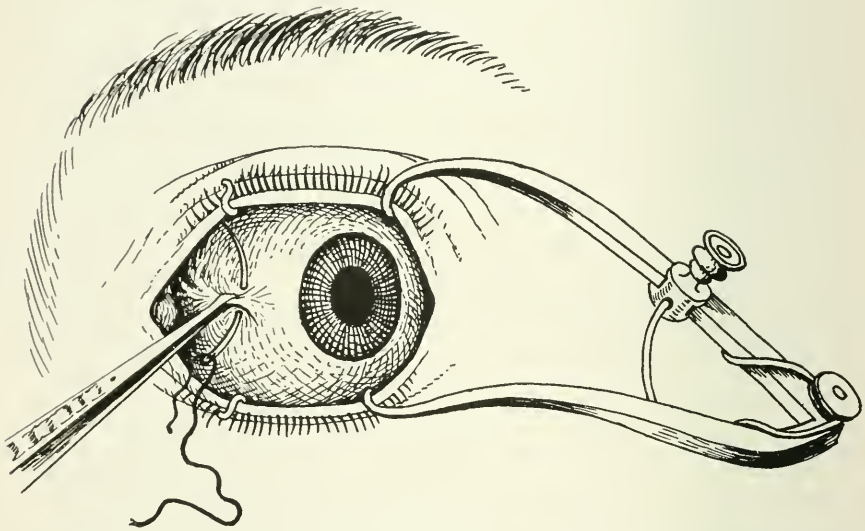

Enucleation of the Eyeball. (Priestley Smith.) The conjunctiva and internal rectus muscle are clamped by forceps, and transfixed by a needle and suture.

Priestley Smith (*Ophthal. Review*, May, 1899, p. 121) proposed the following operation: "The speculum having been introduced the globe is rotated strongly upward either with forceps, or more conveniently in some cases, by pressing the convexity of a strabismus hook deeply into the sulcus at the external canthus. A narrow horizontal fold of the conjunctiva over the internal rectus is then pinched up so as to include the subjacent connective tissue and muscle, and a black silk suture is carried through these structures by means of a curved needle. The suture is then tied firmly, but not too tightly.

"A second suture is applied in like manner to the external rectus. The upper and lower recti may be treated in the same way, but this

is of less importance. The enucleation is then carried out, and the conjunctival aperture may or may not be closed by one or more vertical sutures."

De Schweinitz (*Therapeutic Gazette*, April 15, 1900) suggested the following procedure: "After insertion of a speculum which widely separates the lids, the conjunctiva is divided as close as possible to the corneal margin; each rectus tendon is next exposed and caught upon a hook, as in the operation for strabismus, and is secured with a double-armed black silk suture, which is knotted upon it. The eyeball is now enucleated with the least possible disturbance of the relations between the conjunctiva and the underlying structures, and a small ball of sterilized gauze is inserted into the capsule of Tenon, in the manner in which a Mules' sphere would be placed in the operation of implantation. Each rectus tendon is now drawn forward to the edge of the cut conjunctiva and securely fastened with the ends of the same suture which had originally secured the tendon and which have been left long. That is to say, the tendon is brought forward precisely as it would be in the operation of advancement. The wad of sterilized gauze, which has served its purpose of checking entirely the hemorrhage and keeping for the time being the cavity bulged out as it was when occupied by the globe and therefore has facilitated the advancement of the tendons, is now removed, and the edges of the conjunctiva and capsule of Tenon are united with interrupted sutures."

Todd (*Ophthal. Record*, May, 1902) advised that—"After severing and dissecting up the ocular conjunctiva in the customary manner the superior rectus is picked up on a hook, a curved needle is passed from without inwards through the conjunctiva and tendon, and out again through the tendon and conjunctiva, thus forming a loop which includes the tendon and conjunctiva; the tendon is then severed near its scleral attachment. The internal rectus is now picked up with a hook and the same thread carried in the same manner through the conjunctiva and tendon, after which the tendon is severed. The same thread is carried on around in the same way through the inferior rectus and external rectus, and their tendons cut. The optic nerve is severed and the globe removed. The two ends of the thread are then tied, and the tendon and conjunctiva are thus brought together with a purse-string suture."

In 1903 Hansell and Sweet proposed that after the circum-corneal incision is made, the conjunctiva, capsule and each tendon should be singly sutured. Then the tendons are severed, the globe removed and the tissues pulled together with the sutures.

The Vienna method of enucleation. The method in vogue in Vienna and some other medical centers is as follows: The first part of the operation, including the circum-corneal incision, etc., is practically the same as already described; the only essential difference consists in the severing of the tendons, since no tendon hook is used. It is usual to begin the operation on the tendon of the internal rectus. The conjunctiva covering this muscle is elevated with one hand, while the other holds a strong pair of toothed forceps with which to grasp the tendon and draw it forward. To do this the closed forceps are care-

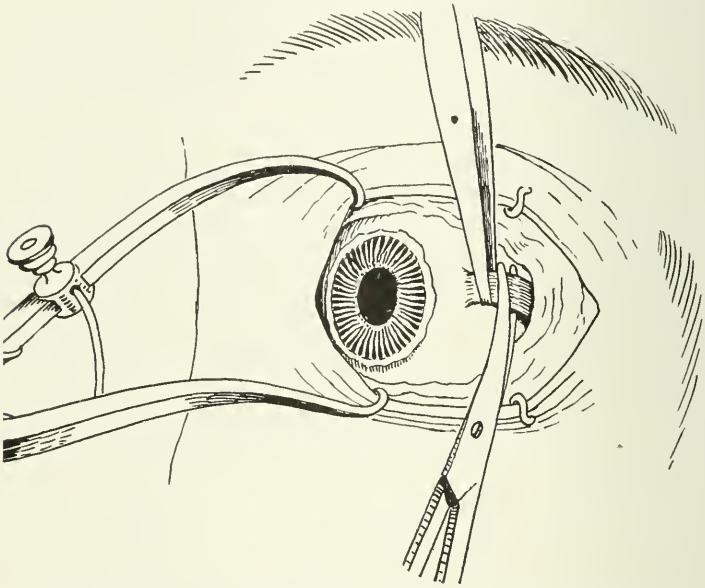

Enucleation. The Vienna method. The circum-corneal incision has been made and the muscle has been grasped by the forceps close to the eyeball. The scissors are cutting the muscle between the forceps and the belly of the muscle.

fully introduced through the opening in and beneath the conjunctiva, along the line of the internal rectus muscle, keeping the end of the forceps in contact with the eyeball. When the tendon is felt the forceps are opened and the tendon firmly grasped and pulled forward. The tendon is then severed by scissors, not between the forceps and eyeball, as is done in a tenotomy, but between the forceps and the internal canthus, to leave a piece of tendon attached to the eyeball sufficiently long that it can be grasped by forceps and be used as a sort of handle to move the eyeball in such various directions as are necessary to complete the subsequent steps of the operation. A blade

of the scissors is now pushed upwards toward the superior rectus muscle, keeping close to the sclera, the eyeball meanwhile being rotated downwards by the forceps acting on the internal rectus tendon. When the superior rectus muscle is found its tendon is cut close to the two blades of the scissors. The eyeball is now pulled towards the nose, while the external rectus is searched for and severed. The inferior rectus is not cut until the optic nerve is severed—the next step in the procedure. The eyeball is pulled toward the external canthus as far as possible by the forceps and internal rectus stump, a pair of strong,

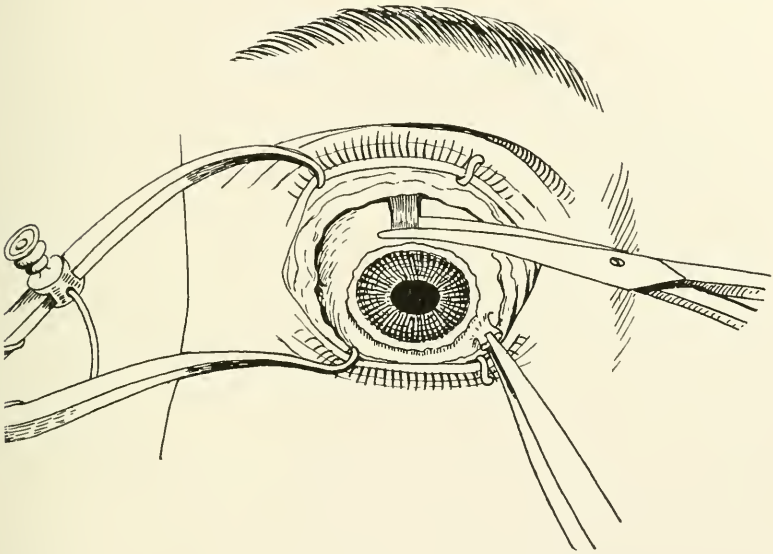

Enucleation. The Vienna method. The stump of the internal rectus muscle is held by the forceps, while the superior rectus is being cut with scissors.

curved, blunt scissors introduced behind the eyeball close to the sclera until the nerve is found, the blades are opened and the nerve severed. The eyeball is now pulled away from the socket by the forceps and internal rectus tendon, and the internal rectus and oblique muscles cut away as close to the sclera as possible. The subsequent procedures are not different from those already described under the Ferrall-Bonnet operation.

Arlt's method of enucleation (1859), described by H. Knapp (*System of Diseases of the Eye*, Vol. 3, p. 885) is as follows (he uses no strabismus hook): "He incises the conjunctiva from 2 to 3 millimeters behind the limbus corneæ, and pushes it somewhat back. Standing on the right of his patient, he, in the left eye, divides first the

external, in the right the internal, rectus, grasping it with toothed forceps, but leaves a small stump to get a firm hold of the globe with the forceps. After division of the inferior and superior recti, he pulls the eye with the forceps horizontally towards the inner (or outer) canthus, passes a pair of scissors over the posterior segment of the sclerotic, as far as the optic nerve, opens the branches, advances the scissors, so that the nerve lies between the branches, and cuts it close to the sclerotic. He now turns the protruding eyeball to the side of the uncut rectus, divides the insertions of the obliques, and the vessels and nerves, at the posterior half of the globe, and lastly detaches the insertion of the fourth rectus, together with the overlying conjunctiva, from the sclerotic."

H. Knapp's (*System of Diseases of the Eye*, Vol. 3, p. 885) own method of operating is practically the same as the Ferrall-Bonnet method, only he does not make the circum-corneal incision; he cuts the conjunctiva as he goes around the globe, at the same time he cuts the tendons, feeling that thereby he saves considerable conjunctival tissue. At the end he closes the conjunctival wound by a purse-string suture.

Tillaux, in 1872, proposed a modification of Ferrall's or Bonnet's method. He severed the external rectus and then drew the eyeball toward the nose and cut off the optic nerve. He then grasped the stump of the nerve attached to the eye, with forceps, and rotated it forward through the conjunctival wound. He then cut the other recti and the oblique muscles, and the capsule of Tenon, and delivered the globe.

Cunier endorsed the method of Tillaux, but he reversed the procedure and commenced with the internal instead of the external rectus.

Agnew's method of enucleation, as described by Beard (*Ophthalmic Surgery*, 1909, p. 459), is essentially as follows:

"After making the circum-corneal incision, and undermining the conjunctiva, the superior rectus is caught by a strabismus hook and cut. Before freeing the point, however, another hook is passed under the internal rectus tendon, thus keeping the globe fixed from time to time by the hooks instead of forceps, as muscle after muscle is severed. Enough of the external rectus is left attached to the globe to serve as a handle, to be held by the forceps, so that the eye may be pulled toward the nose, in order to bring the optic nerve and oblique muscles into prominence, to facilitate their severance by the scissors."

E. Meyer (*Révue Générale d'Ophtal.*, May 31, 1898, and *Bulletin et Mém. de la Soc. Franç. d'Ophtal.*, 1898, p. 185) emphasized the importance of preserving all possible ocular and orbital tissue. He

refrains from cutting either capsular or subconjunctival tissue, and when the tendons are severed he lifts them with a hook and carefully shaves them from their scleral attachment with a knife. He closes the conjunctival and capsular openings by vertically placed sutures in order to improve the lateral movements of the artificial eye.

Monosmith has recently devised a knife which he uses, instead of scissors, for enucleating eyeballs. The knife resembles a Weber canaliculus knife bent to an angle of 45 degrees. The point is thin and blunt to facilitate its passage beneath the muscles and conjunctiva. The knife is passed underneath the muscles which are severed without the use of either hook or scissors.

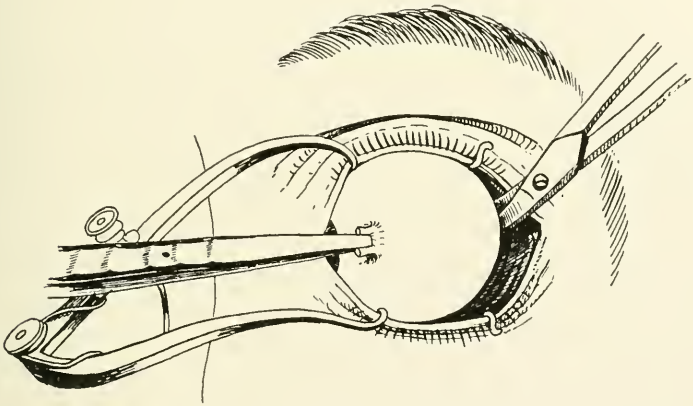

Enucleation of the Globe. Vienna method. The forceps, with its firm grasp of the internal rectus muscle, is strongly rotating the eyeball towards the external canthus, while the strong, curved scissors are severing the optic nerve.

De Wecker, in 1902, strongly opposed enucleation except in imperative cases, and tattoos the globe to imitate a natural appearance. To assist in restoring the size of the globe and of advancing its position, he divides the recti muscles which retract and constrict the eyeball. This procedure has also been recommended by Darier and Trousseau (*La Clinique Ophtal.*, Vol. XI).

It should not be forgotten, in this connection, that tattooing is sometimes followed by sympathetic ophthalmia, as was attested by Rava in 1872, Reuss in 1873, Panas in 1878, as well as by Lucas-Championniere, Girand-Teulon and others.

Buttons of granulation tissue occasionally appear in the socket, after enucleation. They can be easily snipped off.

Lamentable, but fortunately rare, instances have occurred where the wrong eye has been removed. This should not be forgotten, and great

care should always be exercised that this dreadful calamity does not befall both the patient and surgeon.

Self-enucleation of an eyeball is one of those horrible incidents only of scientific interest from the fact that it demonstrates the constant care that should be given to insane people. Noyes (*Ophthal. Record*, March, 1897) records such a case and other instances have been noted by Mackinlay, McHardy, Dearden and others.

Lundsgaard (*Klin. Monatsbl. f. Augenheilk.*, p. 131, 1909) reports the case of an insane woman, who within two minutes tore out the eyes of another insane woman. There were no witnesses to the occurrence, but there can scarcely be a doubt as to the verity of the incident.

ABSCISSION AND EVISCERATION (EXENTERATION) OF THE EYE.

The history and evolution of evisceration are so intimately connected with abscission that it is difficult to refer to the one without including the other.

Evisceration of the eye was performed (rather unintentionally) by James Beer (Graefe-Saemisch *Handbuch der ges. Augenheilk.*, Vol. 3, p. 376) in 1817 in a case of hemorrhagic glaucoma where severe choroidal hemorrhage occurred during an operation for iridectomy; by Butter in 1834; by Barton in 1837; by Noyes (1872) in panophthalmitis; and by Fröhlich in 1881. It was deliberately proposed by Graefe and Mules in 1884 to minimize the danger of meningitis, and is now sometimes employed as a substitute for enucleation. Early in the history of this operation Mulder, of Gröningen, seriously considered the advisability of this procedure, as a routine substitute for enucleation, and performed many experiments on cadavers and animals to demonstrate its practicability.

Wardrop (*Morbid Anatomy of the Human Eye*, 1834) notes that veterinarians observed that horses with one suppurating eye frequently become blind in the other eye, unless the first eye burst and sank into the orbit. They, therefore, conceived it to be good practice to burn out the first eye with lime, or to thrust a nail into it and destroy it. Wardrop improved upon this method by incising the cornea and forcing out the lens and vitreous humor. He suggested this procedure in human beings threatened with sympathetic disease of the other eye.

Mackenzie (*Treatise on Diseases of the Eye*, 1834) mentions a case reported by Dr. Butter, of a gun-shot wound of the eye where the lens and vitreous were removed to save the eye, but where the globe was subsequently enucleated and a duck-shot found near the optic nerve. Mackenzie again, in 1837, mentions the suggestion of Mr. Barton in the treatment of the retention of percussion caps within the

globe. He made a large corneal flap with a Beer's knife and then thrust the knife into the lens and vitreous to encourage their discharge, meanwhile hoping the cap would present itself. If it did not appear he cut the cornea away with scissors. A dose of laudanum was then given and a linseed poultice applied upon which usually the cap was deposited. Mackenzie recommended this practice in diseased eyes, where vision is lost and when the other eye appears to be in danger. These views were also entertained by Beer.

Abscission of the cornea was proposed by Saint Ives, Guerin and Heister in the 18th century, later by Critchett (1863), and was partially described by Wilde in 1847. Critchett made a semicircular-corneal incision with a Beer's knife and completed the amputation with scissors. The iris and lens were removed, but everything else was allowed to remain. Before incising the cornea, he inserted a few sutures back of the sclero-corneal junction through the ciliary region, and these sutures were tied after the cornea was abscised, leaving the vitreous humor within the scleral walls. Some cases did well and a fine stump was produced, but as the sutures passed through the ciliary region, cases of sympathetic ophthalmia occurred in the practice of Carter and others, which brought the operation into disfavor.

Critchett (*Royal Lond. Oph. Hosp. Reports*, Vol. 4, 1863, p. 1) also operated by passing three curved needles, armed with sutures, through the sclera above and below the cornea, a little back of the area to be removed. The needles were left in position until an elliptical segment of the eyeball was cut out with knife and scissors. The segment included the cornea, iris, lens and some sclera. The needles hindered the escape of vitreous. After the amputation had occurred, the needles were drawn through and the wound was closed by tying the sutures. See the illustration, page 37, Vol. I, of this *Encyclopedia*.

Lagrange (Grimsdale and Brewerton, *Ophthalmic Operations*, p. 174) modified the operation by making, first, the regular sclero-corneal incision and exposing the recti muscles, each one of which was secured with a suture before being severed. A purse-string suture was then passed around the conjunctival opening. Amputation of the anterior portion of the globe followed, after which the superior and inferior recti muscles were tied together and then the internal and external recti muscles. The purse-string suture was then tied and the operation completed. See the figures on pages 38, 39, Vol. I, of this *Encyclopedia*.

Chevallereau (*Bull. et Mém. de la Soc. Franç. d'Ophtal.*, Vol. 22, 1905, p. 225) operated by completely incising the cornea transversely. Iris forceps were then introduced into the opening and the iris com-

pletely removed. The capsule of the lens was then opened by a cystotome, the lens evacuated and a pressure bandage applied.

Knapp (*Archiv f. Ophthalmologie*, XIV, 1. p. 275) modified Critchett's plans by inserting the sutures into the conjunctiva (after abscission), from which delicate membrane they frequently escaped before the scleral opening was united. Knapp and de Wecker often closed the opening with a purse-string suture.

In 1872 Noyes advocated evisceration in panophthalmitis, an opinion which he reiterated in his text-book of 1881. Noyes' first operation consisted merely in incising the cornea and thoroughly wiping out the contents of the eyeball.

Williams reported, in 1878, a case where he intended to do an abscission, but upon opening the eyeball a large bony or calcareous shell was found, which he removed, together with all the contents of the eyeball, before suturing the scleral opening.

In 1878 Williams read a paper before the American Ophthalmological Society advocating the scooping out of the contents of sloughing globes before the scleral sutures were applied, believing it to be the best method of preventing sympathetic ophthalmia.

H. W. Williams inserted (after abscission) very fine sutures, threaded upon small needles, into the outer layers of the sclera, without passing through the ciliary region. This modification proved quite successful and has been extensively used for staphyloma, etc., as well as in other cases where enucleation was not made. Carter recommended passing the sutures through the muscles and conjunctiva. Fröhlich reported a case of abscission, with complete evisceration of the scleral contents, followed by suturing of the scleral opening, where the result was excellent. E. G. Alcorn advocated evisceration, which he called "corneotomy," and was evidently under the impression that he was advancing a new operation. Then followed in 1884, Graefe's (*Versam. Deutsch. Naturforscher und Aertze.*, Sept., 1884) classical paper on complete evisceration which he formally puts forward as a tried operation in most cases superior to enucleation.

J. L. Thompson first introduced sutures and then, before removing a staphyloma, divided the tendons of the superior and inferior recti muscles in order to relieve the stump of their traction, hoping thereby to allow the lips of the scleral opening to come together easily and thus promote speedier and better healing.

Chibret freely opened the cornea and the lenticular capsule, extracted the lens, removed the iris, and evacuated the contents of the globe by repeatedly irrigating the inside of the eye with bi-chloride solution 1:2000. He then packed the eye with cotton soaked with an

ointment of iodoform and cocain. The irrigating and packing were repeated a number of times from day to day until healing occurred. He claimed good results.

Panas (*Arch. d'Ophtal.*, Sept., 1898) proclaimed himself an earnest advocate of abscission or keratectomy, saying that he had practically abandoned enucleation operations; in panophthalmitis, however, he eviscerated. He performed keratectomy as follows: "The patient being anesthetized, a speculum is introduced between the lids. The eyeball is seized with a fixation forceps. A half-curved Reverdin's needle is then passed through the sclero-corneal junction back of the iris and the crystalline lens, and is made to come out of the eyeball at the opposite sclero-corneal junction. The needle, which is to remain in situ until the last stages of the operation, is next threaded. By means of a von Graefe knife, introduced at the point of union of the transparent and the semi-opaque portions of the cornea, the cornea is freed throughout for about four-fifths of its circumference. The keratectomy is completed by a couple of strokes of the scissors.

"In case the iris has not been detached with the cornea it is seized with a pair of forceps and is removed. The speculum is next gently raised away from the globe and the lens is removed with a scoop. The wound is closed by withdrawing the Reverdin needle armed with its thread and this suture is reinforced by one on each side. To complete the operation the projecting angles of the wound are trimmed off with scissors. As a rule there should be no hemorrhage. A one to twenty thousand strength solution of biniodide of mercury is used to cleanse the wound. The stump is dusted with iodoform and a dry dressing with a layer of iodoform gauze is placed next to the lids. At the end of three days the dressing is changed, and four days later the sutures are removed."

Bourgeois (*Recueil d'Ophtal.*, April, 1899) proposed an incision with a Graefe knife two or three mm. back of the corneal limbus, chiefly to avoid the ciliary region. He then closed the opening with three sutures.

The stump in this operation is not large, but it is healthy and heals quickly. He applied the operation in total corneal staphyloma, absolute glaucoma, severe corneal burns, severe traumatism where vision is lost and sometimes in anteriorly situated malignant tumors. His view of the last indication is certainly not shared by many surgeons.

Fage (*Arch. d'Ophtal.*, July, 1906), in endeavoring to mitigate some of the objectionable features of abscission as noted by previous surgeons, proposed the following operation: "The conjunctiva is dissected up all around the limbus. The cornea is then incised transversely

with a Graefe knife. A fine catgut thread armed with two needles is passed through the cornea from within outward, to avoid pressure on the vitreous, and the necessary portion of the cornea is excised, leaving two flaps adherent to the limbus. The lens is removed, after incising its capsule and, if necessary, the iris also. The thread is then tied and reinforced with two or three others, and the conjunctiva is drawn over the cornea and sutured, as has been recommended in accidental wounds. At the end of eight days the latter sutures are removed and the conjunctiva retracts, leaving the cornea uncovered. Later the cornea is tattooed to imitate a pupil."

Objections to abscission. Poncet, Suker, R. Derby, Priestley Smith, Treacher Collins, Knapp and others have noticed irritable stumps following abscission, necessitating removal of the eyeball. Others have noted, as objections to abscission, sympathetic irritation and ophthalmia, loss of vitreous, scleral contraction, etc., and it is quite generally conceded that if the operation has any place in ophthalmic surgery at all, its use should be limited to non-inflamed staphylomatous eyes, especially in children, and possibly in megalophthalmos. Harlan's writings, however, show an enthusiastic allegiance to the operation.

Rogman, in 1903, issued a warning against enucleation in tuberculous eyeballs, as he had observed several fatalities (especially meningitis) following this operation. He believes that evisceration is to be preferred and, in advanced cases, exenteration of the entire orbit.

Final state of the eyeball after evisceration. In the modern operation for evisceration the sclera with its muscular attachments is left intact and it was believed by its advocates that this would leave an especially good, prominent and movable stump. Such claims are undoubtedly primarily true, but in course of time the scleral shell atrophies to such an extent, and the optic nerve pulls the sclera, muscles, conjunctiva, etc., so far back into the socket that the ultimate cosmetic effect of the stump is no better, in the writer's judgment, and perhaps not as good as that of any good enucleation where the muscles and conjunctiva are gathered together.

Estimates of ocular movement, as between enucleation and evisceration, as observed by Hotz, True and de Schweinitz, fortify this assertion. Besides this, cases of sympathetic ophthalmia have been reported by Dransart, Van Duyse, Forget, Nieden, de Wecker and others, following this operation and it is not at the present time a favorite surgical procedure, especially since it was quite generally condemned at the Heidelberg Ophthalmological Congress of 1908.

H. Knapp practised evisceration until he (*Arch. of Ophthal.*, Vol. 14, Nos. 2 and 3, 1884, p. 309) observed a severe case of orbital cellulitis

and thrombosis following the operation, after which he practically abandoned the procedure. Shieck, Hotz, Schmidt-Rimpler, de Schweinitz, Waldispühl and others have reported instances of sympathetic ophthalmia following evisceration where investigation showed

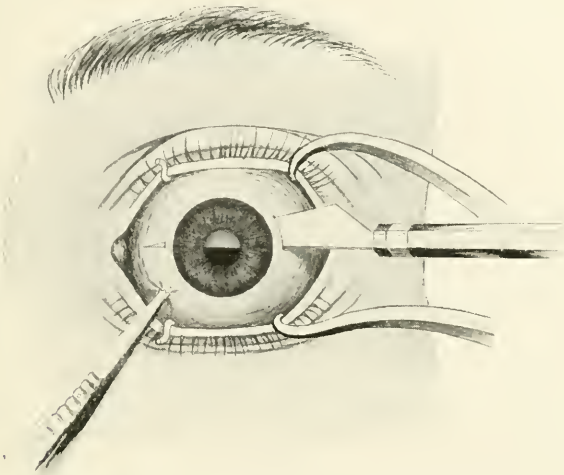

Abscission. Showing Beer's knife in position.

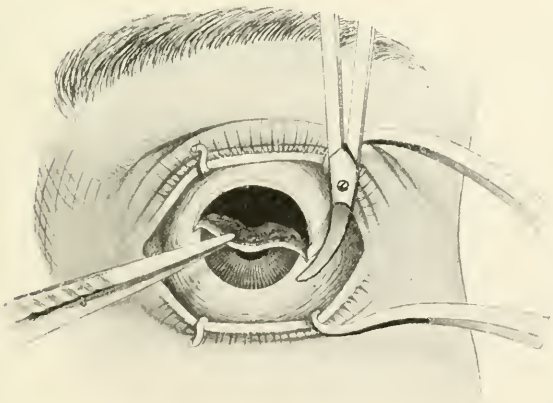

Abscission. Removing the lower flap with scissors.

fragments of uveal tissue (left after the operation) lining the sclera. These shreds contained structures liable to produce sympathetic ophthalmia, and because of this and other objections evisceration is regarded as an unsafe operation. Such opinions as the foregoing, how-

ever, are not shared by every one, since Gifford, Henderson and others regard evisceration as a safer operation than enucleation. They feel that in panophthalmitis fewer avenues of infection are opened in evisceration and that in all cases, inasmuch as in this operation the optic and ciliary nerves are not cut, the danger of sympathetic ophthalmia is much less. It must be admitted that these are good arguments and that the question is still unsettled.

Evisceration is employed by some surgeons in preference to enucleation in cases of panophthalmitis, where it is deemed dangerous to cut the optic nerve for fear of opening up a surgical pathway of infection from the eye to the brain, with the possible production of a meningitis.

This fear is not by any means groundless, as indubitable records such as those of Hobby, Delibes, Graefe, Risley, Siffre, Enslin and Kuwahara, Nettleship, Coppez, Panas and others prove that meningitis sometimes follows enucleation, especially (but not solely) if this operation occurs during the existence of acute suppurative panophthalmitis.

Randolph (*Jour. Am. Med. Assoc.*, June 18, 1910) reports experiments made on 43 rabbits. He produced a purulent panophthalmitis in one eye and then removed it. No meningitis was produced in any case. Nevertheless, Randolph prefers not to enucleate a panophthalmitic eye. He prefers deep incisions into the eye on each side of the cornea.

In the discussion which followed the reading of this paper Fox, Kipp, Taylor, Ledbetter, Ellett, Ziegler and Jackson advocated enucleations during panophthalmitis.

Nor is meningitis the only serious consequence that may follow panophthalmitis, for, contrary to the belief entertained by some surgeons that sympathetic inflammation of the opposite eye does not follow panophthalmitis in the other, Ahlström, Schirmer and Würdemann report cases where this unfortunate termination has occurred. These cases seem to contradict the theory of Leber and Deutschmann that the panophthalmitis inflammation stopped up the lymph passages and prevented germ migration, and the theory of Gifford that the infiltration of the pus corpuscles in the optic lymph spaces prevents bacterial invasion of the sound eye.

Cavernous sinus thrombosis has been known to follow enucleations, etc., as noted by Nettleship and others.

EVISCERATION.

After the insertion of the speculum the conjunctiva is firmly grasped by the forceps and a large Beer's knife is inserted (from the temporal side) into the eyeball just back of the (posterior to the iris)

sclero-corneal junction. The knife is pushed through the eyeball to the other side, thus transfixing the globe upon the blade of the knife. The half-section of the eyeball is completed by the knife and the other half of the anterior section of the globe is grasped by forceps and cut away with scissors, thus completely exposing the interior of the bulb to view. The upper section is usually made first by the knife and the lower section completed with the scissors, but this can, of course, be reversed if desirable. The entire contents of the eyeball are now removed by a sharp and rather large spoon curette, by the scoop recommended by Fox, by the exenteration spatula of Beard, or by firm gauze sponges held in forceps as recommended by Voorheis. One must be careful to scrape away everything down to the bare sclera. Should the intra-scleral hemorrhage be troublesome it may be controlled by hot bichloride tampons, adrenalized tampons or pressure applied firmly to the posterior wall of the scleral sac. The interior of the eye should now be cauterized by carbolic acid, which must be quickly neutralized by alcohol. This application, suggested by Prince, not only mitigates the pain following the operation, but strongly sterilizes the scleral interior. It forms, as Prince says, a coagulum which closes the vascular openings in the sclera and lessens the tendency to microbic invasion backwards. The carbolic acid is applied by a large tuft of cotton wound on a cotton holder, the alcohol may be poured in with an eye-dropper and then dried out by cotton or gauze. The scleral and conjunctival openings should be sewed together with the interrupted or purse-string suture, and the operation is finished.

Gifford (*Archives of Ophthal.*, 1900) pointed out that what is generally called an evisceration is really evisceration plus a keratectomy, and proposed as a routine a simple evisceration, i. e., without a keratectomy. His technique at present (*Ophthalmoscope*, Jan., 1914) is as follows: Cut across the cornea extending one-fourth inch into the sclera at each side. The interior of the globe is carefully scraped out and then rubbed out with a gauze swab. The cornea and anterior part of the sclera is pushed back against the anterior wall, with one or more globular gauze swabs dipped into oxide of zinc ointment. Firm bandage. Swabs are removed after forty-eight hours. This gives an unusually large, flat stump which gives good support to the margin of the glass eye and reaction is less than where the cornea is excised. If it is desired to do a Mules operation, the conjunctiva is loosened and a one-inch cut is made through the sclera, one-eighth inch above the cornea; interior scraped and scrubbed out; glass or other globe introduced; scleral cut sewed up and conjunctiva drawn over cornea with purse-string suture. This leaves more room for the artificial vitreous

and gives more time for the scleral wound to heal solidly; hence less danger of extrusion. The conjunctiva retracts and the cornea becomes insensitive.

Voorheis and Ahlström have advocated a similar operation. Ahlström uses no sutures. He has sometimes combined this procedure with the introduction of an artificial vitreous with good results. He claims that the cornea becomes insensitive and that Mules' globes are not so likely to escape on account of the presence of an intact or comparatively intact cornea.

Chevallereau tried the operation in 1900, but abandoned it on account of the small stump obtained. This experience is contrary to that of Gifford.

Beard (*Ophthalmic Surgery*, 1910, p. 413) proposes to make the incision in Gifford's operation vertical instead of horizontal, which makes, he thinks, a better and a more mobile stump.

Evisceration Scoop Used in Evisceration or Mules' Operation.

Cautery methods in evisceration. Lapersonne (*Arch. d'Ophtal.*, Vol. 1, Jan., 1901, p. 4; also, *Arch. d'Ophtal.*, June, 1900, p. 289) proposed another method of operating for evisceration, which he uses particularly in cases of panophthalmitis and where the sclera threatens to rupture. The cornea is incised with a Graefe knife and the incision is enlarged up and down with scissors. The cornea is not removed. The lens is now extracted, after which a large cautery knife at white heat is introduced within the ocular cavity and passed all around the circumference.

A small cautery knife is sufficient but the large one in use in general surgery is by far the best, and this knife should be curved, its convexity corresponding about to that of the eyeball. When the cautery is withdrawn, it is usually covered with the contents of the eyeball, and purulent debris. It is then reintroduced at a white heat and the sclera thoroughly cleansed. The operation is concluded by washing out the globe with sublimate, not so much for the purpose of antisepsis, as for the special object of removing charred tissue left behind. No suture is necessary. The opening is covered with iodoform and dressed with a simple bandage. In this way not a drop of blood is lost. All vascular tissue is charred and adheres to the cautery knife. The immediate effect of this procedure is an absolute cessation of all pain.

It is marvelous to see how these patients, after recovering from the chloroform, express their gratitude at the relief from the terrible agony which was suffered before the operation, a great contrast to the usual method of operation in which the pain remains for some time afterward. The secretion continues for three or four days and it is therefore necessary to renew the bandage about twice a day. The swelling of the lips of the wound diminishes rapidly and after ten or more days the cicatrix is complete. The stump is regular but small, and the remains of the cornea can still be detected, but there is no pain in the stump and the artificial eye can soon be inserted, the movements of which, in his experience, are much more natural than after the ordinary operation.

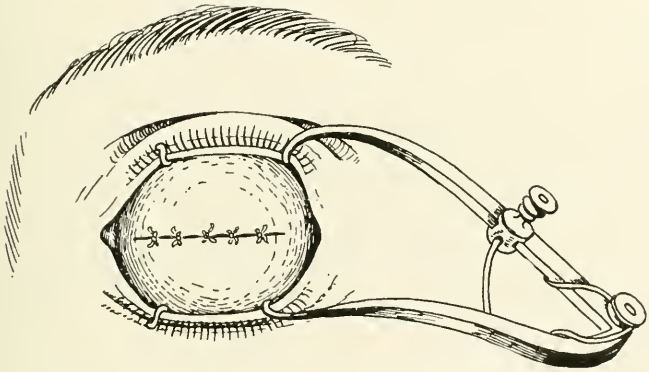

Abscission or Evisceration. Showing closure of wound.

Dianoux (*Annal. d'Oculist.*, Vol. CXXVII) suggests another cautery operation for anterior staphyloma in children. He draws, with the cautery at dull heat, a star on the cornea, the incisions nearly but not quite perforating the cornea. He then makes (also with the cautery) a circular perforation in the cornea which evacuates the aqueous humor. He then dresses the cornea with bismuth powder and applies a compress bandage. Tattooing the eye, after irritation has subsided, completes the procedure.

Schmidt-Rimpler (*Deutsch. Med. Wochenschr.*, No. 27, 1900, p. 429) in drawing some deductions from a large number of eyeball removals, etc., performed at his clinic, concluded that healing was quickest after enucleation and longest after optico-ciliary neurotomy. Sympathetic inflammation subsided after enucleation in four of his cases and in five instances the eye was lost. In some cases sympathetic ophthalmia occurred three or four weeks after enucleation, even later after

neurotomy or neurectomy, and after exenteration within the first week. He concludes that enucleation is the safest operation for the prevention of sympathetic ophthalmia. In a few cases he was compelled to resort to it after performing exenteration or optico-ciliary neurectomy on account of pain. He thinks that exenteration is always indicated in suppurative choroiditis as fatal cases of meningitis have followed enucleation, although he has never seen one.

It should not be forgotten that sloughing of the sclera has been observed after evisceration by Albini (*Trans. Oph. Soc. U. K.*, 1898, p. 258), Treacher Collins and others, and that the operation is rather apt

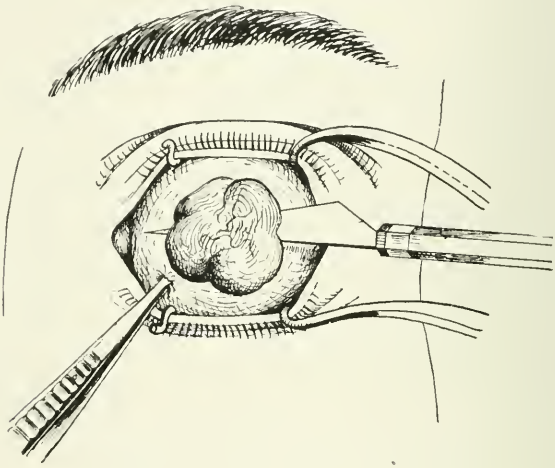

Incision for Removal of a Staphyloma.

to be followed by more reaction and by a little longer stay in the hospital than where an excision has been performed. The stump may also be somewhat painful and irritable.

MULES' OPERATION.

The operation of evisceration combined with the transplanting of a hollow globe in the scleral sac, devised by Mules in 1885, is one of the most interesting procedures in the whole range of ophthalmic surgery. It is performed as follows: The fullest aseptic and antiseptic precautions must be observed during all the steps of the operation.

The evisceration is performed exactly as has just been described, with the exception that in Mules' operation the conjunctiva should be well undermined by scissors as far back as the equator of the globe, being careful not to tear it or to interfere with the muscles. Besides this the optic papilla should be carefully scraped with the curette to a

level with the surrounding sclera to prevent irritation of the nerve by the hollow sphere, which is to be transplanted and retained permanently within the scleral sac. Two small, triangular pieces of the sclera are now cut away, that the upper and lower sides of the wound come neatly and evenly together when they are sutured. Unless this precaution is taken, there will be a lump at each end of the sutured opening. Bissell, in order to make an adequate opening that could be nicely coapted, proposed to pass a Graefe knife through the eye from one sclero-corneal junction to the other. This is done in the horizontal meridian and the edge of the blade is then turned directly

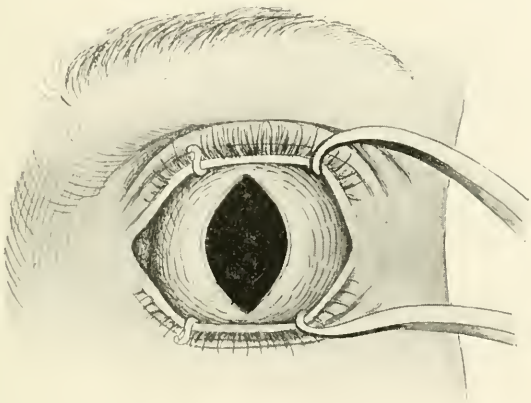

Mules' Operation. Removal of triangular pieces of sclera to facilitate the accurate closure of the opening.

forwards, and the cornea cut through in the same meridian. This makes a complete incision through the entire width of the cornea. The knife is then passed up beneath the upper corneal flap, and the point brought out through the sclera about 6 or 7 mm. above the cornea and the flap divided in two halves by a forward cut. The same is done to the lower flap. The four triangular flaps are then cut off by scissors, and when the ball is finally placed within the scleral pouch, the incision is brought together with sutures without overlapping, gaping, puckering or tension. This makes, so Bissell claims (*Trans. Am. Ophthal., Otol. and Laryn. Soc.*, 1900, p. 51), a smooth, vertical closure, with satisfactory results.

The routine followed by most operators at this point is to insert the hollow globe (after cessation of hemorrhage) into its scleral resting place.

L. Webster Fox (*Diseases of the Eye*, 1910, p. 527) severs the recti muscles from and close to the sclera, because he believes that owing to the irritation induced in the neighborhood of the muscles by the operation, great muscular contraction occurs which sometimes pulls apart the sutured scleral opening and allows the expulsion of the ball. He thinks that this is the reason why so many balls have escaped and the operation fallen largely into disuse. He claims that since adopting this method he has retained all balls and that by being careful to include the capsule of Tenon in the conjunctival sutures at the end of the operation, the recti muscles become reattached to the sclera farther back than their original site of attachment which, of course, weakens

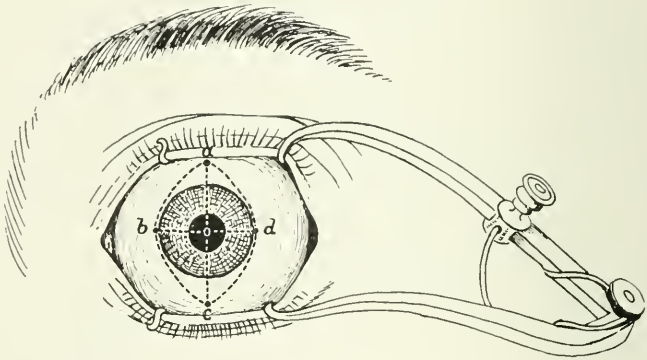

Mules' Operation. Bissell's method of preparation of the opening.

their power but retains sufficient strength to freely move the stump in all directions without exerting disastrous traction on the sutured scleral opening.

Fox has had much experience with Mules' operation and his opinion is certainly deserving of great weight, but it does not seem at all certain that the muscular traction is the sole cause of the expulsion of the ball. The writer has made many of these operations and has had only one ball ejected. This experience leads to the belief that if the scleral opening is securely closed by numerous, delicate, strong, silk sutures, placed far back in the sclera, so as to guarantee a firm hold; if strict asepsis is observed; if the operation is not made in the presence of a thin or disorganized sclera; and if the ball is not too large, there is little likelihood of an expulsion.

Buller and de Schweinitz do not consider attenuated sclerotics, such as seen in buphthalmos for instance, a contra-indication to the operation.

An unfortunate blunder is to select an overly-large ball, thinking thereby to secure an increased cosmetic effect. The sclera contracts a great deal after this operation and if a ball is selected which is a "tight fit" the wound will be quite likely to open and permit its escape. The ball should be so small that the sclera wrinkles over it instead of fitting tightly.

Risley and Suker have maintained, on the other hand, that the selection of too small a ball invites its expulsion. It is difficult to conceive why this should be true, but of course it is not wise to select an extremely small ball, as this would largely defeat the very object of the operation. The ball should be of a size that enables the surgeon without the slightest effort to draw the sides of the scleral opening together over it. The sutures should be easily inserted and the sclera should wrinkle just a little as it envelops the ball. If a small ball be selected and plenty of delicate but strong sutures are used, which are placed far back in the sclera, it will be exceedingly unlikely to escape.

It would also appear that inasmuch as a freely-moving stump is one of the chief arguments in favor of Mules' operation, great pains should be taken to preserve intact the function of the recti muscles, and yet Fox proposes to tenotomize all these muscles and trust largely to the sutures which pass through the conjunctiva and Tenon's capsule to insure their reattachment and restoration of their power. It can easily be conceived that this does not always occur, and when it does not, one of the chief objects of the operation is surrendered. It would also seem much easier (if the muscles are to be tenotomized at all) to sever the tendinous connections either before the evisceration is performed or after the glass ball has been sutured in place, and before the conjunctiva is united, as tenotomies can be more readily performed over a full than a collapsed eyeball.

This question of tenotomy may, however, be settled by each surgeon for himself.

The intra-scleral hemorrhage is given time to cease, hemostasis being facilitated by the application to the interior of the eye of cotton pads soaked in hot bichloride of mercury or adrenalin solution, accompanied with pressure. The result is aided by the application of the carbolic acid and alcohol aforementioned.

The next step is the insertion of the hollow ball, care being taken that it is thoroughly aseptic, round without holes and is not too large.

Brundenell Carter (*Trans. Med. Soc. of London*, 1891-2, Vol. 15, p. 473) proposed (for the purpose of arresting hemorrhage) to fill the scleral cavity with an air-filled India-rubber ball, which is introduced

collapsed, and afterwards inflated with air from a syringe. It has not been much used.

Before inserting the sterilized ball, the interior of the scleral sac should be thoroughly irrigated with a bichloride solution; then the ball should be dropped into its permanent resting place, either by the fingers of the operator or by one of the instruments devised for this purpose. The scleral opening should be closed vertically by numerous strong, black, dialyzed sutures, set well back into the sclera, to prevent their pulling through when the subsequent swelling and contraction occur. The sclera is tough and sometimes difficult to perforate with a needle; this difficulty may be greatly overcome by a pair of eyelet-forceps, which steadies both tissues and needle and guides the passage



Mules' Operation. Showing different sizes of balls.

of the latter through the dense sclera. These silk sutures remain permanently in position and become buried under the conjunctiva; they should, consequently, be left as smooth as possible and their ends should be cut off as close to the knot as is consistent with safety. They must not be of catgut, as it is quickly absorbed; and their continual presence is necessary to keep the scleral opening closed and to resist the traction on the tissues which, if unresisted, would ultimately result in the expulsion of the ball.

The conjunctival opening is now closed horizontally (at right angles to the scleral opening) as by sealing it in this direction the efficacy of the closure is increased. The sutures should be removed in about one week or, in other words, when the conjunctival tissues are firmly united. They should be set well back in the conjunctiva and should include the capsule of Tenon. Mittendorf (*Trans. Internat. Oph. Congress,* 1900. Committee Report) recommends suturing the conjunctiva and sclera together at the same time.

Mules has recommended placing a horsehair drain in the orbital

tissues, at the end of the operation, hoping thereby to lessen the usual reaction. He cuts the external canthus with scissors, burrows freely into the orbit with sharp, curved scissors and in the opening places the horsehair. Other surgeons do not appear to have followed Mules' suggestion and even he does not lay much emphasis upon it in his later writings.

The operative field is now thoroughly irrigated with a bichloride solution. Considerable reaction and swelling usually occurs after this operation, thus subjecting the tissues to great strain. This edema encourages a loosening of the sutures. To combat this tendency Fox uses what he calls a "conformer," made either of glass or gold-plated silver. It is shaped to the contour of the eye, is either solid or perforated in its center, and acts as a splint to support the sutured scleral and con-



Mules' Operation. Instrument for insertion of the ball.

junctival wounds. The writer has used the conformer in a number of cases and can endorse Fox's claims.

The operative area and conformer should be well dusted with an antiseptic powder, or, what is better, abundantly smeared with a bichloride ointment; if powders are used, the lid margins and lids should be covered with the ointment. A perfectly dry, antiseptic dressing is preferred by some surgeons. A pressure bandage is applied over both eyes to support the sutured wounds and promote immobility of the operated eye. It should remain in position for about two days and may be slightly loosened if the pain and swelling are great. It may be necessary to give anodynes and the patient should be kept quietly in bed for the first few days.

Fever sometimes occurs and Mules, Frost, and Bickerton have seen cases of scleral sloughing.

The stay of the patient in hospital is somewhat longer than after an enucleation.

In rare cases the stump after a Mules' operation becomes painful and in some instances enucleation to relieve this pain is necessary. Folker and Richardson Cross have reported such cases. Excessive

vomiting sometimes occurs and is attributed by Bickerton to traction upon the optic nerve.

The bandage may be removed in about two days (see below), and the conformer in three or four days, but the stitches should not be removed for about a week as the conjunctival wound is apt to gape if the sutures are removed too soon. Stitch abscesses are infrequent, but if they occur the stitches should, of course, be removed.

It has been said that the bandage may be removed in two days, but this is merely for the purpose of thoroughly cleansing the parts, inspecting them, applying fresh powders or ointments (or both) and placing a firm pressure bandage again over both eyes.

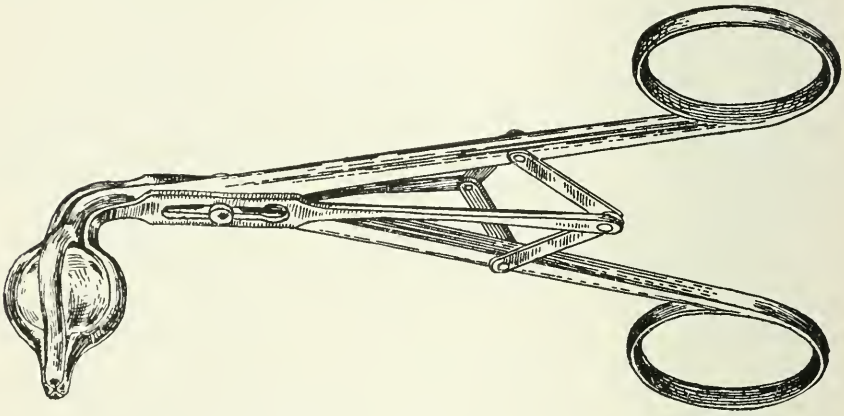

Mules' Operation. Instrument for insertion of the ball.

There is usually some reaction and swelling following this operation and the sutures need to be supported until they are removed, after which time the bandage can generally be permanently removed. If the reaction is marked ice packs may be applied over the bandage for several hours a day, or, as Fox (*Diseases of the Eye*, 1910) recommends, the following lotion may be poured both upon the ice and the bandage over the eye operated on, which ought to be kept constantly moist with this iced antiphlogistic:

Liq. plumb. subacet. dilut., ℥ ii; tr. opii.; tr. belladon. āā, ℥ ss; tr. arnicæ, ℥ ii; aq. camphor.; aq. destill. āā q. s. ad., ℥ iv.

Bickerton (*British Med. Jour.*, Sept. 26th, 1896) claims to have largely done away with the after-pains and swelling by the abolition of a pressure bandage and by the almost constant application of iced saline packs over the closed lids.

Prothesis in Mules' operation. The artificial eye should not be adjusted for at least one month after the operation.

Fox (*Diseases of the Eye*, 1910) has devised artificial eyes for use after the Mules and other similar operations "having a cup-shaped depression on their posterior surface" which comes in contact with the prominence produced by the ball and is held in place by suction. They are manufactured by Wall and Ochs, of Philadelphia.

So far as cosmetic results are concerned, this operation is unequalled, and when its advantages are considered, such as life-like appearance, mobility of the prothesis, flow of natural secretions over the shell

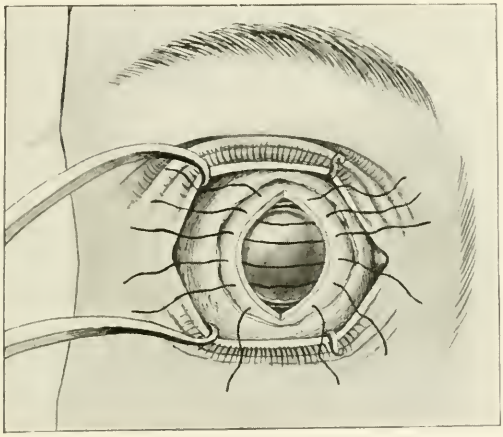

Mules' Operation. Showing the ball in place and the scleral sutures in position.

(directed into proper channels instead of overflowing on the lids), lack of enophthalmus and the maintenance of the physiological orbital development, leaves little to be desired.

If certain objections to its use could be overcome, the operation would be much more generally adopted, especially in individuals where personal appearance is highly important. The idea prevails that very few balls remain in situ, but this is only true where the operation is poorly performed; if done in accordance with the directions set forth here, very few balls will be expelled. If balls are expelled, it occurs in a short time after the operation, although instances of extrusion some years after are on record. If even a small opening occurs at the line of suture, exposing the ball, its total expulsion is inevitable if the ball is of some hard material like glass or gold. If it is, for instance, of paraffin, it can be taken care of, as will later be described, but, if it is of glass, gold, etc., an entirely different procedure must

be instituted. In the latter case no success has followed refreshening of the edges of the opening and resuturing of the parts.

Juler reported one successful case in which he pared the edges of the aperture and grafted on a piece of the patient's lip.

Mules reported two successful cases and Lang (*Trans. Ophthal. Soc. U. K.*, 1898. Committee Report) one where they removed the sphere, refreshened the edges of the aperture, inserted a smaller globe and resutured the wound.

Should the globe escape, however, the most practical procedure is to convert the operation into one of simple evisceration by cleansing

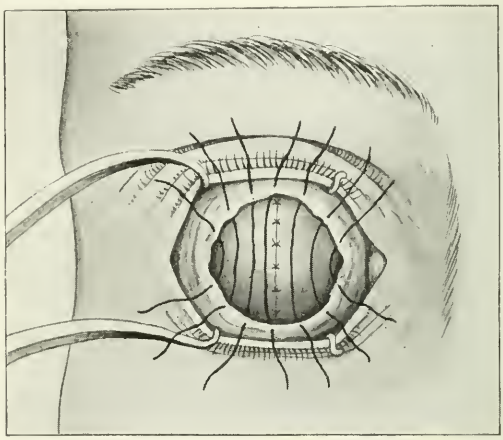

Mules' Operation. Scleral and conjunctival sutures in position.

the interior of the scleral sac, cauterizing it with carbolic acid, after the manner of Prince, freshening the edges of the aperture and suturing the opening with catgut.

To combat the expulsive tendency of the ball, Grimsdale and Brewerton (*Text Book of Ophthalmic Operations*, p. 181), in 1907, proposed that the cornea should not be amputated, but that a long, curved incision should be made in the sclera just above the cornea, through which the evisceration should be made. After this the ball is inserted and the sclera sutured. They report good results and feel that the strain upon the sutures (especially the central suture) is much less than in the other way of operating.

J. J. Thomson (Wood's *System of Ophthalmic Operations*, Vol. I, p. 599) describes his method of suturing the sclera as follows:—"Instead of drawing the smooth, glossy and apparently non-vascular inner surfaces of the sclera together by simple interrupted sutures,

a Lembert stitch is used. Three main sutures are first introduced in such a way that when they are tied, 3 mm. of raw episcleral tissue on each side is folded in and brought together, instead of the inner and comparatively non-vascular coat of the sclera. As many sutures as are deemed necessary can then be put right through, and each will be a Lembert suture. The stump, instead of having a projecting point at each end of the line of sutures, in nicely rounded, and owing to the fact that the muscles are placed at a greater mechanical advantage, the motion seemed to me to be better than in the other forms of operation."

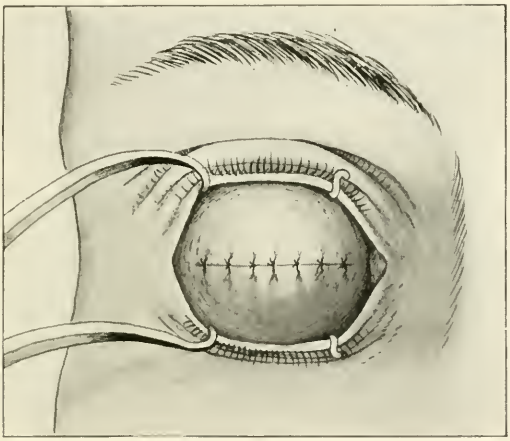

Mules' Operation. Closure of the wound.

The other erroneous impression which prevails is that sympathetic ophthalmia is likely to occur after a Mules operation. This notion is incorrect, for, although it is not denied that sympathetic ophthalmia may follow this operation, it is frequently difficult to prove that the operation caused the disease, since it might have followed some other form of enucleation. Fox (*Diseases of the Eye*, 1910) had done four hundred and twenty-five Mules operations in fifteen years and had never had a case of sympathetic ophthalmia. The writer has done many such operations and can corroborate Fox's remarks; and the same may be said of many surgeons. It seems, therefore, to be a reasonably safe procedure and one that should be encouraged and utilized in suitable cases. It should not be forgotten, however, that there is considerable evidence to show that ball implantations do sometimes produce sympathetic ophthalmia.

Gifford (*Ophthalmic Record*, November, 1908) found that fourteen

cases of sympathetic ophthalmia have followed the Mules operation; nine after ordinary evisceration and three after Frost's operation. Gifford acknowledges that in the majority of these cases the same result might have occurred after a simple enucleation, but feels justified in attributing the disease in seven cases to the operation. He thinks the patient should decide whether he wishes to assume the extra risk for the sake of improved cosmetic appearances.

Oliver reported a case of sympathetic ophthalmia which he claims followed a Mules operation, but the evidence appears to be inconclusive.

Brobst (*Ophthalmic Record*, 1908, p. 583) reports a case where a Mules operation was performed ten hours after an accident. Sixty

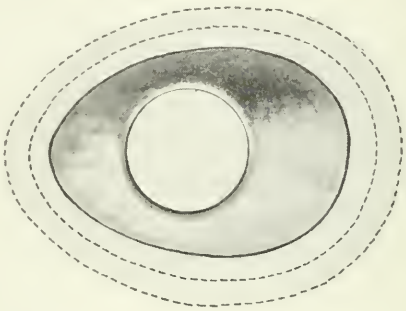

Mules' Operation. The Fox conformer.

days later sympathetic optic neuritis developed and the stump was removed. Recovery followed. The evidence seems quite clear in this case.

Contrary to the opinion of some surgeons, Mules' operation is thoroughly permissible in young people; indeed it is advisable, since it affords the best incentive for development of the orbit, which is, perhaps, arrested after an enucleation or an ordinary evisceration in children. Indeed, de Schweinitz says that this operation "is only contra-indicated by malignant disease, sympathetic ophthalmitis, extensive laceration of the sclera and extreme phthisis bulbi."

Bickerton has prepared a list (modified from Mules) of the advantages the Mules operation possesses over an ordinary enucleation:—

ENUCLEATION	versus	MULES' OPERATION.
1. Complete removal of globe and its contents.		1. Retention of the framework of the eye.

2. No stump, therefore a sunken eye.	2. A firm, round globe forming perfect support for artificial eye.
3. Disturbances of all muscular relations and arrest of movement.	3. Perfect harmony of muscular movements retained.
4. A fixing, staring eye attracting attention.	4. Fitted with selected eye defies detection.
5. Patient shuns society.	5. No qualms as to personal appearance.
6. Arrested development of orbit in cases of children.	6. No interference with growth of orbit.

Besides the advantages of the Mules operation already mentioned, it should not be forgotten that when an artificial eye is worn after this procedure the tears flow more readily into the natural channels and dried secretions are not so apt to accumulate on the artificial shell. In all fairness, however, it must be stated that so far as the sixth clause of the above comparative table is concerned, this is a matter of opinion, inasmuch as the committee appointed in 1896 by the Ophthalmological Society of the United Kingdom to consider such matters was unable to find cases of arrested orbital development after removal of an eyeball. Gordon Byers at that time carefully examined in adult life ten cases where the eyeballs had been removed in childhood and he was unable to find any practical difference in the dimensions of the two orbits.

Frost reports a case where a glass globe was inserted, but healing did not occur. An examination disclosed a ball with a small hole. The ball was one-third full of pus. Ayres has reported a similar case.

If a hollow ball is used it should be made either of glass, as proposed by Mules, or of gold, as proposed by Fox. Aluminum, celluloid, sponge, cotton, asbestos, glass, wool, silver, rubber, silk, catgut, peat, wire, agar-agar, bone, vaseline, fat, paraffin, etc. have been proposed, but most of these materials have been condemned after experience in their use had demonstrated their inferiority.

Bryant warmly recommended aluminum balls with fenestrated walls on account of their strength and lightness. He claimed that new tissues formed inside the scleral sac and entered the openings in the

ball, thus eventually producing a solid mass of aluminum and living tissue which effectually prevented an expulsion of the ball. Cases reported by Coleman, Fox, Todd and others, however, clearly demonstrated that aluminum balls, when sewed into the scleral sac, are liable to disintegrate and break down, a defect which, of course, entirely destroys their usefulness in this operation. Silver balls, recommended by L. Verrey, Bickerton and others, are also objectionable as they produce argyria and are apt to become disintegrated.

Paraffin as an ocular prothesis was first proposed by Brockaert, in 1901. Since then articles have been written on the subject by Ramsay, Suker, Oatman, Alter, Hertel, Lagleyze, C. N. Spratt, Hitschman and others. Paraffin has certain advantages, viz., it can be cut to any size and shape; the body warmth molds it to the contour of the retaining sclerotic envelope and it is claimed that strands of ocular tissue readily penetrate the mass, thus reducing the chances of extrusion. Hertel found after rabbit experiments that hardened paraffin was the best to use, since soft paraffin was apt to become at least partially absorbed.

Spratt's (*Archives of Ophthalm.*, 1905) directions for the preparation of the paraffin and his method of operating are given below. It will be observed that his operations have been confined to the implantation of the ball beneath the capsule of Tenon, and not to the Mules operation proper. "The spheres are prepared as follows: Paraffin with a melting-point of about 60 degrees C. is melted and filtered through ordinary filter-paper into clean test-tubes. These are stopped with cotton and placed in a steam sterilizer. When these have become cool and the paraffin is solid, the glass is heated in hot water or over a flame until the layer of wax next to the glass is liquid. The central solid paraffin rod is readily removed and placed in a warm solution of bichloride. With a knife, this long candle-like piece of wax is divided into suitable-sized pieces and while yet warm is rolled into spheres. During this process, rubber gloves should be worn. The spheres are kept for future use in a wide-mouthed bottle containing a 5% solution of formalin. The most convenient-sized sphere is 17 mm. It is a good plan to have several sizes ranging in diameter from 1.5-2 cm. although the larger sizes can be quickly cut down to a smaller size."

The operation is as follows: "The patient, being under a general anesthetic, the skin about the eye and face is cleaned with soap and water followed by alcohol, ether and bichloride (1:5000). A double layer of gauze, with an opening over the eye to be operated on, is placed over the face and ether cone. This prevents the sutures and the hands of the operator from coming in contact with the ether

inhaler and aids materially in maintaining a clean field of operation. Aseptic precautions should be observed, as an infection is certain to be followed by failure. The conjunctiva is divided close to the limbus and dissected backward beyond the insertion of the recti muscles. These are picked up on a strabismus hook and separated from the surrounding tissue. Before dividing the tendons from their insertion in the sclera, each is caught by a silk suture or held by a small clamp. This prevents retraction of the muscle and the possibility of losing it. The writer uses four Halsted hemostats known as the 'mosquito' pattern. The use of these forceps saves unnecessary puncture of the tendon with the needle and shortens the time of the operation materially. After dividing the tendons close to their insertions, the globe is enucleated in the usual manner. A paraffin globe is then dipped in bichloride to remove the formalin, and cut, if necessary, to the proper size. The globe is seized with a pair of ordinary forceps and placed in Tenon's capsule. An elaborate introducer is entirely unnecessary as the sphere can be placed in position with almost any instrument.

"The superior rectus is sutured to the inferior by a mattress or U-suture and the two lateral recti by a similar suture. A slender full-curve needle threaded with No. 00 chromicized catgut should be used. The large needles tear the tendon unnecessarily and the plain catgut is too rapidly absorbed. To prevent the muscle loops from slipping back over the globe and to give a common point of insertion, an additional suture is placed so as to include each muscle at the crossing of the two loops. Tenon's capsule is closed over the globe by a catgut purse-string suture. This relieves the tension of the muscle sutures, covers the globe with an extra layer of tissue, and prevents the ball from slipping out between the muscles. The conjunctiva is then closed with a purse-string, making, in all, three layers.

"Care must be taken during the operation not to puncture the tendons unnecessarily, as each needle puncture causes the fibres to separate and a possible cutting through of the sutures. Too large a sphere should not be used, as this places tension on the sutures. In the adult a globe 17 mm. in diameter will be found the most suitable size. After the enucleation the hemorrhage may be rather free, but the insertion of the paraffin checks this. No irrigation is used during the operation. A firm gauze dressing is placed over the eye. This is changed daily for the next four or five days and then discontinued. The pressure bandage has been found to lessen the subsequent chemosis. The reaction following the operation is about the same as after an evisceration. Chemosis, as a rule, lasts less than a week, but may, in exceptional cases, continue longer. One patient was discharged

from the hospital with no chemosis on the fifth day. Two cases had thickened conjunctivæ thirty and thirty-five days. The writer has, however, seen chemosis and ecchymosis eight weeks after a simple enucleation.

"The writer believes that the insertion of a paraffin sphere in Tenon's capsule is the operation of choice in all cases requiring the removal of an eye, except when a malignant growth involves the orbital tissue or panophthalmitis is present. In the former cases, exenteration of the orbit; in the latter condition, evisceration with good free drainage of the scleral cavity, are the operations preferred.

"Conclusions: The modified Mules or Frost operation combines the cosmetic results of Mules with the advantages of simple enucleation. These are:

"1. Good cosmetic result is obtained; the artificial eye has good motion; the eye does not have a receding appearance; and the glass is in contact with the lids.

"2. Secretions will not accumulate in the hollow behind the eye, as this is occupied by the stump.

"3. Globe is preserved in toto for microscopic or macroscopic preparations.

"4. No danger of overlooking malignant intraocular tumors.

"5. Best prophylaxis against sympathetic ophthalmia.

"Paraffin is the most suitable material for the prothesis.

"1. It is non-irritating and least likely to be extruded.

"2. Spheres can be easily made and are inexpensive.

"3. No danger of being broken.

"4. Paraffin adapts itself to the shape of the cavity, is soon surrounded by a fibrous capsule, and is firmly held in place by connective-tissue down growths."

Ramsay (*loco cit.*) prefers to use melted paraffin instead of the gold balls. The essential steps of his operation are as follows: After the conjunctiva has been cut and separated from the eyeball, each muscle is caught up by a hook, a catgut thread passed through it and its overlying conjunctiva, and the tendons severed. The eye is then removed. The four recti muscles which have been tenotomized are now put upon the stretch and the cavity left by the removed eye is tamponed with adrenalized gauze which will soon control the hemorrhage, after which a strong, black-silk, purse-string suture is passed through the muscles, conjunctiva, etc. The socket is now dried and filled with melted sterilized paraffin, at a temperature of 104 degrees F. This is accomplished by using a metal, rubber-jacketed syringe, the nozzle of which is inserted into the capsule of Tenon and the liquid paraffin

injected. The catgut sutures should then tie the muscles together in opposite pairs and the black-silk, purse-string suture should also be tightened and tied, and the operation then completed.

Ramsay claims that the paraffin molds itself to the socket and that the tissues become attached to the ball. Some reaction follows the operation and the silk suture is removed in about two weeks. He also says that in thirty-four cases the globe escaped three times.

Oatman (*loco cit.*), who uses a hard paraffin ball, in 1903 drew attention to a feature of paraffin globes which is certainly worthy of consideration. He says that in using unyielding substances, such as glass or gold, when once the incision opens and the globe can be seen, the result is inevitable; the globe sooner or later escapes if it is not

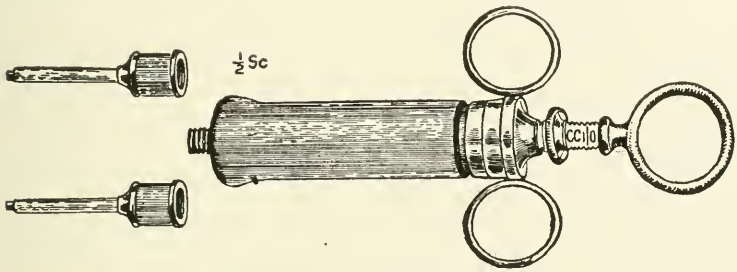

Ramsay's Paraffin Syringe.

instantly removed by the surgeon, which, after all, is the best plan. With paraffin globes, however, if the incision opens, there is still an excellent chance for its retention because portions of the balls can be scraped away by using a small, sharp, heated spoon, after which the wound margins can be freshened and resutured, or, even if the sutures are not applied, the wound frequently closes spontaneously, if enough paraffin has been removed, an event which will be favored by the natural softening and escape of considerable paraffin through the fistulous opening.

Objections have been raised by Davis, Parker and others that paraffin spheres are apt to produce sympathetic irritation, but such fears have not been substantiated by a sufficient number of cases to warrant this conclusion. In using melted paraffin, however, the remote possibility (as pointed out by Hertel, Hurd, Holden and others) of producing embolism should not be entirely forgotten, although when the paraffin is not introduced into the open socket until after the ends of the vessels are plugged, as indicated by a cessation of hemorrhage, there is certainly but little likelihood of any paraffin entering a blood vessel.

Claiborne and Belt have advocated the insertion of a well-sterilized *piece of soft sponge* beneath the capsule of Tenon, muscles and conjunctiva. Belt said that "in a few weeks the sponge is filled with new tissue, which in time becomes firm, solid flesh, making a full orbit and a fine support for the artificial eye." The sponge fibres are apparently absorbed.

Claiborne at the same time experimented unsuccessfully with masses of cotton inserted into the scleral cavity. Claiborne also reported some unsatisfactory experiments in placing *balls of sponge, cotton, asbestos, glass and wool within the scleral walls.* He concludes that these materials are unsuitable for the purpose. Bourgeois recommended a ball of silk, which he used in the same way as Belt's sponge.

The method of Belt was tried and recommended by Trousseau, Risley, Suker, Chandler and others, but the operation has never been much used and later was discarded by Belt himself and practically all the other experimenters.

Suker (Internat. Oph. Congress, 1900; Committee Report) proposed the following procedure which seems to be a combination of several operations:

"The eyeball is removed by the ordinary method, care being taken to save as much of the conjunctiva as possible. The recti muscles are severed as close to the eyeball as possible, and each provisionally anchored by a black silk suture. The cavity, after the eyeball has been removed, is completely evacuated, and all hemorrhage checked before the artificial combination globe is inserted. Avoid using even the weakest solution of bichlorid of mercury during the operation, but instead use a sterilized normal salt solution. This for the reason that the former agent is prone to attack the vitality of the tissues and cause more or less annoyance.

"A suitable and sufficiently large artificial globe (of glass, silver, aluminum, etc.), properly sterilized, is embedded or wrapped up in a layer of very fine surgeon's sponge, likewise aseptic, and tied or sewed with catgut. This embedded globe is inserted into the capsule cavity. The capsule is next sutured with catgut (chromicized). The recti muscles are now brought together in pairs, and the whole fixed by an annular ligament. The black silk sutures are now removed from the recti muscles. Next, the conjunctiva is brought over the muscles, and sutured with silk or catgut. It is best to employ two sets of sutures for the conjunctiva: a so-called edge suture and an anchor suture alternating. This anchor or retention suture is placed as far back as possible from the cut edge of the conjunctiva, in order to relieve any strain upon the continuous or interrupted edge sutures.

"The eye is now dressed with a dry dressing—gauze pad immersed in one part boric acid and four parts amyloform—and if everything has been thoroughly aseptic during the operation, very little reaction or consequent suppuration supervenes. Above all things avoid using pressure bandages. It is advisable to employ an ice bag for the first twenty-four or thirty-six hours. Great caution must be observed in preparing the sponge and globe so as to have each thoroughly aseptic —especially is this true of the sponge."

The implantation of fat taken from the gluteal region and inserted into the capsule of Tenon after an enucleation had been performed, was recommended by Barraquer (*Archiv. de Oftal. Hisp.-Amer.*, Vol. 1, 1901, p. 82). The fatty mass was held in position by suturing over it the muscles, capsule and conjunctiva. He reported some excellent results. D. Velez, F. Lopez (*Arch. de Oftal. Hisp.-Amer.*, July, 1903, p. 506) and U. Troncoso (*Bericht der Ophthal. Gesell. in Wien*, March 9, 1910) performed similar operations with success and have also implanted fat within the scleral sac.

Rollet (*Ophthalmic Operations*, Grimsdale and Brewerton, p. 186) inserted into the capsule of Tenon a lump of fat and skin taken from the deltoid region. The segment of skin should be a little larger than the cornea. The mass of tissue is placed in the capsule with the skin side out. The four recti muscles are sutured to the mass and then the conjunctiva is stitched to the skin all around its periphery. Rollet claims good results and a mobile stump.

Bartels (*Bericht der Ophthalm. Gesell.*, Heidelburg, 1908, p. 333) discussed the method in a paper before the Ophthalmological Congress at Heidelberg. He made some experiments on dogs and operations on human beings. He suggested also the use of fat implantation into the scleral sac, as well as into the walls of the capsule of Tenon. In 1908 Valez reported ten successful cases of fat implantation and warmly recommended the procedure in 1910. Alling reported two successful cases, and in the same year Ibershoff also indorsed the operation and claimed good results. There was but little decrease in the size of the stump, after one year had elapsed.

In 1910 Hans Lauber reported to the Ophthalmological Society of Vienna 37 cases of fat implantation into the capsule of Tenon. His cases were almost all successful, and while some shrinkage of the stumps ultimately took place, he secured prominent, movable stumps in most instances, that afforded excellent and mobile support for an artificial eye. He enucleates the eye in the usual manner, but secures each muscle with a quilted catgut suture before allowing it to retract into the socket. After the eyeball is removed the lump of fat is placed

within the capsule of Tenon and the capsule and muscles drawn over it with catgut. The conjunctiva is then stitched over the entire mass with silk sutures which are removed in from eight to ten days, unless they have meantime been spontaneously expelled. The fat should be gently cut with scissors and as a single mass from its normal location. It ought to be large enough to fill the capsule and yet not so large as to induce tension upon the enveloping walls or the sutures. Any extruding fat should be excised. Sometimes considerable pain, with edema of the lids and conjunctiva, occurs which, however, soon disappears.

Stieren (*Jour. Am. Med. Asso.*, p. 545, Aug. 15, 1914) introduces fat into the orbit instead of into the capsule of Tenon. The piece should be the size of the eye, and should be introduced with the subcutaneous side up. The muscles and conjunctiva are then sutured.

Spratt (*Ophthal. Record*, Vol. 22, p. 596, Oct., 1913) thinks highly of fat implantation, and describes minutely the different steps of the operation in a manner most helpful to those who have not performed the operation.

Landmann (*Am. Journ. of Ophthal.*, May, 1902) recommended wire balls instead of hollow spheres in Mules' operation. He claims as peculiar advantages that they are light and that they become solidly anchored in the socket by granulation tissue springing up between the wires which binds the ball down permanently and prevents its extrusion. The ball is made "of seven vertical, complete circles of silver wire and three horizontal circles, soldered at their intersections." This method has never been much used, but if used, gold wire would surely be preferable to silver.

Pick (*Journ. Am. Med. Assoc.*, Jan. 8, 1898, p. 66) recommended hollow rubber balls and tried the experiment upon one rabbit. The animal unfortunately accidentally died and no more efforts were made.

Silver balls have never been much used as they cause a dark stain on the surrounding tissues and undergo oxidation. Agar-agar, tried by Suker and Gifford, was finally condemned by both as not producing a sufficiently prominent stump. H. Schmidt proposed the implantation of balls of polished bone, and reported some favorable results. Balls of elder-pitch have been employed by Elschnig and Waldstein, who are much pleased with the results.

Haseltine (*Jour. Ophth. Otol. and Laryngol.*, XVII, p. 271) recommends a large, sterile catgut ball to fill the orbit; and reports good results in two cases.

So far as the surface roughening of the glass globe is concerned, if it occurs, it is difficult to conceive how this can do any damage

under the circumstances. Nevertheless there is no apparent objection to the use of gold balls if one desires.

Certainly, of all balls or substances that have as yet been proposed for any form of implantation operation, those of glass or gold are declared generally to be the best.

Suker lays much emphasis on the superiority of "lead-free glass," for he says that our bodies "furnish no acids or alkalies that affect lead-free glass."

So far as the breaking of glass globes is concerned the writer has yet to see a record of one case where this has occurred. They are very strong.

C. H. Sattler (*Ophthalmology*, July, 1913) has transplanted into Tenon's capsule of dogs and three patients, slices of the costal cartilage, from 6 to 8 cm. long and from 1 to 2 cm. wide, which spontaneously curled, so that they could be easily shaped like the eyeball. In one case, the prothesis could be permanently worn from the twelfth day, and the movements of the stump were decidedly better than ordinarily after enucleation. A certain shrinkage occurred, but in from six to nine months later the stump had still the size of a hazelnut.

Lauber (*Annals of Ophthal.*, 1907, p. 208) says that "if the reason is sought for the unfortunate results following the various implantation operations, it can be found in the nature of the implanted body itself. Such transplanted structures are expelled either from chemical reaction, with resultant inflammation, as mentioned by Zeitz and Hertel, or in the production of traction upon the scleral and other surrounding tissues. The smaller the chemical activity of the implanted body, the better will it endure the test." This is one of the principal reasons why Lauber recommends balls of fat. It is the patient's own tissues that are being transplanted, and Lauber feels (with the writer) that there is less liability of chemical antagonism from this source. The reasoning is plausible and the results ought to be good.

The Frost-Lang and Morton-Oliver operations. These operations have so many points in common that they will be considered together.

The Ferrall-Bonnet operation, or the modification which the writer generally uses (already described) can be supplemented by the insertion of a ball into the tissues. This procedure provokes much less reaction than when the ball is inserted into the scleral sac, as in the regular Mules' operation, and makes a fine, movable stump. The method was devised by Adams Frost, in 1886. After the Bonnet operation, a ball may be dropped into the cavity previously occupied by the globe, after which a strong, silk suture should unite the superior and inferior recti

muscles, the same stitch including the overlying conjunctiva. Another suture should unite the internal and external recti muscles and conjunctiva.

The inclusion of the capsule of Tenon in the sutures was the idea of Lang, who proposed this procedure shortly after the Frost operation was suggested. The subsequent treatment is the same as after a Mules' operation. Great care should be taken to see that the ball is placed and remains in the center of the socket, as it is very easy for it to slip to one side or the other.

Morton (*N. Y. Med. Journ.*, Oct. 30, 1897) described an operation similar to that of Lang, the details of which are here quoted:

"The patient being anesthetized, a circular incision is made in the conjunctiva close to the corneal limbus. The internal rectus is dissected free from surrounding tissues up to its attachment to the globe, and held by a pair of advancement forceps, after which it is cut close to the sclera. A double needle catgut suture is passed from within outward, inclosing the central bundle of the tendon and tied to its external surface. The ends of the suture, which are cut to a generous length, are now laid aside to the nasal side of the field of operation. The external, the superior and inferior recti are treated in a similar manner. The oblique muscles are cut, and, no suture being used, escape. The globe is removed after section of the nerve, and all capillary hemorrhage stopped before we proceed. The glass sphere is now placed into the cavity previously occupied by the eyeball, and now lined with the parietal and a portion of the visceral layer of Tenon's capsule.

"The sutures holding the externus and the internus are now taken by the operator, the assistant taking at the same time the sutures retaining the superior and inferior recti. Before the second turn is made in the sutures held by the operator, the assistant ties the sutures together, and these are inclosed in the final turn of the knot holding the external and internal recti. The sutures are now inclosed in a common knot at their intersection.

"I have attempted to explain this process of tying the sutures in detail, since it is of the most vital importance for two good reasons, as I will now proceed to explain. In the first place, should the sutures slip over the glass sphere (the horizontal up or down, the vertical in or out), it would escape from the cavity as placed, and put all of the strain upon the light silk sutures in the conjunctival wound. The second is, if anything, a more important reason; for, should the suture slip, the normal position of the muscles (as retained by this method) upon the glass ball is disturbed, and a condition of unequal tension

results, which destroys the proper movement of the artificial bulb. This is a point in the operation that I desire to lay stress upon—i. e., the careful adaptation of the sutures, so that the tendons assume the same position they occupied in the living eye. By attention to this point, which is obtained by the method of tying the sutures, the excursions of the artificial ball are as unrestricted as in the Mules' operation. The muscles are retained in their place by a process of adhesive inflammation to the over-lying and surrounding conjunctiva, which is completed before the sutures are absorbed. It must be clearly understood that the tendons are not sutured together, but merely held in a normal position until retained by the inflammatory process. The catgut sutures and sphere are now covered by the conjunctiva, which is held by interrupted sutures of Chinese silk. I dust some finely powdered iodoform into the cul-de-sac and apply a bandage, which is allowed to remain for three days. It is interesting to note that the reaction which follows in this operation is very slight, and as a rule causes the patient no pain or elevation of temperature. At the end of three weeks the patients wear the artificial eye with comfort."

The reaction after operations of this nature is practically no greater than after an enucleation, and the stay in the hospital is about the same. The tendency to an escape or displacement of the ball can usually be overcome by care in applying the muscular and scleral sutures. Nevertheless it must not be forgotten that the globe does sometimes escape and there is sometimes considerable reaction and cellulitis. Suker records a case of sympathetic irritation, where the removal of the ball relieved this condition. These operations often give nearly as good cosmetic results as a Mules' operation.

J. W. Barrett (*Intercolonial Med. Journ. of Australia*, 1898, III, p. 210) advised the following method of applying the sutures after introducing a glass globe into Tenon's capsule:

"The operation of enucleation is proceeded with in the usual way. Then the needle is passed in through the conjunctiva about ten mm. from the cut edge, in the position of the tendon of the inferior rectus. It is then passed from within outwards in the position of the external rectus, at the same distance from the cut edge, back from without inwards in almost the same position; it is then passed from within outwards and back again, in the position of the superior rectus and of the external rectus, and finally from within outwards, in the position of the inferior rectus, so the two ends of the suture are close together. The globe is inserted and the suture is tightly tied. The conjunctiva, capsule of Tenon and tendinous expansion of the muscles are therefore drawn firmly in front of the globe and about 10 mm. of con-

junctiva and capsule are loose in front of the suture. The edges of the conjunctiva are now joined by a fine suture."

After the modification of Bonnet's operation, employed by the writer, a ball may be dropped into the socket and the purse-string suture including muscles and conjunctiva closed over it, but it is better in this procedure to use a strong silk instead of a catgut suture. The after-treatment of a Mules' operation should be employed.

Wm. W. Sweet (*Archives of Ophthal.*, Sept., 1910, p. 467) reports the results of forty-eight cases in which a ball was inserted in Tenon's capsule. He performed forty-eight operations in this period of time with the loss of two balls. He used gold balls in forty-two cases, and platinum balls in six. In five of the cases there was evidence of sympathetic irritation at the time of the operation, which subsided after the surgical procedure. In the two cases where the ball was lost an excellent movable stump was obtained. He thinks the operation is entirely safe in all cases where malignant growths or purulency are not present. He does not advocate, however, the operation in case of shrunken eye balls. He does not believe there is any greater danger of sympathetic ophthalmia than when an ordinary enucleation is performed. He thinks that gold balls are lighter than platinum and are, therefore, to be preferred. His method of operating is as follows: "After the conjunctiva has been dissected loose at the limbus, and the usual precautions to preserve all the structures have been observed, the four straight muscles are picked up on a strabismus hook and stitched to the conjunctiva in the normal position or brought forward to the edges of the cut conjunctiva. After the nerve has been cut and the eyeball removed, hemorrhage is stopped by pressure of dry sterile gauze pads, the upper and lower borders of Tenon's capsule are picked up with forceps and the ball placed in the exposed cavity. A stitch is inserted through the upper and lower edges of the centre of the capsule and tied; one end of the thread is cut off, while the other is used to raise the capsule that the sutures may be more readily inserted. From 6 to 8 will usually be required to join the edges of the capsule. Should any portion of the capsule be so thin that the ball shows through, a tuck of the adjoining tissues should be made and the thinned portion covered. The conjunctival edges are now brought together by interrupted sutures placed horizontally. A binocular bandage is applied, but no iced compresses are employed. At the dressing the following day the monocular bandage is used, and the patient allowed to get up. Should edema of the lids be present, cold formalin applications may be made through the light bandage."

Oliver (*Phil. Med. Journ.*, May 27, 1899, p. 1182) proposed the following procedure for which he claimed excellent results:

"The conjunctiva around the entire corneal limbus is freed from the globe and dissected sufficiently far back so as to expose the tendons of the four recti muscles. The tendinous extremities of the muscles are made ready for separation from the globe. A half-curved needle with its point directed toward the corneal border, and holding a long piece of catgut thread, is carried directly through the belly of the internal or the external rectus muscle, and brought out of the tendon of the muscle just behind the remaining attachment to the globe. The muscle thus secured is cut loose from the globe just as in an ordinary

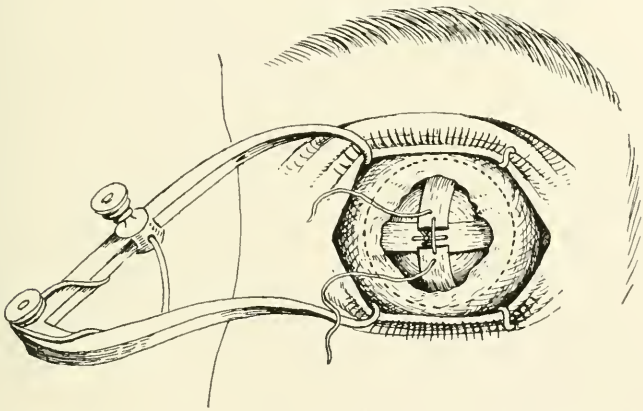

Implantation of Ball (Oliver). The four sutured recti muscles.

tenotomy. The catgut thread is drawn through as far as practicable, and a sufficient length of the strand of gut is left untouched in order to allow a loop broad enough for free manipulation between it and the eyeball. The needle is carried over to the opposite side of the cornea, and, with its point directed away from the cornea, is made to transfix the tendinous belly of the lateral muscle, which is secured and freed from its connection with the eyeball.

"The vertically-placed muscles are dealt with in a similar manner.

"The four recti muscles are thus freed from their tendinous attachments to the globe, and each pair of muscles is secured in a loose sling that can be tied the moment that this becomes necessary.

"Working in between the broad loops of catgut attached to the ends of the muscles that are held apart by an assistant the eyeball is enucleated with as much of the optic nerve as may be desired, without any difficulty.

"The cavity previously occupied by the globe is thoroughly cleansed and a water-tight glass ball of about three-fourths of the size of the normal globe is dropped into place.

"The ends of the lateral recti muscles which are held by the lower and the first placed catgut thread are neatly trimmed and sutured together. The same is done with the two ends of the vertical recti muscles. The circular opening made by the cut edges of the overlying conjunctiva is lengthened into a lozenge by a couple of horizontal snips, and is carefully brought into linear apposition by a series of silk threads.

"The operative field is covered by a gauze protective bandage upon which iced compresses are placed.

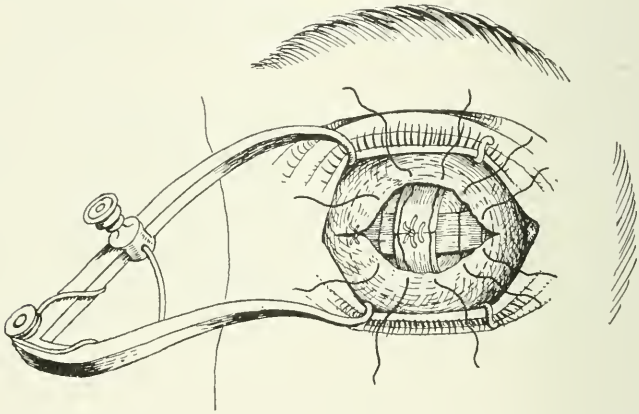

Implantation of Ball (Oliver). Suturing the conjunctival opening.

"If the operation be done under strict asepsis, without any undue violence, and the parts be kept thoroughly freed from blood-clots and loose or hanging tissue, and if iced compresses be employed for the first 24 to 48 hours after the procedure, there will be absolutely no reaction, and the surfaces will be ready for the insertion of an artificial eye in a very brief time—in fact, earlier than after an ordinary enucleation, while the cosmetic results will be fully as good as those that are gotten by Mules' method.

"The operation is offered on trial for cases in which abscission, keratectomy, or evisceration with insertion of artificial vitreous are inadvisable or impossible, such as in many cases of phthisis bulbi, extensive ruptures of the sclera, etc., thus giving opportunity to obtain well-fitting and freely mobile artificial eyes in cases in which it is necessary that a globe without any of the other orbital contents must be sacrificed."

Delayed implantation. The implantation of a ball into the orbital tissues some time after a Ferrall-Bonnet enucleation, as suggested by Fox (*Diseases of the Eye*, 1910), is a desirable surgical procedure, as it transforms a deep, sunken cavity into a prominent stump and is one

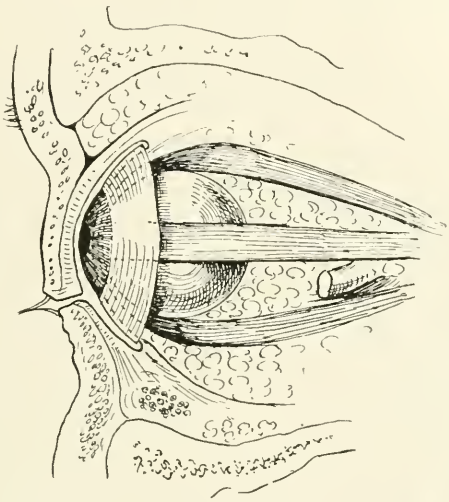

Implantation of Ball (Oliver). The ball and the artificial shell in position.

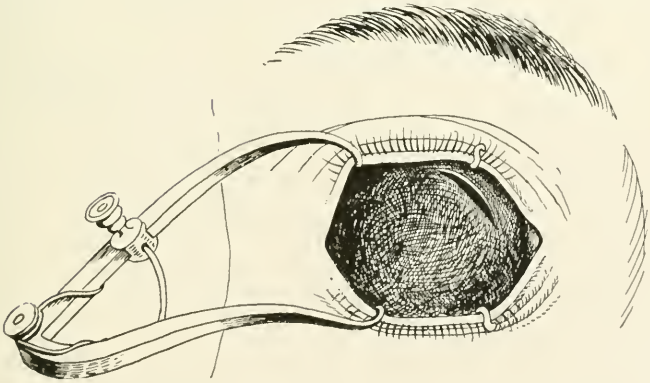

Delayed Implantation (Fox). The opening in the socket.

that gives a life-like appearance to an artificial eye. The operation is performed as follows: The conjunctiva of the socket is firmly grasped by forceps and an incision is made about three-quarters of an inch long through it and somewhat into the underlying tissues. The incision should lie either between the location of the superior and internal recti, or between the superior and external recti muscles, and

should be at about an angle of 45°. A thorough separation of the tissues should be made with knives and scissors so that a space is produced (in the center of the socket) large enough to accommodate a ball, and deep enough to secure its retention. It will be observed that when the ball is in its central position there are no stitches directly over

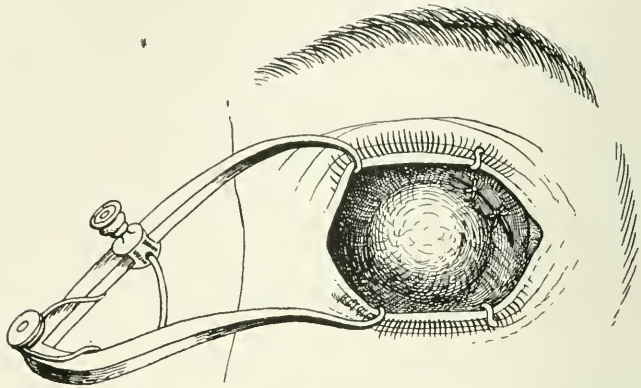

Delayed Implantation (Fox). The ball in position and the opening sutured.

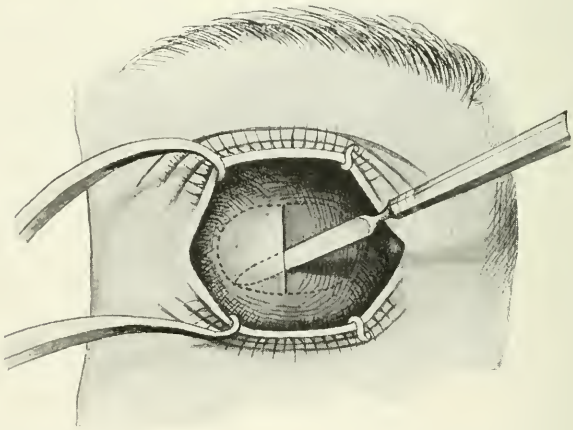

Delayed Implantation (Lagrange). The opening in the socket and the tissues being undermined.

it, they are off to one side, which, of course, greatly adds to the security with which the ball retains its position. After the space has been made for the ball, it is inserted into its place and the incision securely sutured by an abundance of silk sutures inserted well back into the tissues to guard against their untimely liberation. The conformer is used and the after-treatment is the same as for a Mules' operation.

The sutures may be removed in six or seven days. Sometimes Fox dispenses with sutures. There is not much motion to the ball, owing to the contraction and disuse of the recti muscles, the stump is prominent, well supports an artificial shell and undoubtedly relieves the deformity.

L. Borsch (*Bulletins de la Soc. Frs. d'Ophtal.*, 1898) implants a

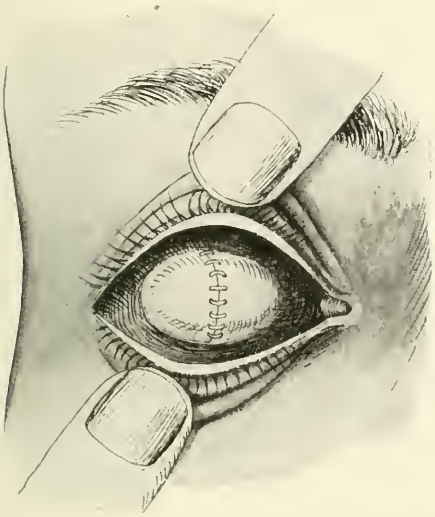

Delayed Implantation (Lagrange). The hollow shell in position and the tissues sutured over it.

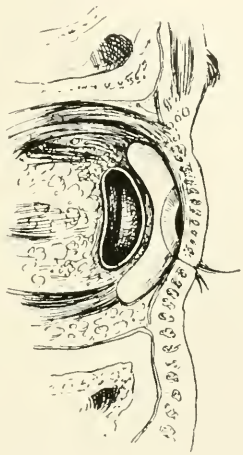

Delayed Implantation (Lagrange). Showing the completed operation and the artificial eye in position.

Delayed Implantation (Lagrange). The hollow shells.

hollow, half-spherical shell in the apex of the socket, after the superficial tissues have been undermined by a spatula-shaped knife. A vertical incision is made at the apex of the socket, and the tissues undermined to the right and to the left sufficiently to admit easily the hollow shell, which is then confined in its position by firmly suturing the vertical incision. In proper time the artificial eye is placed over the prominent stump. Borsch prefers gold or silver shells. It should

not be forgotten in this connection that silver shells discolor the tissues, and that lead-free glass shells do not become rough or irritating.

Suker (*Annals of Ophthalm.*, Jan., 1903) advocated a similar operation, but used paraffin instead of a glass or gold ball. He makes a pocket in the apex of the socket and passes a suture through the lips of the wound. He then injects paraffin into the pocket and ties the suture.

OPTICO-CILIARY NEUROTOMY OR NEURECTOMY.

Optico-ciliary neurotomy or neurectomy is seldom a desirable substitute for enucleation, but if employed as such, is especially applicable in painful, sightless eyes of normal appearance and unaffected by tumors. The operation is particularly useful in cases of absolute glaucoma, for, according to Nicati (*Archiv. d'Ophtal.*, Dec., 1900), whose experiments are mentioned by Fage, section of the ciliary nerves moderates or lessens the secretion of the aqueous humor, while section of the optic nerve favors filtration by widely opening the sheaths of the nerve.

When first systematically proposed and practised by Schoeler (*Archiv. of Ophthal.*, Vol. 16, 1887, p. 37), it was thought by many surgeons to be applicable mostly in cases where foreign bodies were lodged within the eyeball, and could not be safely removed. It was thought that this operation would give the patient a chance to retain the eyeball and that sympathetic ophthalmia would be prevented by severing the optic and ciliary nerves. When the magnet was introduced, however, it was found possible to remove many foreign bodies and the opinion of surgeons soon became crystalized into the belief that it was unsafe to allow an eyeball to remain that permanently harbors a foreign body, unless, perhaps, such an invader be lodged in the lens; and even this exception has by no means been received as good surgery by a majority of ophthalmologists. If, however, it is deemed expedient to allow a foreign body to remain in the eyeball without enucleation, or some substitute therefor, the operation of optico-ciliary neurotomy should certainly be performed.

Although Schoeler was the first surgeon to adopt this procedure and put it to considerable use, it must not be supposed that he was the first to propose the operation, for as early as 1853, Arlt (*Arch. Ophthal.*, Vol. 14, Nos. 2 and 3, 1884, p. 223), who believed in the theory of sympathetic ophthalmia by way of the ciliary nerves, suggested their division, a view which was also shared by H. Müller.

Von Graefe, who believed that the disease was carried by the optic nerve, suggested its division as a preventative measure. The idea of

severing both the ciliary nerves and optic nerves, to cover the possibilities of both theories, was a natural evolution, and in 1866 Rondeau formally proposed this procedure after experimenting on many cadavers. The operation then became known as "optico-ciliary neurotomy."

Rondeau operated without cutting any muscles by incising the upper and inner portion of the conjunctiva. He then cut the nerves by passing behind the eyeball with a narrow, curved tenotome.

The operation fell more or less into disuse, but was finally revived by Boucheron in 1876, who operated without myotomy or tenotomy, but opened the conjunctiva between the superior and external recti muscles and pulled the posterior portion of the eyeball forward with sharp forceps, to facilitate the cutting of the optic and ciliary nerves. Later, he advocated severing the internal rectus muscle and holding it aside by a suture to provide ample field for the operation and observation. After the optic and ciliary nerves were severed and the hemorrhage had ceased, a firm compress bandage was applied.

Schoeler, in 1878, began to do the operation frequently. He opened the conjunctival sac more extensively, tied and cut off the external rectus muscle and thus gained a larger operative field. The muscle was subsequently reattached to the eyeball by sutures.

Schweigger performed many such operations, but altered the technic by operating from the nasal side, as recommended by Meyer and others, and by exsecting a piece of the optic nerve at least 10 mm. long. He claimed that the nerve was more easily reached from the nasal side, that the oblique muscles were in the way and must be severed when operating from the temporal side. By exsecting a portion of the nerve the two ends would not unite and that infection could not, consequently, pass through it into the fellow eye.

Schweigger laid great stress on removing a large section of the optic nerve as he believed that sympathetic ophthalmia is the result of infection from the opposite eye and that the ciliary nerves have little or nothing to do with it. Meyer went a step farther and advised the division not only of the internal and external recti muscles, but the oblique as well, so that the eyeball might be rotated with perfect ease and the nerve fully exposed to view. Schweigger also recommended that the posterior pole of the eye be pulled forward not by forceps but by a hook caught in the sclera. His hook had only a single arm. Schweigger severed the internal rectus muscle, but before doing so he sutured the tendon and conjunctiva with two catgut strands, one near the insertion of the muscle and the other a little farther back. He then severed the muscle, conjunctiva, etc., between the two sutures.

An assistant utilized these sutures (which were left long) to pull aside the conjunctiva and freely expose the eyeball. He then generally cut through the insertion of the oblique muscles. After severing the nerve, etc., the wound was closed by tying the two sutures. He sutured the upper and lower lids together and applied a compress bandage, to prevent protrusion of the eyeball. He called attention to the fact that severe ecchymosis often occurs and this frequently extends to the other eye. He thought that the hemorrhage was no worse than after an enucleation, but that the drainage was not so good and the blood not having as good egress, made more disturbance, especially as the eyeball was still in place. Schweigger's further observation did not lead him to believe that the operation produced any atrophy of the globe, as claimed by some.

Knapp did the operation by way of the space between the superior and internal recti muscles, after the manner of Rondeau, Boucheron, Dianoux, and others, and without cutting a muscle. He employed a double-armed hook to draw the posterior pole of the eye into the conjunctival opening so that the optic and ciliary nerves might be inspected in order to be sure that they were all cut. He took great pains to operate as close to the sclera as possible, as in this area muscles and vascular tissue are largely avoided and the hemorrhage is much less. Chisholm, in later years, operated similarly in a large number of cases with success.

Knapp at this time was impressed with the idea, more or less shared by many observers including Boucheron, Mauthner-Jaeger, Schöler, Dor, and others, that sympathetic ophthalmia passes from one eye to the other by way of the ciliary nerves. The optic nerve was, it is true, severed "so as to make sure" as it were, but the ciliary nerves were regarded as the real offenders. Great pains were taken to sever all the ciliary nerves. This is an undertaking not as simple as it seems, when it is remembered, according to Dor and Cruveilhier, that a few ciliary nerves penetrate the anterior portion of the sclera, beneath the recti muscles, one of which, at least, remains after the ordinary optico-ciliary neurotomy.

Another point which consumed considerable attention at that time was the possibility of some, at least, of the nerves uniting after they were cut, a condition evidenced by a restoration of corneal sensibility which, of course, is lost when all nervous connection is severed. Bietti, Mauthner-Jaeger, Boucheron, and others, have seen cases where such reunions have occurred in enucleated eyeballs. Later opinions, however, leaned heavily in the direction of the optic nerve as being the real pathway of pathological connection between the two eyes. Acting

upon this theory, therefore, it became necessary to sever the optic nerve and even, as suggested by Schweigger, to remove a large portion of its intra-orbital structure to prevent reunion.

Pagenstecher began practising neurotomy, but did not long remain enthusiastic on the subject. De Wecker used it to a considerable extent and employed a right-angled strabismus hook with which to pull the optic nerve forward. He also used compress scissors with which to sever the nerve and compress it, so as to prevent hemorrhage from the central artery.

Optico-ciliary neurotomy. General anesthesia should be adopted. The conjunctiva over either the internal or external rectus muscle (preferably the internus) is picked up by forceps just as in a tenotomy for strabismus, and a large, vertical opening made through the conjunctiva. The muscle is drawn out with a strabismus hook, and a suture passed under it and tied around it about ¾ cm. from its insertion. The muscle is now cut between its insertion and the knot, close enough to the knot to leave a large section of the tendon hanging from the eyeball, to serve as a handle to be caught by the forceps for the purpose of pulling the eyeball into positions convenient for the surgeon. The long suture is now given to an assistant who draws the muscle, etc., away from the eyeball, while the operator grasps the tendon with the forceps and rotates the eye in the opposite direction as far as possible to bring the optic nerve as prominently to the surface as possible. A curved double hook piercing into the sclera may, of course, be used instead of the forceps, or in conjunction with it, for this purpose.

The curved scissors are now passed back of the globe, searching for the optic nerve which, when found, should be carefully severed from the eyeball. The neurotomy can, of course, be converted into a neurectomy by exsecting a long piece of the optic nerve, a procedure which is adopted by most operators. The speculum, scissors and forceps should now be withdrawn, the lids closed and gentle but firm pressure exerted upon the eyeball, to prevent hemorrhage. If the bleeding be violent and persistent and causes an irreducible protrusion of the eyeball, it should be enucleated, but as a rule the hemorrhage will be controlled in a few moments and further progress can be made.

The speculum should be replaced, the assistant should again pull the muscle away from the eyeball by means of the suture, the tendon should be grasped by the forceps and the eyeball rotated as far as possible in the opposite direction and the ciliary nerves, as they pass into the sclera in the neighborhood of the optic nerve, should all be carefully cut to prevent the transmission of pain, using great caution,

as Golovine suggests, to sever that branch of the ciliary nerves which lies beneath the internal rectus muscle. This branch is easily overlooked, but should be cut, else the operation will not bring relief from pain, and this is often the main purpose of the procedure. At the same time (the bulbar portion of the nerve is now plainly in view) the optic nerve should be cut off level with the scleral surface, if this has not already been accomplished at the original section.

Linds Furgeson claims that the hemorrhagic proptosis can be greatly relieved by passing the curved scissors back of the eyeball, lifting it a little and allowing the blood to escape.

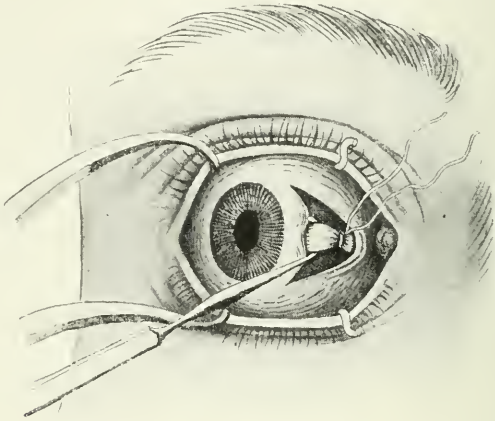

Optico-Ciliary Neurotomy. Showing the conjunctival incision and the muscle tied, the latter being held on a strabismus hook.

The socket back of the globe should now be thoroughly irrigated with bichloride solution, the muscle caught by fixation forceps, the suture which held the globe liberated and the muscle securely sutured to the tendon with catgut—to preserve its function. The lips of the conjunctival wound should be drawn together with catgut sutures, the speculum withdrawn, the lids closed and the operative field and lids abundantly smeared with bichloride ointment.

A firm pressure bandage should be applied and the eye subsequently inspected from day to day.

Some exophthalmus persists for a short time, but it almost always disappears.

The results of the operation are freedom from pain, with an anesthesia of the cornea that gradually disappears. Corneal ulceration sometimes occurs from defective nourishment, or exposure due to in-

ability to close the lids—as recorded by Landesberg, Poncet, Leber, Ridard, and others. Tension is usually normal, but the fundus vessels are anemic. Atrophy of the eyeball is not apt to occur. Pain sometimes returns, according to Landesberg, Linds Furgeson, Treacher Collins, and others.

If successful, the operation is certainly excellent, since an eyeball remains, normal in appearance, and perfect in its muscular excursions.

Linds Furgeson (*Trans. Ophthal. Soc. U. K.*, 1898) has devised a pair of curved scissors with a clamp on its concave surface for cutting

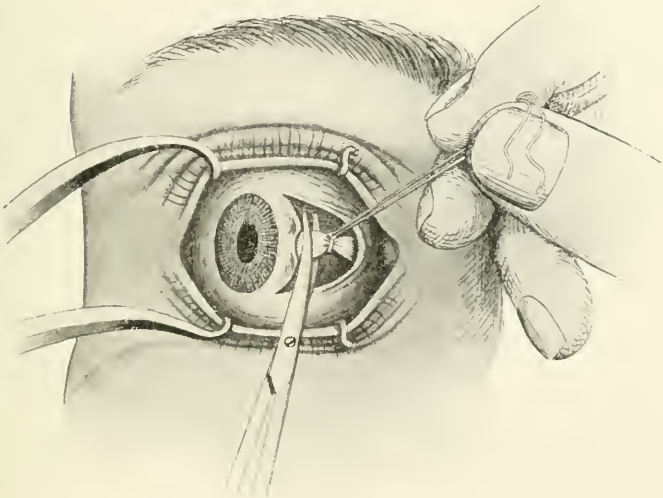

Optico-Ciliary Neurotomy. Severing the muscle.

the bulbar end of the optic nerve. The scissors and clamp operate simultaneously so that, after the nerve is severed, the globe can be pulled completely around by the clamp. Briggs (*Arch. of Ophthal.*, Vol. 16, No. 1, 1886, p. 37) has devised a pair of curved scissors with two sets of blades several mm. apart by which a section of the nerve can be cut out with one compression of the blades. Claws between the scissor blades catch the exsected portion of the nerve; which insures its removal when the scissors are withdrawn.

Golovine clamps the optic nerve with strong pressure forceps and then divides it in front. He allows the forceps to remain in situ about ten minutes, and claims that as a result, there is very little hemorrhage. Golovine also exsects a portion of the optic nerve.

Henry Joseph (*Arch. d'Ophtal.*, Nov., 1904, p. 715) devised an instrument, something after the form of a tonsillotome, for the purpose of cutting the optic nerve, that may be used either in optico-ciliary or any other form of ocular neurotomy. Richard Vollert, of Leipzig, in 1909, devised a pair of scissors with false, dull blades in front. These

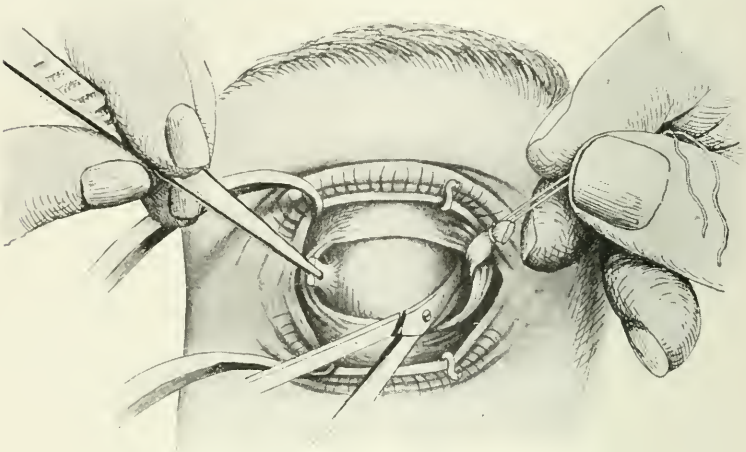

Optico-Ciliary Neurotomy. Cutting the optic nerve.

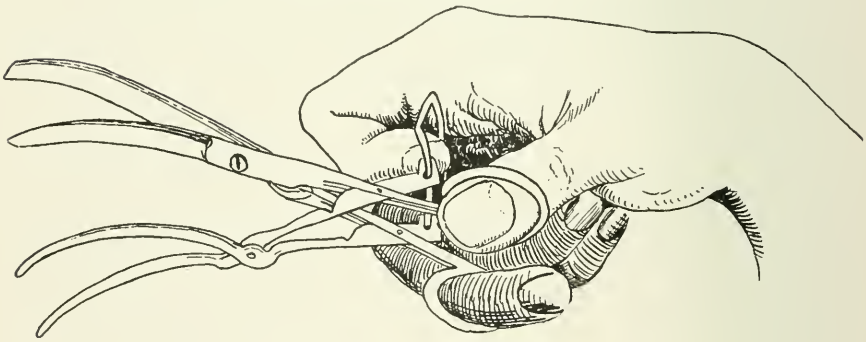

Scissors of Vollert.

latter are forced forwards by pulling their base backwards. This manœuver forces the eyeball forwards and allows the section of the nerve to be made as far backward as possible. The instrument may be used in neurotomy or in any form of enucleation.

Chisholm (*Journ. Am. Med. Assoc.*, Sept. 10, 1892) advocated a short anesthesia, as his operation takes only a few minutes. He makes, with scissors and forceps, a short, horizontal incision in the conjunctiva

along the lower border of the internal rectus muscle. Scissors are inserted beneath the membrane to open the space of Tenon. A double-pointed, curved hook inserted beneath the capsule, engages the sclera. The eyeball is rotated outwards, bringing the optic and ciliary nerves

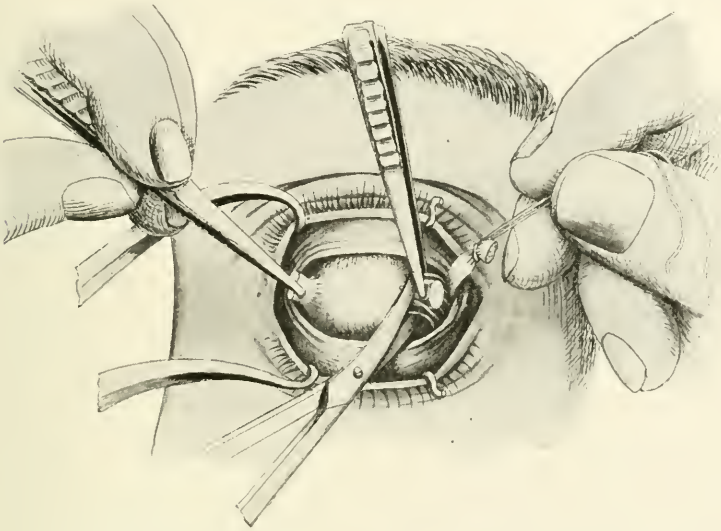

Optico-Ciliary Neurotomy. Cutting the ciliary and optic nerves.

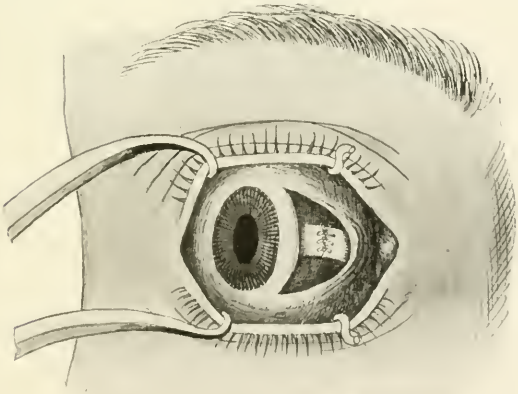

Optico-Ciliary Neurotomy. The sutured muscle.

within easy reach. Strong, curved, enucleation scissors are now passed back of the eyeball and both nerves are severed. A compress bandage is quickly applied after the ordinary dressings, to prevent excessive hemorrhage. It is kept in place for one day.

Chisholm claimed extraordinarily good results, but this statement should be taken guardedly as many surgeons have abandoned his operation on account of excessive bleeding, corneal necrosis, bulbar atrophy, etc.

In a personal communication from Menacho, of Barcelona, he advocates making the circum-corneal incision and afterwards cutting the internal and external recti muscles quite a distance back from the globe. A suture is then passed through each end of the severed muscle. The sutures transfixing the tendons next to the sclera are held in one hand while the eyeball is pulled forward as far as possible, thus lifting it from its bed. This enables the operator to pass the scissors back of the eyeball and perform the neurotomy or neurectomy, after which the cut tendons are sutured together. Menacho claims for the operation simplicity and speed.

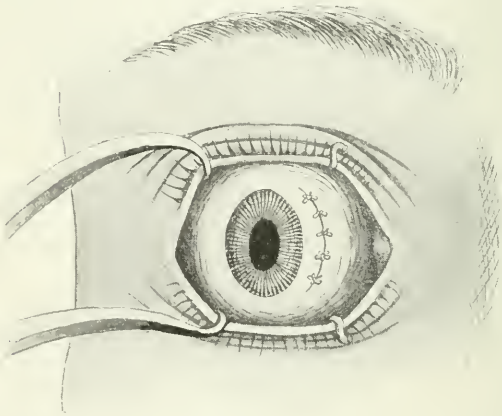

Optico-Ciliary Neurotomy. The sutured conjunctiva.

Ernest Hall (*Am. Journ. of Surg. and Gynecology*, Vol. 8, July, 1896, p. 96) proposed as a substitute for enucleation the following procedure: "The scissors having been inserted about 25 mm. behind the sclero-corneal junction, sufficiently to include the ciliary body, a complete section is made, so removing the whole front of the eyeball. The vitreous is then evacuated and the retina and choroid removed by curette. The hemorrhage is profuse but controlled by hot water and pressure. Then the speculum is inserted within the ball and so made to hold the eyelids and edges of the sclerotic opening. The optic nerve is grasped with toothed forceps and scissors, or a long slender knife inserted as close as possible to the nerve to avoid wounding the ciliary arteries, and a circular incision made in the sclerotic, freeing the optic

nerve. The nerve is then drawn forward and severed about 25 mm. from the sclerotic and conjunctiva. A piece of gauze is inserted in the sclerotic and conjunctiva closed vertically so as to give normal tension to the internal and external recti."

By this operation the ciliary region is excised in front and the optic nerve, etc., behind, thus removing the two principal sections of the eyeball whence trouble may be expected. The central zone of the sclera, with its muscular attachments, is undisturbed.

Huizinga (*Journ. Am. Med. Assoc.*, Feb. 17, 1900) proposed an operation which he called "Eviscero-neurotomy." It is a combination of evisceration and optico-ciliary neurotomy. A Mules globe may be inserted or not, and he claims complete immunity from sympathetic

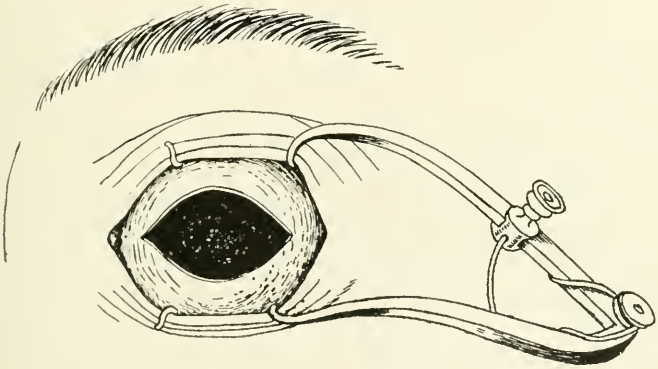

Preparatory Evisceration for Huizinga's Operation.

ophthalmia. In this operation the anterior portion of the globe is abscised by knife, scissors and forceps; the contents of the globe are removed exactly as in the ordinary evisceration operation. The bulbar opening is enlarged laterally by splitting the sclerotic up to the insertions of the internal and external recti muscles. The peculiar feature of his operation is as follows: "While an assistant keeps the mouth of the wound widely open, a pair of forceps is introduced into the inside of the ball, through the opening made by amputation of the cornea, and the sclerotic coat is caught about midway between the equator and the posterior pole, and button-holed with blunt-pointed scissors.

"This opening is then enlarged laterally, parallel with the equator, until it has encircled one-half of the ball. A blunt, curved enucleation scissors is then introduced through this opening and passed back of the globe, and the optic and ciliary nerves are severed. Having thus

loosened the eyeball posteriorly, this part can then be drawn forward up to the corneal opening by partly everting the sclerotic from behind by the aid of forceps, and that part of it, including the nerves, is removed by continuing the cut parallel with the equator until it extends entirely around the eye. In this manner the posterior segment of the eye, a section somewhat larger than the cornea, is removed, and all nerve connection thoroughly and permanently obliterated, while the rest of the sclerotic with its muscle attachments is allowed to remain.

"The introduction of an artificial vitreous is very desirable, notwithstanding the fact that it is not always retained and the difficulty occasionally experienced to obtain prompt and perfect union by first

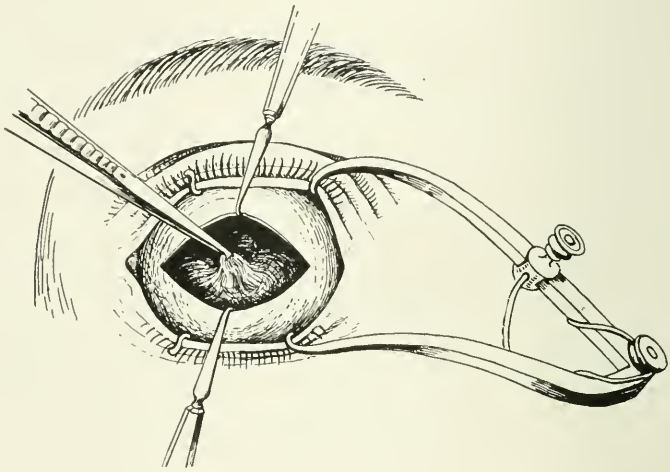

Operation of Huizinga. Grasping the sclera from the inside of the eye.

intention. Where such unfortunate conditions do not obtain, and they are in the majority, the results are so much better for a prothesis that I believe this practice would be more generally adopted if some material could be obtained that is more suitable to the purpose than either glass or metal.

"The wound is closed with fine silk sutures, and the after-treatment is the same as in evisceration. The local reaction following this operation has in no case been as severe as that following simple evisceration. In fact, I should say that it has been no more severe than after enucleation.

"This operation is strictly in accord with what I consider one of the first rules in surgery, viz., to obtain the maximum in results by the removal of the minimum of tissue.

"In conclusion: 1. This method, with the use of an artificial vitreous, leaves as perfect a stump as after Mules' operation. 2. It prevents absolutely the dangers of sympathetic inflammation. 3. The local reaction appears to be no greater than after enucleation. 4. We obtain the maximum in results by the removal of the minimum of tissue. 5. We obtain, besides this, all the advantages claimed for Mules' operation, as well as those of enucleation without their disadvantages."

Shortly after the publication of this paper, Huizinga began a series of operations on dogs and considerably modified his previous procedures. His improved method is as follows: "Having introduced a speculum and taken the ordinary precautions to guard against infec-

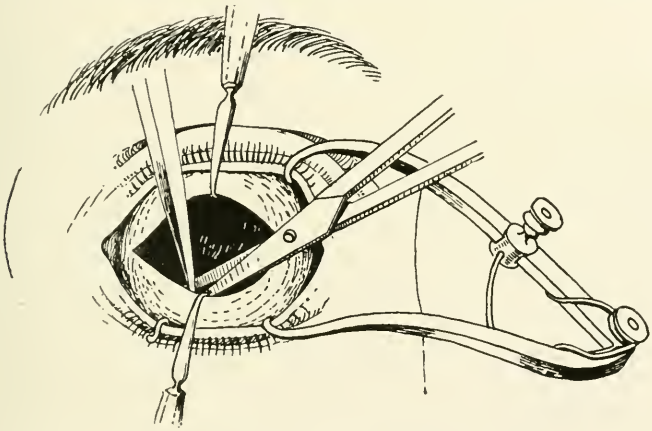

Operation of Huizinga. Cutting away a portion of the sclera from the inside of the eye.

tion, the eye is drawn inwards and upwards as far as possible so as to expose the external inferior quadrant. With a small scalpel the sclerotic is pierced about a quarter of an inch posterior to the sclerocorneal margin and just below the insertion of the external rectus. This incision is carried backwards meridionally up to the entrance of the optic nerve. The cornea is not amputated but left intact. The contents of the eyeball are carefully removed and its interior thoroughly cleansed. I find that an ordinary eye speculum introduced into this wound assists in keeping its edges apart and greatly facilitates the work. A circular section of the posterior portion of the sclerotic, just large enough to include the optic and ciliary nerves, is then removed through the opening in the globe and the end of the nerves amputated. After all hemorrhage has ceased, a fenestrated metal ball,

the largest size that can possibly be accommodated, is introduced. The edges of the wound in the sclerotic are closed with catgut sutures, which are covered by the conjunctiva being drawn over them and sutured with black silk.

"The local reaction is comparatively slight. The cornea soon loses its characteristics and becomes lustreless and opaque. In about six or eight weeks after the operation the cornea is tattooed so as to resemble as nearly as possible a normal eye—i. e., the center of the cornea black to resemble a pupil, and around this circle of such color as may harmonize with that of the iris of the other eye.

"The results have been fairly satisfactory and have encouraged the hope that it may be possible to remove as much as may be necessary in an offending organ and yet retain a fairly presentable eye without the necessity or inconvenience of wearing an artificial shell. In size the globe decreases a little. The sclerotic remains slightly congested for a time, giving the appearance of an inflamed eye. Subsequent enucleation has shown that the interior of the metal sphere became filled with new tissue entering in through the opening in the posterior part of the sclerotic and through the fenestræ of the metal ball."

Nicati (*Arch. d'Ophtal.*, June, 1903, p. 347) proposed an operation which is quite similar in its process to that of Huizinga. It is called "partial ablation of the ocular globe by the process of sub-enucleation." He operates as follows: "A horizontal or vertical incision is made into the conjunctiva on the inner side of the globe. The adductor muscle is seized, divided through its tendon and guarded by a catgut suture which is passed through the tendon and the conjunctiva. The capsule is separated above and below and the optic nerve is sectioned in the ordinary manner. The posterior pole of the eyeball is seized with a tenaculum and is drawn forward. It is separated from the oblique muscles and is drawn through the conjunctival opening, after which the posterior portion of the globe is exsected up to the insertion of the rectus muscles. The conjunctival opening is closed, and the tendon of the internal rectus muscle is secured. An accumulation of blood back of the cornea forces the eyeball forward but this, he says, is removed by compression.

"Convalescence is more rapid than in total enucleation, and the results are an excellent stump with the conjunctiva entire.

"Sympathetic ophthalmitis is avoided, the anatomo-pathologic collectors alone being the losers."

L. Müller, in 1908, practised a similar operation.

Nicati's statement should not be allowed to pass unchallenged, as sympathetic ophthalmia is not always averted, as evidenced by cases

cited by Trousseau and Rohmer in 1893, Pflüger, Clausen, Schweigger, Krones, and others, after the performance of this operation.

When for any reason *closure of the conjunctival sac* seems desirable, Macnab (*Trans. Ophth. Soc. United Kingdom.* Vol. 33, p. 50) incises each lid, on its outer aspect, down to the tarsus, beginning at the junction of the inner fourth and the outer three-fourths and extending to the external tarsal ligament. The external ligament is cut with scissors, and the two incisions joined at one stroke. Drawing the edges of the lids together with the tarsal plates, towards the nose, the conjunctiva is separated from the orbital tissues. The whole mass, consisting of lid margins, conjunctiva, and tarsal plates, is divided at the external canthus. The orbit is then closed by four catgut sutures which pick up the tissues at the bottom of the wound.

TRANSPLANTATION OF ANIMALS' EYES INTO HUMAN SOCKETS.

The transplantation of a rabbit's eye into the human orbit has up to the present time resulted in little more than the exploitation of a surgical curiosity, but extending some slight encouragement for future investigation. While a few experiments have produced movable, and more or less prominent, stumps by such procedures, no case has as yet been reported where vision has been produced and in the very nature of things it is exceedingly improbable that such a result will ever be attained. It must be mentioned, however, that S. Zervos, (*Grèce Médicale*, Vol. XII, No. 1 and 2, 1909) narrates some wonderful results in transplanting testicles, kidneys, spleens and eyeballs from one animal to another. He claims that eyes from young animals can be successfully transplanted and that they will resume their functions. Certainly, further proof is necessary before such astounding claims will be accepted. It is difficult to see how the stump-producing results of these experiments are really superior to a well-performed enucleation, where the muscles, conjunctiva, etc., are all sutured together, as described in earlier portions of this section, since under the most favorable circumstances the implanted eyeball shrinks to one-half or one-third of its original volume. The results certainly cannot be compared in their cosmetic quality to a Mules' operation.

Some operators merely adjust the rabbit's eyeball into the space just vacated by the human globe and attach the muscles, conjunctiva, etc., to the implanted sphere; others also unite the ends of the two optic nerves.

The first experiment was made by Chibret (*Bull. de l'Academie de Médécine de Paris*, May 28, 1885; also, *Révue Générale d'Ophtal.*, May 31, 1885) on a girl of seventeen years. He implanted a rabbit's eye by suturing the patient's conjunctiva to the rabbit's cornea. The

cornea, of course, sloughed, as might have been expected, and the operation was a failure. Terrien (Report to the *Société de Chir. of Paris,* 1885), a little later, reported another failure and Rohmer, still later in 1885, reported another. Bradford (*Boston Med. & Surg. Journ.,* Sept., 1885, p. 269), still later, reported a fourth case, which he claimed as successful. This operator united the two optic nerves, and the two conjunctivæ, as well as the muscles of the orbit to the implanted globe. The records of this case, however, disclosed the fact that within a year the cornea became opaque, wrinkled and sclerosed, and while no pain, inflammation or discharge was present, it was deemed best to remove the eye. Terrien followed Bradford's plan, but did not succeed.

May (*N. Y. Med. Record,* May 29, 1886, p. 613) performed a valuable series of experiments on 24 rabbits into whose sockets he implanted the eyeballs of other rabbits. He established the fact that the operation is entirely feasible, but whether it is profitable or not is quite another matter when we consider that the rabbit's eye is much smaller than the human eye and that after a successful operation it shrinks to from one-half to one-third its original size. May says that the tissues of the socket and the implanted eyes heal promptly and that muscular movement is evident in from 3 to 16 days. He had sloughing in 9 cases, but some kind of an eyeball was preserved in all cases; small in some and larger in others. He claimed that the optic nerves became united in all cases.

In 1901 Lagrange instituted some experiments in grafting a rabbit's eye into a human socket. He warns surgeons not to be influenced by Rohmer's failures as his technic was faulty, he having deposited the rabbit's eye into the human capsule of Tenon before bleeding had ceased. He used purse-string instead of interrupted sutures, with the rabbit and human muscles nicely approximated. He regards the following rules as essential to success: "1. That, as each rectus is cut, a thread be passed through it to prevent its retraction. 2. Following enucleation, that the eye be not inserted until all hemorrhage has ceased. 3. That an eye of a young rabbit be selected. 4. That the opposite muscles be drawn into apposition by appropriate sutures. 5. That the sutures in the conjunctiva be close together and be allowed to remain a week. 6. That the most careful antisepsis be carried out."

In 1905 Lagrange still further improved his technic, by protecting the cornea from those influences which favor its necrosis. His features of improvement are enumerated as follows: "The rabbit's eye is placed into Tenon's capsule with the cornea turned downward and

then the several muscles of the patient's eye are sutured to the posterior pole of the rabbit's eye. Rolling up of the muscles can be prevented by flattening them out. This method of implantation should not be used after enucleation on account of iridocyclitis and panophthalmitis, where the capsule of Tenon is implicated in the process. The implanted eye shrinks in the course of time, but there usually remains enough of a stump for the artificial eye to facilitate its mobility. Out of 11 cases observed, 8 showed a very good result. The longest time of observation was 4 years."

In 1907 Lagrange (*Arch. d'Ophtal.*, March, 1907, p. 150) modified his operation by placing the eye of the rabbit directly backwards, as the sclerotic is better able to withstand the pressure of the threads than the cornea.

Wicherkiewicz (*Pastep. Okulist.*, No. 7, 1908) reports the results of 35 implantations of the rabbit's eye, which he performed in his clinic. His conclusions are as follows: "1. The implanted and sutured eyeball becomes well attached to the straight muscles and acquires normal movements. 2. The course of healing, considering the operation, is comparatively short. 3. The connection of the implanted globe with the surrounding tissues is intimate, as, for instance, a recurrent neoplasm, not only the orbital tissues but the rabbit's eye itself grows fast. 4. In course of time the implanted globe becomes one-half or one-third the original size. 5. The older the subject the greater is the shrinking of the globe, which sometimes becomes so atrophic that it cannot be felt. 6. In no instance has the implantation given rise to sympathetic symptoms in the other eye."

From longer observation Wicherkiewicz is inclined to restrict this heteroplasty to children or young subjects, on account of the atrophy of the implanted globe. He followed the plan of Lagrange and advocated the turning of the cornea directly backward to protect the cornea, by keeping it warm and guarding it from outside influences. It was also found that in this position better motion could be obtained than if the eye was turned downward, as first proposed by Lagrange.

The writer of this section suggests that the cornea may be amply protected by placing it well forwards within the capsule of Tenon, and then uniting with catgut sutures the muscles of the patient to the stump of muscles left on the rabbit's eye. The undermined conjunctiva might then be sutured over the implanted eyeball.

Gifford operation for sightless stumps. Gifford (*Archives of Ophthalm.*, Vol. 31, No. 2) has suggested an operation for the protection of the cornea, in some sightless eye stumps, where the patient will not consent to an enucleation or evisceration, and yet desires to wear an

artificial eye but is deterred from so doing on account of a sensitive cornea. His remarks and directions for operating are as follows: "I believe that many sightless stumps are worth preserving, as they make the best possible support for an artificial eye; and as being entirely harmless if, after once becoming quiet, they can be kept from being infected. Where such a stump has any considerable amount of cornea left, this sometimes becomes irritated when an artificial eye is worn, and often drives the patient to the oculist with the request that the stump be removed in order that a shell may be worn with comfort. In another class of cases, the amount of cornea left is so small that it would not be irritated by the artificial eye, but having been penetrated either by an ulcer or a wound, bits of the iris tissue are exposed in the scar so as to become not only a source of irritation, but possibly of deep-seated and dangerous infection. In the third class, the eyeball may be quite natural-looking, but on account of its distorted nutrition, either from glaucoma or from some other cause which impairs the vitality of the corneal epithelium, it is subject to frequent attacks of corneal ulceration which render the ball a nuisance. In all of these cases I have been accustomed for the last six years to cover the cornea either with a conjunctival flap, a Thiersch flap, or an epithelial lip flap. Where, as in the majority of cases, conjunctiva is used, the membrane is excised around the lower half of the cornea for an area about 3-16 of an inch wide at the sides, and ⅛ inch below. Above this zone the membrane is dissected free from the globe as far as the upper fornix in the neighborhood of which a cross cut is made through the membrane to allow it to be slid down over the cornea without putting too much tension on it. Three sutures below are generally sufficient, but these should be put well into the episcleral tissue, nearly as deeply as in the advancement of one of the straight muscles. It may be asked why not accomplish the same thing by dissecting up the conjunctiva both above and below and sewing it together in a straight line across the center of the cornea. This is the method which first occurred to me and which I tried without success, both on men and rabbits. It proved to be practically impossible to bring enough raw surface from each side into contact to produce a firm union. As soon as the stitches came out, the conjunctiva slipped gradually back, leaving the cornea nearly as much exposed as before. This is the reason for putting the stitches into the episcleral tissue after denuding the sclera below the cornea. Unless this is done, the tension on the upper flap is apt to pull up the conjunctiva from below, so that the line of sutures lies across the cornea and firm union does not take place.

"Where, from any cause, the conjunctiva is atrophic and the space

for an artificial eye would be too much limited by the operation just described, I use an epithelial lip flap (i. e., a thin flap shaved from the lip with a razor), or a Thiersch flap. The conjunctiva having been dissected up for ⅛ of an inch around the cornea, and the cornea having been scraped (especial care being taken in the neighborhood of the limbus), the flap is spread out carefully over the cornea and tucked under the loose conjunctiva on all sides. It is well to bandage both eyes for twenty-four hours after these operations. I have used the Thiersch flap for this purpose only once, because, although it healed on perfectly, the accumulation of dead epidermis on its surface caused some irritation and I scraped the skin flap off and substituted a lip flap for it. I think, however, that the irritation could have been avoided if the patient had wiped off the dead epidermis once or twice a week (as I have since learned to teach other patients to do, where Thiersch flaps have been substituted for conjunctiva in other sorts of operations); and the ease with which larger Thiersch flaps can be obtained, inclines me to give them another trial where a nearly full-sized cornea requires to be covered.

"It should not be understood that I propose these operations as substitutes for evisceration or enucleation in actively infected globes. But rather in the class of cases in which the patient comes to the oculist with a perfectly quiet stump over which a shell cannot be worn on account of the irritation of the cornea; or on account of the danger of irritating and infecting exposed bits of iris tissue; or where the stump is irritable solely from the degeneration of the corneal epithelium, one or the other of these operations does excellent service in doing away with the necessity for a more radical operation and in preserving the best kind of support for an artificial eye. Moreover, it is readily accepted by some patients who will not consent to an evisceration or an enucleation."

Dianoux proposed, to avoid an enucleation, the following operation for hydrophthalmus: "The cornea is slowly cauterized in lines radiating from its center to the depth of two-thirds its thickness. A cone with a radius of 2 mm. is then formed in its center, the apex of which is perforated, allowing the aqueous humor to escape. A bismuth compress and bandage dressing are applied and retained for a period of three days, after which cleansing and bi-daily instillations of cocaine-eserin solutions, followed by the application of compress bandages, are practised for several weeks' time. If an excess of tension is observed, massage is employed twice daily. If necessary the operation may be repeated. Tattooing of the globe may increase the value of the method from an artistic standpoint."

Conclusions. Probably no operation will ever deprive some form of simple enucleation of its well deserved popularity. Other procedures, such as evisceration, Mules' operation, etc., are doubtless useful and desirable under certain conditions, but enucleation will probably ever remain a favorite with most surgeons. This must, almost necessarily, be the case since a large proportion of eyes requiring removal are suffering from some form of anterior ocular suppuration, when any procedure short of total extirpation is accompanied by more or less risk. Besides this, many cases of eyeball removal are necessitated on account of ocular or orbital tumors (especially when malignant) and this condition demands complete excision of the eyeball.

Again, when sympathetic ophthalmia is present or threatened, no operation is so reliable in its results as a complete enucleation. This statement is especially to be emphasized if two weeks or more have transpired since the original traumatism, as by that time dangerous extension may have occurred and any operation which does not sever the optic nerve as far back as possible may be insufficient to check the further progress of disease. If the injured eye is seen before two weeks have elapsed it may be regarded as safe to perform some other operation, such as evisceration or Mules' operation.

These and other pathological conditions, such as badly lacerated and excessively shrunken eyeballs, removable eyeballs in old people, etc., constitute a majority of the cases calling for some form of extirpation and it becomes quite apparent to an unbiased mind that enucleation is, and must remain, the most frequent of the operations that have been considered in this section.

In this connection it should likewise be said that the old-fashioned Ferrall or Bonnet operation, in which no effort is made to preserve muscular activity of the stump, so generally done now and in the past, should be employed with much less frequency in the future. Some operation in which the conjunctiva, capsule and muscles are sutured together for the purpose of producing a prominent and movable bed upon which a well-selected artificial eye may rest and move is the operation of election. The Ferrall or Bonnet operation will probably always have a place in ophthalmic surgery, especially when a severe orbital infection calls for open drainage and when malignant orbital tumors require thorough orbital exenteration, but in practically all other cases every structure possible should be preserved. In selecting an operation where muscular activity of the stump is preserved, one of the procedures heretofore described, where the muscles are firmly secured, before tenotomy is performed, should be chosen, for if the muscle is cut and allowed to shrink into the socket, it is difficult to

pick it out from the surrounding tissue and secure it with a suture.

Evisceration is particularly applicable to those cases of ocular or orbital suppuration that have extended into the posterior portion of the globe or have invaded the orbital tissues. Most operators perform enucleation even under these circumstances, but statistical warnings render this operation open to criticism.

Mules' operation may be done except in cases of ocular or orbital suppuration, sympathetic ophthalmia, malignant tumors and badly lacerated or shrunken eyeballs. Great care should be exercised to eviscerate thoroughly the ocular contents, purify the internal scleral walls, select a sufficiently small glass or gold globe and to suture thoroughly the scleral opening.

The implantation operations of Frost, Lang, Morton and Oliver are indicated wherever Mules' operation is applicable; also in much lacerated and shrunken eyeballs, possibly, also, in sympathetic ophthalmia.

Further experiments in the implantation of fatty tissue should be encouraged.

The delayed implantation operation of Fox may be used in any orbit where an improved bed for a prothesis is desired and where sufficient tissue is present to render the procedure possible.

If optico-ciliary neurotomy or neurectomy is useful it is in painful, sightless, glaucomatous eyes, and for sightless eyes where a chronic, non-traumatic iridocyclitis is present.

If abscission or complete keratectomy is ever justified, it is in patients with anterior staphyloma, especially in children.—(F. A.)

Enucleationsscheere. (G.) Enucleation scissors.

Enucleation, Thyroid. See **Exophthalmic goitre.**

Enucleator. (L.) An instrument used in the operation of enucleation.

Enucléer. (F.) To enucleate.

Envahissement. (F.) Invasion.

Envie. (F.) A birth-mark.

Enzymol. This is a trade name given by Fairchild Bros. & Foster to a "purified solution of the proteolytic enzyme," obtained direct from the stomach glands. As marketed it has an agreeable odor and flavor. It digests or converts purulent material into a soluble form which, in turn, is readily removed by irrigation. J. H. James believes that, injected into the sac in cases of dacryocystitis, this remedy is very efficient and, in some cases, can be relied upon entirely.

H. M. Lokey uses the following prescription as a part of his treatment of eczematous blepharitis: Acid. carbolic., gr. ii; Sol. adrenalin. chlorid., m. xxx; Enzymol ad. fl. ℥i. To be applied to the lids with

a cotton swab. H. D. Bruns advises the use of this agent in cleansing infected ulcers. He uses a 50 per cent. solution and employs it, also, as an antiseptic wash for disinfecting the lachrymal sac, as well as the whole conjunctiva.

Eosin. Tetrabromfluorescein, $C_{20}H_8Br_4O_5$, a 4-atom bromine substitution product of fluorescein; a brownish-red powder which crystallizes from its solution in acetic acid in yellow prisms. It is a well-known staining agent in microscopy.

A common stain in which eosin is used is that of Fischer—a one per cent. solution of the agent in water. For staining purposes this solution may be diluted from three to five times with water. 1. Place the section in the diluted stain for from three to five minutes; in some instances one minute will suffice. 2. Wash in water for a few minutes. 3. Dehydrate the sections in alcohol of 95 per cent. strength. If the section should have been overstained it may be left in 70 per cent. strength alcohol until the excess of the eosin has been extracted. One per cent. strength eosin in 90 per cent. strength alcohol may also be employed. Stain the same as above with the exception that the specimen is transferred from the stain directly to alcohol.—(J. M. B.)

Eosinophile. In bacteriology and histology this term is applied to microbes or histologic elements showing a peculiar affinity for eosin-stain. See **Bacteriology of the eye.**

Epacme. (F.) Strength; force.

Epaississement. (F.) A thickening.

Epalpebratus. (L.) Without eyelids.

Epanastema. (L.) An old term for the caruncle.

Epanesis. (L.) A remission or abatement (of a disease).

Epanouissement. (F.) The branching of arteries.

Epars. (F.) Scattered; dispersed.

Eperon. (F.) Folds in the internal coats of arteries.

Ephedra distachya. (L.) A species of plant whose astringent fruit and aments are used in diarrhea and leucorrhea and occasionally in conjunctivitis.

Ephedra vulgaris. This is the name of the plant from which the mydriatic alkaloid ephedrin is obtained.

Ephedrin. $C_{10}H_{15}NO$. This is an alkaloid possessing mydriatic powers obtained from a Japanese plant, *Ephedra vulgaris.* As the hydrochloride it occurs in colorless, crystalline needles easily soluble in water, less soluble in alcohol. When used in a 2 per cent. solution one or two drops produces almost complete mydriasis in a normal eye after fifty minutes. The pupillary expansion lasts about twelve hours. It produces very little cycloplegia and no increase of tension. Com-

bined with homatropin it forms a useful mydriatic, called by Merck *mydrin* (q. v.). Groenouw says that it increases sufficiently the cycloplegic quality of homatropin as to make the mixture a reliable cycloplegic in refraction work. He uses the following: Ephedrin. hydrochlor., 1.0 gm.; Homatropin., 0.01 gm.; Aquæ dest. 10.0 c. c.

Probably the cycloplegia induced by this mixture is mostly due to the homatropin. The N. D. describes the mydriasis as lasting about as long as that produced by atropine; homatropin must have been meant.

Ephedrin. (Pseudo-). PSEUDOEPHEDRINE. This alkaloid must not be confused with ephedrin (q. v.); it is obtained from *Ephedra vulgaris* and is found as colorless crystals insoluble in water. The hydrochloride forms yellowish crystals quite soluble in water and as 10 to 12 per cent. solutions acts promptly as a mydriatic without disturbance of accommodation or refraction.

Epheliden der Lider. (G.) Freckles of the lids.

Ephelotes. (L.) An ancient name for corneal leucoma.

Ephialtes. In Greco-Roman mythology, one of the giants that warred against the gods. His left eye was destroyed by Apollo, his right by Hercules.—(T. H. S.)

Ephidrosis. An excessive secretion of the sudoriparous glands of the upper lid. When the secretion of the sweat glands is excessive it may call for treatment. For example, as the condition is sometimes due to a spinal affection, that should be first considered. The local applications indicated in these cases are penciling with a 2 to 3 per cent. of nitrate of silver, combined with the use of a simple salve containing glycerin.

Ephidrosis cruenta. HEMATIDROSIS. Bloody sweat.

Epiblepharon. A name given by von Ammon to a dystrophy of the lid-skin, with ptosis. Also, a synonym of epicanthus.

Epibulbar. Resting on, or overlying, the eyeball. Situated upon the exterior of the eyeball.

Epibulbäre Geschwülste. (G.) Tumors of the eyeball.

Epibulbar tumors. See **Tumors, Epibulbar.**

Epicanthus. EPICANTHIS. Epicanthus is a congenital deformity in which a fold of skin, with its concavity lateralwards, extends from the side of the nose and partly covers the inner canthus. A similar fold of skin at the outer commissure has been described as *external epicanthis.*

In the Mongolian races a slight degree of epicanthus is naturally present, giving to these people their characteristic expression about the eyes. In the Caucasian race, it constitutes a deformity that may

require operation for its correction. It is frequently associated with other deformed conditions, such as ptosis, ankyloblepharon, convergent strabismus, microphthalmus, etc.

The condition may also be hereditary and has been reported as occurring in several generations of the same family. See, also, **Congenital anomalies.**

A mild degree of epicanthus is frequently seen in young children, which may be regarded as temporary, for it disappears with the development of the bridge of the nose. It is unwise, therefore, to operate on very young persons, or until it has been made clear that the condition will not disappear of itself. If with the subsequent growth of the child the condition persists, one of the following operations for its correction may be practised.

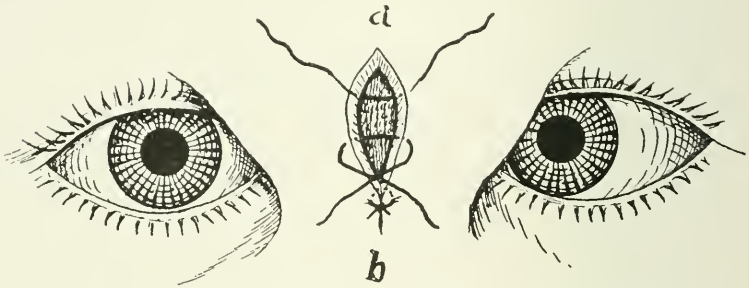

von Ammon's Operation for Epicanthus. (Rhinorraphy.)
Fold of skin, a, b, on the bridge of the nose removed, and the wound brought together with sutures. (*Encyclopédie Franç. d'Ophtal.*, Vol. IX.)

The fact that by pinching up a vertical fold of skin on the nose the deformity will disappear suggested the operation, called by von Ammon (*Zeitschr. f. Ophthal.*, 1831, Vol. I, pt. 4, p. 533; also, *Zeitschr. f. Augenheilk. u. Chirurgie*, 1839, Vol. II, p. 110) "rhinorraphy." (See the figure.) He pinched up a fold of skin on the bridge of the nose sufficient to uncover the inner canthus, marked out the line of incision with ink and then excised an oval piece of skin. Von Ammon brought the lips of the wound together with surgical pins, around which were placed figure-of-eight sutures, but in place of these the wound can be directly closed with silk or silk-worm-gut sutures. The resulting scar is a linear one and not very noticeable if healing by primary union follows.

Knapp (*Archiv f. Augen. u. Ohrenheilk.*, Vol. III, 1, p. 59) modified this procedure by cutting out a rhomboidal or diamond-shaped piece of skin; and, to facilitate movement of the skin flaps, he undermined

them in order to have less tension on the sutures which closed the wound. Further support was given by the use of a collodion dressing.

Kuhnt (*Zeitschr. f. Augenheilk.*, 1899, Vol. II, p. 169) modifies the von Ammon method in the following manner: He marks out the oval piece of skin on the bridge of the nose and forehead, but does not excise it, merely abrading it by removing the superficial layers of the skin with a sharp scalpel. He also loosens the skin flaps from the periosteum by a subcutaneous dissection, to enable them to move more freely, and then brings the edges of the abraded area together with sutures. In this way the skin is folded on itself, thus giving a fuller form to the bridge of the nose. To prevent the sutures from cutting

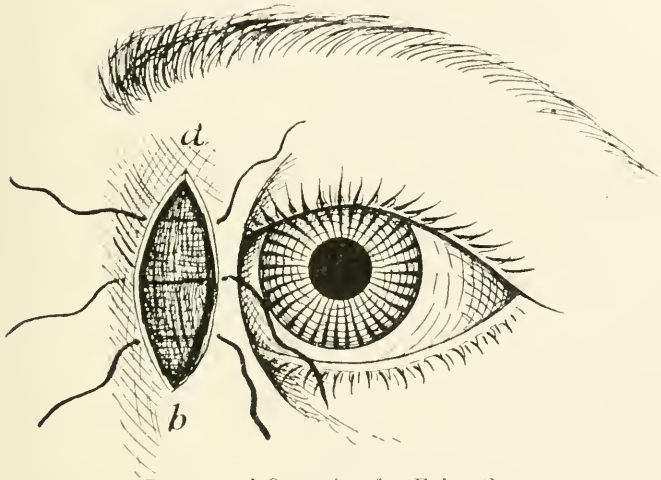

Desmarres' Operation for Epicanthus.

An oval piece of skin, a, b, is excised from the side of the nose, and the wound closed with sutures. (*Encyclopédie Franç. d'Ophtal.*, Vol. IX.)

out before union has taken place, several silver wires are placed across at the base of the wound, to reinforce the skin sutures.

Arlt (Graefe-Saemisch *Handbuch der gesamten Augenheilk.*, Vol. III, p. 443), to avoid the scar on the bridge of the nose that follows as a result of the von Ammon method, suggested removing a rhomboidal or diamond-shaped piece of skin from the side of the nose and the fold of the epicanthus. The long axis is vertical and the wound is of such width that when its edges are brought together by three or four sutures, the fold can be drawn from the inner canthus.

Desmarres (*Traité d'ophtalmologie*, p. 474) followed the same method of excising a piece of skin from the side of the nose and the fold itself. He removed an oval piece of skin, with its long axis vertical

and of a suitable width, uniting the edges with sutures. (See the figure.)

Instead of excising an ellipse of skin from the side of the nose Berger (*Archives d'Ophtal.*, 1898, Vol. XVIII, p. 453) removes a piece in form somewhat like a triangle, with its base toward the eye and broken by a re-entering angle, as shown in the accompanying figure. An incision is made from the upper part of the fold to a point on the nose in a horizontal line with the inner canthus. This is joined by an incision from the lower part of the fold to the same point on the nose,

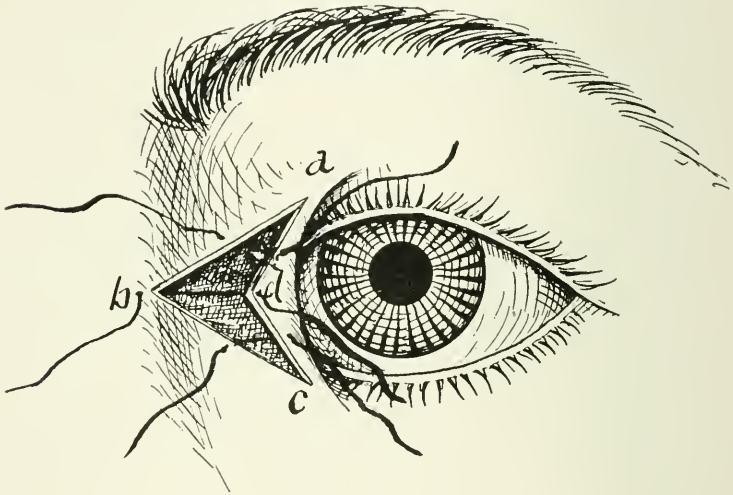

Berger's Operation for Epicanthus.

The incision, a, b, from the upper part of the fold is joined by incision, c, b. Two other incisions, a, d, and c, d, mark out the area of skin, a, b, c, d, which is then excised. The defect is closed by sutures, as indicated.

making a V-incision with its apex on the side of the nose. From the ends of this incision two others are made that converge at greater angle than the preceding, and thus mark out a trapezoidal area of skin, a, b, c, d, which is then excised. When opposite points of this denuded area are united by sutures, the fold forming the epicanthus is drawn toward the nose. In this way the center of the fold is drawn upon more than its upper and lower parts.

The account of this procedure, which is the same as that of Berger, was presented at the Ninth International Congress of Ophthalmology held at Utrecht in 1889.

The operation of Berger and Wicherkiewicz (*Congrès internat. d'Ophtal. d'Utrecht*, 1899. Comptes rendus, p. 583) is one of the best for this deformity since, by varying the length of the incisions and the amount of tissue excised, the fold can be drawn up at those points where it is most needed. The resulting scar may be well concealed by the mountings of a spectacle or an eye-glass.

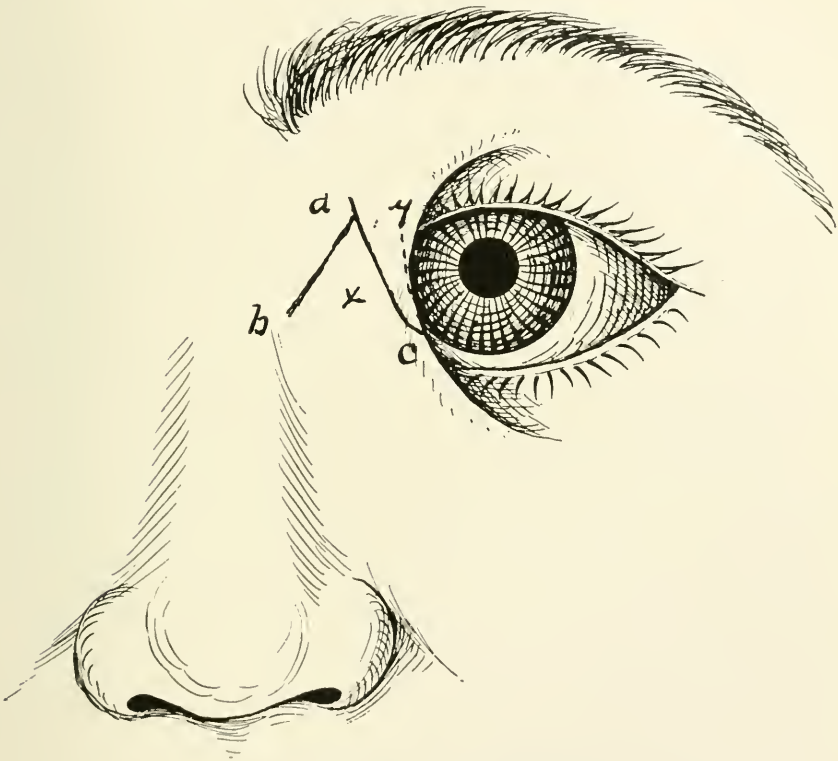

Rogman's Operation for Epicanthus.

Incisions, b, a, and a, c, mark out the inverted V-shaped flap, x, on the side of the nose.

The lateral incision, a, c, is prolonged to the edge of the fold, then directed upward on the ocular side of it (as indicated by the dotted line) forming an erect V-shaped flap, y, the apex of which is at c, on the edge of the fold.

Flaps x and y are then transposed, and c is fixed at b.

Instead of excising any tissue Rogman (*Annales d'Oculist.*, 1904, Vol. CXXXI, p. 464) transposes flaps that are made in the fold of the epicanthus in the following manner: Between the semilunar border of the fold and the median line of the nose a cutaneous flap is cut in the form of an inverted V. (See figure, a). The lower ends of the incisions that form this flap extend downward about to the level

of the internal angle of the lids. The lateral incision, a, c, is now prolonged to the edge of the fold, then is directed upward on the ocular side of it in such a manner as to form a second V-shaped flap, the apex of which is downward in this case and at a point on the border of the fold of the epicanthus. There are thus marked out two flaps x and y, the size of which must be proportioned to the degree of subtraction of the skin in the horizontal line that will be necessary to correct the deformity.

After these flaps have been sufficiently freed from the underlying tissues they are transposed and fixed in place with small sutures. This brings the apex of flap y to a point on the side of the nose.

The advantages claimed for this operation are that there is less tension on the sutures, so that primary union is more certainly obtained; and that the effect can be modified at the time of operation by trimming the flaps more or less as may be found necessary. It is also said to be more suitable for cases of cicatricial epicanthus than operations of the von Ammon class.

In marked forms of epicanthus there is a tightness of the skin over the bridge of the nose that is thought by Foggin to be a factor in preventing proper development of the bones of this part. This he relieves by the following procedure.

Foggin's operation for epicanthus—With a narrow cataract knife, the tissues on either side of the nose are separated from the periosteum subcutaneously, the knife entering the skin at a point above the bridge of the nose and between the eyebrows. This subcutaneous dissection is done sufficiently to allow a fold of skin to be drawn up to form a considerable nosebridge. Sutures are then passed through this fold, from side to side, and tied in the holes of specially-shaped lead plates that fit on the sides of the nose and thus hold up the fold of skin that forms the new bridge until it has become fixed.

Within recent years many operators have abandoned operations of this class to make use of subcutaneous injections of hard paraffin for the correction of epicanthus, as well as of other deformities of the nose. —(W. H. W.)

Epicanto. (It.) Epicanthus.

Epicauma. (L.) (Obs.) A caustic; a superficial burn; a phlyctenule of the cornea; a gangrenous inflammation of the eyelids.

Epicaume. (F.) Phlyctenule on the cornea.

Epichnus. (L.) An ancient term applied by Hippocrates to a wool-like accumulation on the eye.

Epicœlides. (L.) An old term for the upper eyelid, and afterwards for the eyelashes.

Epicranial. Pertaining to the epicranium or the upper part of the skull.

Epicrasis. (L.) An old term for alterative treatment.

Epicrisis. (L.) A conclusion as to the character, probable termination, etc., of a disease; concluding critical remarks in a clinical history or an essay.

Epicritic nerves. A term applied by Head (*Brain*, Vol. 29, 1906) to a certain class of sensory nerves.

Epicurus. The founder of the Epicurean school of philosophy, and a speculator concerning vision and the nature of light. He was born in 342 or 341 B. C. His early years were passed at Samos and at Teos. He taught for a short time at Mitylene and Lampsacus, then for thirty-six years at Athens.

His theory of vision was that rays of light proceed from the eye (not the object) and, securing visual information, return therewith to the crystalline lens. Here the "soul" was supposed to receive the information.—(T. H. S.)

Epicylis. EPICYLIUM. (L.) An upper eyelid.

Epidemic conjunctivitis. EPIDEMIC OPHTHALMIA. This term is generally applied to the Koch-Weeks conjunctivitis or "pink-eye." See page 3089, Vol. 4, of this *Encyclopedia;* also, **Bacteriology of the eye.**

Epidémie. (F.) Epidemic.

Epidermic grafts. This term is generally applied to Reverdin's method of skin-grafting, an account of which is given under **Blepharoplasty.**

Epidermoid cysts. This term is generally applied to formations in the iris. They have the appearance of small seed-pearls, grow very slowly and may originate in any part of the iris. See **Tumors of the eye**; as well as **Iris, Cysts of the.**

Epidermolysis bullosa, Ocular lesions of. This rare disease is occasionally associated with eye symptoms. A case is described by de Schweinitz (*Sec. on Oph., Coll. Phys., Phila.*, Feb. 1913) in a man fifty years of age, who for sixteen years had been subject to attacks of bleb formation in the right eye, always appearing in the early morning and lasting several hours. There may have been some dependence on an ethmoiditis in this case. The writer compared the change in the form of the basal cells as a determining factor in the loosening of the epithelium from Bowman's membrane, following a probable local irritation and forcing beneath it of fluid, to the changes found in the skin lesions of this disease, where there is a degeneration, detaching the loosely fastened rete, thus giving rise to bleb formation. Treatment was unsatisfactory.

Epidiascope. A projection apparatus arranged for ordinary lantern slides, and also for opaque objects; a combined magic lantern and episcope.

Epilation. The act of extracting hairs by the roots. This procedure is generally employed to remove "wild" or abnormally placed eyelashes the result of trachoma, after operations on or injury to the lid edges, etc. The misplaced hairs are sometimes so fine and so light-colored that a careful search with good illumination and the aid of a lens is necessary to discover them. If epilation is practised the hair is seized near its base with cilia forceps and gently drawn (not jerked) in the direction of the shaft. Cilia forceps, as manufactured by most instrument makers, are ordinarily very imperfect, and many of them are quite useless for the purpose for which they are intended. The opposing surfaces at the ends of the blades should come into perfect apposition, otherwise fine hairs will not be caught. In selecting such an instrument one should subject it to the test of holding it up to a light with the blades closed, and noting whether any light can be seen between the apposed surfaces at the ends of the blades. Too frequently it will be found that the surfaces come into actual contact at one small point only.

Even after proper epilation, however, it is only a matter of time until the hairs grow again, so that it is much better to destroy the hair follicles by means of electrolysis (q. v.).

Epilepsy, Ocular relations of. According to D'Orsay Hecht (Wood's *System of Ophthalmic Therapeutics*, p. 359) the symptoms arising in the course of an epileptic attack have to do with abnormal changes in consciousness and motility. This being true, the clinical manifestations are of necessity either mental or physical, or both. Their wide range and great variability make it difficult and on the whole unsatisfactory to formulate a brief or accurate definition of the disease, but the one suggested by Spratling seems very acceptable: "Epilepsy is a disease or disorder affecting the brain, characterized by recurrent paroxysms, which are abrupt in appearance, variable in duration, but generally short, and in which there is impairment or loss of consciousness, together with impairment or loss of motor co-ordination with or without convulsions."

The ocular symptoms of epilepsy are manifest (1) as a part or whole of an aura, when they are purely visual and entirely subjective; (2) during the first stage of the fit, when we note variable forced deviations of the eyes and transitory pupillary changes; (3) in a post-convulsive period there may appear conjunctival hemorrhages; (4) strabismus, nystagmus and diplopia are reported as occasional sequelæ.

Conceding the undoubted influence of heredity in the transmission of epilepsy, the physician is not infrequently called upon to advise as to the feasibility of marriage where one of the contracting parties is epileptic or is known to have had epileptic antecedents. The particular emotions that find their best solution in matrimony are usually too intense to be dominated by much medical guidance, but it is none the less incumbent upon a conscientious physician to discourage such marriages. The marital relation of epileptics cannot of itself be said to modify the type or course of the disease, but in the matter of procreation the danger lies, and who that has seen the blight of epilepsy upon a child would sanction a union in which distinct heredity is acknowledged to and evident? It is not easy, however, to give advice to that class of cases in which epileptic or epileptoid phenomena have occurred somewhat later than in the infantile period, in the absence of referable cause or hereditary taint. Here, after a careful survey of the facts and a frank statement by the physician of the possibilities (however remote), the final disposition must rest entirely with those chiefly interested. Neither the wisdom nor justice of such legislation as has been enacted for the control of epilepsy need receive comment here.

The prompt recognition of the mental, moral and physical needs of the neuropathic child and the institution of such medico-pedagogic measures as will toughen its physical and psychic fiber is a firm step made in the direction of effective prophylaxis. A predisposed child should not be made to enter school or embrace any competitive opportunities until quite equal to the exertions requisite thereto. A combination of school and sanatorium in a quiet, rural environment, where selective study and an equable division of work and play (especially outdoor) is planned, should prove most beneficial for neuro- or psychopathic types. Especially desirable is it to tide such a child well over the trying period of pubescence. After that, good hygiene and a wise general supervision in the adolescent years will accomplish much.

The convulsive seizure of infants, so readily ascribed to teething, intestinal worms or "mere fever," is all too lightly regarded and inadequately treated at the time of first occurrence. "I incline," says Hecht, "to the belief that it required but very little irritation to a supersensitive or superexcitable group of cerebral cortical cells, to promptly establish a tendency to convulsions which in later years become frankly epileptic. The timely exhibition (at the occurrence of the first seizure in infancy) of very small doses of sodium bromide, gr. i to ii, with or without chloral, gr. i, in emulsion, given per rectum, and repeated for some days at a time, may do much to avert subsequent

cerebral explosions. Better therapeutic observance of night terrors, bed-wetting, fits of uncontrolled temper, and perverse headaches will also reduce the incidence favoring later epilepsy.

"The mental and physical development of an epileptic should not be undertaken contingent upon epilepsy *per se*, as is so often the case, but upon the individual who has epilepsy in one or another form and degree. Instruction and exercise must not be denied him on general principle, but be nicely proportioned and so adjusted as to meet his capacity as an individual epileptic. Too often is the epileptic asked to conform to general advice and told indifferently to live a life of so and so. Not sufficient regard is shown for those personal attributes of mind and body, which, when painstakingly directed, enable the sufferer to pursue a day's work with greater happiness to self and better service to the community at large. Educate epileptics according to their mental qualifications and physical powers, providing them with graded instruction that is manual, rather than purely intellectual, in well equipped special institutions, or arrange for their private tuition. In the early stages of this disease mentality is hardly ever disturbed, much less impaired, hence asylum treatment is to be discountenanced. If confinement be at all desirable, special hospital wards, set aside for epileptic cases only, should be provided. This method of treating in seclusion the early and advanced cases alike has proven very satisfactory and led to a now quite universally approved and adopted plan of outdoor colonization for the epileptic. A systematic outdoor life, giving preference to light, open air occupation, together with enough study and reading to avert mental sluggishness, is what epileptics most need and should have.

"The food prescribed for epileptics should fulfill the conditions of being non-irritating, easily digestible and nutritious, but in all other respects adapted to the particular needs of the individual patient. There are those who have seen fit to advocate a rigid vegetarian diet, deprecating meat of all kinds, while others again suggest meat in great moderation and altogether interdict red meat. I have not been able to note the favorable influence of specialization in diet.

"The success with which food is assimilated depends quite as much upon the quantity as the quality of the meal, hence moderation in eating is of great importance. Patients must avoid alcohol in any form and take coffee or tea but sparingly. Tobacco in moderation does no harm. Constipation is to be avoided. When the occurrence of epileptic phenomena can be brought into direct causal relation with some underlying pathology, such as brain syphilis, tumor or cerebral arteriosclerosis, these conditions then require appropriate treatment

before one may hope to control the seizures. Unfortunately, the sources of epilepsy commonly referred to as peripheral are not discovered, and the treatment from beginning to end remains purely symptomatic.

"The neurologic version of the relation of eye strain to epilepsy is quite at variance with the one firmly held to by some ophthalmologists. Gould has written extensively in support of his belief that epilepsy is not infrequently cured by the relief of eye strain, accomplished with properly fitting glasses. Ramey and Stevens, also impressed with the factor of eye strain, believe that muscle imbalance corrected by operation, cures epilepsy. The report of a most careful and scientific investigation made by Gould and Bennett, on 78 epileptics at the Craig Colony, in 1902, to ascertain the facts is interesting, but it is recorded that no relief followed. The premises for the experiments were most favorable. The diagnoses were made by Gould and Bennett, the glasses carefully fitted by an expert optician, and the cases subsequently observed daily by a physician, who could reassure himself that the glasses were constantly worn. A record of all epileptic attacks occurring day and night in these cases was kept for one year, and it is conclusively proven from this series that the 31 males who had 766 seizures during three months prior to wearing glasses had 765 in the first three months after, and 1,332 during the first six months after; that in similar intervals 33 females had 670 before, and 592 and 1,426 attacks respectively after. The negative character of the results embodied in this tabulated report would tend to discredit any theory that eye strain could initiate or by its presence aggravate epileptic seizures.

"Since their introduction some fifty years ago the bromides in one combination or another have been a sovereign remedy for the control of the epileptic fit. In the majority of cases, either potassium, sodium, strontium, ammonium bromide singly or together, are capable of diminishing the seizures in frequency and intensity, but there is very little likelihood of their complete arrest. To achieve results with bromides, they must be taken in adequate doses for a continuous period of time, and then at the risk of developing symptoms of bromism, viz., widespread acne and marked cerebral depression. It is well to be conservative in prescribing the initial dose of bromide, being careful to test it out and give no more than is needed to control the attacks. The best time for administration will depend largely upon the periodicity of attacks. Bromides are best taken an hour after meals, with large dilutions of water. Observation in each case will alone determine the dosage, which in adults may vary from fifteen grains to sixty grains, three times daily, but it is highly improbable that these doses can be maintained without evidence of bromism.

"The prevention of bromism is desirable, and to this end active elimination through kidneys, bowels and skin is encouraged. Liquor potassi arsenitis (Fowler's solution), two to five drops, added to each dose of bromide, will lessen the liability to the widespread acneiform skin eruption. During an attack, the patient, if he has fallen in an uncomfortable or dangerous position, should be moved to safety, and all neck clothing opened or removed to allow of free breathing. A cork, clothespin or knotted corner of a handkerchief may be shoved between the upper and lower teeth to prevent repeated tongue biting incidental to the clonic stage. Especially in the nocturnal types of epilepsy, when the force of a convulsion turns the patient face downward in the pillows, must suffocation be averted by the prompt intervention of someone near at hand. For status epilepticus inhalations of chloroform to the anesthetic degree are indicated.

"The opium treatment for 'fits' is as old as Paracelsus, but had been abandoned these many years, until Flechsig, in 1893, reintroduced it in combination with bromides, to be given in chronic cases, where bromide alone had failed. The plan is to mildly narcotize the patient for a month or so, beginning with small doses of opium, and increasing the same gradually until fifteen grains are taken daily. The sudden withdrawal of opium at this point, substituting 120 grains of bromide daily for two months, and gradually reducing that dose to twenty or thirty grains, constitutes Flechsig's method of administration. The majority of observers who have given this measure extended trial do not regard it with much favor. Borax (sodium borate) has been extensively employed by some, because of Gower's recommendation. In doses of from 10 to 30 grains, t. i. d., it may reduce the number of seizures in a few cases.

"Occasionally, in the senile or arterio-sclerotic cases, nitroglycerine, gr. 1-100, taken several times daily, is of service in lessening the attacks. It is hardly necessary to more than mention amylene hydrate, chloral, chloretone, tincture of belladonna, urethan, simulo and solanum carolinense among the many preparations that have been enlisted in the service of controlling epilepsy, and are of very doubtful value. It is premature to say much of the prospect of serotherapy in this disease, but thus far the results have been disappointing.

"There is no field for surgery in cases of essential epilepsy, nor have the prophecies concerning surgical achievement in the cases with a local exciting cause been fulfilled. In some traumatic cases where a sharply circumscribed lesion from depressed fracture or hemorrhage can be early diagnosed, prompt surgical interference may bring about the cessation of convulsions. When epilepsy is associated with irrita-

tion referable to the nasopharynx, eyes or ears, local improvement may ameliorate the symptoms, but tampering with normal ovaries, or performing hysterectomies, and maltreating the pelvic viscera and genitalia in general in a vain endeavor to cure epilepsy, are practices of which too much cannot be said in condemnation. The Jacksonian or symptomatic types of epilepsy, in which the etiology, focal symptoms and seizures point to some gross, circumscribed, accessible brain lesion, are regarded as suitable for surgical intervention, but it cannot be said that the results of operation are any too favorable. When a meningeal hemorrhage has occurred in a child, resulting in the cerebral type of palsy, the immediate exposure and removal of a circumscribed clot may perhaps prevent a subsequent palsy and seizure, but if scar tissue once has formed, it seems quite improbable that it can be excised without replacing it with an artificial (operative) scar, but little less inclined to cause convulsions than the original one."

According to Ball (*Modern Ophthalmology*, p. 789) this disease has no characteristic eye-symptoms, although few, if any, attacks of epileptic convulsions are unaccompanied by them more or less. The most frequent is visual aura—a subjective symptom elicited from the patient. He may describe it as a sensation of light, color, flames, or flashes. Visual aura is strongly indicative of organic trouble in the occipital lobe, especially if homonymous. Conjugate lateral deviation of the eyes to the opposite side of the body from that in which the convulsive movements began may occur at the beginning of an attack. The head inclines in the same direction. Later the eyes turn strongly in the opposite direction.

The action of the pupils during an attack is varied. They may be strongly contracted or widely dilated, or they may be both during the same attack. A rapidly changing pupil after an attack of unrecognized nature is diagnostic of epilepsy. Hippus has been observed. The ophthalmoscopic appearance of the fundus during a convulsion may be normal, or there may be extreme pallor of the disc with contraction of the vessels, or hyperemia of the disc with dilation of the vessels. Following the convulsion there is often a transient concentric narrowing of the field of vision and lowered acuity of vision. The contraction of the field of vision may become permanent after repeated attacks.

Subconjunctival ecchymosis and opacity of the lens or complete cataract following an epileptic seizure are to be regarded as accidents rather than as symptoms of the disease.

We have been considering epilepsy and its ocular symptoms as of organic origin, but it should also be considered as a reflex phenomenon due to an irritation the seat of which may be in the eye itself. An

error of refraction, especially one of high degree, or much astigmatism is sometimes the cause, and its correction may prevent or ameliorate the attacks. In the same manner the correction of muscular insufficiencies by advancements and tenotomies has effected cures, but the results have not been as brilliant as could be reasonably expected.

The eyes of epileptics have been studied by Rodiet, Pansier and Cans (*Rec. d'Ophtal.*, March, April, 1908), who find the permanent disturbances to be: pallor of the optic disk and retina, probably anemic; passive venous congestion of the fundus with a pale disk; often intense blackish pigmentation of retina and choroid; irregular contraction of the visual field; and, in cases of long duration, with frequently occurring attacks, optic neuritis or advanced gray atrophy. At the close of an attack there is likely to be corneal anesthesia and dilated pupils. Rodiet and Bricka (*Rec. d'Ophtal.*, September, 1908) report their observations on 2 cases of Jacksonian epilepsy, one showing optic atrophy due to meningitis, the other choked disk due to gumma.

Hubbell (*Trans. Sec. on Ophth.*, A. M. A., 1908) made a study of the relation of so-called ophthalmic migrain to epilepsy. Among more than 1,500 patients who suffered from migrain, careful questioning showed not one that had manifested epilepsy, or knew of its existence, either in ancestors or descendants. In the few epileptics subject to migrain, the attacks are entirely separate and independent, and the coexistence of the two diseases in a few patients does not prove a pathologic kinship.

A case is reported in which visual hallucinations, followed at times by epileptic seizures, was relieved by the correction of myopia with astigmia, with careful attention to hygiene and general treatment. Nearly ten years after the disappearance of the symptoms, the patient continued well, and hard at work in his profession, the law.

Hodskins and Moore (*Jour. Ophthal and Oto-Laryngol.*, May, 1908) reviewed earlier statistics bearing on the connection of eye-strain with epilepsy, and report the results of keeping 88 epileptics completely under the influence of atropin for one month, and comparing the average of seizures during that month with those of the four months preceding and the month following, when not under a cycloplegic. The average for the maximum month was 19.6, for the minimum month 6.1, for an average month 13.2, and for the month under atropin 12.6 per patient. They "firmly believe that the role played by ocular defects in the causation of epilepsy is a very modest one."

Kinderman (*Klin. Monatsbl. f. Augenh.*, March, 1909, p. 333) reports a case where three years after the removal of an eye for pain, a man developed epilepsy with visual aura. The stump of the nerve was

excised and a small piece of the sclera and choroid were found attached thereto. The attacks soon ceased permanently. The explanation offered is, that the epileptic attacks originated in irritation of a retained piece of retina, thus resembling cortical epilepsy.

E. R. Neeper reported (*Annals of Ophthalmology*, p. 620, July, 1912) the case of a man who had been subject to attacks of *grand mal* about thrice weekly, and who had been free from attacks so far for six weeks since receiving his refractive correction, with the exception of a slight seizure on the night of the day when he first wore the glasses. Twenty-two years previously he had been unconscious for several days after being struck with lightning. There had been attacks of vertigo for some time, after which no trouble was experienced till about four years ago, when the vertigo reappeared, occurring about once a month for a year. Later he fell on the street with the attacks of vertigo, and still later symptoms of *petit mal* appeared, to be followed by the liability to complete epileptic fits. The eyegrounds were normal, and the correction was about + 1.25 D. sph. ⌣ 0.75 D. cyl. with the rule in each eye. The patient's mentality appeared to be normal.

Epilepsy, Retinal. Epilepsy of the retina is a term applied by Hughlings Jackson to a condition of arterial spasm which occurs during epileptic attacks. He has seen the retinal blood-vessels suddenly disappear while the fundus was being examined ophthalmoscopically at the time of the seizure.

Parsons believes that the so-called retinal epilepsy is probably a complicated condition in which papillitis with distention of the retinal vessels plays a part.

Epileur. Epileuse. (F.) An attendant in a bathing establishment who extracts superfluous hairs.

Epimelium. (L.) (Obs.) A fatty tumor.

Epinephrin. This drug is a suprarenal gland derivative, resembling adrenaline. The hydrate, under the trade name of adrin (q. v.), is employed in the same manner and in the same dosage as suprarenin, suprarenaline and other adrenal extractives as a vaso-constrictor and hemostatic.

Epinephrin hydrate. See **Adrin.**

Epineurium. (L.) A name suggested by Key and Retzius for the general connective tissue of a nerve, exclusive of the perineurium and endoneurium.

Epinine. Synthetical suprarenaline, recommended for injections in conjunction with cocain in operations on the lids.

Epiocular. Epibulbar. Situated on the surface of the eyeball.

Epione. (F.) Any mucous membrane.

Epiopticon. In biology, a ganglionic swelling in the optic nerve of insects (Hickson).

Epiphanin reaction. A test for the detection of toxic agents in certain forms of intraocular disease. For example Kümmel (Graefe's *Archiv f. Ophth.*, Vol. 84, p. 440, 1912) has reported the examination of the serum of ten cases of sympathetic ophthalmia and plastic uveitis by means of the epiphanin reaction with about 30 per cent. positive results, independent of the character of the disease. Various normal eyes also gave positive results. Although he used better methods for preserving his serum antigens, still further refinements are necessary for the clinical success of the epiphanin reaction. Of further serological experiments—one injection of uveal tissue into the vitreous produced but little reaction, whereas a second injection resulted in a severe uveitis. A third injection, made intravenously, produced a very severe uveitis of about five days' duration, even though the eye had been quiet previously for months. Repeated injections, however, caused no further trouble.

Epiphora. This symptom is characterized by an overflow of tears. It is commonly differentiated from *lachrymation* by the fact that the latter is a more active condition, usually associated with inflammatory conditions or some irritation in the neighborhood of the lachrymal apparatus. Although a sign of many dissociated diseases it is a most troublesome symptom and one that often calls loudly for relief. It is commonly associated with stenosis of the lachrymo-nasal duct and dacryocystitis.

A proper study of this symptom can only be made in connection with diseases of the lachrymal apparatus. However, a few references to it *per se*, are given here.

Epiphora may be produced mechanically and reflexly through changes in the nose. Among the diseases that act mechanically are hypertrophies, crusts of dried up secretions, polyps, etc.; these act by obstructing the naso-lachrymal canal. When the inferior turbinal is closely attached to the concave wall of the lower meatus of the nose, the latter becomes very narrow and is easily obstructed by any swelling of the mucous membrane.

In quite a number of cases of epiphora Meyer (*Berlin Klin. Wochen.*, p. 751, 1906) has observed a peculiar form of the lower turbinated body. Its surface closely touched the lateral wall of the inferior meatus, thus obstructing the mouth of the naso-lachrymal duct, which lies about the middle point of the lower turbinated body. In 500 or 600 cases Meyer deflected the attachment of the lower turbinated body to the lateral wall by turning it 30° to 50° toward the septum with

Heymann's forceps, modified by Killian. The epiphora disappeared after two weeks.

Welleminsky (*Wiener Klin. Woch.*, No. 21, 1909) observes that if in idiopathic epiphora the anterior extremity of the middle turbinate be touched with a probe profuse lachrymation is excited; it will also be found that the mucous membrane of this region is not normal but hyperemic, edematous, hypertrophic, etc. He has found that a few scarifications will result in cure of the epiphora. Reinflet (*La Clin. Ophtal.*, p. 577, 1909) finds that simple epiphora without catarrh of the sac or dacryocystitis is quickly cured by simple dilatation of a canaliculus. In fact almost all strictures begin in that portion of the canal, particularly at its junction with the sac. If such treatment is not sufficient the canal is to be catheterized by number 2 or 3 probes without incising the canaliculus.

Dacryo-pericystitis is to be treated not by extirpation of the sac but by some method which destroys the pericystic pocket with conservation of the sac and re-establishment of drainage. Where there is true stricture or destruction of the nasal duct, and catheterization has not succeeded in re-establishing drainage by the nose, it may be necessary to arrest the secretion of tears; not by extirpation of the gland but by deep galvano-cauterization of the same in its parenchyma, respecting, as far as may be, the mucous membrane. Cauvin (*La Clin. Ophtal.*, p. 490, 1909) has employed fibrolysin (a soluble combination of thiosinamin) satisfactorily in simple inveterate epiphora, injected into the lachrymal canal in conjunction with catheterization.

Darier (*Ophthalmoscope*, July, 1909, p. 209) gives an account of different varieties of epiphora and the treatment appropriate to each. The congenital form, the simplest of all, is usually due to a collection of epithelial cells and mucus. A simple injection or even insufflation of air is frequently all that is required. Injections, probing, electrolysis, radium-covered sounds, extirpation of the palpebral and orbital glands, and finally extirpation of the sac, are the usual methods at our command. When the punctum is displaced or the canaliculi are occupied by calculi or concretions (streptothrix, actinomycosis) incision is necessary.

Epiphora arthritica. (L.) Epiphora dependent upon a narrowing of the punctum lacrimale caused by rheumatism.

Epiphora catarrhalis. (L.) Epiphora dependent upon a narrowing of the punctum lacrimale due to a catarrhal inflammation of the conjunctiva.

Epiphora dacryadenitide. (L.) Epiphora due to dacryocystitis.

Epiphora erethica. (L.) Epiphora due to the presence of an irritating substance.

Epiphora exanthematica. (L.) Epiphora occurring during an eruptive disease and dependent on the conjunctivitis caused by that disease.

Epiphora impetiginosa. (L.) Epiphora accompanying impetigo.

Epiphora intermittens. (L.) Epiphora appearing periodically.

Epiphora lacrimalis. (L.) The watery eye; a more or less constant overflow of tears upon the cheeks, due to eversion, tumefaction or narrowing of the puncta lacrimalia, or to stoppage of the nasal duct. In Young's classification of diseases, a genus of the *Apocenoses*. (Foster.)

Epiphora sanguinea. EPIPHORA SCORBUTICA. (L.) An increased secretion of tears mixed with blood. It occurs in scurvy.

Epiphora venerea. (L.) A form of epiphora which occurs in a stage of syphilis. The tissues about the punctum are thickened and swollen without an abnormal quantity of secretion.

Epipolic. Pertaining to fluorescence.

Epipolic dispersion. The decomposition of light that takes place at the surface of various substances, producing the phenomenon ordinarily called fluorescence.

Epipolism. Fluorescence.

Epirenin. One of the numerous imitations of adrenalin.

Episclera. The visceral layer, covering the eyeball, of Tenon's capsule.

Episcleritis. SUPERFICIAL SCLERITIS. This is a localized inflammation associated with an exudate into the episcleral tissue. The exudation causes a protuberance, which is usually rounded or flat and is situated at a distance of several millimetres from the cornea. The mass is attached to the sclera, and the conjunctiva can be moved over it. Two kinds of injection are visible in a case of episcleritis: a superficial hyperemia of the conjunctiva, and a deeply-placed, violet-colored injection from the episcleral vessels. The eye is red only in the neighborhood of the nodule, which is hard and, if it enmeshes one of the ciliary nerves, is acutely sensitive to the touch. The subjective symptoms in episcleritis may be mild or severe, but the course of the disease is subacute or chronic. In some cases photophobia, lachrymation, and a dull, heavy pain are symptoms. After several weeks the affection usually disappears, the nodule is absorbed, and either no trace is left or a slate-colored patch remains to mark the site. In some cases other nodules form until the entire circumcorneal zone is involved. A characteristic feature of the disease is the tendency to recurrence, either in the old site or elsewhere. The process may persist for months

or even years. The inflamed patch frequently resembles phlyctenular conjunctivitis, with which it may be confounded. Although, as a rule, the cornea is unaffected in episcleritis, if the nodule is located near the cornea, an infiltration of the latter may occur during the height of the disease. Iritis is rarely a complication. Both eyes may be involved in episcleritis.

The etiology of episcleritis is somewhat obscure, although it undoubtedly can be attributed to gout or rheumatism in some cases. Exposure to cold, menstrual derangement, and scrofula are supposed causes. Syphilis and tuberculosis are rarely etiologic factors.

In episcleritis the conjunctiva, the episcleral tissue, and the superficial scleral layers are involved. The conjunctiva is hyperemic and the episcleral tissue is edematous. The superficial scleral layers show abundant fibrinous and cellular infiltration, with dilation of lymph-vessels and blood-vessels. The walls of the vessels are generally thinner than normal and are surrounded by an area of cellular infiltration. Hemorrhages may be present or absent. The inflammatory products do not tend to disintegration; they disappear by resorption. There is not a clearly-defined line of demarcation between episcleritis and scleritis, transition forms existing.

In fully-developed cases there can be little difficulty in the diagnosis. Episcleritis may be mistaken for phlyctenular conjunctivitis. In the latter affection there is present a denuded area of a whitish-yellow color, and the whole inflamed patch is movable with the conjunctiva.

Darier states that the diagnosis of episcleritis from conjunctivitis is facilitated by the use of adrenalin, which produces marked anemia of all the conjunctival tissue, but leaves a hyperemic spot at the level of the episcleral inflammation.

Episcleritis generally lasts one or two months, but may continue longer. Recurrences are not infrequent. In general, the prognosis is favorable; exceptionally the deeper layers will be involved, leading to ectasiæ.

In the *treatment* of episcleritis it is necessary to attend to the general health. Gastric and uterine disorders should receive appropriate treatment. Salicylate of sodium, aspirin, and colchicum are valuable remedies for internal use. Pilocarpin by the mouth or hypodermically will often produce an amelioration of the symptoms. Massage, heat applied by the Japanese hot-box, and the subconjunctival injection of a solution of bichlorid of mercury (1 to 3000) are valuable therapeutic measures. Adrenalin, applied three or four times daily, is of value.

After each application gentle and prolonged rotary massage with

mercurial lanolin is to be practised (Darier). Injections of salicylate of sodium (2 per cent.) of cinnamate of sodium (hetol), or of salt solution have been recommended. Astringent metals and caustics should not be used. If the cornea is involved, atropin should be applied, but with due caution in elderly persons. In rebellious cases the inflamed patch may be excised, or scarification or curettage may be tried. Reuss advises the use of the constant electric current, applying a small electrode to the nodule. Attention should be given to the state of the refraction and of the muscle-balance.—(J. M. B.)

According to Wood's *System of Ophthalmic Therapeutics* the treatment of the more acute form should include hot fomentations, frequently applied. A 1 per cent. solution of sulphate of atropin should also be used sufficiently often to keep the pupil well dilated.

To the prescription 1 per cent. dionin can generally be added with decided advantage.

Smoked protective glasses should be worn, with complete rest of the eye. When there is much pain and pericorneal injection the natural or artificial leech should be applied to the temple. The sub-conjunctival injection of normal salt solution, or 1 to 5000 solution of bichlorid of mercury, sometimes proves useful in obstinate cases. Pilocarpine sweats and iodide of potassium may be used with success, especially where the deeper structures of the eye are affected.

The rheumatic, gouty or tubercular taint should be neutralized by appropriate remedies. Tuberculin should be employed, both as a diagnostic and as a therapeutic agent, in cases of suspected tubercle.

The internal treatment is of considerable importance and it has been found that pilocarpin, colchicum preparations, sodic salicylate, aspirin and similar remedies act very well. Massage in its various forms with mercurial ointment has been shown by Darier to be of considerable use.

Sub-conjunctival injections of sodium cinnamate, normal salt solution and sodic salicylate have also been recommended. Attention must be called to the fact that the episcleral patches are sometimes merely aggravated forms of angular conjunctivitis and call for the local exhibition of zinc salts, or they may be tubercular deposits that require the usual methods of diagnosis and treatment. In addition to the foregoing applications hyoscin may be ordered and should be instilled as a one-tenth per cent. solution once or twice a day to keep the pupil well dilated.

For the interfibrillary deposits commonly left after the scleritis has subsided, massage with brown ointment and internal administration of

thiosinamine (two grains three times a day) will be of considerable assistance.

The resources of hydropathy and a residence at some health resort where baths, water-drinking, dieting and out-of-door exercise are fashionable are not to be forgotten in the conduct of this frequently stubborn disease.

The raised and generally pigmented exudates of scleritis commonly give trouble. When the inflammation is beginning to subside these plaques should be treated by daily massage with the following as an adjunct to other applications: Sodii iodidi, 0.25; petrolati, 10.00.

Painting the lids with the tincture of iodine is a favorite remedy with some surgeons. Thus, Peuch advises it to remove the deposits in all forms of deep scleritis, applying the remedy daily for five days. This procedure is occasionally employed in chronic iritis and other inflammations of the uveal tract. Its action is, of course, that of a counter-irritant.

Homer E. Smith finds that, in this disease, aspirin internally and in full doses is preferable to the salicylates.

H. Bailey uses half a grain of pilocarpin to a fluid ounce of water instilled into the eye three times a day.

Under the name of *subconjunctivitis epibulbaris gonorrhoica,* Heerfordt (Graefe's *Archiv f. Ophthal.*, Vol. 72, p. 344, 1909) describes a metastatic gonorrheal affection observed by him 23 times in five years at Copenhagen. The disease shows a tendency to be localized in the episclera or the epibulbar, sub-conjunctival mucosa. He has seen no cases in which the retrotarsal fold is affected, such as are described by Saemisch and Groenow as complicating urethritis. Neither has he found anywhere described the condition as he himself has observed it. It bears a close resemblance to a phlyctenular conjunctivitis. The presence of a urethritis and joint disease, and the absence of a history of similar attacks would serve to differentiate the two affections. There is usually a muco-purulent secretion which is more profuse when the inflammation is superficial. The lids are sometimes swollen. In every case he examined the discharge for the gonococcus, but with negative results. He thinks that the disease is caused by the presence of remnants of dead gonococci or by toxins. In 17 of the 23 cases there was some joint affection present. Corneal vesicles are a frequent complication. Iritis also may be present. It is a more frequent complication of urethritis in the male than in the female. Libby saw episcleritis in a woman aged 30, which followed a mild attack of iritis. There was no specific or tubercular history.

Episcleritis partialis fugax. Gouty eye. Hot eye. Fugacious episcleritis. Sub-conjunctivitis (von Graefe). Episcleritis periodica fugax. This curious disease occurs in the form of a sudden, transient hyperemia of the episcleral tissue and overlying conjunctiva. It lasts for a few days and reappears at intervals varying from a few weeks to several months. There is pain, photophobia, and lachrymation, but vision is unaffected. The disease occurs chiefly in adults of a rheumatic or gouty diathesis, but children are not exempt. The affection is supposed to be identical with that described in 1892 by Swan Burnett as "a vasomotor dilation of the vessels." The name "hot eye" was given to the disease by Hutchinson. The *treatment* is the same as for episcleritis.—(J. M. B.)

Some additional observations of this affection are the following:—E. T. Smith (*Ophthalmic Review*, October, 1907), after an opportunity of watching the onset and recovery of this affection during five attacks in a man under close observation for five years, concludes that episcleritis periodica fugax may exist in a severe form without any exudation of serum or round cells into the sclera or overlying tissue; that a period of depressed general health precedes the attack; that the affection may be para-gonorrheal (to use an analogy with syphilis) in origin; that in such cases quinin in full doses is of more service than the so-called anti-rheumatic remedies; that in the way of local treatment, warmth and protection are all that is needed; drugs which act on the pupil being unnecessary and probably harmful. He thinks the disease is not merely a mild and fleeting form of episcleritis, as suggested by many authors, but a distinct affection, whose prominent characteristic is that the eye is left after the attack in apparently normal condition, both as regards structure and function.

A maiden lady of 40 years, who had suffered from recurring attacks of inflammation of one or both eyes for four years, was treated by Wyler (*Practical Medicine Series*, 1910, p. 69). The attacks seem to have been associated with her periods of menstruation. Her general health was good, except for constipation and irregular, frequent menstruation. The attacks came on suddenly and were evidenced by the lower outer quadrant of the ocular bulb assuming a dusky-blue color and by a small localized edema. The area beneath showed dilated ciliary vessels. The cornea was not involved. She continued to have these attacks about every two weeks. Treatment was of value only in shortening the attacks or in making them milder. Dionin was of most value as a local measure. The author believes this ocular inflammation to be the expression of a deranged physical state. More or less dis-

agreement exists among writers as to what this derangement is, the greater number favoring the gouty diathesis.

A. C. Snell (*Annals of Ophthal.*, October, 1911) reports two examples of fugacious episcleritis, one in a woman, the other in a man. The woman's attacks came on suddenly without prodromal symptoms, always at the beginning of a menstrual period, and lasted until the period was over. From 1905 to 1911 she missed having attacks during only a few months each year. An attack had the appearance of an acute inflammation limited to one quadrant of the eye. This area was usually edematous, but there was no nodular enlargement. The vessels of the conjunctiva, sub-conjunctiva and episclera were all distended and congested. The inflamed sector was situated exactly in the region of the insertion of a rectus muscle. The eye was subject to pain of a neuralgic character. The attacks came in either eye, sometimes in both at the same time. There was no regularity in the involvement of the quadrants, but it was usually the lateral quadrants which were affected. During 1910 and 1911 the attacks were of longer duration, lasting from ten days to three weeks. During all this time she observed strict rules regarding diet. She boasted of always being physically well. She was, however, of a neurotic temperament. Notwithstanding the number of attacks the sclerotics showed no alteration whatever. Between attacks the patient was free from discomfort. Menstruation was always regular and perfectly physiologic.

The man, who was 29 years of age and weighed 240 pounds, was first seen in June, 1911. He gave a history of recurring attacks of inflammation in various parts of one or the other eye for three and a half years. The inflammation lasted from four to ten days. The eye felt "hot" and at times was very painful. Sometimes he was free from attacks for several months and then he would have as many as four attacks in one month. They came on suddenly and reached their height in a single day. The symptoms were severe for two or three days and then gradually subsided. On the day of the patient's first visit to the author there was an inflamed area confined to the region of the tendon of the right inferior rectus muscle with practically the same appearances described in the case of the woman. This attack had been going on for sixteen days, and two days later it terminated. In five days he had another attack, this time involving the inner quadrant of the same eye. He had always enjoyed good health, with the exception of an attack of rheumatism nine years past. He was endeavoring to restrict his diet—more as to quality than as to quantity.

The treatment mostly consisted of the use of saline laxatives, Turkish baths, restriction of the diet and the local application of a five per

cent. solution of dionin with atropia, assisted by hot fomentations, two or three times a day.

Episcope. Aphengescope. Megascope. Opaque lantern. Epidiascope. An apparatus for projecting the image of opaque objects, like coins, pictures in books, etc. It consists of one or more powerful radiants for illuminating the opaque objects, an ordinary projection objective, and a prism or mirror for making the vertical rays from the object horizontal. (Gould.)

Episcotister. An instrument for testing the sensitiveness of the eye, invented by Talbot and improved by Aubert, consisting of two black, metallic discs, in each of which four octants are cut out. The discs are placed one on the other, and can be so rotated round their centres that the non-excised octants of the upper disc cover any arbitrary parts of the excised lower disc. By means of a screw arrangement the two discs may be fastened in their opposed position, and the degrees of the free sectors may be read off on a scale. The glass to be examined is then brought close to the disc, which is rapidly rotated like Masson's discs, so that a gray circle is produced. If we now look alternately through the disc and through the glass toward a white surface, we can, by displacement of the sectors of the first, equalize the diminution of the light produced by it with that produced by the glass. (Foster.)

Episemasia. (L.) A diagnostic or prognostic sign.

Epistagmos. (L.) Instillation. Also a name given by Dioscorides to "catarrh."

Epistaxis. Nosebleed. Although the relation of nasal hemorrhages to eye diseases is generally regarded as largely accidental yet some observers have noted a closer connection between the two. For example, Eales (*Birmingham Medical Review*, 1880) described a group of recurrent hemorrhages into the retina, and into the vitreous from the retinal vessels, associated with epistaxis, in young males in whom chronic constipation and high arterial tension were present. Eales held that constipation was the main factor in the production of the retinal hemorrhage in these individuals.

Episyntheticus. (L.) Pertaining to episynthesis, medical doctrine taught by an ancient class of physicians professing eclecticism.

Epitase. (F.) The first appearance of a disease, especially of a fever.

Epitelio pigmentato. (It.) Pigmented epithelium.

Epithalamic. Situated on the optic thalamus.

Epithel. (G.) Epithelium.

Epithelhaufen. (G.) A mass of epithelium.

Epithelial dystrophy of the cornea. See **Cornea, Dystrophy of the.**

Epithelial hyperplasia. This is a tumor-like exudate occurring mostly in old age which, according to Parsons (*Pathology of the Eye*, p. 359), exhibits small, festoon-like thickenings; also in cyclitis (Alt, Treacher Collins), with the formation of non-pigmented and pigmented bands and tubes or tumor-like thickenings. Krückmann describes small nodules of granulation tissue covered by epithelium, which sprout out into the vitreous in cyclitic conditions. The granulation tissue shrinks later, so that spaces covered with epithelium are formed in the scar

Epithelial Hyperplasia of Ciliary Body. (Parsons.)

tissue. Only rarely does the epithelium appear to invade the preformed tissues, and these are then found to be in a sclerosed cicatricial condition.

Epithelial invasion. See **Down-growths.**

Epithelial optograms. An optogram is the retinal image formed by the bleaching of the visual purple under the action of light. Strong contrasts of light and shade may be observed for a short time on the retinas of animals recently killed. An epithelial optogram is the term employed by Kuehne to indicate the direct action of light upon the migration of fuscin.

Epithelial plaques. These are wart-like growths generally found on the conjunctiva and cornea. Parsons (*Pathology of the Eye*, p. 130)

believes that they are all either cases of xerosis of the conjunctiva or of epidermoid changes in the cornea, which occur under all conditions of exposure, *e. g.*, in lagophthalmia. He adds, "I have had an opportunity of examining two such cases. In each case they occurred in young patients and were probably congenital. In one the plaque occupied the typical position of a dermoid tumor, being partly over the cornea, out and up. In the other it was in a similar direction, but separated from the cornea by normal conjunctiva. In each case the epithelium was much thickened and the superficial layers were corneous. I think these plaques are the simplest expression of a dermoid tumor, only the epidermal elements being represented, those of the cutis being absent."

Epithelial xerosis. A xerotic condition of the conjunctiva or cornea in which these membranes become dry, thickened and of a whitish color resembling the skin, and covered with an epidermoid epithelium.

Epithelioma benigna. EUTHELIOMA. Names given to non-malignant intraocular tumors, especially to innocent tumors of the ciliary body. They are also referred to as adenomata, and (by Fuchs) *innocent tumors of the ciliary epithelium.* See **Ciliary body, Tumors of the.**

Epithelioma of the eye. See **Tumors of the eye**; as well as epithelioma of the various ocular structures under corresponding, separate captions.

Epitheliosis desquamativa conjunctivæ. See **Conjunctivitis, Samoan.**

Epithelique. (F.) Epithelial.

Epithélium à cils vibratiles. (F.) Ciliated epithelium.

Epithelium humoris aquei. A synonym of Descemet's membrane.

Epithélium pavimenteux. EPITHELIUM PLAT. (F.) Pavement epithelium.

Epithelverlust. (G.) Loss of epithelium.

Epithem. EPITHEMA. An ancient medicinal preparation for external application, exclusive of plasters and ointments.

Epizoen des Auges. (G.) External ocular parasites.

Epkens-Donders' ophthalmoscope. Gould (*System of Diseases of the Eye*, Vol. 2, page 70) describes this early and rather elaborate instrument as follows: A cubical box held, diagonally, a mirror perforated in the centre; this mirror could be rotated by means of screws. The box had openings on three sides—one opposite the reflecting surface of the mirror for the patient's eye, one behind the mirror for the observer looking through the lenses of a Rekoss disk and the central perforation into the fundus of the eye, and the third for the tube that admitted light to the mirror. The whole instrument was fastened by an adjustable stand to the corner of a table, so that

observer and patient could sit opposite and facing each other, with the instrument between them. The light-tube had at its extremity a convex lens of small focal length, to collect the rays of a lamp placed opposite. These rays struck the mirror, and, after adjustment of the instrument, were reflected into the patient's eye, illuminating the fundus. A micrometer screwed into the end of the light-tube had, when properly focused, its two sharp points pictured on the fundus, and, as the tube with micrometer could be turned on its own axis, an exact measurement of all spots, changes, etc., could be obtained. Then, knowing the distance between the micrometer points and the length of the tube, the exact size of blood-vessels, nerve-head, and discolorations

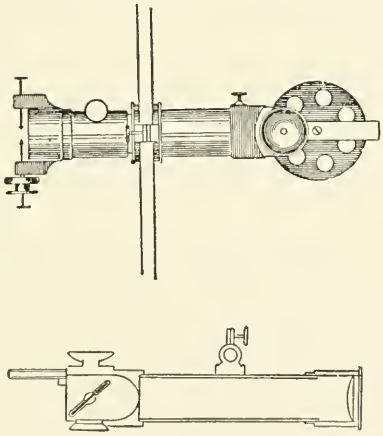

Epkens-Donders Ophthalmoscope.

could be determined. A camera lucida could also be placed at the observer's end of the tube, permitting a correct drawing of any desired part of the fundus.

Eponge. (F.) Sponge.

Epoptic figures. The interference figures seen in idiophanous crystals

Epsilon, Angle. The angle included between the macular axis and the papillary axis. This angle is usually greater in hyperopes than in myopes.

Epsomite. (F.) Epsom salts; sulphate of magnesium.

Epsom salts. See **Magnesium sulphate.**

Epuisement nerveux. (F.) Neurasthenia.

Epyrèle. (F.) Empyreumatic oil.

Equation of achromaticity. An equation expressing the relation which must hold between the radii of curvature of a compound lens in order that it may be achromatic.

Equation of color. The fundamental examination of the color-sense is made by means of what is called *equations of colors.* Two or three colors are mixed in different proportions until the observer declares the mixture similar to a fourth given color, most frequently white. We then examine whether an eye, of which the color-sense is normal, recognizes the equation, that is to say, whether the mixture appears likewise similar to white for this eye.

Neglecting slight differences, it can be stated that, as a rule, an equation of color which is true for a normal eye, remains true for all eyes; as well for normal as for dichromatic eyes.

Equation of light. The correction applied to the observed position of a celestial body in respect of the finite velocity of light.

Equatorial. An astronomical telescope having its principal axis of rotation parallel to the axis of the earth.

Equatorial plane. A plane vertical to the optic axis which cuts the eye-ball at its greatest circumference; it intersects the sclera at the equator of the eye-ball.

Equator of a lens. The angular edge at the meeting of the anterior and posterior surfaces of the lens.

Equator of the eye. EQUATOR OCULI. The boundary of the transverse and central vertical planes of the eye. Practically, it is a plane dividing the globe into an anterior and posterior half. In an adult eye the equatorial circumference averages 77.6 mm.

Equerre à reflecteur. (F.) Optical square.

Equiconvex. Having two equally curved convex surfaces.

Equicrescent. Having equal increments; increasing at an equal rate.

Equilibrating operation. Tenotomy on the direct antagonist of a paralyzed ocular muscle.

Equilibration. Equipoise; the maintenance of an even balance.

Equilibrium. The condition of repose under the operation of equal and opposite forces.

Equilibrium test. For heterophoria. A prism of 8° or 10° is placed with the base down before either eye and a small light at twenty feet (six metres) distance is used as the test-object. The prism removes the tendency to fusion by displacing the image belonging to the eye before which the prism has been placed to a point below the fovea, in consequence of which it will be projected above the image belonging to the other eye. If orthophoria for the lateral muscles exists, the images of the two eyes will stand one directly above the other. If exophoria be present, the displaced image will lie to the opposite side of the image belonging to the other eye from that before which the

prism had been placed. If esophoria be present, it will lie on the corresponding side.—(J. M. B.)

Equivalent focus. The magnifying power of a compound lens referred to that of a single lens.

Equivalent lens. In *optics*, a lens which, being placed at a suitable *fixed* point, produces an image of the same size as that produced by a combination of separated lenses placed generally in some other position. Two thin ophthalmic lenses are said to be *equivalent* when their corresponding principal congeneric meridians are of the same refractive powers.—(C. F. P.)

Shahan (*Trans. Soc. Oph. A. M. A.*, 1913) calls attention to the difference in strength of convex lenses according to their shape, that is, whether double convex, plano-convex, or menisci. He has constructed a series of charts from which, by a slight calculation, equivalent lenses of the above form may be ground. The charts show what curvatures should be given to correspond to the ordinary double convex lens of the trial case.

Equivocal characters. In alphabets and print for the blind (q. v.), this term has been used to designate certain characters which differ only as to their position in the line, upper, lower, or middle. When in the lower or middle position, they have been called *low-level characters.*

Eradiation. Emission of rays or waves of light.

Eraillement. (F.) An elongated rent or tear with irregular edges.

Eraillement de la paupière. (F.) Ectropion of the eyelid.

Erasion. Removal (as of diseased tissue) by scraping.

Erbfällig. (G.) Hereditary.

Erbium glass. Under this name an almost colorless product has been suggested for lenses with the idea that they would protect the eye from the ultra-violet rays without interfering with vision.

Erblassen. (G.) Discoloration; pallor.

Erbliche Augenleiden. (G.) Hereditary eye diseases.

Erblichkeit. (G.) Heredity.

Erblinden. (G.) Becoming blind.

Erblindungsursachen. (G.) Causes of blindness.

Erbschaft. (G.) Inheritance.

Erb's disease, Ocular symptoms of. This affection, also called asthenic bulbar paralysis or myasthenia gravis, is characterized by muscular fatigue, especially of the muscles of mastication and those of the neck. The eye-symptoms observed are ptosis, usually bilateral, and other ocular palsies. The orbiculares are often involved, while the internal ocular muscles are rarely affected.—(J. M. B.)

Erbse. (G.) A pea.

Erbübel. (G.) An inherited defect.

Erdiges Hagelkorn. (G.) Chalazion terreum.

Erect image. In *optics,* an image whose various parts occupy the same relative positions with respect to its center as the corresponding parts in the object. See, also, **Image.**—(C. F. P.)

Erecting microscope. A microscope in which the object appears in its natural position, an effect due to the interposition of an erecting prism above the objective.

Erecting prism. Erector. A prism placed between the two lenses of the eyepiece to re-invert the image. This prism, with angles of 45° and 90°, erects the image when the incident rays are parallel to the hypothenuse face and impinge upon one of the mutually rectangular faces coincident with a principal section. The rays refracted at the incident face impinge upon the hypothenuse face within the prism at an angle exceeding the critical angle and are there reversed through reflection towards the second rectangular face, where they are again refracted as emergent rays parallel to the incident beam.—(C. F. P.)

Erethism. Exaggerated sensibility or irritability. A morbid degree of excitement or irritation.

Erfahrung. (G.) Experience; experimental knowledge; empiricism.

Erfrischung. (G.) Refreshment; also the act of refreshing or denuding a part of the surface of the body in a plastic operation.

Erg. The unit of energy; the amount of work done by a body moving through 1 ctm., in opposition to a force equal to 1 *dyne.*

Ergänzungsfarben. (G.) Complementary colors.

Ergograph. A recording ergometer. An instrument for recording the extent of movement produced by a contracting muscle, or the amount of work it is capable of doing. See **Muscles, Ocular.**

Ergostat. A machine for testing muscular power. G. Gaertner's ergostat consists of a crank for turning a wheel which is connected with a small wheel serving as the fulcrum of a weighted lever, with a registering index.

Ergot. Spurred rye. Secale cornutum. This powerful and often poisonous agent is manufactured from diseased rye and contains ergotic acid, ergotine and several other derivatives.

J. G. Dorsey, from a suggestion of Bartholow's *Therapeutics,* instils a single undiluted drop of the fluid extract (alcoholic) into the eye two or three times a day. The application is painful for a moment but is immediately followed by a sense of relief. He uses it in the acute stages of both simple and purulent conjunctivitis as an adjunct to other antiseptic treatment.

As regards its oculo-toxic relations Parsons (*Pathology of the Eye*, p. 1339) furnishes the following list of symptoms: Retinal anemia, constriction of the retinal vessels, retinal edema and slight neuritis have been seen in ergot poisoning. No case of optic atrophy has been recorded. Slight transitory amblyopia and contraction of the field have also been observed. Several cases of cataract ascribed to ergotism have been reported. Experimental intravenous injection of the active principles of ergot produces passive intra-ocular hyperemia. Nystagmus, hemorrhage into the lids, transitory exophthalmos and iritis have been described.

A more extended account of the amblyopia from the use of this agent is furnished by J. Fejér (*Ophthalmology*, July, 1914). The writer remarks: "Under ergotinin, ergotoxin, cornutin, sphacelinic acid and sphacelotoxin, different substances are described, to which sphacelotoxin was attributed the most important action. It was supposed to contract the blood vessels and increase the blood pressure to such an extent that the constant spasm of the small arteries may produce hyaline, thrombosis, with subsequent dry necrosis. Barger and Dale, however, proved that not these, so far described substances are the active properties, but several amines, especially isoamylamine and hydroxylphenylethylamine, which in traces stick to the cells of secale cornutum and exert a specific influence through the sympathetic nerve of the vaso-constrictors and the blood pressure.

"The most certain injury is the formation of cataract, which has been brought in connection with the convulsions and attributed to lack of nutrition of the anterior segment of the globe due to the spastic constriction of the vessels. The optic nerve is not affected and, according to Uhthoff, there are no changes of the fundus. Anemia of the retina, contraction of the retinal vessels, haziness of the borders of the disc, intense hyperemia of the retina and disc, have been described, but Uhthoff does not admit them beyond doubt. Blindness from affection of the optic nerve and retina after ergotism has so far not been observed. According to Lewin and Guillery visual disturbances were found in 22 out of 89 cases of ergotism; in some patients the visual field was contracted. In most of them the visual impairment soon subsided, and only in the convulsive forms opacities of the lens remained. In one case the retina was very pale and the vessels narrow during the convulsions, but became again hyperemic, as well as the disc, after their cessation. In most cases the fundus remained normal. In animals contraction of the vessels was ascertained after 30 minutes, and in carnivora total blindness can be produced by chronic intoxication with secale cornutum. Literature contains a case of a man, aged 30, who

developed internal ophthalmoplegia after taking extract of secale cornutum. A woman who, on account of a uterine hemorrhage, took a teaspoonful of fluid extract, fainted, and her vision was dim for several days. A physician complained, aside of other symptoms, of visual disturbances after a dose of 4 grammes of secale cornutum.

"From these publications and experiments on animals it transpires that secale cornutum may produce haziness of sight in man, in animals complete blindness, but the ophthalmoscopic conditions are insufficient and, according to Uhthoff, entirely unreliable.

"Fejér also reports the case of a woman who took secacornin 'Roche' on account of slow involution of the uterus. Secacornin 'Roche' is a watery-alcoholic extract prepared by dialyzation, and considered by Prof. Bókay as a good preparation, although not better than the simple extract.

"A slender woman, aged 20, without any organic diseases, was normally delivered on Sept. 15, 1912. For better involution of the uterus she took 10 drops of secacornin on Oct. 1st, 2nd and 3rd. In the afternoon of Oct. 3rd she complained of poor vision and saw the pictures in the room darker. On Oct. 4th she again took 10 drops, on the 5th and 6th none and saw a little better. On Oct. 7th she took 15 drops three times and her sight was again hazy. On Oct. 13th none, but saw better. On Oct. 14th the sight was clear. On Oct. 11th, after dilation of the left pupil by homatropin, Fejér noticed an anemia of the macula lutea, its surroundings veiled and the vessels very much contracted. The aspect of the macula resembled that in embolism of the central retinal artery without the cherry-red spot, which is a phenomenon of contrast, caused by the yellowish macula covered by the opaque retina. Vision, visual field, color sense, showed nothing abnormal, except fogginess. Hence, Fejér was firmly convinced of a disturbance of circulation of the retina, caused by secacornin, consisting in an intense contraction of the vessels and marked anemia and slight opacity of the center of the retina. This characteristic picture of the center existed also in the other eye.

"Secacornin was at once discontinued. The next day an improvement set in, and on the third day vision was restored. The opacity of the retina subsided, the vessels grew wider and vision normal.

"The patient took in all 255 drops, *i. e.*, from about 10 to 12 grammes. The first symptoms appeared after 75 drops, *i. e.*, from about 3 to 4 grammes, had been taken. During the whole puerperal state the temperature remained constantly under 37°, and the pulse fluctuated between 84 and 100; it was of normal tension. Hence, the secacornin did not seem to influence the blood pressure, although this was not

measured with instruments. The vaso-constrictors of the fine terminal arteries of the retina must have been irritated by certain chemical agents, in order to produce this intense anemia and vascular contraction at the center of the retina."

Erhaltensbrille. (G.) An eye-preserver; spectacles of colored glass. Protective glasses.

Erholungsausdehnung des Gesichtsfelds. (G.) Widening of the visual field.

Ericeron. ERICERUM. (L.) A collyrium prescribed by Ætius, probably made from a species of *Erica.*

Erigne de Beer. (F.) Beer's iris hook.

Erinus. A plant mentioned by both Pliny and Dioscorides, but which cannot now be identified. Mixed with honey, it was used in epiphora. —(T. H. S.)

Eriometer. An instrument devised by Young for measuring the diameter of fibres or minute objects by the colored rings produced by their diffraction of light.

Erioxylum. (L.) (Obs.) In the older pharmacopœias, cotton-wool.

Eristalis tenax. This is an ocular parasite described by Reis (*Ophthalmology*, p. 152, October, 1913) as having been removed from the conjunctival sac of a patient. It derives its name from its surprising immunity against even the strongest poisons, flourishing, the author states, in the mud of sulphur springs and can be immersed without perishing in a saturated solution of corrosive sublimate for eight hours and in pure formalin for twelve hours.

Erithales fruticosum. (L.) A species of tree found in the West Indies. The resin is employed in nephritic complaints; the wood is used by the natives for torches, in powder as a perfume, and in decoction for ophthalmia and cholera morbus.

Eritropsia. (It.) Erythropsia.

Erkältung. (G.) Refrigeration; chilling; taking cold.

Erkennungszeichen. (G.) A diagnostic sign.

Erkrankung. (G.) The state of being sick; a disease.

Ermüdung. (G.) Fatigue; exhaustion.

Ernährung. (G.) Nutrition.

Ernährungsstoff. (G.) Nutritive material.

Ernia totale dell' iride. (It.) Complete hernia of the iris.

Eröffnung. (G.) An opening; foramen.

Erpete. (It.) Herpes.

Er-Razi. See **Ar-Razi.**

Erregung. (G.) Stimulation.

Error of dispersion. The indistinctness produced in the outlines of an image by chromatic aberration.

Errors of refraction. See **Refraction and accommodation of the eye.**

Erscheinung. (G.) Phenomenon.

Erschlaffung des Thränensacks. (G.) Dacryocystatonia or atony of the lachrymal sac.

Ersetzen. (G.) To replace.

Erstarrung. (G.) Rigidity.

Ertränkung. (G.) Suicidal or homicidal drowning.

Ertrinkung. (G.) Accidental drowning.

Erwachsen. (G.) Adult.

Erweichende Mittel. (G.) Emollient remedies.

Erweichung. (G.) Softening.

Erweiterer der Pupille. (G.) Dilatator pupillæ.

Erweiterung der Lidspalte. (G.) Widening of the interpalpebral space.

Erworbener Staar. (G.) Acquired cataract.

Erysipelas, Ocular lesions of. This disease is a specific inflammation of the skin and subcutaneous tissues, characterized by redness, swelling, edema and heat. It exhibits a marked tendency to the formation of vesicles and blebs, and is accompanied by more or less febrile disturbance. The disease, though rarely as a primary affection, has been observed with relative frequency about the eye, extending as a rule, from contiguous areas on the face or scalp.

It is unusual for the ophthalmologist to see cases at the incidence of the attack. Commonly he sees it after the eruption has been preceded by a more or less distinct prodromal period, lasting variously from a few hours to two or three days, during which there may have been such constitutional disturbances as malaise, chilliness, nausea and perhaps vomiting, with a moderate rise in temperature, followed by rapid appearance of the eruption.

As found about the eyelids erysipelas varies in its appearance, depending upon the varying structures of the skin and subcutaneous tissues. It may consist simply of an erythema, or it assumes, very early, a phlegmonous aspect, and is accompanied by abscesses in the orbital tissues. In ordinary cases the lids have a uniform dusky-red color; they are swollen by an edema which extends to the eyebrows and cheeks, usually so pronounced as to make it impossible for the patient to open the eye, and difficult for the surgeon to expose the ball. The swelling occupies both lids and extends to the neighboring parts. The skin is glazed and shining, the border may be slightly elevated; it is bright-red, and the border is always sharply-defined.

Because of the texture of the subcutaneous tissues, and because of the anatomic limitations of the palpebral structures, the disease affects the entire area of the surface at the initial outbreak, so that one usually does not see the disease spread by extension in the manner frequently noticed when other parts of the body have been affected. At the same time the swelling may gravitate from place to place in the loose palpebral tissues; circumscribed infiltration, however, is absent. On the surface there may be the formation of vesicles or blebs which may subsequently become purulent. As a rule, there is more or less conjunctivitis.

By the end of the third or fourth day the disease has reached its height, remaining stationary for a few days, when, unless complications have arisen, it subsides, the swelling becomes less pronounced, the redness becomes brownish or brawny, changing rapidly until the natural white is resumed. The constitutional symptoms abate, desquamation ensues, and the disease is over in from ten days to two or three weeks. When there has been pronounced vesiculation or bleb formation, the dry crusts resulting drop off, leaving a faint pitting of the red surface which gradually fades. In my own experience the disease has remained localized to one side in the majority of cases, but not infrequently both sides are affected.

As the greater number of cases are seen at dispensaries or in one's office, the constitutional symptoms, as observed there, are not usually severe. In spite, however, of the mildness of the symptoms in such cases the disease is both contagious and infectious. The infection is now believed to be due to the presence of the streptococcus of Fehleisen, although other pyogenic organisms have been found. Since the disease rarely arises as a primary affection in the eyelids, usually taking its origin from slight wounds and excoriations at the angles of the orbit, especially the inner, it may be that it arises there by transmission through the lachrymal passages. This supposition is borne out by the fact that it is quite common to find the nasal mucous membrane affected also, and to find the streptococci in the nose.

The disease rarely attacks the young or the aged. It is more common between the twentieth and fortieth years of age. Anything which depresses or weakens the vitality will predispose to its invasion; therefore poor health, exhausting illness, or alcoholism usually precede the infection. Since few cases are seen in the summer months, it is likely that damp weather predisposes to the occurrence.

One attack of the disease does not protect against other attacks. On the contrary an attack serves as a predisposing factor towards further outbursts, probably because of the retention of microbes within the

integument. Succeeding attacks, however, are seldom as severe as the primary.

The disease is a dermatitis involving the integument and deeper parts. It is accompanied by serous exudation into the skin and subcutaneous tissues, with the deposit of fibrin and dilatation of the blood vessels and lymphatics and swelling of the connective tissue fibers.

The streptococci may enter the skin to greater depths and invade the lymph spaces, from which they can enter the general circulation, and thence enter the globe itself. Vesicles and blebs form when the exudation has been rapid. Repeated attacks are apt to leave a permanent thickening of the skin. A more or less doughy or firm edema not infrequently remains a long time after erysipelas of the lids. This resolves very slowly, but in the end disappears without leaving a trace. In other cases the skin becomes hypertrophied and the solidity continues and the case assumes the appearance of elephantiasis.

The chief danger of this affection of the eyelids is the likelihood of infecting the tissues of the orbit and, by transmission to the cranial cavity, meningitis taking place with fatal consequences. Orbital abscess has been observed in rare cases. A more frequent finding is simple infiltration, or serous soaking of the orbital contents, producing more or less proptosis. In this event implication of the optic nerve may occur with papillitis or ischemia from compression of the central vessels of the retina, terminating in atrophy and usually in complete blindness. Other cases may present paresis of the ocular muscles, as for example of the oculo-motor or of the levator. Acute inflammations of the lachrymal gland occur quite frequently, and abscesses of the frontal sinus may occur under the influence of erysipelas.

Many dermal affections are commonly spoken of as "erysipelas" and to those affections have been ascribed all sorts of consequences; it is, however, probable that a large number of cases of blindness can be ascribed to erysipelas as the primary cause, for, as we have seen, there are many affections associated with erysipelas of the eyelids, since besides the dermal lesions, there may be gangrene of the subcutaneous and orbital tissues, which lead to ectropion and other distortions, and adhesions like symblepharon and anklyloblepharon; phlebitis of the orbital veins and extension to the cavenous sinus leading to a fatal termination; orbital abscess and cellulitis (which, when both sides are involved, is usually fatal); exophthalmos from pressure by the extensive edema of the orbital tissues; paresis of the extra-ocular muscles, and, from compression on the oculo-motor nerves, internal ophthalmoplegia. Lachrymal disease occurs quite frequently.

It must not be forgotten when studying cases of disease of the sinuses adjacent to the orbit, to consider the likelihood of a previous attack of erysipelas as the cause of the sinusitis.

The eyeball itself may be affected. From external necrosis, which is secondary to the infective conjunctivitis, the cornea may ulcerate extensively, and perforate with the involvement of the iris and the setting up of a septic uveitis. In the scrapings from the necrotic area in the cornea streptococci have been found in great numbers. Metastatic iritis and irido-choroiditis have been noted. The orbital compression may give rise to retinal thrombosis, ischemia or hemorrhage and obliteration of the retinal vessels, to neuro-retinitis and optic atrophy. The other eye may be affected, not by the spreading of the disease over the skin, but perhaps by phlebitis and by way of the cavernous sinus. Such cases have always been fatal.

The characteristics of erysipelas of the eyelids are so distinct that the diagnosis is rarely attended with difficulty. It may, however, be confused with simple erythema, dermatitis (essential, or venenata), eczema, and herpes zoster. The points to be considered are the character of the onset, the shining redness, the swelling, the elevated, sharply-outlined border, and the accompanying constitutional disturbance. The dermatitis of poison ivy, or from drugs, lacks the sharp borders and is free from constitutional disturbance and is not localized, but may start up in several distant points. Erysipelas is rarely marked by itching, whereas it is a common symptom in eczema. In herpes zoster the affected area is usually confined to a definite area in the distribution of the trigeminal nerve and never crosses the median line.

Mild and moderate cases of erysipelas usually run a rapid and favorable course. When the disease extends from lid to lid and from eye to eye, the entire course may occupy several weeks; seldom, however, does it continue for more than a month. Deep-seated cases, especially when septic, occurring in debilitated individuals, particularly the alcoholic or those with nephritis, must be looked upon as of the greatest gravity. When the general symptoms are pronounced, with high fever and evidences of meningeal involvement, the probability of a fatal termination must not be overlooked.

While erysipelas may give rise to serious inflammation of the ocular appendages, the affection is said to possess the fortunate property of healing certain affections present at the time of the erysipelatous invasion. (It has been said to have cured an otherwise intractable dacryocystitis.) Phlyctenular disease and trachoma likewise have been observed to exhibit a striking improvement after erysipelas of

the lids. And irido-choroiditis and cases of uveal disease have recovered spontaneously after erysipelas.

The remedies prescribed and the methods of treatment of erysipelas are legion. Each case must be regarded in its general and in its local aspects. When we consider the accepted causative factor, the application of local antiseptics would seem to be all that is requisite. But as most cases occur in the debilitated, stimulating tonics and nourishing food are necessary. The tincture of the chloride of iron combined with quinine has long been believed to possess specific properties. Strychnine and alcohol, especially in the debauched, may be required to support the system. In grave cases frequent injections of anti-streptococcic serum have given favorable results.

Among the many local applications recommended, hot saturated aqueous solutions of magnesium sulphate have given the best results in my own practice, applied by compresses continuously or for half-hour periods three or four times a day. Carbolic acid ointment, one per cent.; boric acid salve; ointment of ichthyol. Painting the border with tincture of iodine or strong solution of nitrate of silver are advocated and believed to have specific action on the streptococcus.

Abscesses and phlegmonous involvement of the orbit require surgical procedures. The orbit should be tapped without delay to reduce the danger to the vision as well as to protect it from the effects of the deeper invasion.—(B. C.)

Erysipelatous conjunctivitis. The inflammation of the palpebral and sometimes of the ocular conjunctiva which accompanies erysipelas of the face.

Erythema, Belladonna. A form of the disease, due to overdoses of belladonna, resembling the rash of scarlatina. It is not followed by desquamation. See **Toxic amblyopia.**

Erythema, Multiform. MULTIPLE EXUDATIVE ERYTHEMA. POLYMORPHOUS ERYTHEMA. A form of skin disease presenting a great variety of bullæ, nodules, papules, etc., surrounded by reddened dermal areas.

R. Salus (*Klin. Monatsbl. f. Augenheilk.*, p. 30, Jan., 1912) believes that one form of croupous conjunctivitis is really a conjunctival multiform erythema. Often the conjunctivitis is the first symptom, and precedes the eruption on the skin. It may occur in three forms, catarrhal, croupous, or nodular conjunctivitis. The polymorphous erythematous process may also affect the cornea, either in a papulous or a vesicular form.

V. Benedek and Müller (*Zeitschr. f. Augenh.*, Vol. 24, p. 81, 1910) examined a man, 34 years of age, suffering from an atypical variety of exudative multiform erythema. Several ill-defined, purplish, con-

fluent, flat nodes were present at the limbus in the right eye and in the fissural space of the left eye. There were no epithelial changes.

Two cases of episcleritis in the course of erythema multiforme were reported by Toulant, Chevalier and de Jong (*Ann. d'Ocul.*, Vol. 150, p. 209, 1912), which were bilateral, with discrete and distinct superficial conjunctival lesions. All were concomitant with the skin lesions of this affection.

Terson (*Bulletins de la Soc. Belge d'Ophtal.*, Apr., 1912) points out that of the polymorphous erythemata, the papular, nodular, macular and bullous all produce distinctive ocular lesions.

The papular variety shows enormous wheals, symmetrically occupying the exposed portion of the globe; these violet-colored elevations appear and disappear in a few days without leaving any trace.

In the nodular erythema the nodosities are still more dense, are much slower in disappearing, but easily return, in this respect resembling the original malady.

The author reported a case of nodular erythema attacking the eyebrows and eyes of a tubercular subject. It is well known that nodular erythema is frequently encountered as an early sign, or is concomitant to tuberculosis, and on that account should not be overlooked. The author also cited another tubercular case in which sclerosing keratitis appeared, and without any other ocular lesion, although the patient had erythema maculosa.

In the vesicular form, enormous bullæ are often produced upon the mucous membranes (mouth, lips and tongue) and upon the conjunctiva. This affection is generally cured without corneal complications and without retracted conjunctival cicatrices. He tells us we should be careful in making a differential diagnosis between the bullous form, benign to the eye, and pemphigus which is serious, terminating in symblepharon and blindness.

The author states that these diverse ocular manifestations were but little known before his works, which were published twenty years ago, and the thesis of Beaudonnet (1894), which had inspired him. He mentioned other writings which have since appeared and concluded by mentioning a case of acute bilateral glaucoma in which there appeared during the first days, successively to each eye, a crop of recurring nodular erythema. (*Ophthalmology*, p. 227, Jan., 1913.)

Erythema nodosum. Multiple, from five to fifteen, raised, rosy patches, round or oval, from one-half to three inches in diameter. They may develop suddenly, often attacking the skin covering the region of both tibiæ or the ulnar side of the forearms. They are exquisitely tender,

tense and shining. The condition chiefly occurs in children and delicate young women.

This dermal affection has, though very rarely, ocular relations. For example, in a case of iritis in both eyes, reported by Lurie (*Zeitschr. für Augenheilk.*, Vol. 24, p. 458, 1910) the iridic inflammation was three days before preceded by a well-marked attack of erythema nodosum. The iritis differed in several particulars from that which occurs in rheumatism, of which this disease is a congener: the temperature was higher, the ocular affection was double, which is not usually the case in rheumatism, and it preceded the general affection. The author lays stress on the excessive sensibility to pressure over the ciliary region which was present from the commencement of the disease.

Erythema of the lid. SIMPLE ERYTHEMA. A redness of the skin, due to various causes, that may be made to disappear, temporarily at least, by pressure. As it affects the eyelids, it may result from slight burns, atropin, iodoform and other toxic agents. See, also, **Dermatitis, Ocular relations of.**

Erythema, Polymorphous. See **Erythema, Multiform.**

Erythème excentrique. (F.) A variety of annular erythema, most commonly observed upon the cheeks and chin, in which a small erythematous patch extends at the periphery while in the centre it presents the appearance of a superficial cicatrix. A similar form described by Devergie, affects the tip of the nose and the ends of the fingers, and generally follows severe fevers. It may also extend to the eyelids.

Erythrean. Of a red or reddish color.

Erythremia. VAQUEZ'S DISEASE. A condition in which arterial blood circulates in the venous system. A complete account of this rare and curious disease is given by Dupuy-Dutemps and Lutembacher (*Annales d'Ocul.*, Vol. 148, August, 1912). A review of the article appears in the *Ophthalmic Review* (March, 1913) by W. C. Souter. The patient was a man of 53, "without special antecedents." At 39 he had a sudden stroke followed by left hemiplegia and right hemianesthesia, including the face. The paralysis lasted some months but the sensory defect three years. At 41 he had albuminuria. At 44 the man, previously pale-complexioned, began to develop more and more of a red color, and he had some hours' bleeding after teeth extraction. At 49 a large hematoma developed on the shoulder from the recoil of a fowling piece. He kept in bed on this occasion, and had in his feet acute pains with all the characters of erythromelalgia with swelling and local cyanosis. Since then these pains have recurred in crises. At 50 considerable splenomegaly was already present, the edge being

distant 4 cm. from the umbilicus. At 51, on the occasion of a rather sharp movement a voluminous hematoma developed, and fresh painful crises, very violent and more diffuse, occurred. In October, 1910, the red cells were 4,800,000—the anerythremic phase. On December 15, 1910, the red cells were 6,000,000, white cells 14,000, Hb 110, diameter of reds 7μ. On January 19, 1911, reds 8,000,000. Spleen had reached umbilicus; fresh painful crises; albuminuria 7 grms.

He was seen on May 7th, 1911—erythrosis of all the face, feet and hands bluish, lips and tongue of an intense red-wine color, conjunctivæ injected. Spleen enormous, measuring 22 to 39 cm. Liver extended three fingers' breadths below the short ribs. No glandular enlargements. Gums spongy, digestion upset, obstipation. Lungs and heart normal; as is usual, curiously enough in these cases, no sign of dilatation or hypertrophy. Urine normal except for 3.30 gr. of albumin in 24 hours. Nervous system normal except for an exaggeration of the left reflexes and a slight hypesthesia on the right. He had no complaint of his eyes and his vision was normal in each.

As seen by Thörner's ophthalmoscope, the papilla has its contour quite defined, and its color more marked than normal, but there is nothing striking here. The arteries have their normal calibre and their color is not appreciably altered. No retinal hemorrhages in this case. The veins, however, are markedly increased in volume and at once attract attention. No varicosities nor tortuosities seen, although such are common enough in this condition. The abnormally dark tint is most marked in the larger vessels and the normal tint is approached in the smaller branches. The tint is probably due both to the increased amount of blood in the distended vein and to the increased number of red cells, even although the normally-sized arteries show no appreciable change of tint.

In *congenital cyanosis* there is no vascular dilatation, and the relative calibres remain unaltered, but by the arteries having a deeper tint the contrast between arteries and veins is reduced. In *erythremia* the red cells keep their normal characters, but the volume of the blood may be doubled or even trebled and yet there is no cardiac hypertrophy nor elevation of arterial tension. The excess of blood is accommodated apparently in the subcutaneous and visceral veins. The marrow of the long bones shows great erythroblastic activity. Close inspection shows that the skin presents a fine network of dilated vessels which help to give the unusual tint. The erythrosis is unequally distributed, being present especially on the face and extremities, where the skin is more transparent and vascular. Migraine of the classical type and vertigo closely resembling Menière's disease are not infrequent. The

enlarged liver has a peculiarly soft feeling. The pains are very characteristic, they commence abruptly, are seated often in the lower limbs, may be very intense, more marked at night, being aggravated by the horizontal decubitus and the warmth of bed. Purpuric spots may appear in the skin, and hemorrhages and thromboses occur freely, the gums, stomach, bowels, and brain being affected. See, also, **Cyanosis of the eye.**

Erythrochloropia. Erythrochloropy. A rare variety of color-blindness in which there is inability to distinguish colors other than red and green.

Erythrocytometer. An instrument for estimating the number of red blood corpuscles.

Erythroid. Of a ruddy color.

Erythromelalgia. A term applied by Weir Mitchell to a condition sometimes called "red neuralgia." It is a terminal neuritis, a variety of chronic dermatalgia, characterized by burning and aching pain of a part, usually of one or more extremities, intensified by warmth and accompanied by flushing and local fever.

Erythromelas. (L.) Marked with red and black.

Erythrophlein hydrochloride. This compound is a salt of an alkaloid from the bark of *Erythrophleum guinense,* or sassy bark. It is a yellowish-white, amorphous powder, soluble in water and alcohol. It resembles digitalis in its general action but locally is an anesthetic and has been used as such, as well as to relieve irritative symptoms about the eyes in 0.05 to 0.25 per cent. aqueous solution.

By dropping into the normal conjunctival sac or by applying to the cornea a drop of a 0.125 per cent. solution of this salt, slight anesthesia and a corneal haze are produced, while well-marked colored rings are seen around flames. This physiological experiment imitates and realizes the early conditions observed in some forms of glaucoma in which iridescent vision is produced. It is due, as Treacher Collins has shown, to a slight disturbance of the anterior epithelium, the first stage of that edema of the cornea which in genuine glaucoma may go on to permanent corneal cloudiness. In both the experimental and the genuine glaucomatous iridescence the red ring is outermost.

Erythrophobe. An animal to which red light is objectionable.

Erythrophobia. (L.) Intolerance of the red color in the spectrum: an occasional symptom occurring after extraction of cataract.

Erythrophthalmia. (L.) (Obs.) Inflammation of the eye accompanied by decided redness.

Erythrophthalmus. (L.) In zoology, having red eyes.

Erythrophytoscope. Erythroscope. A sort of eye-glass consisting of

a blue glass superimposed upon one slightly tinted with copper oxide. It has the effect of making the green of leaves appear red. Also, a kind of optical instrument used in examining light reflected from different bodies.

Erythropia. A condition in which objects appear as if colored red. See **Erythropsia.**

Erythrops. (L.) In zoology, having red eyes.

Erythropsia. Red vision. An abnormality of sight, either uniocular or binocular, which causes all objects to appear red. It often follows after dazzling by light reflected from snow; it also occurs in aphakia and in some forms of optic atrophy.

The causation and nature of erythropsia due to dazzling has been studied experimentally by Vogt (*Arch. f. Augenh.*, Vol. 60, Pt. 1, 1908), by the use of sunlight and the incandescent electric light. He finds it occurs much more frequently than was hitherto supposed; that slight degrees of it may be regarded as a physiologic effect of looking at any glowing light. To bring it out in these lower degrees, one eye should be subjected to the influence of the light, and the other kept in darkness for purposes of comparison. He thinks erythropsia does not depend on exhaustion of the fluorescence of the lens to ultra-violet rays, and consequent damage to the retina by the passage of these rays, as suggested by Schanz (*Bericht der Oph. Gesellsch.*, 35, 1908). It appears after much too short an exposure to be due to such a change. Still he found that the blue-green rays produced the least erythropsia, and that red-green color-blind persons experienced the same effects as those with normal sight.

The first authentic description of red-vision following cataract operation occurred in 1753. Pathological forms of red-vision have been described by a number of investigators; that form in connection with the gradual fading away of the color; red-vision in connection with other forms of illness. In one case the anomaly was one-sided, lasted for two and a half years, and disappeared after treatment by "animal magnetism." A case of red and green vision in an epileptic has also been described. See, also, **Colored vision.**

Erythropsin. An organic substance in the retina. In the presence of light it is believed to form different combinations, constituting color-perception. It is also called *visual purple* and *rhodopsin.*

Erythroxylin. See **Cocaine.**

Erythroxylon coca. Cuca. Hayo. Ipaado. According to Merck's *Index*, this agent is obtained from the dried leaves of a South American plant commonly known as Truxillo coca. It derives its name from the color of the wood. It contains cocain, benzoylecgonine and a

number of resinoids. Apart from its use in obtaining cocain, it is given in doses of from 1 to 4 grams. There is also a fluid extract, the dose of which is from 20 to 60 minims.

Esame dell'occhio. (It.) Examination of the eye.

Escavazione fisiologica. (It.) Physiological excavation.

Escharotics. Agents that applied to the tissues destroy them and produce a slough or eschar. A useful escharotic is zinc chloride paste, sometimes employed for the removal of epitheliomata, tubercular growths, warts, and other superficial tumors of the lid-skin. See, also, **Caustics.**

Esciorcin. See **Escorcin.**

Esciorcinol. Same as **Escorcin.**

Escorcin. Esciorcin. Escorcinol. Æscorcin. $C_9H_8O_4$. This agent is a product of esculetin by the action of sodium amalgam. It dissolves in alkalies (the green color changing to red) and is then used in detecting corneal defects and lesions of the conjunctival epithelium. According to Frölich a single drop of a 20 per cent. solution is the best test for corneal ulcers and abrasions as the red color of the alkaline escorcin solution shows more plainly on the cornea than the green of fluorescein.

Escorcinol. See **Escorcin.**

Esculin. This active principle is obtained from the bark of *Esculus hippocastanum*—the horse-chestnut. It appears as white crystals with a bitter taste, solutions being faintly blue and fluorescent. Given in large quantities it has been known to give rise to symptoms similar to those of belladonna poisoning.

Esculine glass. Protectives (plane and lenticular) made from this glass are much used in France under the name "*Verres à l'Esculine.*" It is claimed that this very slightly tinted glass protects the eye against glaring better than Fieuzal, yellow, or other form of colored glass. Esculine, believed to be capable of intercepting ultra-violet rays and not interfering with the passage of the red or visual rays, is cemented between two layers of slightly tinted or neutral glass. These glasses were presented to the *Société Française d'Ophtalmologie,* March 27, 1906.

Eselsgurke. The squirting cucumber.

Eséré. (F.) The *Physostigma venenosum.*

Eseridine. This miotic alkaloid is found associated with eserine in Calabar bean. Its formula is $C_{15}H_{23}N_3O_3$ and it occurs as colorless crystals, soluble in alcohol and ether. Its action resembles that of eserine but it is only one-sixth as powerful. There is also a tartrate of eseridine, a white powder soluble in water.

Eserin. PHYSOSTIGMIN. According to Wood's *System of Ophthalmic Therapeutics* this poisonous alkaloid, obtained from *Physostigma venenosum,* or Calabar bean, is found in commerce as a white, crystalline, hygroscopic powder ($C_{15}H_{21}N_3O_2$), and was introduced into ophthalmic surgery in 1870 by Laqueur. Exposed to air and sunlight it decomposes, turns red and should, consequently, be preserved in sealed glass tubes. Similar changes occur, more or less completely, in solutions of all its salts. The commonest of these are the sulphate (acid and neutral) hydrochloride, nitrate, borate, citrate and the salicylate, the first being generally preferred, although the last is less irritating and quite as efficient.

It has been pretty well demonstrated in late years that the old salts of eserine are practically of equal value to the new, and it is proved that eserine salts do not suffer in efficacy with the course of years.

Not only does eserine produce miosis as the result of contraction of the pupil sphincter but it causes a temporary spasm of the ciliary muscle, increasing the accommodative force and separating the punctum remotum from the punctum proximum. Its chief clinical use, however, is in the treatment of peripheral ulcer of the cornea and to reduce the intraocular tension, especially its abnormal rise, in glaucoma. Schmidt-Rimpler advises its use as a half per cent. solution from 2 to 6 times daily. As long as central vision does not decline and the visual fields show no diminution in size this local medication (or that by pilocarpin or arecolin) should be continued and no surgical procedure undertaken.

It is not yet clear how this reduction of tension is brought about, the commonly accepted explanation being that during the miosis the stretching of the iris permits of a readier exosmosis of the intra-ocular fluids.

American patients seem very susceptible to the irritation that follows the use of eserin (especially of the sulphate) and it cannot be used in the doses (½ to 1 per cent.) generally prescribed by European writers. This difficulty may be avoided by giving the drug in smaller proportions as an oily solution or in the form of ointment. Another plan is to instil it in conjunction with cocain or after cocainizing the eye. This procedure not only relieves the pain but increases the miotic action of the drug. The Editor has used for several years: Cocain. mur., gr. j; Eserin sulph., gr. ss; Aquæ dest., fld. ℥j. The eye to be kept closed for 20 minutes after using.

Eserin lamellæ with cocain also act satisfactorily. Often the salicylate is tolerated when the sulphate or the pure alkaloid is found too irritating.

In addition to the employment of some form of cautery in spreading or deep ulcer of the cornea, deWecker believed that there was no agent more prompt in effecting a cure than subconjunctival injections. Among other remedies, he recommended the following, fifteen drops of which should be injected beneath the conjunctiva as near the ulcer as possible: Hydrarg. bichlor., 0.015 (gr. ¼); Eserine. salicylatis, 0.05 (gr. i); Aquæ dest. 100.00 (fl. ℥iiss).

The Editor has not been able to verify the classic contention that eserine is superior to atropia in peripheral corneal ulcer and that the latter remedy should be preferred in central keratitis but it is mentioned here as taught by many authorities.

Schmidt-Rimpler gives the following prescription for the use of the salicylate: Eserin. salicylatis., 0.05; Hydrarg. bichlor., 0.002; Sodii chlor., 0.01; Aquæ dest. 10.0.

It is well to remember that a drop of a one-tenth per cent. eserin solution in castor oil materially aids the recovery from the cycloplegia and mydriasis following the use of homatropin, mydrin and other drugs employed for the determination of the refractive condition.

Woelfflein (*Klin. Monatsbl. f. Augenheilk.*, March, 1913) shows how eserin solutions can be prevented from turning red. A minimum amount of alkali suffices to transform eserin into rubreserin, which in neutral solution, is constant, in alkaline solution is converted into physostigmin blue. Solutions of salicylate or sulphate of eserin turn red in consequence of the alkaline content of the glass, aided by a very small percentage of alkaline salts in distilled water, and access of light and air. Therefore, a container should be used which is as much as possible free from alkali, and light should be excluded. In this respect, the glass of Schott, especially fiolax glass, is preferable to quartz glass; or the bottle should be given a coat of paraffin, or the eserin solution be kept in a metal bottle, e.g., of zinc.

Kaz (*Klin. Monatsbl. f. Augenheilk.*, March, 1912) believes that corneal ulceration resisting the atropin treatment will quickly yield to the use of eserin, used in the form of eserin-xeroform mixture. He thinks that atropin should only be used when there is involvement of the iris, and even then it should be used in conjunction with the eserin. The mixture suggested consists of eserin 0.01, xeroform 0.06, vaselin fl. 2 to 3 gramme.

Casali's (*Annali di Ottal.*, Vol. 40, p. 544) practice in the treatment of keratitis with hypopyon is first to treat any underlying condition of the lachrymal passages; then, after antiseptic irrigation of the conjunctival sac, and provided there is not a marked inflammation of the iris, to introduce an eserin pomade of 0.5 to 0.75 per cent. strength,

and to bandage the eye for twenty-four hours. If at the end of this time the condition has improved, the eserin is repeated until the hypopyon has disappeared and the ulcer has become clean, after which atropin is used. If after the first use of eserin improvement does not come, atropin is at once resorted to. Of 100 cases treated with eserin, sixty-nine were cured without recourse to other measures. In the rest of the cases satisfactory results were seldom obtained by any method. The author accepts Guaita's explanation of the favorable action of eserin as due to stimulation of the fifth nerve.

Fuhrmann asserts that eserin may set up an amblyopia in the form of a disturbance of vision, caused by the contraction of the pupil and the approximation of the near and the far points. Temporary blindness in cases of general poisoning by physostigmine has in a few instances been reported without further particulars, and fugitive amblyopia is said to have followed injections of pilocarpine.

Eserinum. (L.) Eserine.

Esocataphoria. This term has been used to indicate the tendency of the visual line to curve inward and downward.

Esoche. (F.) Internal hemorrhage.

Esoftalmo. (It.) Exophthalmos.

Esohyperphoria. Excessive esophoria, or an oculomuscular imbalance exhibiting both esophoria and hyperphoria.

Esophoria. Tending of the visual lines inward. There is an esophoria which, because of its nature, may be called "true," or "intrinsic;" while another form should be termed "pseudo." The one kind is entirely distinct from the other, and yet the two often coexist, the one being grafted on to the other. Whatever may be the kind of esophoria, there is a tendency on the part of the interni alone, or with the aid of their synergists, to converge the visual axes at a point between the observer and the object fixed; but this too near intersection of the visual axes is prevented by excessive nerve impulses sent to the antagonizing muscles, increasing their tension abnormally. In the interest of binocular single vision the too great inherent tension of the interni is counteracted by a corresponding nervous tension of the externi.—(G. C. S.) See **Muscles, Ocular.**

Esophoria, Pseudo. See **Pseudoesophoria.**

Esorhinus. Having an angle of between 20° and 0°, formed by the intersection, at the punctum naso-frontale of two lines, the one drawn from the *punctum premaxillare* and the other from the *punctum foraminis incisivi* to the first-named point. See **Ethnology.**

Esotropia. CONVERGENT STRABISMUS. CROSSED EYES. CONVERGENT SQUINT. See page 3297, Vol. V, of this *Encyclopedia;* also **Muscles, Ocular.**

Esox lucius. The common pike. The liver yields an oil (*oleum lucii piscis*) which was formerly employed to disperse opacities of the cornea.

Esprit ophtalmique de Himley. (F.) A solution in ½ oz. of alcohol, of 6 drops each of balsam of Peru, oil of lavender, oil of cloves, and oil of amber; used as an embrocation in eye pains and other ocular symptoms.

Essence of lemon. In the early days of Columbian spirits poisoning some manufacturers of essences, Jamaica-ginger, etc., were in the habit of substituting that form of wood alcohol for grain spirits. For example, Dunn (*Virginia Med. Semi-Monthly*, January 25, 1900) gave an account of a 19-year-old boy who drank two bottles of Jamaica-ginger with lemon essence. This was followed by the usual symptoms—optic neuritis and blindness—as has since been the case in a number of other instances of methylated essence poisoning in America. See **Methyl alcohol**; **Toxic amblyopia**; **Columbian spirits.**

Essential atrophy of the conjunctiva. PEMPHIGUS XEROSIS CONJUNCTIVÆ. Under this term are included all those changes in the conjunctiva associated with hardness and dryness of the lining membrane of the lids. The reader is referred to the various synonyms above given.

Essential nystagmus. A malady of occupation; commonly, miner's nystagmus.

Essential sclerosis of the cornea. According to Nuel (*System of Diseases of the Eye*, Vol. 4, p. 242) this term includes the maculæ that are consecutive to pannus and to parenchymatous keratitis, also those which result from vegetations of the corneal endothelium, and finally opacities that originate in irido-cyclitis and in scleritis. Under the name of corneal sclerosis, *par excellence*, is described an affection in which the cornea becomes porcelain-like, slightly vascular, and irregular as to its surface. The affection extends from the periphery towards the centre, as if it were being encroached upon by the sclerotic. This opacity is a consequence of certain forms of scleritis, and lessens but little in the course of time. In one of the published cases it was due to fatty degeneration of the tissue of the cornea; and in another to hyaline degeneration. In a word, it results from regressive metamorphosis of the tissue of the cornea and that of the cicatrix, and occurs in cases of long-continued faulty nutrition thereof. These maculæ, especially all those which degenerate, are not capable of being cleared up, and when they are deep, as they usually are, treatment by corneal abrasion is of no utility.

Essential shrinking. A term usually applied to pemphigus or other disease of the conjunctiva or cornea, involving shrinkage of the tissues.

Essig. (G.) Vinegar.

Essigsäure. (G.) Acetic acid.

Esslöffel. (G.) A tablespoon.

Essudato. (It.) Exudate.

Estensione d'accomodazione. (It.) Range of accommodation.

Esthesiogeny. The production of altered or perverted sensations.

Esthesiography. A description of the organs of sensation and perception.

Esthesiometer. Æsthesiometer. An instrument resembling a pair of dividers used for the measurement of tactile sensibility. It consists essentially of two movable points, which, being placed upon the skin, are approximated until the two tactile sensations afforded by them are blended into one, and but a single point is felt. The distance between the two points, which is indicated by a graduated scale attached to the instrument, is inversely proportional to the delicacy of tactile sensibility.

Estlander, Jakob August. A Danish surgeon, who devoted considerable attention to ophthalmology. Born at Helsingfors Dec. 24, 1831, he there received his medical degree in 1860, there settled as surgeon, and there became professor of surgery at the University in 1860. He died at Messina March 4, 1881.

Estlander's only ophthalmologic writing was "Ueber Chorioiditis nach Febris Typhosa Recurrens" (v. Graefe's *Archiv.*, XV, 1869).—(T. H. S.)

Estomac. (F.) Stomach.

Estrazione a lembo. (It.) Cataract extraction at the limbus corneæ.

Etat actuel. (F.) Present condition (of the patient).

Etendue. (F.) Amplitude.

Eteroforia. (It.) Heterophoria.

Etheric. Etherical. Pertaining to the luminiferous ether.

Etheriform. Analogous to the ether.

Ether, Luminiferous. A supposed medium filling all space, through which in the form of transverse wave-motion, radiant energy of all kinds, including light-waves, is propagated. This medium, whose existence most modern authorities consider to be established, is thought to be more elastic than any ordinary form of matter, and to exist throughout all known space, even within the densest bodies. Electric and magnetic phenomena can be explained as due to strains and pulsations in the ether.

Ether, Ocular relations of. SULPHURIC ETHER. ETHER ANESTHESIA. ETHER AMBLYOPIA. Ethylic ether (the oxide of ethyl) is a clear, colorless, mobile liquid, which boils at 35° C. It readily dissolves ethereal oils, fats and resins. Its use as an anesthetic is well known and will be found fully described under the caption **Anesthesia,** in this *Encyclopedia.* The purely ocular relations of ether are discussed by Lewin and Guillery (*Die Wirkungen von Giften auf das Auge,* Vol. 1, p. 141), as follows:

The condition of the pupils after the inhalation of ether is less constant than with chloroform; it is, therefore, of less value as a danger signal.

In young children a slight miosis appears at the beginning of the etherization; with complete narcosis mydriasis. In the further course of the narcosis slight miosis shows itself, with almost complete immobility of the pupils. In a limited number of cases one observes slight mydriasis during the period of excitement.

In adults, soon after the first part of the inhalation mydriasis sets in, which in most cases is succeeded by miosis. However, the latter sign may be entirely absent when the muscular relaxation is complete. On the other hand, contraction of the pupils is noticeable for some time after recovery from an ether narcosis, although this miosis shortly gives place to mydriasis, as in chloroform anesthesia.

The corneal reflex is usually well preserved, and at the end of the etherization the contracted pupils also react to light. If asphyxia occurs the pupils are always dilated.

During twelve hundred anesthesias mydriasis occurred six times, accompanied by cyanosis, epileptiform seizures and spasm of the glottis.

Since the earliest employment of ether, the muscular movements of the eyes in anesthesia have been observed. Dieffenbach noticed that the eyeballs roll upwards. Later, nystagmus was noted after and during deep, prolonged narcosis. This action is produced by weakening of the fusion power as well as that of convergence and divergence, so that inward as well as outward movements are limited.

The visual and muscular disturbances sometimes are noticeable as long as an hour and a half after the termination of the anesthesia. The muscles are no longer controlled by the will, so that entirely uncoordinated movements are made, or the coordination is made in a faulty direction.

Ether fumes, especially when inhaled by means of close-fitting masks, often cause reddening of the conjunctiva and increased secretion of tears. This irritation is still further increased if drops of fluid ether find entrance into the conjunctival sac.

Ethics, Medical. MEDICAL DEONTOLOGY. The duties that the medical practitioner owes his patients, his professional brethren and himself. In this country the code of ethics is that of the American Medical Association, whose rules and suggestions are binding as much upon specialists as upon general practitioners of medicine. A discussion of these principles as they in particular affect the ophthalmic surgeon will be found in the *Transactions of the Am. Acad. of Oph. and Oto-Laryng.*, p. 197, 1912.

Ethmoidal diseases, Ocular relations of. See Vol. III, p. 1810, of this *Encyclopedia,* **Cavities, Neighboring, Ocular relations of,** under which this important subject is fully treated.

Ethmolachrymal. Relating to the junction of the ethmoid and lachrymal bones.

Ethmyphitis. ETHMYPHLOGOSIS. (Obs.) Inflammation of connective tissue; cellulitis.

Ethmyphre. (L.) A name given by Hippocrates to connective tissue.

Ethnology of the eye. ANTHROPOLOGIC OPHTHALMOLOGY. ETHNIC EYE DISEASES. The ocular apparatus varies greatly from race to race, particularly in the amount of pigmentation, but the physiological reasons for most of these "characters" have not been discovered. Consequently, though much statistical information has been recorded here and there, it has been of but little practical use. Moreover, only a few races have been studied and there are not yet enough data to warrant safe generalizations. Roure, of Valenci, and Kalt, of Paris, have epitomized the material in anthropological literature, mostly French, and many of the references herewith are taken from their articles in the *Encyclopédie Française d'Ophtalmologie.*

The orbit varies with the shape and size of the skull. The distance between the two orbits is said to be large in the skulls of great cranial capacity and in the brachycephalic, and though it varies from 21 to 28 mm., no rule can be made out. The anterior nasal aperture varies enormously in area in each race, though the narrowest ones are found mostly in the northern races, which have narrow noses and nostrils, while the biggest and broadest apertures are mostly in tropical races, which have a corresponding broad but flat nose. The northern type must have a thin but prominent nose with large warming surface for the cold air, which enters in a thin, ribbon-shaped stream from the slit-like nostrils. This narrowing of the nose tends to bring the orbits together in cold countries, but the larger skulls of the north have the opposite effect. The net result is very little.

The other measures do not seem to have any significance. The depth, for instance, is about 50 mm. in western Europe and 55 among the

brachycephalic Chinese, 56 in dolicocephalic Australians, and 57 in the dolicocephalic Esquimaux.

The area of the opening seems to vary with the size of the skull, being as low as 1100 in races of little intelligence, to 1456 in the larger brained.

The orbicular index, or height of the orbicular opening divided by the width, varies greatly from 77 to over 100. It is 100 in the fetus but lessens with age, and is smallest, strange to say, in some prehistoric skulls, and large in the modern Mediterranean race, Esquimaux and Arabs, though medium in the rest of Europe and in negroes. It is largest, that is, the opening is roundest, in the Chinese, averaging 93.1; in some specimens over 100. It is smallest in Australians and Parisians. It seems to bear no relation to head-shape. The index is increased and the superciliary arches are poorly developed, as in the Chinese, but is only medium in negroes, who have small arches as a rule. Broca has classed the rounder orbits, with index over 89, as *mégaséme*, the *mésoséme* between 89 and 83 and the *microséme* below 83.

The plane of the opening is never transverse, but slopes outward and backward at an angle which may be as low as 131 degrees, but increases to 144 degrees as the prominence of the malar bone throws the outer border forward. The axes of the two orbits converge to the front in monkeys, are parallel in human infants, but always diverge in adults. The angle of divergence may be as low as 3 degrees in the narrow-skulled Esquimaux, or as much as 30 degrees in certain broad heads of eastern Europe. There is some relation of this angle to the frequency of esophoria and exophoria, as well as actual strabismus, but it has not been worked out.

There are said to be differences in the porosity of the orbital plate of the frontal bone in different races, but how much, and their significance, is not known.

The eyelids are very thick in cold climate types, so thick indeed as to give the appearance of dropsy, particularly in the upper lid, which may have a transverse fold of skin dropping over to cover the free border. This variation is unquestionably evolved to keep the globe warm. In tropical races the lids are very thin, but in northern Europe the eyelids not infrequently are almost puffy, though not to the extent of such arctic types as northern Siberians and Esquimaux.

The palpebral fissure varies with the temperature and light. In the arctics or subarctics, where the snow glare is intense, the opening is a mere slit which may be less than the diameter of the pupil. This is done without squinting and must result from a lengthening of

the superior levator palpebræ muscle or its ligament, thus causing a normal ptosis. The natives enhance this effect by wearing protectors of wood which have a horizontal slit about a millimeter across. White men often find such protection necessary in the glare of arctic summers. In the tropics the palpebral fissure is much wider, as there is no need of protection from cold and the pigment is a shield from light. In Europeans the fissure is between the two extremes, but it is to be noticed that the blonder a person is, the more he squints the eye in light climates. In the cities of southern Germany the writer was amazed, on sunny days, at the wide fissure of the very brunette and the painful squinting of the very blonde. The fissure in Mongols approaches the arctic type, being but half that of Europeans, who are pigmented enough for the light. The opening has more of the shape of a scalene triangle, with a very oblique apical angle, and the two commissures are obscured. The horizontal dimension of the opening, from canthus to canthus, averages 27.5 in French males, 30.0 in females, 31 in New Caledonians, 32 in Chinese, 33 in Australians and 33.5 in negroes, but the significance of these differences is unknown.

The obliquity of the interpalpebral fissure, so common in Mongols, seems to be the result of raising the outer canthus by high, prominent malar bones. It is far from universal in that mixture of races we call Chinese, and though no statistics are recorded, it seems to be absent in those types with a long, oval face, and perhaps also dolicocephalic. There is a suspicion that this long-headed type is an extension into Asia of the "Eur-African" race, which is also called the Indian Ocean type, because it is found in and around that sea from Cape of Good Hope to Tasmania. The Asiatic, or broad-headed type, also called Pacific because found in and around that ocean, has sent offshoots all over Europe excepting a few corners and the Mediterranean shore. The oblique eye is therefore found quite frequently in eastern Russia, and in about 15 per cent. of some highlanders and in Arles and Auvergne, where the Alpine type is common. It is found in only 2 per cent. of Bavarians, and is very rare in the extreme northwest and probably absent around the Mediterranean. It is not uncommon in European infants, but disappears in a few years—possibly indicating an Alpine type in the ancestry. Among the Laps the obliquity of the fissure is inverse, i. e., drooping of the outer angle. The cause is unknown.

Epicanthus is said to be fetal (Metschnikoff), and frequently persists until some years after birth, though it always disappears in adult life, except in certain Mongols. Since the lids are glued to-

gether in the fetus, the persistence of a narrow fissure and the epicanthus are said to be instances of arrested development. There is no justification for this opinion, for the epicanthus seems to have a use—a protection of some kind—since it is so common and large in certain plains people.

The *eyeball* is much more sunken in cold-climate races than in the tropical, probably as an additional protection from cold. In the Mongols it is said to be level with the face, but quite prominent in negroes. This might be the reason for the increased depth of the orbit in Chinese and Esquimaux mentioned above. The cartilage, which occasionally appears in the semilunar fold or remnant of the membrana nictitans, is quite common in monkeys and must have some protective value, but it has now undergone involution and is entirely absent in 84 cases out of 85 in Europeans. In negroes it is more common. The size of the globe is practically the same in all races, the small differences have no known significance. The assertion that it is small in the yellow races has no statistical basis as far as known. Roure states that the globes are more widely separated in the negro, but this may be an effect of their prominence.

Pigmentation of the sclera, iris and retina, is unquestionably a protection from the sun, particularly the ultra-violet part of the spectrum. The reasons will be enlarged upon in the article upon light and its effects. Whenever the sclera is subjected to any kind of prolonged irritation, as from dust in ectropion, trachoma, etc., it becomes pigmented. In light countries the exposed parts in the palpebral fissure take on pigment in proportion to the amount of light exposure and the ability of the cells to form pigment. This is not marked in the Mongols and arctic types with a very narrow palpebral fissure, but in the tropics the wider fissure exposes the unprotected sclera. In the Malay pigment is deposited in these places in black or brown spots, which may be three or four mm. in diameter. It may be scattered irregularly or even diffusely. In the Javanese it is still more marked, and in negroes this part of the sclera may be entirely covered and the pigment also extend completely around the cornea and even into the edge of the cornea and over parts of the bulbar conjunctiva, which are only rarely uncovered. This dark ring gives the appearance of a very large cornea.

The sclerotic pigment is quite common in dogs, rabbits and monkeys and serves the same purpose as in tropical man.

The *iris* is blue from the color of the blood in the veins and takes on other colors from the deposition of yellow to reddish-brown patches of pigment in the parenchyma. The more need of protection from

sunshine, the more of this pigment and the browner the eye. There are apparently more statistics of eye color recorded than of any other ethnic character—probably because it is such a good mark of identification for police purposes, and for classification. Since there is an infinite graduation of shades and mixtures from the pale-blue of the albino with no pigment whatever to the dark-brown of the blackest negro, who, by the way, never has a pure black iris, classification is impossible.

Every statistician groups his cases according to his own needs. All pigments are said to be formed from the hematin derived from worn-out red blood corpuscles—at least they are of similar chemical composition, and their color is from the red to yellow part of the spectrum. Chlorophyl, which is of almost identical chemical composition, has a color varying from red to green. The upper part of the spectrum is not represented except in the retinal purple.

The more light there is in a country, the more brown pigment is deposited in the iris as a light screen. The southern part of Norway has the highest percentage of blue-eyed population, and if we draw a straight line in any direction the proportion of this type decreases in the lowlands. In France the blue eyes are mostly in the north, east of the line from Cape Finisterre to Savoy. On the other hand, elevation into the cloudiness of mountains preserves the type. In the whole sub-tropical belt around the world, the uplands harbor blue-eyed people, though the surrounding lowlands may be strongly brown-eyed.

In central Europe and countries with similar climates the mixed types, between the blue of the Baltic race and the brown of the Mediterranean, are the best fitted. These vary from the light-grey, yellow and green to the slightly brown, called hazel and chestnut. The brown is generally deposited in the periphery, though it may be scattered, or even on the pupillary border, and an eye called blue by one observer may be classed as brown by another. There is no known ethnic significance to these minor variations.

The broad-headed Asiatic or Pacific race is generally brown-eyed, but by survival of the fittest its modern descendants in Europe—the Alpine—are largely grey-eyed. Grey eyes are also not at all uncommon in the Mediterranean race, but they are very dark and nothing at all like the blue Baltic eye.

There is also some evidence that races which dwell in dense forests have lighter eyes from the survival of such variations.

The blue-eyed mountaineers are constantly drifting down to the lowlands, where they survive a variable number of generations, accord-

ing to their lack of adjustment. These migrated specimens have given an impression to anthropologists that pigment is not of survival value. The blue-eyed are found even in northern Africa, but they originated in the northern or more shady upper valleys of the Atlas. The brunette eye is found in 97.5 per cent. of Arabs, 65 per cent. of Belgians, 44 per cent. of Englishmen, and much less on the coasts of Scotland and Scandinavia, and still less in the interior of southern Norway, which might be called the center of blue eyes of the world.

The *retina* varies in tint with the color of the skin. In the negro it is reddish-brown, from the deposition of pigment in the retinal epithelium. If there is not sufficient pigment to protect from the sunlight, as in migrants, we find all the diseases grouped under photo-ophthalmia. These are therefore ethnic eye diseases to a great extent, particularly in America.

Fritsch is quoted by Kalt as asserting that in Berbers, the contour of the fovea is clear and the bottom is level, as in the anthropoid apes. In the Soudanese, Arabs and Egyptians, the depth is slight, but in Europeans it is deep. The reason is unknown.

Albinism is found all over the world and is pathologic, not ethnic.

The *color-sense* was once supposed to be appreciably lower in the primitive races, but the examinations of such types at the St. Louis World's Fair, and reported in *Science*, Feb. 4, 1910, by R. S. Woodworth, of Columbia University, show that there is very little difference. On the whole, all races are about the same in ability to distinguish color. The present-day savages are a little defective in the blue and yellow tints, but not of red. Civilized men vary greatly in the width of the visible spectrum, probably no two being exactly alike, particularly in our ability to distinguish the extreme red and violet. But this is the ordinary variation of all species and has no ethnic significance. It has been suggested that the heavy pigment in the retinæ of dark races makes them unable to distinguish faint shades of blue, particularly the greenish blues, since the pigment absorbs these wave lengths. The lower races and children of the higher certainly derive more pleasure from pure, vivid colors, particularly green, yellow and red, which are more or less painful to higher civilized people, but the lower races do perceive the mixed and subdued colors when attention is aroused. Training, then, seems to develop our ability to notice these shades, but not our ability to perceive them. The latest spectroscopic method of testing how much of the ends of the spectrum are dark has not yet been tried on lower races. Some races have only a few words for color, and this was once thought to indicate inability to see the unnamed shades, but it is now known that all races, even the

highest, see colors for which there are yet no names devised, and man unquestionably saw them before he had names for anything. Language gives no hint at all to physiology.

Color-blindness, according to Woodworth, is about the same in all races, being perhaps a little less common in Mongolians, but even this is not certain.

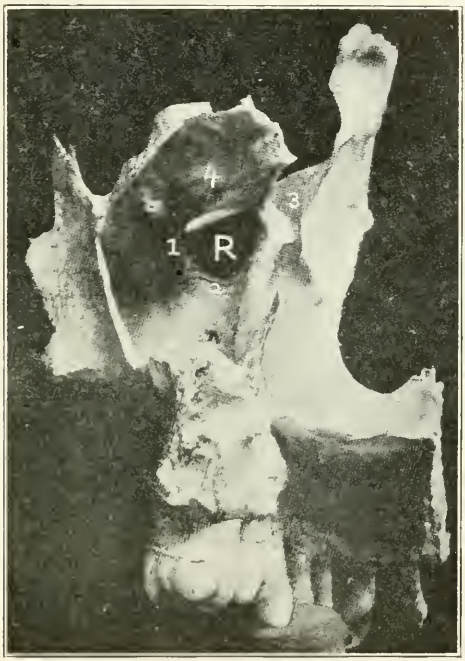

Left Maxilla Seen from Behind. (Whitnall.)

The posterior and medial walls of the antrum have been removed so as to show the lachrymal recess R, the constricted entrance to which is bounded by the infra-orbital canal 1, the anterior superior dental canal 2, the naso-lachrymal canal 3, and the floor of the orbit 4.

The *acuity of vision* is popularly believed to be higher in savage races than in the civilized, but the St. Louis tests showed all races to be essentially equal in keenness of vision. The savage man has often astounded us by the facility with which he interprets distant signs that were unnoticed by his civilized companion. This has now been shown to be a result of training. Savants and experienced explorers learn how to do this better than the natives, or at least as well. Similarly the anomalies of refraction are not at all infrequent in lower races. Myopia is quite common in Germans and others who take up

near-work at an early age when the tissues are more plastic. This was once thought to be evolutionary and ethnic, but it seems to be largely occupational and pathologic, for it is not hereditary as a rule, if at all. It was once thought that the eye in long heads tended to be myopic, and in broad heads hyperopic. In France, for instance, there is less myopia in the central regions than in the more dolichocephalic northeast and southwest. The broad-headed "Celts" or Alpine race are said to have 151 cases per 100,000, the Belgians 391 and the south of France 517. The data are not sufficiently detailed to correlate

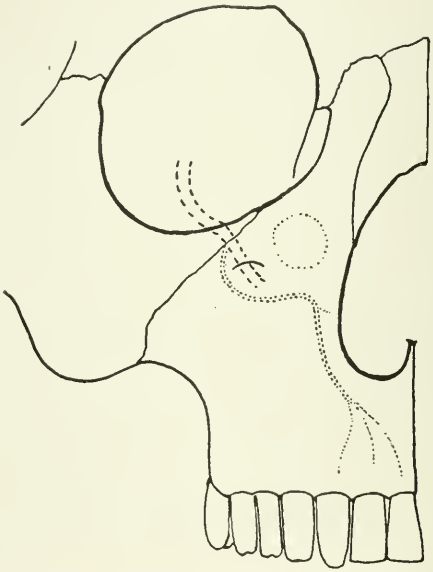

Diagram to Show the Origin and Course within the Anterior Wall of the Maxillary Antrum of the Anterior Superior Dental Nerve (in dotted lines). The circle indicates the position of the lachrymal recess. (Whitnall.)

refraction with head shapes. There has also been an attempt to correlate myopia with deep sockets and hyperopia with shallow, yet the long, myopic eye may bulge out of a shallow socket and the hyperopic sink back in a deep one. Indeed, the races with the deepest sockets—Esquimaux, 57.7; Australians, 56.2; Chinese, 55.6—are not noted for myopia, nor are the shallow socket races noted for hyperopia—Arabs, Basques and Dutch.

Astigmatism is so generally a pathologic acquirement that it is difficult to find ethnic relations. Javal found it common in the French Jews, but the greater curvature was horizontal instead of

vertical, as is the rule in other races. The suggestion has been made that this partly accounts for the manner in which Hebraic letters are written with heavy, horizontal lines. The alleged frequency of astigmatism in asymmetrical skulls is not an ethnic matter.

Ethnic diseases are mostly those resulting from mal-adjustment to light, and are found in migrants—a subject to be dealt with in the article on **Light**. Ethnic immunity or susceptibility to infections is a very important and well-proved fact, but in the enormous and detailed statistics as to the geographic distribution of ocular diseases, there is little which can be surely ascribed to ethnic causes. Negroes, for instance, while comparatively free from trachoma in the United States are affected in the Soudan. In Bavaria there is little or no trachoma, a serious matter farther away in similar ethnic types; while in Constantinople it constitutes 15 per cent. of all eye diseases. The Alpine race has few cases, but the Belgians and Germans have many. Glaucoma is rare in Arabs and Hindus, but common in negroes and the brown-eyed generally. European Jews suffer from it two and a half times more than Christians, but it is so often found in several generations in the same family as to give rise to a suspicion that it is an acquirement rather than an ethnic inheritance.

Nevertheless it might be well to construct maps showing the geographical distribution of each disease, for we might find unexpected ethnic relations. It is far more important to correlate these diseases to each of the ethnic characters, such as pigmentation, for this is a very practical matter in therapy and hygiene. Migrants are greatly injured where natives are immune, as among arctic explorers for instance, and preventive rules are quite practical in many conditions common in the United States. For instance, all the many diseases which should be classed as photophthalmia are much more common in those insufficiently pigmented.

It must be remembered that the evolution of the various types of humanity is accomplished by the preservation of the fittest variations and destruction of the rest by disease or accident. A type which migrates to an environment, which has evolved something entirely different, must suffer from higher morbidity and mortality rates than at the ancestral home. We need a careful ethnic survey, such as was made in Germany by Virchow, and by Tocher for Pigmentation in Scotland (Biometrica, 1908). When ethnic studies of disease demonstrate what types are most affected by particular diseases rules for preservation will more likely follow.—(C. E. W.)

An excellent critique of Stilling's theory dealing with the *influence exerted by the shape of the orbit upon the eyeball* is by S. E. Whitnall

(*Oph. Review*, February, 1913). According to the writer, it was in 1888 that Stilling claimed that shortsightedness is commonly associated with a low orbital aperture, the suggested explanation being that in such microsemic skulls the superior oblique muscle is placed at a lower level than normal, and by compressing the eyeball could cause it to become elongated in an antero-posterior direction with consequent myopia.

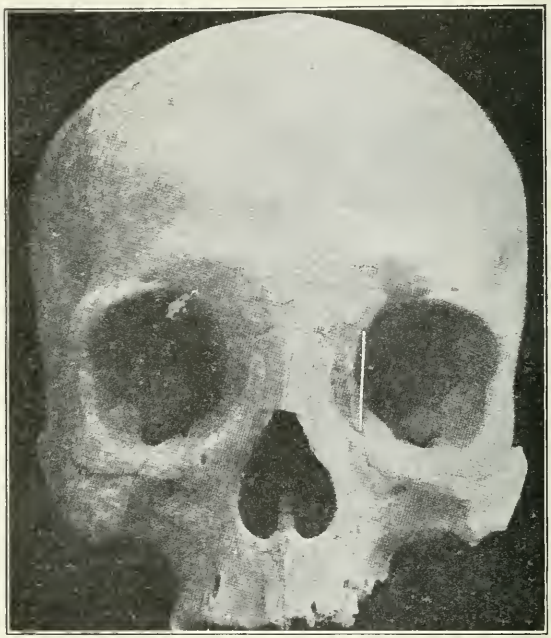

Skull 1. (Borneo.) [Whitnall.]
Skull 1. Right orbit. (Borneo.)
Marginal height 31 mm. Intra-orbital h. 38 mm. Inter-oblique h. 28 mm.

This theory was supported by Seggel (1890), who found that myopia is specially entailed by a low, broad orbit, and Ask (1906), who showed that the short-sighted have a lower orbital index, whereas the Swedes, with rather high orbits, are rarely myopic. Schmidt-Rimpler (1889) on the contrary gave nearly the same orbital index for myopic and emmetropic subjects; moreover, Hamburger (1904) pointed out that a high orbit does not preclude short-sightedness, and that on experimental raising of the intra-ocular pressure by injection of the globe in the cadaver there is no furrow caused by the tendon of the superior oblique: other observers have shown also that the intra-ocular

tension is unaffected by the action of any of the external muscles of the eye.

A point which appears to have been overlooked and which is also detrimental to Stilling's theory is that the position of the pulley (trochlea) of the superior oblique muscle, that is, the point from which the action of the muscle in compressing the globe would originate, is not necessarily correlated to either the height or shape or index of the orbital base.

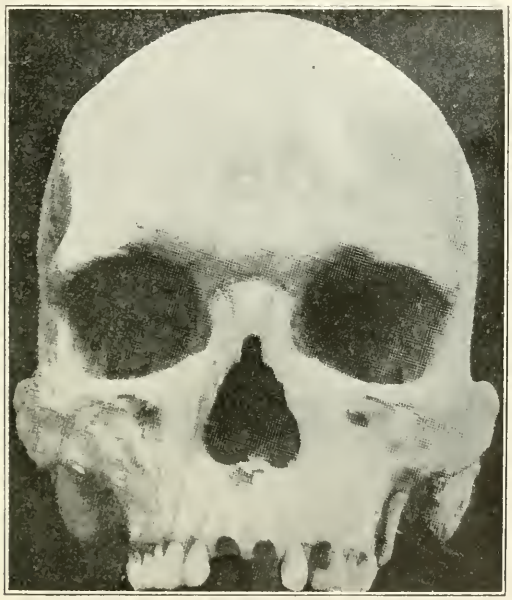

Skull 2. (Australia.) [Whitnall.]

Marginal height	38 mm.	Intra-orbital h. 40 mm.	Inter-oblique h. 28 mm.
Difference	7 mm.	2 mm.	0 mm.

The position of the trochlea is usually marked on the skull by a small depression, the fovea trochlearis, sometimes accompanied by a spine, situated in the fore part of the angle between the roof and medial wall of the orbit and a few millimetres within its margin. In choosing a point from which to measure the position of this site, the one most relevant to this discussion is the shallow fossa which marks the origin of the inferior oblique muscle from the floor of the orbit, adjacent to the opening of the naso-lachrymal canal and lying almost vertically beneath the fovea trochlearis, since the distance which separates these two origins, that of the tendon of the superior oblique

muscle which passes over the globe and that of the inferior oblique muscle which passes beneath it, must be an important consideration in determining any compression these muscles could exercise upon the eyeball. The fossa is much more rarely present in well marked form than the fovea trochlearis, but in its absence the lateral margin of the orifice of the naso-lachrymal canal (ignoring the presence of the hamular process of the lachrymal bone) can be taken as the lower measuring point, for here is often found the slight development of a tendinous origin for the muscle.

The inter-oblique distance then was measured between the center of the fovea trochlearis and the floor of the fossa for the inferior oblique or the edge of the naso-lachrymal canal, skulls being chosen in which these points could be undoubtedly defined. The orbital height was taken at the base (marginal height) and also at its most roomy dimension within the margin (intra-orbital height); both measurements were taken because the terms "low orbit" or "flattened orbit," which, strictly speaking, should refer to the cavity of the orbit, are often loosely used in reference to the margin as well. It will be seen that the dimensions of neither margin nor cavity are closely related to the distance between the origins of the oblique muscles of the globe.

The results of a comparison of these three measurements in thirty skulls, ten being European and twenty of varied races, are as follows:

	Extremes of variations between measurements.		Difference.
Orbital height at margin....	30.3 mm.—38.5 mm.	...	8.2 mm,
Intra-orbital height	35 mm. —43 mm.	...	8 mm.
"Inter-oblique" distance ...	28 mm. —30 mm.	...	2 mm.

The full list of measurements, taken to the nearest half-millimeter, is appended. It may be of interest to note that the vertical diameter of the globe is about 23.5 mm.

STILLING'S THEORY.

Skull.	Height at margin.	Height within margin.	Inter-oblique distance.
European	32.5	38	29.7
European	31	36	29.5
European	34	40	27
European	35.5	37	28
European	36	38.5	29
European	34.5	40.7	28.5
European	32.2	40	29

Skull.	Height at margin.	Height within margin.	Inter-oblique distance.
European	32.3	40	29
European	33.7	38	28.5
European	34	40	28.5
Australian	30.3	35	28
Australian	35	37	29
Ancient Egyptian	33.5	40.5	29.8
Australian	31	38	28
New Guinea	35	37	28.4
Esquimo	35.8	39.5	29
Esquimo	35	39.8	29
Esquimo	35	37.5	29
Esquimo	35	37.5	30+
New Zealand	36.5	39.5	30
New Zealand	38.5	40	30
Indian	32	36	30
Indo-Malay	37	39	29
Amboyna	32	37	29
Peru	34	39	28
Patagonia	35.5	43	29
Samoa	37	42	30
Borneo	38	40	28
African	34	—	29.5
Negro	37	36	30

30 skulls of various types. Right orbits in each case. Measurements to nearest ½ millimeter.

According to Whitnall these measurements show that the distance between the origins of the oblique muscles (taking the trochlea as being the place from which the action of the superior oblique originates) of the globe is less variable than either the orbital height at the margin or within the cavity, and that the size of the orbit cannot affect the shape of the eyeball through the agency of the superior oblique muscle.

L. Steiner (*Zeitschrift für Morphologie und Anthropologie*, x. 3, 1908), who practised as an ophthalmic surgeon in Java, has written an interesting paper upon the peculiarities of the eye of the Javanese, illustrated by a few beautiful colored sketches. The first thing which strikes one, he says, is the apparent small size: this means merely (we gather) that the palpebral aperture is narrow and exposes a com-

paratively small portion of the surfaces as contrasted with the European; but then the Javanese is usually a smaller person altogether. On the ocular conjunctiva irregular, brownish spots are frequent, as they are on other mucous membranes, e. g., those of the palate, gums, and vagina; these usually are more marked in those of advanced years; in older persons the whole visible sclera (which itself has a brownish tinge) may be spotted over with these masses, especially at the limbus. Frequently, too, there are large, dark, almost black, splashes of pigment on the posterior surface of the upper lid. The iris is very dark-brown, hardly distinguishable from the black pupil. He tells us that the fundus differs very materially from that of the European.

Ethyl alcohol. Grain alcohol. Spirits of wine. Hydrate or hydrated oxide of ethyl, $C_2H_6O = C_2H_5.OH$; a clear, colorless, mobile, very volatile and inflammable liquid of burning taste and peculiar, pleasant ethereal odor, occurring in a dilute state in all beverages formed by the vinous fermentation of saccharine and starchy vegetable substances, and prepared in a pure state from these beverages by repeated distillation (rectification) and by dehydration with alkalies. It also occurs ready-formed in various vegetable substances, and occurs in coal-tar, bone-oil, and other products of organic distillation, as well as in bread. It has never been frozen, although at extremely low temperatures it becomes viscid. Boiling point, 78.3° C. Its sp. gr. varies greatly with the temperature, being 0:80625 at 0° C., 0:79367 at 15° C., 0:7809 at 30° C. It is very hygroscopic, and cannot be freed by distillation alone from the moisture which it absorbs. It unites with various mineral salts, in the same manner that water does, to produce compounds, with one or more molecules of alcohol of crystallization. It is freely miscible with water, chloroform, ether, and benzene, and is a solvent for volatile oils, concrete oils (such as camphor), resins, phosphorus, iodine, bromine, and many other substances. On account of this solvent power it is largely employed in the arts and pharmacy as a vehicle. Solutions of medicinal substances in ethyl alcohol are called *tinctures* and *spirits*. Locally, ethyl alcohol, owing to its volatility, acts as a refrigerant, and when its evaporation is prevented, as an irritant and astringent, dehydrating moist surfaces, and coagulating albumin. Internally administered in moderate doses, it acts as a cardiac stimulant, particularly in cases of enfeebled cardiac action, but in excessive doses diminishes both the rapidity and force of the heart-beats. Small doses contract the arterioles (particularly in inflammatory conditions) and raise the blood-pressure and body temperature; large doses dilate the arterioles, diminish the blood-pressure,

and lower the body temperature. Small doses likewise act as a stimulant to the gastric mucous membrane, the liver, and the cerebro-spinal centres, while large doses interfere with the functions of all of these organs. Applied in excessive or in continued doses, ethyl alcohol produces the condition called alcoholism, which may include an alcohol amblyopia. Ethyl alcohol is mostly eliminated unchanged by the lungs, kidney, and skin, but a small portion is oxidized in the body. This fluid is official in all of the pharmacopoeias. (Foster.) See, also, **Alcohol**; as well as **Toxic amblyopia.**

Ethylaminoacetobrenzcatechin hydrochloride. See **Homorenon.**

Ethylaminoketone. See **Homorenon.**

Ethyl-benzoyl-cocain. See **Homococain.**

Ethylbenzoylecgonine. See **Cocaethyline.**

Ethyl bromid. Monobromethane. Hydrobromic ether. Bromic-ether. C_2H_5Br. This substitute, as an anesthetic, for ether and chloroform is a colorless, inflammable, volatile liquid, with a burning taste. It is insoluble in water and boils at 39° C. Although it is an efficient anesthetic yet it probably presents no advantages over common sulphuric ether.

Ethyl bromid, Eye symptoms from inhalation of. Inhalation of ethylbromid may induce reddening of the eye, lachrymation and hyperemia of the conjunctiva. The pupils may become dilated soon after beginning the narcosis and remain until its completion. These symptoms were noticed in several hundred cases. On the other hand, in a case of fatal ethyl bromide narcosis with paralysis of the heart a contracted pupil was noted. Immediately after the cessation of attempts at resuscitation (heart massage) a dilated pupil was noticed. In this instance the usual rule applies, viz., on the appearance of disturbed respiration or cyanosis during narcosis the pupils become dilated. In another case the eyes turned convulsively upwards about ten seconds after the narcosis had been well under way. In one instance only has ethylbromid narcosis caused permanent loss of vision.

Ethyl chloride. Monochlorethane. Kelene. Chelene. C_2H_5Cl. At ordinary temperatures this compound, made from ethyl alcohol by the action of hydrochloric acid, is a gas. It is easily compressed into a colorless, very volatile liquid. Kelene is highly inflammable and burns with a green flame. It is commonly used in minor and dental surgery as a local anesthetic in the form of a spray, the heat of the hand being sufficient to force a stream from the tube in which it is marketed. The end of the tube is generally held from 6 to 10 inches from the surface to be sprayed.

It is also used as an inhalant for producing general narcosis.

Rapid and complete anesthesia is produced by this drug, but if it be inhaled in large quantities, or if air be excluded for even a few minutes, there is great danger of respiratory paralysis and failure of the heart's action. Nausea and vomiting follow its use so that it is not well adapted to ophthalmic surgery. Moreover, it does not relax the muscles as well as ether or chloroform.

Occasionally ocular symptoms are produced from contact with the external eye. One of these is keratitis followed by an opacity of the cornea.

Ethylenbromid, Oculo-toxic symptoms from. ETHYLENE BROMIDE. This poisonous agent is occasionally prescribed or taken, in error, for ethylbromid. Persons who inhale the fumes of ethylene bromide show a marked conjunctivitis in addition to the severe general symptoms. Pupillary disturbances also occur.

Ethylene chloride. ETHYLENE DICHLORIDE. LIQUOR HOLLANDICUS. DICHLORETHANE. DUTCH LIQUID. ETHYL CHLORIDE. This is a colorless, oily liquid with a rather pleasant odor and sweet taste. The vapor is irritating. It is soluble in alcohol and slightly soluble in water. It has been used as a general anesthetic instead of chloroform for operations on the eye, but its use for that purpose has been very properly restricted.

According to Parsons (*Pathology of the Eye*, p. 1007) clouding of the cornea, first observed by Dubois, may occur after continued inhalation of ethylene chloride. This is probably due to necrosis of the endothelium. There is also considerable conjunctival injection with lachrymation and photophobia; while the cornea becomes white like porcelain, and the pupil is dilated. The opacity, after a week or more, commences to clear from the periphery towards the centre; occasionally the cornea becomes conical. Microscopically, there is necrosis of the endothelium and edema of the substantia propria, the epithelium being normal. The condition may be induced also by the subcutaneous injection or introduction into the anterior chamber, but not by the action of the vapor upon the cornea nor by instillations.

The effects of inhalation and subcutaneous injection of ethylene dichlorid on the eyes of dogs, rabbits and guinea pigs have been investigated by Erdmann (*Archiv. für Augenheilk.*, p. 63, Vol. 73, 1912). In the dog a parenchymatous opacity of the cornea develops from edema of the ground substance of the cornea in consequence of a lesion of the endothelium. In the majority of cases the cornea clears up from the periphery towards the center after regeneration of the swelled or detached endothelium. In insufficient regeneration, especially in older animals, the opacity may stay for months or permanently. After

the clearing of the cornea renewed inhalations may again produce an opacity. A tolerance to the poison has not been observed. The pathological process consists in simple edema, never complicated by inflammatory infiltration or vascularization. The epithelium also suffers an edematous imbibition, indicated by expansion of the intercellular spaces and the formation of vacuoles, but it is never elevated in form of vesicles. Tension is not unfrequently lowered. In longer duration the spongy parenchyma may present larger lacunæ filled with fluid and detached, partly necrosed, lamellæ. After transient edema complete restitution may occur. Chronic edema may lead to immigration of pigment into the epithelium from the limbus and to the formation of a sub-epithelial, nuclear, fibrillar tissue, causing, with the irregular arrangement of the fixed cells and the undulary course of the lamellæ, the remaining opacity of the cornea after subsidence of the edema. The edematous cornea by yielding to the intraocular pressure may assume a greater curvature.

The parenchymatous opacity of the cornea, produced by the absorption of ethylene dichlorid, resembles the edematous opacity following direct mechanical or chemical lesions of the endothelium from the anterior chamber. It is also similar to certain, not inflammatory, congenital opacities of the cornea in man, which are mainly due to swelling of the parenchyma in defects of Descemet's membrane or permeability of the endothelium. In some cases a deleterious influence on the epithelium of the lens capsule was apparent by the development of blister cells at the equator. Hyperemia and formations of blisters on the ciliary processes were ascertained as a consequence of the passage of the poison from the circulation into the aqueous.

Injection of ethylene dichlorid into the anterior chamber produced intense local inflammatory changes. Vapors of ethylene dichlorid striking the eye directly cause intense inflammations and a lesion of the cornea with shrinking, which by longer action may extend to the endothelium and may be followed by an edematous imbibition of the damaged parenchyma. Erosions developing on the edematous cornea in form of streaks or areas heal normally. If the edema spreads to the epithelium a single instillation of fluorescein stains the whole thickness of the edematous parenchyma diffusely green.

Ethylene dichlorid is ophthalmologically of great interest, as it enables us to produce in the dog a lesion of the corneal endothelium with subsequent edematous opacity of the cornea by absorption, without essential damage to the other parts of the eye. See **Toxic amblyopia.**

Ethylhydrocuprein chloride. See, for a full description of this agent, the end of the section on **Cornea, Serpent ulcer of.**

Ethylidenediamin. A poisonous ptomaine obtained from decomposing fish, e. g., from haddock. Injections of the ptomaine in mice and guinea-pigs produce abundant flow of secretion from the nose, mouth, and eyes; the pupils dilate and the eyeballs project. Violent dyspnea follows and continues until death, which does not take place for twenty-four hours or more. The heart is stopped in diastole.—(Gould.)

Ethyl-morphine hydrochloride. See **Dionin.**

Ethyl-morphin iodide. This agent is allied to dionin—the ethyl-morphin hydrochlorid. Because of good results obtained by using iodoform with dionin (ethyl-morphin-hydrochlorid) Sylla (*Woch. f. Therap. u. Hyg. d. Auges*, Feb. 10, 17, 24 and Mar. 3, 1910) was led to try ethyl-morphiniodide as a substitute. It is less soluble than dionin, only 4 per cent., and on that account is commonly used in powder. It produces much less pain, hyperemia and edema than dionin. But Sylla claims it is equal to the latter in power of stimulating resorption. To preserve in full its activity ethyl-morphin-iodide should be kept in bottles of smoked, black or gray glass. Hillegas (*Homeo. Eye, Ear and Throat Jour.*, Vol. 16, p. 311, 1910) reports good results from the use of this drug in powder, and also in 2 per cent. solution, in ulcer and burn of the cornea.

The Editor has employed this remedy in the form of powder as a substitute for dionin and finds it of considerable value. He generally reserves its employment for those cases in which the latter remedy fails, either from prolonged use or for other reasons, to produce the conjunctival edema that chiefly indicates a favorable reaction.

Ethyl nitrite. NITROUS ETHER. The "spirits" of nitrous ether is a 15 per cent. solution of true ethyl nitrite in ethyl alcohol. It is a yellowish, ethereal, aromatic, inflammable and very volatile liquid. There are very few oculotoxic symptoms attributed to its employment, although it is readily absorbed by the capillaries and lymphatic vessels. When inhaled or taken internally it converts oxyhemoglobin into methemoglobin. Large doses may produce general collapse with almost imperceptible pulse, or, in other cases of poisoning, acceleration of the pulse with cyanosis and dilatation as well as immobility of the pupils.

Ethyl phenylcarbamate. See **Euphorin.**

Etincelle. (F.) Spark.

Etiolated cataract. An obsolete term for a very white, stellate opacity in the lens.

Etoilé. (F.) Stellate.

Etourdissement. (F.) Dizziness; vertigo; stupor; shock.

Ettmüller, Christian Friedrich. An eighteenth century German physician, of some ophthalmologic importance. Born at Altgersdorf, near Zittau, in 1773, he received his medical degree at Wittenberg in 1796, and afterwards entered the army in a medical capacity. He was also for a long time county physician (Kreis-Arzt) at Delitsch. In addition to numerous works of a general medical character, he wrote the following: 1. Abhandlung über die Krankheiten der Augen und Augenlider. (Leipsic, 1799.) 2. Von den Mitteln, die Gesundheit der Augen zu Erhalten. (Lübben, 1800; 2d ed., 1802.)—(T. H. S.)

Euæsthesia. (L.) A normal condition of the senses.

Eucain. This important drug, chemically allied to cocain and used as a substitute for that anesthetic, was first recommended by Merling. There are two modifications of this agent, eucain "A" and "B"—now called "Alpha-eucain" and "Beta-eucain" respectively. Alpha-eucain is a synthetic derivative of triacetonamine; beta-eucain is derived from vinyldiacetone-akalmine. Both are proprietary remedies and were issued by the same firm but the latter is the one now recommended as a cocain substitute under the trade name beta-eucaine hydrochloride or eucaine hydrochloride-B. The drug does not blanch the conjunctiva and its instillations are occasionally painful.

In 1 to 3 per cent. watery solution, beta-eucain does not produce mydriasis or paresis of accommodation, is not poisonous and is less liable to decomposition than cocain and can be boiled without decomposing. The lactate is by several ophthalmologists, including Darier (*Thérapeutique Oculaire*, p. 77), regarded as a desirable and efficient local anesthetic. It is much more soluble than eucaine-B chloride and quite as stable. In eye surgery it is used in 2 to 15 per cent. solutions. It enters, with suprarenaline, into the composition of eucapren (q. v.).

Eucain (Beta) lactate. BENZOYLVINYLDIACETONEALKALMINE LACTATE. This compound is a white powder, soluble in five parts of water, 9 of alcohol and 20 of glycerine. It is a valuable local anesthetic and owing to its greater solubility in water than eucaine is preferred to it in many mixtures. Alone it is employed in from 2 to 15 per cent. solutions.

Eucalyptus oil. The volatile oil obtained from *Eucalyptus globulus*, or Australian blue-gum tree, is a colorless or yellowish liquid used both for inhalation (in asthma) and as an external application in skin diseases. In doses from 5 to 15 minims it is taken internally, usually in the form of an emulsion. Lewin and Guillery (*Die Wirkungen von Giften auf das Auge*, Vol. 1, p. 130) state that in cases of poisoning from large doses of this agent the pupils are contracted and immovable.

Eucapren. EUCARENALINE. This is a proprietary combination of a one per cent. solution of beta-eucaine lactate with 0.5 milligrm. of suprarenalin per c.c. It is marketed by Armour & Co., and used like cocarenaline and similar compounds as a local anesthetic, hemostatic and blanching agent in ophthalmic operations. The Editor can speak confidently of its value.

Eucerin. The trade name of an ointment base said to be prepared from the "pure wax alcohol of wool fat," and to be superior to wool fat, petrolatum or any of the paraffin bases. According to the proprietors, the advantages of eucerin in ophthalmic practice are chiefly due to the fact it is neutral and not affected by acids or bases, with both of which it gives perfectly durable mixtures. It never turns rancid, and its keeping qualities are unlimited. It is homogeneous and odorless, and of perfect ointment consistency. It forms with all liquids, aqueous solutions, and water—of which it takes up to 150 per cent.—permanent, durable, homogeneous mixtures, and therefore is especially suited for cooling ointments and pastes. Owing to its hydrophilic nature, eucerin is readily absorbed by the skin, and therefore brings any medicaments incorporated with it quickly and surely to action even in the deeper parts of the epidermis. Eucerin anhydrous is suitable for ointments of all kinds, but especially those which are to take medicaments in the form of aqueous solutions, as liquor aluminii acetici, resorcin, potassium iodide, and others. Eucerin hydrous has all the advantages of the eucerinum anhydricum, but is preferable for ointments or pastes which are to be prepared with powders insoluble in water—boric acid, zinc oxide, tar, etc. As an ointment in itself it is very suitable as a covering and cooling ointment for injured and inflamed parts in place of glycerine, lanoline, or cold cream.

Euchlore. EUCHLORIC. Having a distinctly green color.

Euchromatopsia. Correct recognition of colors. Normal color sense.

Euclid. A mathematician, optician and astronomer who flourished at Alexandria B. C. 280. His school of mathematics was not only the first to be established at the Egyptian capital, but it remained in useful existence until the Mohammedan conquest (7th century A. D.). Euclid wrote *"Elements," "Data," "An Introduction to Harmony," "Phenomena," "Optics"* (certainly genuine), *"Katoptrics"* (now certainly known to be spurious, and attributable, probably, to Theron).

Because of his work on *"Optics,"* Euclid is easily the "father" of that subject. In this book the following passages are of especial historical interest: "We must accept that the visual rays which pass out from the eyes, proceed in straight lines, leaving between them certain intervening spaces. The figure formed by the visual rays is a

cone, whose point lies at the eye, its base, however, upon the edges of the visual objects. We see only those things on which fall these visual rays; we do not see those things on which these rays do not fall. No visible object is ever seen as a whole simultaneously. We seem, however, to see the whole object, because the visual rays are rapidly moved from one side to another."

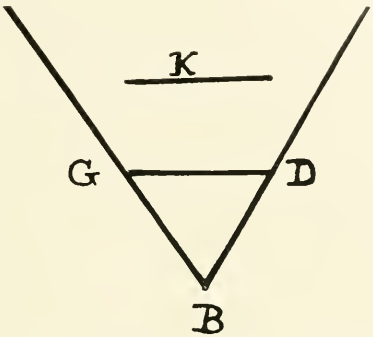

A Demonstration in Optics. (Euclid.)

The following passage, as pointed out by Hirschberg, is the earliest mention in history of what is known today as "the smallest visual angle." "For every visible object there is a certain distance from the eye at which it ceases to be visible. Let B be the eye, GD the visible object. I now assert that GD, at a certain distance from the eye, remains no longer visible. Let GD be brought into the interval between the visual rays at K: then no visual ray proceeding from B will fall upon K."

It is really a wonder that Euclid did not, advancing just one step farther, invent a card of test-types.—(T. H. S.)

Eucyclos. (L.) Orbicular; circular.

Eudrenine. This is a concentrated solution of eucaine and adrenaline. Each cc. contains eucaine 0.15 grain (0.01 gm.) and adrenalin 1-2000 grain (0.03 mgr.). One-half to 1 cc. is suitable for ordinary hypodermic dose. Diluted with four volumes of normal saline solution it forms a solution suitable for local infiltration anesthesia.

Euelpidion. EUELPIDIUM. An ancient and obsolete term for a liquid collyrium.

Eugenia corymbosa. A species of plant found in the East Indies. An infusion of the bark is used in ophthalmia.

Eugenic acid. See **Eugenol.**

Eugenics. The science and art of improving the human race by applying the ascertained laws of inheritance of characteristics to the selection of marriage mates, with the aim of securing to the offspring a desirable combination of traits, including resistance to untoward

conditions; the term was first used by Sir Francis Galton in 1884.—(*Standard Dictionary.*)

C. P. Franklin (*Jour. Med. Soc.*, New Jersey, Vol. 9, p. 437, 1913) has discussed the special relations of eugenics to the ophthalmologist.

Eugenol. Eugenic acid. $C_{10}H_{12}O_2$. This agent is a colorless, oily liquid which darkens on exposure. It is an oxidation product of oil of cloves, with a strong clove odor, and is a powerful antiseptic and antiputrescent. While it reduces the sensibility of the conjunctiva and cornea it does not bring about complete anesthesia.

Eugenol acetamide is a crystalline, non-caustic antiseptic, like eugenol. It has a strong clovelike odor and has been recommended as a local anesthetic. It produces considerable anesthesia of most mucous membranes but there does not seem to be any reason why it should ever displace cocaine, eucaine or alypin in ophthalmic therapy

Eukinesia. (L.) Normal power of movement.

Euler, Leonard. A famous optician and professor of mathematics, who, during the last seventeen years of his life, was totally blind.

He was born, the son of a Protestant minister, at Basle, Switzerland, April 15, 1707. When twenty-eight years of age, he became blind in one eye as the result, according to some, of three days uninterrupted reading and thought, according to others, however, of a severe fever. At the age of fifty-nine, Euler lost the other eye. Twelve years later (in 1778) he received at the hands of a famous oculist, Baron Wenzell, a complete restoration of the sight of one eye. Soon, however, owing, it is said, to long-continued reading, he became completely blind again, and so remained until his death.

Euler, after the onset of his blindness, wrote a number of valuable books—one, in particular, on algebra, of very high repute, and several, of scarcely less repute, concerning the moon. He was wont to declare that his powers of mind had been enormously increased by his blindness, and that he had no cause at all to regret what, to others, must have appeared as an inexpressible calamity.

In 1730 he became professor of Physics at the Academy in St. Petersburg, and in 1733, in the place of Bernouilli, professor of the higher mathematics in the same institution. In 1741 he went to Berlin as Director of the mathematical class. In 1736 he published "*Mechanica sive Motus Scientia Analytica Exposita,*" a valued contribution to its subject. He was also very active in the field of optics, bitterly opposing both the omission theory of light and also the theory of immediate action at a distance. Euler it was, in fact, who, next to Fresnel, afforded the greatest service in establishing on a firm (it would almost seem a permanent) foundation the theory of a luminiferous ether. And Euler himself was blind!

On the 7th of Sept., 1783, the brilliant blind man, who had done so much to increase our knowledge of the world visible, as well as the manner of its visibility, passed from life, as, long before, he had passed from light. He had dined with Lexell, and had been conversing on the newly discovered planet, Herschell, and also on the motions of balloons, when, just as he began to play with his grandchild, he fell over suddenly and expired.—(T. H. S.)

Eumydrin. ATROPIN METHYL NITRATE. METHYLATROPIN NITRATE. This remedy is a white, odorless crystalline salt resulting from the action of atropin on methyl nitrate. It melts at 160° C (325° F.) is readily soluble in water and alcohol; sparingly dissolved by ether.

This agent is employed as a substitute (although its action is distinctly weaker) for atropia on account of its non-toxic quality.

Goldberg noticed that a one per cent. solution acts from five to eight minutes quicker than a 1 to 1000 solution of atropin, producing a dilatation of the pupil from 2.5 to 3 mm., and that its effect disappears toward the end of the second day, while the atropia mydriasis is still present on the fourth day. It acts more rapidly and thoroughly than homatropia solution of the same strength and its effects last about twelve hours longer. As a ciliary and iridic paretic agent it ranks between atropia and homatropia. In pathologic conditions the effects of a one per cent. solution seem to be about the same as that of one per cent. atropia solution, but it is not so lasting. Moreover, the drug produced no increase of pressure or other untoward phenomenon either in the normal or diseased eye.

Euonymin. This agent is a glucoside mixture obtained from the bark and root of *Euonymus atropurpureus*, the burning brush, bitter ash, or American arrow-wood tree. It is a yellowish powder. In its action on the eye it resembles digitalis; in large doses it causes a mydriasis.

Euphlogie. (F.) Slight, transitory inflammation.

Euphorbia nivulia. A species indigenous to the East Indies, very much like the *Euphorbia ligularia*. The juice of the leaves, warmed, is used for earache, and is sometimes rubbed over the eyes to remove dimness of sight.

Euphorbium. Gum-euphorbium, the concrete resinous juice of certain species of *Euphorbia*. Its precise source is unknown, having been ascribed to *Euphorbia officinarum, esula, canariensis, antiquorum*, etc., but it is now thought that *Euphorbia resinifera* is its chief source, most of it coming from Morocco and Barbary. It occurs in the form of tears or oblong masses of about the size of a pea, with small holes produced by the prickles of the plant, and has a light-yellowish or reddish color, acrid taste, and slight odor. It contains resin, wax, calcium malate, lignin, bassorin, volatile oil, and water, and is violently emetic

and cathartic. Largely diluted with wheat-flour or starch, it is employed as an errhine in amaurosis, deafness and other obstinate affections of the head.—(Foster.)

Euphorin. Ethyl phenylcarbamate. Phenylurethane. A white, colorless, crystalline powder with a faint aromatic odor and an aftertaste of cloves. It is sparingly soluble in water, more soluble in alcohol. It is an analgesic and antiseptic and is generally used in powder form as an ointment.

Euphorin was recommended in 1890 by L. Sansoni (*Therapeutische Monatshefte,* 1890, p. 452) as an antiseptic for the treatment of obstinate corneal ulcers and chronic ophthalmia, in the form of a powder, but this method of treatment appears to have passed into oblivion.

For the relief of the pain of herpes zoster ophthalmicus it has been prescribed as a dusting powder to be applied to the scabs or vesicles.

Euphos glass. According to F. Schanz (*Ophthalmology,* Vol. IX, Jan., 1913) this is a yellow-greenish tinted glass which absorbs the ultraviolet rays of light, at the same time weakening the visible rays as little as posible. It is made in two shades, "A" and "B." Shade "A" is used for ordinary cases of eye protection, such as in hunting, automobile drivers, etc. Shade "B" is employed for guarding the eyes against very strong lights, such as high-power electric lamps, reflections from sunlight on the snow, and in such occupations as that of glassblowers, and electric arclight regulators. Roald Amundsen of the South Polar expedition wrote that he and one other member wore them during the whole time he was seeking the South Pole, and did not have a symptom of snow-blindness, while his companions, who used other glasses, were all more or less affected.

Meyer (*Woch. f. Ther. u. Hyg. des Auges,* July 3, 1913) gave euphos glass a thorough trial while on a three weeks' cruise on a man of war. His experience with this glass, under most variable conditions, was so satisfactory that he is convinced it will prove serviceable in both the army and navy.

Wearing such glasses, he found the dazzling due to the reflection of the sun's rays by the water, the glare of searchlights, etc., distinctly lessened without visual acuity being impaired; on the contrary, he frequently noticed improvement of vision. For example, when his boat was leaving the harbor the sun was directly behind, and it was impossible to discern that part of the coast line with the glare, but with euphos glasses the coast line appeared of normal outline.

He also contends that with these glasses vision at twilight is improved, because the shadows appear intensified, and that prolonged wearing of the glasses results in more rapid dark adaptation, a factor which certainly ought to prove of value in these days of modern warfare,

with night marches and night engagements rather the rule than the exception.

Euphrasia. EYEBRIGHT. EYEWART. EUPHRASY. *Euphrasia officinalis* is a species commonly found in heaths and dry meadows, formerly held in high repute for its medicinal virtues, the variety *pratensis* being recommended as the best because its herb, *herba euphrasiæ* (seu *euphragræ,* seu *ophthalmica,* seu *ocularia* (Ger., Augentrostkraut, Augenkraut) contains more of the astringent and bitter properties than the other varieties. Its use was recommended by the old herbalists both outwardly and inwardly, in powder and in decoction, for diseases of the eyes. It is still a domestic remedy, and has been recommended for colds in the head.—(Foster.)

Euphrasy was once supposed to be of marvelous efficacy in clarifying the vision. Hence, Milton, "*Paradise Lost,*" Book XI:

". . . but to nobler sights
Michael from Adam's eyes the film removed,
Which that false fruit that promised clearer sight
Had bred; then cleansed with euphrasy and rue
The visual nerve, for he had much to see."—(T. H. S.)

Euphthalmin. This agent is usually prescribed as the hydrochloride. It is a colorless, crystalline powder, very soluble in water and alcohol and, chemically, is a mandelic acid derivative of beta-eucaine.

Two drops of a 5 per cent. solution produces complete dilation of the pupil, with very little effect upon the ciliary muscle, in about 60 minutes. This lasts about two hours with a return to the normal size in 24 hours.

Jackson has used it combined in equal parts (two per cent.) with cocain for ophthalmoscopic examination. It produces in this combination the most satisfactory mydriasis, with the least annoyance to the patient, in from fifteen minutes to half an hour. Its employment is quite free of pain, vascular injection, rise of intraocular tension or corneal irritation. As mentioned before, the patient into whose eyes any cocain mixture is exhibited should keep them closed at least one-half the time until the ocular examination is made.

European institutions for the blind. See **Institutions and occupations for the blind**; as well as **Alphabets and literature for the blind,** on page 1124, Vol. 2, of this *Encyclopedia.*

European walnut. See **Walnut, English.**

Europhen. CRESOL IODIDE. This proprietary compound contains 27.6 per cent. of iodine. It is a light-yellowish, aromatic, amorphous powder, analogous to thymolis iodidum, U. S., and, like it, is occasionally used as a dusting powder in substance, or mixed with boric acid for the same purpose, in chancre of the lids, corneal ulcer, trachoma,

etc. It may also be employed as an ointment (5 to 10 per cent.) with lanolin, lard, or other excipient in various forms of blepharitis. It has not the disagreeable odor of iodoform and for that reason is preferred by some in treating lid wounds and for other ophthalmic purposes.

Europisocephalus. This term was applied by Mayer to a skull broad in the occipital region.

Eusebius Asiaticus. A blind Christian philosopher of the fourth century. He wholly lost his sight when five years old, but became a famous preacher and philosopher notwithstanding. Nothing else is known about him.—(T. H. S.)

Eusémie. (F.) The whole of the favorable symptoms noticed during an illness.

Eusemin. This is the trade name of a member of that numerous class —combinations of a local anesthetic with a suprarenal derivative. It is a mixture of 0.00075 per cent. of cocain with 0.0005 of adrenalin and recommended chiefly for intracutaneous, hypodermic and subconjunctival injections. Half a cc. suffices for advancement of a tendon; 1 to 2 cc. is enough for enucleation.

Ideler (*Therapeutische Monatshefte*, July, 1907), who had employed eusemin both by instillation and injection in one hundred minor operations on the eye, states that the results were almost always satisfactory.

Vossius (*Deutsch. Med. Wochenschr.*, Dec., 1906) has performed extirpation of the lachrymal sac under eusemin.

Euthelioma. A name given to non-malignant intraocular tumors, especially to innocent tumors of the ciliary body. They are also referred to as *adenoma*, *epithelioma benigna*, and (by Fuchs) as *innocent tumors of the ciliary epithelium*. See **Ciliary body, Tumors of the.**

Euthyopisthocranius. (L.) A term used in ethnic examinations to describe an angle of between 154° and 172°, formed by the union of two lines drawn from the external occipital protuberance and the *punctum occipitale*, at the point upon the skull highest above the horizontal plane.

Euthyuranus. (L.) In cranial measurements, having an angle of from 163.5° to 180° formed at a point highest above and in the same vertical plane with a line drawn from the *punctum occipitale* to the *punctum bregmatis*, the angle being formed by two lines drawn from those points respectively and meeting at the point indicated.

Eutropion. Inversion; also trichiasis.

Eutropion partiale. (L.) An inversion of the ciliary margin of the eyelid, so that the edge of the lid as well as the cilia rubs against the eyeball. A partial trichiasis.

Eutropion totale. (L.) Inversion of the entire length of the ciliary margin of the lid from internal to external canthus.

Euvaseline. This is the ordinary American vaseline of commerce to which ceresin (hard paraffin) has been added. It is supposed that in its application to the eye one obtains the double action of the vaseline as an aseptic application and a protective action from the admixture with ceresin.

Evaporating lotions. These are generally eye waters or lotions containing alcohol or other substances capable of rapid evaporation. They produce cooling of the ocular region and are frequently employed in ophthalmic therapy. In addition, a number of remedies bring about an effect somewhat similar to these and are used for like purposes. Aqueous solutions of alcohol, mixtures containing medicated waters, iced water with tinctures or essences and those agents that are commonly employed with compresses make soothing applications to irritated eyes.

Eventail astigmatique. (F.) Astigmatic fan.

Eventail de tests. (F.) Test fan.

Eversbusch, Oscar. A well known Munich and Erlangen ophthal-



Oscar Eversbusch.

mologist. Born at Haspe, Westphalia, May 26, 1853, he studied at Bonn and Munich, at the latter institution receiving his degree in 1877. In 1882 he became privat docent in ophthalmology at Munich, and at the Veterinary High School in the same city, in which capacity he served till 1886. From that date till his death in 1912 he was full professor of ophthalmology at Erlangen.

Among his more important writings were the following: 1. Beiträge zur Genese der Serösen Iris cysten. 2. Beiträge zur Embryologie und Teratologie des Glaskörpers. 3. Bemerkungen über die Anwendung der Antiseptica. 4. Über einige Veränderungen der Plica Semilunaris. (Munich, 1883.) 5. Die Neue Univ.-Heilanstalt für Augenkranhe in Erlangen. (1893.) 6. Ophthalmolog. Beiträge. (In Handbuch der Therapie von Penzoldt und Stintzing, I and II ed., 1896 till 1898.) 7. Augenerkrankungen im Kindesalter. (1912.)

Eversbusch was also one of the collaborators on the Graefe-Saemisch *Handbuch*, 2d ed., which began to appear in 1899.—(T. H. S.)

Eversion forceps. The principles involved in the construction of most

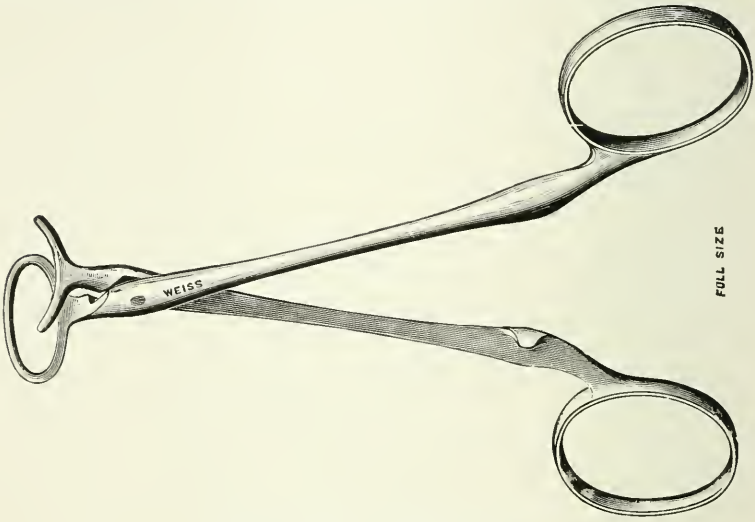

Treacher Collins' Eversion Forceps.

instruments for everting the lids is much the same. A fair example of them is seen in that invented by Treacher Collins, pictured in the text.

Evidement. (F.) The removal of a substance (bone, tissue) from a natural or pathological cavity. Exenteration.

Evil eye, The. To the superstitious the terror of the art, supposed to be possessed by witches and others, of injuring or even killing with a glance, is still widely believed. Charms and amulets are still worn to protect the innocent from those possessing the power to "fascinate" them. Among the Romans it was customary when praising anything to add *Praefiscini dixerim* (Fain Evil! I should say). This custom survives in modern Italy, where, under similar circumstances, it is still said *Si mal occhio non ci fosse* (May the evil eye not strike it).

The evil eye was probably originated in envy and it is in this way

that it began to be regarded as unlucky to have one's possessions praised.

According to the *Encyclopedia Britannica* all sorts of powers have been attributed to the possessor of the evil eye. For example, a "fascinator" is believed to have killed in an African town no less than eighty people in two years! Even as late as the 18th century it was believed in the Scottish highlands that if a stranger admired a cow the peasants thought she would waste away, and they offered the visitor some of her milk to drink in the belief that in this manner the spell would be broken. The modern Turks and Arabs also think that their horses and camels are subject to the evil eye. But the people of Italy, especially the Neapolitans, are the best modern instances of belief in this superstition. The *jettatore*, as the owner of the evil eye is called, is so feared that at his approach it is scarcely an exaggeration to say that a street will clear: everybody rushes into doorways or up alleys, to avoid the dreaded glance. The *jettatore di bambini* (fascinator of children) is the most dreaded of all. The evil eye is still much feared for horses also in India, China, Turkey, Greece; indeed, almost everywhere where horses are found. In rural England the pig is of all animals most frequently "overlooked." While the Italians are perhaps the greatest believers in the evil eye as affecting persons, the superstition is rife in the East. In India the belief is universal. In Bombay the blast of the evil eye is supposed to be a form of spirit-possession. In western India all witches and wizards are said to be evil-eyed. Modern Egyptian mothers thus account for the sickly appearance of their babies. In Turkey passages from the Koran are painted on the outside of houses to save the inmates, and texts as amulets are worn upon the person, or hung upon camels and horses by Arabs, Abyssinians and other peoples. The superstition is universal among savage races.

The work on this subject by Roswell Park is well known in this country, and among the numerous English works on the evil eye that of Elsworthy, London, 1895, is well worth consulting.

Evisceration of the eyeball. An operation which consists in first excising the anterior portion of the eyeball and then completely evacuating its contents, leaving nothing behind but the sclerotic. For a complete account of this operation and its relations to other procedures, see **Enucleation of the eye and its substitutes.**

Evisceration of the orbit. See **Exenteration of the orbit**; also **Enucleation.**

Eviscero-neurotomy. This operation, which originated with Ernest Hall, of Victoria, B. C., consists of an evisceration to which is added an excision of the posterior part of the scleral cup and resection of

the optic nerve. For a detailed description of this procedure, see **Enucleation of the eye and its substitutes.**

Evolution of color-vision. The sources of information on the evolution of color-vision are few, and the methods of investigation difficult. Not until quite recently have researches in this direction been carried out in a scientific manner and yielded valuable results. As pointed out by Parsons (*An Introduction to the Study of Color Vision,* page 130): Positive evidence is derived from three chief sources. In the first place we naturally appeal to the visual sensations of lower animals. These are extremely difficult to investigate since we are almost wholly dependent upon observation of motor responses which the animals make to light-stimuli, though some deductions may be made from the structure of the visual organs. In the invertebrata little can be done beyond recording the phototropism of the animal, i. e., its attraction or repulsion by lights of different wave-length and intensity, as exhibited by its movements towards (positive phototropism) or away from (negative phototropism) the light. As we ascend the animal scale the increase in complexity of the nervous system and of the visual organs is accompanied by a corresponding increase in the complexity of the motor responses, associated with a greater difficulty in their interpretation. On the other hand as we descend the animal scale from man there is an unwarranted tendency to interpret the apparently purposeful responses of the animal in an anthropomorphic manner, which is not necessarily justified on neurological and psychological grounds. For example, we have little knowledge of the psychology of the lower mammal with its less highly developed nervous system. The temptation to interpret such an animal's actions in terms appropriate only to the human mind has proved very great and has undoubtedly given rise to error in the past. Our deductions must of necessity be anthropomorphic, since such terms as visual sensation, attraction, pleasure, pain and so on, have no meaning for us except in so far as these processes form a part of the contents of our own minds. Yet it should be a guarded anthropomorphism, neither exaggerating the psychological elements nor flying to the impossible antithesis of imagining that the anthropomorphism can be eliminated by a new terminology.

In the second place a study of the color-vision of primitive races may throw some light on the evolution of visual sensations. It may be that some primitive races are in a condition of arrested development—of vision as of other faculties. We have only just crossed the threshold of this part of the investigation and it is to be hoped that no time will be lost in carrying it forward, lest the material for the research be obliterated by the march of civilization.

The third source of information is the development of visual sensations in the infant. It is generally admitted that "ontogeny is a compressed phylogeny"—that each individual passes rapidly through the same stages of development which have marked the upgrowth of the race. Here again little progress has been made and the investigation is arduous and full of pitfalls.

Beside these main sources there are others of less security. We are familiar with congenital defects of vision and it may be that some of them are atavistic, that development has become arrested at a stage which corresponds with an earlier stage in the development of the race. Some arguments, too, may be derived from the careful study of normal color-vision, but the evidence derived from both these sources is too uncertain to be of much value. (C. P. S.)

Evolution of the human eye. The origin of the human ocular apparatus from that of lower forms of animal life has been discussed by various scientific investigators. Arguments that strongly appeal to the Editor are to be found in W. H. Gaskell's "*Origin of Vertebrates*" and point to the derivation of all vertebrate eyes from Palæostracan (that is from higher invertebrate) stock of trilobite and scorpion forms. Gaskell summarizes his chapter on the Evidence of the Organs of Vision, as follows: "The most important discovery of recent years which gives a direct clue to the ancestry of the vertebrates is undoubtedly the discovery that the pineal gland is all that remains of a pair of median eyes which must have been functional in the immediate ancestor of the vertebrate, seeing how perfect one of them still is in Ammocoetes. The vertebrate ancestor, then, possessed two pairs of eyes, one pair situated laterally, the other median. In striking confirmation of the origin of the vertebrate from Palæostracans it is universally admitted that all the Eurypterids and such-like forms resembled Limulus in the possession of a pair of median eyes, as well as of a pair of lateral eyes. Moreover, the ancient mailed fishes, the Ostracodermata, which are the earliest fishes known, are all said to show the presence of a pair of median eyes as well as of a pair of lateral eyes. This evidence directly suggests that the structure of both the median and lateral vertebrate eyes ought to be very similar to that of the median and lateral arthropod eyes. Such is, indeed, found to be the case. The retina of the simplest form of eye is formed from a group of the superficial epidermal cells, and the rods or rhabdites are formed from the cuticular covering of these cells; the optic nerve passes from these cells to the deeper-lying brain. This kind of retina may be called a simple retina, and characterizes the eyes, both median and lateral, of the scorpion group. In other cases a portion of the optic ganglion remains at the surface, when the brain sinks inwards, in close contiguity to the epidermal sense-cells

which form the retina; a tract of fibres connects this optic ganglion with the underlying brain, and is known as the optic nerve. Such a retina may be called a compound retina and characterizes the lateral eyes of both crustaceans and vertebrates. Also, owing to the method of formation of the retina by invagination, the cuticular surface of the retinal sense-cells, from which the rods are formed, may be directed towards the source of light or away from it. In the first case the retina may be called upright, in the second inverted. Such inverted retinas are found in the vertebrate lateral eyes and in the lateral eyes of the arachnids, but not of the crustaceans. The evidence shows that all the invertebrate median eyes possess a simple upright retina, and in structure are remarkably like the right median or pineal eye of Ammocoetes; while the lateral eyes possess, as in the crustaceans, an upright compound retina, or, as in many of the arachnids, a simple inverted retina. The lateral eyes of the vertebrates alone possess a compound inverted retina. This retina, however, is extraordinarily similar in its structure to the compound crustacean retina, and these similarities are more accentuated in the retina of the lateral eye of Petromyzon than that of the higher vertebrates. The evidence afforded by the lateral eye of the vertebrate points unmistakably to the conclusion that the ancestor of the vertebrate possessed both crustacean and arachnid characters—belonged, therefore, to a group of animals which gave rise to both the crustacean and arachnid groups. This is precisely the position of the Palæostracan group, which is regarded as the ancestor of both the crustaceans and arachnids. In two respects the retina of the lateral eyes of vertebrates differs from that of all arthropods, for it possesses a special supporting structure, the Müllerian fibres, which do not exist in the latter, and it is developed in connection with a tube, the optic diverticulum, which is connected on each side with the main tube of the central nervous system. These two differences are in reality one and the same, for the Müllerian fibres are the altered lining cells of the optic diverticulum, and this tube has the same significance as the rest of the tube of the nervous system; it is something which has nothing to do with the nervous portion of the retina but has become closely amalgamated with it. The explanation is, word for word, the same as for the tubular nervous system, and shows that the ancestor of the vertebrate possessed two anterior diverticula of its alimentary canal which were in close relationship to the optic ganglion and nerve of the lateral eye on each side. It is again a striking coincidence to find that Artemia, which with Branchipus represents a group of living crustaceans most nearly allied to the trilobites, does possess two anterior diverticula of the gut which are in extraordinarily close relationship with the optic ganglia of the retina of the lateral eyes on each side. The evidence of the optic apparatus of the

vertebrate points most remarkably to the derivation of the Vertebrata from the Palæostraca."

Evolution theory of color-sensation. LADD-FRANKLIN COLOR THEORY. In respect to most of the characters found in the human animal, one has only the lower animals in which to study the course of their gradual development, but in considering the color-sense one has the unique advantage of being able to perceive its successive stages spread out upon one's own retina. It has been found that anatomically the structure of the retina is of a high form of development in the center, and that it gradually becomes less highly developed towards the periphery; of the retinal visual elements, the cones alone (which have been shown by Ramon y Cajal to be more highly developed rods) are found in the fovea, and they occur more and more sparingly farther out until there are practically none in the extreme periphery. Corresponding with this fact of structure is the fact of sensation that we got full tetrachromatic color-vision only in the central portion of the retina, and nothing but achromatic vision (that in which all objective light, of whatever light-ray constitution, looks white in quality) in the extreme periphery. This fact, together with the circumstance that the retina of night birds-of-prey (who have no occasion for color-vision) is very deficient in cones, led Max Schultze to form the hypothesis that chromatic vision is mediated by the cones only, and that the rods furnish nothing but achromatic vision. This view was further strengthened when it was advocated independently by Parinaud, upon reasons based on the facts of hemeralopia, a disease which consists in the non-functioning of the mechanism for darkness adaptation. The disjunction of function of the rods and cones—the specific rod-cone function (Ladd-Franklin) or what has more recently been called by v. Kries the duplicity theory was rendered indubitable by certain discoveries made in König's laboratory in Berlin in 1892. They are: (1) The exact coincidence of the distribution through the spectrum of the subjective intensity of night-vision in the normal individual (which coincides with that of night and day vision in the achromatic defectives) with the objective spectral absorption of light by the visual purple. The latter process appears only—or at least in vastly greater quantity—after adaptation has taken place (König). (2) The following two closely connected facts (Ladd-Franklin, *Sitzber. Akad. Wiss. Berlin* 21. June 21, 1892, p. 362); first, the normal night-blindness of the fovea, viz., the fact that that form of substitute vision which the normal individual acquires after twenty minutes in a dark room—night-vision, as it may be called, or scotopia—he does not acquire in the fovea; and, second, the complete blindness in the fovea

of those individuals who have the typical (non-cortical) form of total chroma-blindness (achromatopia).

Parenthetically, it may here be said that in the opinion of the writer the ambignous word *color* should be used to include the color grey (white), and that for color proper one should say *specific color* (Hess), *toned color* (Hering), or *chroma* (Ladd-Franklin). See, also, **Color terminology.** It would be, for example, absurd to suppose that when we are discussing a *color*-theory we are discussing a theory which accounts for the chromatic sensations only and not for the achromatic ones as well.

A remarkably good evaluation of these (then newly-discovered) facts of color-vision is given by Burdon-Sanderson (*Nature*, Sept. 14, 1893, p. 469).

In the mid-periphery, vision is dichromatic; the colors seen are blue and yellow, the color sensations lacking are red and green. The limits of these color-fields are not at all definite, because much depends upon the size and brightness of the colored objects used for testing. The colors prepared by Hegg, or Berne, in which a bluish-green and a bluish-red (the zonally stable color-tones) are made, by reduction of their chromaticity, such that they vanish together, should always be used by ophthalmologists and in psychological laboratories for investigations of this subject. In this mid-periphery of the retina no structural difference can be made out; the atavism of the color-sense which is here exhibited is evidently due to a non-development in the light-sensitive chemical substances in the cones.

In human vision we have, besides the normal color defects of the non-central retina, many cases (congenital and acquired) of partial color-blindness; these, in their typical forms, consist in seeing the whole spectrum as yellow in the long-wave end and blue in the short-wave end, with an intermediate point at which vision is achromatic. This "neutral" point is not at the place where the normal individual gets the pure green color (the unitary green), but at a place which to him is blue-green. Those who have this yellow and blue vision only are of two distinct types, protamopic and deuteranopic) according as the distribution along the spectrum of their undifferentiated yellow-vision coincides with the normal distribution of the green constituent or of the red constituent (that is, according as the first or the second of the red and the green distributions is lacking). The blue-vision of all these cases coincides with that of normal vision.

Partial color-blindness is comparatively rare in women.

Total defect in the chromatic sensations occurs much less frequently; the distribution along the spectrum of the achromatic sensation (which is all that is left in such cases) is sometimes the same as the intensity

distribution of normal (tetrachromatic) vision, but more frequently it coincides with that of normal scotopia; the maximum is in the yellow-green. The former cases are doubtless instances of cerebral defect (the fovea is not blind in these cases); the latter are congenital, typical, and accompanied by total foveal blindness. The defect is plainly a non-development of light-sensitive substances in the retina, the cones being doubtless wholly out of function.

This remarkably congruent mass of evidence in regard to the development of the chromatic sensations which is here briefly summarized, evidently demands a color-theory which takes it into account, and which explains at the same time, by one and the same conception, the facts of complementation. See the diagrams. The development color-theory has this for its object, and also the avoidance of the inconsistencies of the theories of Hering and of Helmholtz. It assumes that there occurred, first, a light-sensitive chemical substance in the (low-grade) rods which responded non-specifically to light of any sort within the visible spectrum. The simple cleavage-product of this stage of development forms the nerve-excitant which is correlated with the sensation of white (grey). This is the only sensation possible when the rods alone function, i. e., in the cases of (a) normal achromatic vision in the extreme periphery, and of achromatic vision in (b) the normal eye in a state of darkness adaptation and with low objective intensities, and in (c) the totally chroma-blind defectives. Development of the color-sense takes place in the form of the acquiring of greater specificity in that part of the color-molecule which undergoes cleavage. Instead of responding alike to all parts of the visible spectrum, part of it, *Sy*, is synchronous in its electronic vibrations with the longer waves, and part of it, *Sb*, with the shorter waves; but whenever *both* of these nerve-excitant substances are torn off at the same time, they unite chemically to constitute the former whiteness-excitation. This is the stage of development of the normal mid-periphery, and of the two types of yellow-blue vision. In Stage III the complete differentiation of the light-sensitive molecule in the way of greater specificity has taken place, and red and green are added as specific sensations. But the nerve-excitant substances, Eg and Er, when they are both dissociated out together, re-constitute the yellow nerve-excitant, Ey. Again it is plain that yellow and blue nerve-excitants re-unite to constitute the original nerve-excitant, Ew, whose sensation effect, when the cortex is reached, is white in quality.

Contrast and after-images are alike readily explained, on this theory, as a residual phenomenon, due to the completed dissociation of a molecule which in its partially dissociated condition is, like other such substances (Cannon), unstable.

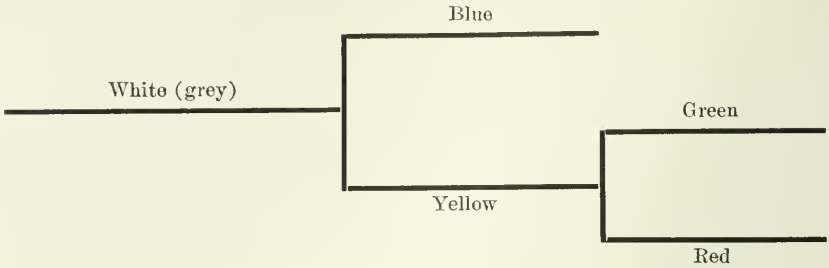

Development of the Color-Sense.

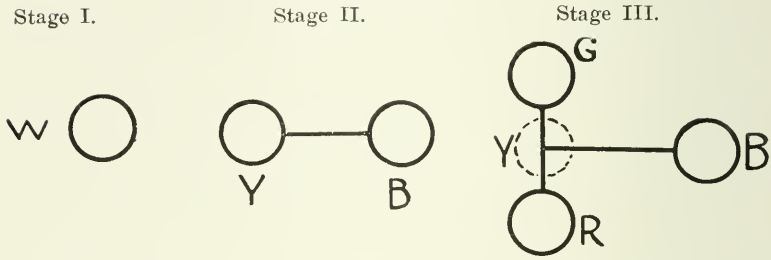

A different (simpler) representation of the development color-theory. Both, of course, are purely diagrammatic, and intended for mnemonic purposes only.

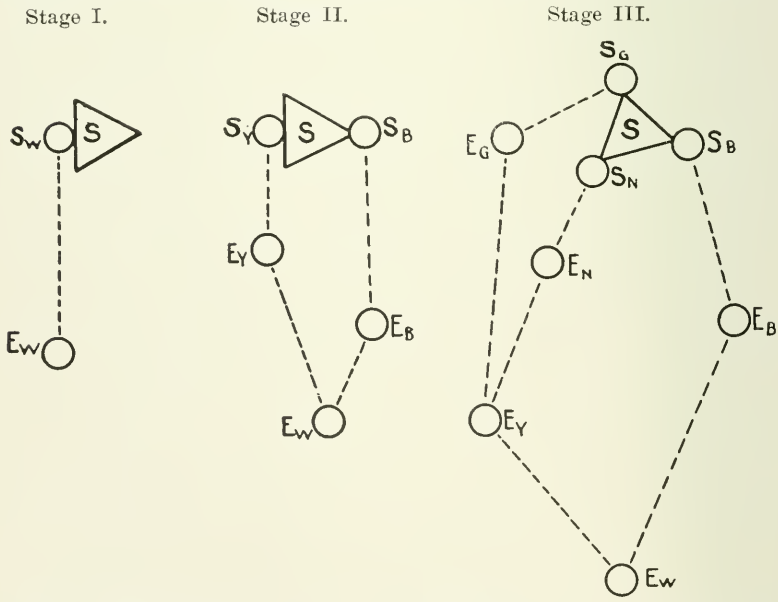

The Development Theory of Color (Ladd-Franklin). S*n*, the color-sensation receptors (resonators, side-chains, light-sensitive electrons, or whatever the current photo-chemical theory may demand), in three successive stages of development. E*n*, the several specific nerve-excitant substances for the five specific light-sensations.

This theory has been adopted in part by Schenck (Pflüger's *Archiv.*, 1907), but he leaves out an important feature of it—the explanation of chroma-extinction in the case of the formation of a plain yellow out of red and green, and also of white out of yellow and blue. Schenck is apparently not aware of the psychological fact that yellow and white, being distinctive unitary sensations (see **Colors, Unitary,** this *Encyclopedia*) and not, like the blue-greens, etc., color blends, are in need of being accounted for. This theory is now frequently referred to, but incorrectly, as the Schenck-Franklin theory (Greenwood, Köllner). Schenck adds many hypotheses for explaining the details of color-blindness, but they are not pertinent to this discussion. (Christine Ladd-Franklin.)

Evulsion of the optic nerve. Forcible tearing out, or "gouging," the eye from its socket may be accidental or deliberate. In the latter instance it may be a form of the automutilation described on page 711, Vol. I, of this *Encyclopedia.* To the remarks made there may be added that Stoewer (*Klin. Monatsbl. f. Augenh.*, April, 1910, p. 426) observed two cases of evulsion of the optic nerve from penetration of a thin stick into the orbit. The diagnosis in one case was confirmed by enucleation. The other was recognized by the ophthalmoscopic appearances only. He observes that while the most certain clinical diagnostic mark is the discovery of a hole at the site of the papilla, this typical appearance may be concealed by a hemorrhage, which latter may become replaced by cicatricial tissue. A second essential symptom is interruption of the retinal circulation, but this is only marked for a short time after the injury, when it may not be recognizable because of vitreous opacities. A third sign is complete blindness with absence of the direct pupillary reflex.

In Birkhäuser's (*Klin. Monatsbl. f. Augenh.*, April, 1910, p. 432) case the orbit was penetrated by a cow's horn; the interest of this rare case was heightened by the fact that the fundus could be clearly observed continuously from the day of the accident. The ophthalmoscope showed a small oval nerve-head with the long axis horizontal; the inferior margin was embraced by a very dark semilune which took the place of the missing portion of the nerve. The marked parallax between the edge and the center left no doubt but that the nerve head had been torn loose in the lower quadrant of the sclerotic canal. The retinal vessels were manifestly lacerated in this situation as they could not be followed to the periphery of the papilla. The vision was reduced to counting fingers at a meter. The upper half of the visual field was entirely blind. Six weeks after the injury the dark semilune had become replaced by grayish-white, new-formed tissue, and no parallactic movement could be detected. Dalen (*Ophthalmoscope,* Vol. 8, p. 519,

1910) reports a case of evulsio nervi optici, by which term he understands tearing of the optic nerve from its scleral canal with preservation of the ocular tunics. A dark-gray excavation was visible in the usual position of the optic disk. The eye was enucleated two and one-half years later for glaucoma; microscopically the fibers of the nerve were seen to be torn through, with displacement backward in the uninjured dural sheath. The cause of the injury was a blow from a stick, which probably occasioned extreme compression of the globe; the lamina cribrosa being the spot of least resistance gave way with the above result. Mary Buchanan (*Tr. Sec. Ophth., Col. Phys.*, Philadelphia, Nov. 18, 1910) observed a case in which an insane woman gouged out one of her own eyes. The muscles and optic nerve had been neatly severed close to the eyeball. No infection followed. In Pichler's (*Klin. Monatsbl. f. Augenh.*, Aug., 1910, p. 246) case of an eye blinded thirty-five years before by the kick of a horse, the appearances indicated partial evulsion of the optic nerve.

A remarkable case of optic evulsion is described by Natanson (*Klin. Monatsbl. f. Augenheilk.*, August, 1912). A boy, aged 18, in falling, thrust the point of his cane into his left eye. The pain was very severe. The lids were very much swollen. After a few days he noticed that he could not see with that eye. He came to Natanson two weeks later, who found subcutaneous and subconjunctival ecchymoses, a recent scar at the inferior medial angle of the ocular conjunctiva, pupil maximally dilated and immovable, and the refracting media clear. Skiascopy showed myopic astigmatism; normal motility; no exophthalmus nor enophthalmus. At the place of the optic disk was a hole. This was recognized by the difference of refraction of 9 D.—a depth of 3 mm. The bottom of the hole, in which the vessels were lacking, was partly black, partly grayish-red, showing no details; its margin, apparently the scleral ring, was white, forming a characteristic myopic conus on the temporal side. It occasionally threw a shadow upon the bottom of the hole which varied in width with the inclination of the rays. Next to the hole there was an oval, yellowish-white area, without retinal vessels (which stopped at its margin) and most probably devoid of retina. Its periphery was covered by hemorrhages. The center of the fundus was milky-opaque. All these symptoms indicated a separation of the optic nerve at the lamina cribrosa. The writer thinks that the point of the cane penetrated the orbit, and, by stretching the optic nerve backwards and pushing the globe forward, tore or pushed the optic nerve through the scleral opening.

Ewetzky, Th. von. A well-known Russian ophthalmologist. Born in 1851 of a noble family, he entered in 1870 the Medico-Surgical Academy at Petrograd. His medical degree, however, was received at Heidel-

berg, Germany. In 1892 he became assistant at the eye clinic in the University of Moscow. In 1893 he was appointed privatdocent for ophthalmology at this institution, in 1895 professor extraordinary, and five years later was called to the full professorship of his specialty at the University of Dorpat. In September, 1908, he was stricken with apoplexy, and never spoke again. He made, however, a partial recovery, but, failing very rapidly, was found on the 20th of April, seated in his armchair, dead.—(T. H. S.)

Exæresis. (L.) (Obs.) One of the general divisions of surgery, according to the ancients, including all operations by which parts of the body were removed; such as amputation, excision, ablation, etc.

Exaggeration, Ocular. The pretense that a certain injury or disease which does actually exist (whether the cause assigned be true or false) is of greater extent or severity than is really the case. See **Legal relations of ophthalmology,** in the middle third of the article.

Examen. (F.) Examination.

Examination of the eye. The keynote to the proper and efficient examination of the eye is expressed in the one word "method." In order to become a keen-eyed diagnostician the ophthalmic surgeon must adopt certain routine steps and carry them out in every case. While many times he will seem to be wasting time on unnecessary details, still if he absolutely continues in their use he finds after a surprisingly short time that many of the acts become almost mechanical and are done practically without thinking. Nearly every mistake in diagnosis we see made by a really competent surgeon, is found to usually have been due to a lapse from his established method of examination; one link in the chain of procedure being omitted and this link the really important one of the whole chain. Of course, there occur conditions where the diagnosis is so entirely obvious that a painstaking examination of every part of the eye would be a mere waste of time; however, it is best to run over the whole ground, as far as possible, in the great majority of cases.

Not only should a regular routine method of observing conditions be carried out, but in addition the oculist should train himself to note down in his case-book, or on his history card, these conditions as he sees them or hears them described. Observance of this rule will not only save much time, if the patient should return, but will furnish data of value to the profession, and also may at some time protect the surgeon from a suit for alleged malpractice. These records should be very carefully filed and catalogued so that any one may be quickly consulted. The card system now so popular in all lines of business has supplanted the old, bulky, case-book, being much more efficacious and less laborious. The cards should be printed with labeled spaces

for writing in the findings. The following outline will be found very complete:

Name .....Residence .....Age.....
Occupation .....Race .....Married, Single, or Widowed.....

Family history: (Including hereditary tendencies; general and ocular health of parents, brothers and sisters.)

Personal history: (Including children, their general and ocular health; miscarriages; menopause; former illnesses; syphilis; gonorrhea; injuries.)

Personal habits: (Including alcohol, tobacco, drugs and sexual relations.) Date and mode of onset and supposed cause of present trouble. (Including complete history of eye troubles.)

General examination of patient: (Including blood, urine, nose, Wassermann, teeth, etc.)
External examination of both eyes:.....
Examination of right eye:.....
Examination of left eye:.....
Vision, right eye:.....
Manifest refraction of right eye:.....
Vision, left eye:.....
Manifest refraction of left eye:.....
Ophthalmometer: Right .....Left .....

Muscle balance: (Including findings by red glass test, Maddox rod, tangent, phorometer, etc.)
Tension: Right .....Left .....
Pupillary reaction: Right.....Left.....
Ophthalmoscopic examination: Right.....Left.....
Fields of vision: Right.....Left.....
Color sense: Right.....Left.....
Retinoscopy: Right .....Left .....
Refraction under cycloplegic: Right.....Left.....
Diagnosis:..... Prognosis:.....
Treatment:.....
Glasses ordered: Right.....Left.....

In addition to a complete written account of the case, drawings, no matter how crude, should be made illustrating the different findings. To facilitate the making of these drawings, outline pictures may be printed on the history cards and filled in by the surgeon. A set of rubber stamps are now made (see cuts) which print these several outlines, which are very desirable and practical.

The examination proper is divided into two groups, viz.—subjective

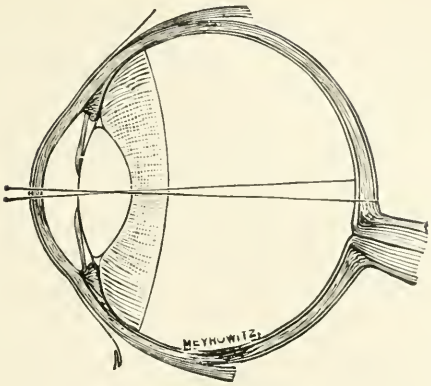

Rubber Stamp for Recording Findings in the Interior of the Eye Ball.

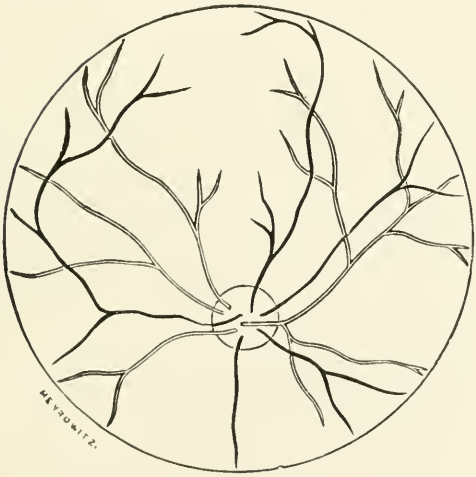

Rubber Stamp for Recording Findings in the Fundus.

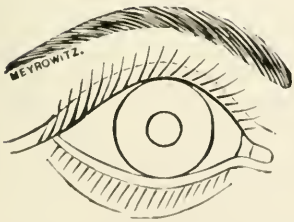

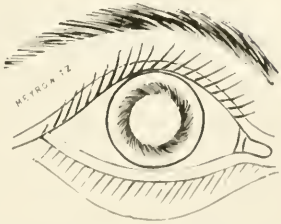

Rubber Stamps for Recording Findings in the External Examination of the Eye.

and objective. The subjective division includes the history of the case and all those procedures which require the patient's cooperation and aid. The objective examination includes all those manipulations which are carried on by the observer and give to him information without answers or aid of any kind from the patient. The most important part of the subjective examination is *the history of the case,* and it is at the same time one of the most difficult, in many instances, to successfully obtain. It consists essentially of a story of the patient's ailment, told in his own way, the examiner only guiding and asking such questions as will keep the story to the front and the facts in their proper sequence. The ability on the part of the questioner to do this accurately and expeditiously, making the patient bring out every point clearly, is an accomplishment he may well be proud of.

The workings of the otherwise clear brain of an intelligent individual undergoing his first examination by a physician is often a strange phenomenon. His insistence on talking completely around a given point, combined with his inability to answer yes or no to a clear-cut question, is often very exasperating. So we find that to obtain a successful history we must exercise much patience, care, and fortitude.

The following outline of questions has been found to be of great service in preparing a history, and if adhered to in all cases will serve as a great time-saver, as well as giving a uniform result:

1. Early in life—when you were first going to school or earlier—did you ever have any trouble whatever with your eyes? If so, in what way did they bother you?

2. When was the next time, or times, that you had any difficulty with, or defect in, your eyes?

3. Have you been in the habit of holding your book or newspaper nearer your eyes than people generally do?

4. During the past six months or so have your eyes bothered you in any way? Have you noticed any blurring of print or mixing of letters when reading?

5. What is your age and occupation?

6. How long can you read a newspaper without noticing *any* difficulty with your eyes? If difficulty, what is it?

7. Have you any headaches? If so, in what part of the head? How often do they come on? Do you have these headaches only in the daytime, or do they sometimes keep you awake at night? Do they affect both sides of the head at one time or are they generally one-sided? Are they made worse by the use of the eyes for reading, writing or any near work?

8. Do you suffer from nausea or dizziness?

9. In riding on a street car or railway train and looking out the

window at passing objects, are you affected in any way? If so, how?

10. In going to church, theatre, concert—anywhere when you have to see distinctly in the distance for any length of time—does it affect your eyes in any way?

11. Do you ever see objects double, either for distance or near?

12. Do your eyelids smart or burn? Is there a feeling of dust in the eyes? Has anybody noticed that your eyes get blood shot or red? Do the eyelids stick together in the morning? Is there any discharge from the eyes when you first wake up?

13. Are your eyes sensitive to light; that is, does gas, electric or sunlight hurt them more than they generally affect other people? Have you ever pain in the eyes, or do they become tired easily, or do they ache? Have you ever worn, or do you now wear, glasses? Let me see the glasses you are now wearing. (Make a note in the place set aside for them the formulæ of glass or glasses worn by the patient.)

14. Have you noticed anything further wrong with your eyes?

15. What is the *principal thing* that bothers your eyes now?

16. What is the state of your general health? Do you sleep well at night-time? How is your appetite and does your food generally digest well? How much do you smoke and drink?

Primarily we should direct attention to *the general condition of the patient,* for we must remember that the eye is not a separate and distinct organ with no relation to the rest of the body. It is only one of the many complex organs which, while possessing their own distinctive functions, must all act in harmony to result in the perfect well-being of the individual.

A rapid general inspection will therefore often furnish one with a clue to an ocular affliction, the cause or origin of which might have otherwise escaped notice.

The contour of the cranium, for example, is often found to bear a direct relation to the conformation of the eye, and as the form of the eye largely influences its state of refraction, we may, by this observation, quickly deduct certain things. A flat or "dish" face is nearly always an indication of hyperopia, particularly if the flatness affects the region of the zygomatic arches. Myopia is often indicated by an elongated antero-posterior diameter of the skull, associated with a thin face and bulging eyes.

Anisometropia, a condition in which one eye is myopic and the other hyperopic, is nearly always accompanied by a lack of symmetry in the face.

Asymmetry of the cranium forms a direct relationship to astigmatism and is observed in nearly all marked cases.

The shape of the nose is important, for a sinking of the root of that

member, whether congenital or due to injury or syphilis, is a great predisposing factor in the causation of catarrh of the lachrymal passages.

Eruptions on the skin should always be observed and are of great significance. Eczema, pityriasis, herpes zoster and other skin diseases may affect the lids as well as other parts of the body. Syphilitic eruptions, if observed at the same time we diagnose a case of iritis, satisfies us immediately that the disease is a specific one and we begin appropriate general treatment. The hue of the skin may give important hints as to the condition of the blood.

John Dunn (*Archives of Ophthal.* 37, p. 687) has shown the importance of the *sphygmomanometer in the examination of ocular disease.* He cites five cases of glaucoma in which the value of the pulse tension as a therapeutic indication is shown, and adds that in every case of essential glaucoma, except hereditary ones occurring in early youth, the pulse tension is above normal, and in the severer cases, both acute and chronic, much above normal. He finds that in simple chronic glaucoma the chances of preserving the vision by an iridectomy vary with the pulse tension; the nearer normal the tension, the better the prognosis with iridectomy. He also finds that the higher the pulse tension the more likely, as a rule, is the use of mydriatics to be followed by glaucomatous symptoms, and that the pulse tension may decide for or against the use of a mydriatic.

In the treatment of corneal ulcers a record of the pulse tension, by pointing out the existence of other abnormal conditions than those in the cornea, may suggest an underlying cause and thus influence treatment. In immature cataract he gives serious consideration to the pulse tension, before operating, stating that, as a rule, the higher the blood pressure the greater the chances; that there exist within the intra-ocular vascular system of old people degenerative changes which may interfere with the absorption of particles of lenticular cortex left behind.

In iritis with high blood pressure pain is relieved by local bleeding; with low blood pressure bleeding does not give such relief.

Dunn finally refers to the value of blood pressure in intercepting lesions of the retina and optic nerve and to its practical value in certain cases of eyeache and headache.

It is now being more generally realized that *certain eye diseases are caused by toxemia* from the alimentary tract and from the genito-urinary system, as well as from the suppurative conditions in other parts of the body, and S. H. Browning (*Ophthalmic Review*, 1913) enters a plea for the more general routine examination of the feces

and urine; at least in those eye conditions in which the cause is not immediately obvious.

He points out that pyorrhea alveolaris, or Rigg's disease, has at last been given the attention that it needs, but even the cure of the pyorrhea does not clear up the general infection of the alimentary tract that results from many years of pus swallowing, and patients with comparatively clean mouths come to be treated for chronic irido-cyclitis with no obvious cause, though an examination of the feces would have revealed the fact that they were abnormal and that the patient was suffering from a streptococcal, pneumococcal or other bacterial infection of the bowel.

Apart from infection from swallowed pus, the patient may have a colitis causing irido-cyclitis, both of which can be cured by vaccine and other treatment. There are, however, more cases from whom no history of colitis can be obtained though the patient is probably constipated and it is in these patients that one is likely to miss the real cause of the disease. Browning now examines the feces and urine of all patients sent to him who are suffering from chronic irido-cyclitis of obscure origin, as well as other forms of inflammatory eye conditions.

He has given the routine of the examination of the feces. If it is decided that the patient is suffering from an infection, a vaccine is prepared and used and general intestinal toilet looked after. In some of these cases the result of giving vaccine treatment has been striking, while in others it has been disappointing, but the results are sufficiently good to make it advisable to examine the feces in all difficult cases. A thorough examination of the urine is made at the same time the routine chemical tests are made, and then one loopful of the fresh urine is planted on to agar and human blood agar. A portion of the urine is then centrifuged and some of the deposit plated out and some is examined in the fresh state under the microscope. It is naturally much easier to detect the presence of bacterial infection in the urine than in the feces, and the results of the treatment by autogenous vaccines have been successful in several cases.

Of course, it does not follow that because the patient has a colitis or cystitis that the eye condition is being caused by either of these conditions, though in the author's experience it is of sufficiently frequent occurrence to justify the trouble expended in examining the feces and urine; and anyhow the patient must be benefited by removing a pathogenic condition. At present irido-cyclitis seems to be the most common eye disease caused by infection of the alimentary tract, though keratitis, retinitis and retino-choroiditis have been met with. The proof that the eye condition is caused by the intestinal or urinary infection is the cure of the eye disease at the same time as the more

general condition. This can be most readily brought about by the use of a suitable autogenous vaccine.

Vaccine treatment is of great help in alleviating the immediate acute symptoms of gonorrheal iritis, but of itself it will rarely effect a permanent cure. The prostate is often infected with gonococci in these cases and the urine passed after prostatic massage will often show the gonococcus in the threads, though attempts at cultivation very often fail. An examination of the prostate ought to accompany all efforts in the treatment of obstinate recurring gonorrheal iritis.

The *practical value of the Wassermann reaction* has been presented by M. Mouradian (*Annales d'Oculistique*, Vol. CXLVII, Jan., 1912), in which he briefly reviews the work of many observers and presents a useful table of conditions in which positive reactions have been obtained. This table includes the cases from several authors, and if one adds to these figures the cases where details are not given one gets a total of 1,345 examinations, with 574 positive reactions, i.e., 42.6 per cent. These results have been obtained by the method of Wassermann properly so-called.

	No.	Positive.	Percentage.
Iritis	238	64	26.8
Parenchymatous keratitis	311	269	86.4
Choroiditis	129	24	18.6
Optic atrophy	25	10	40.0
Optic neuritis	95	18	18.9
Ocular paralyses	86	33	38.3
Scleritis	12	4	33.3
Tabes	32	24	75.0
Hemianopsia	10	6	60.0
Retinitis	9	2	10.5
Retinitis pigmentosa	5	5	100
	969	459	47.3

He then gives the results of the examination of 245 cases of his own from the Eye Clinic at the Lariboisière Hospital, Paris. These examinations were done at the Pasteur Institute under Levaditi and Lotapie, and to ensure greater accuracy the observers were not informed of the clinical points in the cases. Wassermann's original technique was used, but Noguchi's and Hecht's modifications have yielded in other hands similar results except that Hecht's method gives a greater percentage of positive reactions.

Sixty-four cases of iritis and iridocyclitis gave twenty-five positive and thirty-nine negative reactions, i.e., 39 per cent. positive. Forty cases of oculomotor paralyses gave 50 per cent. positive reactions.

Thirty-three cases of parenchymatous keratitis gave twenty-two positive and eleven negative reactions, i.e., 66 per cent. positive. Twenty-five choroido-retinitis cases gave seven positive, i.e., 24 per cent. Eight myopic choroiditis cases gave one positive. Six scleritis gave two positive. Five cases of hemorrhagic retinitis were all negative. Of five zona ophthalmic cases, two positive. Four optic atrophy cases, of which one was positive. Four retinal detachments, one was positive. Thirty-eight sundry cases gave eight positive and eight negative.

Mouradian points out that the results are not very helpful unless taken along with the clinical conclusions, so he gives a very useful table of the results in three classes of cases, syphilis "certain," probable, and doubtful, this last being where there was no evidence about the patient to suggest lues, other than the ocular condition. This table is given below, with the percentages of positive reactions added.

	Certain			Probable			Doubtful		
Diseases.	No.	Positive.	Per Cent.	No.	Positive.	Per Cent.	No.	Positive.	Per Cent.
Iritis	18	12	66	10	4	40	36	9	25
Ocular paralyses	8	6	75	10	6	60	22	8	36.3
Interstitial keratitis	13	11	84.6	13	7	53.8	7	4	57.1
Choroido-retinitis	2	1	—	7	1	—	16	5	—
Optic neuritis	2	1	—	2	—	—	9	2	—
Sundry affections	8	5	—	9	5	—	53	5	—
Total	51	36	—	51	23	—	143	33	—

In lues "certain" 70.5 per cent. give positive reaction.

In lues probable 45 per cent.

In lues doubtful 23 per cent.

Regarding the diagnostic value of the reaction, Leber, Cohen, Guttmann and Igersheimer consider a positive reaction as certain proof of syphilis, while Schumacher and Hessberg even go further and consider a negative reaction as presumptive of no syphilis. The author considers the positive reaction as a strong presumption of lues, but, he says, it does not give the absolute certainty that the finding of the treponema itself does.

The fact that the reaction may be positive in other diseases does not trouble much, as these conditions—leprosy and trypanosomiasis—are rare.

The positive reaction proves the presence of syphilitic antibodies but does not prove that the lesion in question is due to the lues. Errors in the rather complex technique may upset the results.

The negative phase, however, has no significance, and the fact has

to be noted that in 30 per cent. of "certain" lues cases the reaction is negative. This must not be taken as proof that the case is not a luetic one. In doubtful cases a positive reaction gives a strong presumption in favor of syphilis.

Table of percentage of positive reactions in previously published cases added to the author's cases:—

	Cases.	Positive.	Percentage of Positive Reaction.
Iritis and irido-cyclitis	302	89	29.4
Interstitial keratitis	344	291	84.5
Ocular paralyses	126	53	42.1
Choroiditis retinitis	187	34	18.0
Optic neuritis	108	21	19.0
Optic atrophy	29	11	37.9
Ocular tabes	34	26	76.4
Scleritis, etc.	18	6	33.3

Tabes gives a high percentage, 76.4, and interstitial keratitis gives 84.5 per cent.

In irido-cyclitis, choroido-retinitis and optic atrophy and neuritis the number of positive reactions is small, but, Mouradian says, this does not disprove the luetic origin, but merely confirms the previous finding that the reaction is negative in 30 per cent. of "certain" cases.

The examination of the mouth and *the influence oral sepsis may exert on eye disease* is discussed by William Lang (*The Lancet,* May 17, 1913).

He states that his attention was first drawn to the subject of oral sepsis as a factor in the causation of eye diseases by an original observation made by a colleague, Mr. William Hern, who reported he had found pyorrhea in every case of acne rosacea, and noticed that the eruption improved or disappeared after the mouth was treated. At that time a patient with acne rosacea was under care for attacks of keratitis, which had recurred at intervals in spite of local and general medication, but after treating the pyorrhea the keratitis ceased to return.

From this time onwards he examined the gums in all the cases of inflammatory affections where the ordinarily accepted causes of the disease were absent, and thus gradually came to recognize that pyorrhea caused inflammation in every part of the eye.

In hospital practice, where clean mouths are the exception, one sees every day many cases of inflammation of the eye due to oral sepsis. In order to find out what proportion of the cases of inflammation of the eyeball occurring in private practice were due to sepsis, Lang had a

table made from the notes of 10,000 patients. In it is included every case of inflammation, with the exception of those limited to the conjunctiva, where a cause for the disease had been found. The results shown in these tables were unexpected, especially as the cases due to sepsis must have been underestimated in the earlier years, because no search was made in many of the parts of the body which now he would investigate. For example, in the absence of bladder symptoms the urine, when it appeared to be normal to the eye and to the smell, was not examined for micro-organisms, though it might have contained many thousands to the cubic centimetre and have been the cause of the eye affection. Owing to this increase of knowledge the number of cases in which the source remained undiscovered has decreased until it is now half what it was at first, and forms 1.2 per cent. of his later patients.

Table I. The source and number of the cases (215) attributed to sepsis.

Lachrymal sac	1	Large gut infection, including colitis and the like	33
Antrum of Highmore	1	Kidney and bladder	4
Nasal inflammation	2	Male urethra	20
Inflamed tonsils	3	Uterus and appendages	3
Pyorrhea	139	Skin diseases	4
"Indigestion"	2		
Appendicitis	3		

Table II. The number of times that the different parts of the eye were infected in the 215 septic cases of Table I.

Sclerotic	20	Retina	28
Cornea	12	Detached retina	3
Iris	87	Optic neuritis or atrophy	4
Ciliary body	79	Lens (secondary cataract)	14
Choroid	68		

Table III. The causes to which the other cases (168) were attributed and their numbers.

Syphilis, congenital	40	Gout	23
Syphilis, acquired	35	Diabetes	12
Tubercle	27	Following acute fevers	7
Albuminuria	24		

Table IV. The frequency with which the different parts of the eye were affected by the diseases in Table II.

Sclerotic	24	Choroid	35
Cornea	47	Retina	36
Iris	25	Optic neuritis or atrophy	12
Ciliary body	4	Lens (secondary cataract)	1

On comparing the number of cases in Tables I and III the importance of sepsis in the causation of eye diseases is obvious, since 215 are attributed to it alone and only 168 to all the other recognized causes.

Of the 215 toxic cases 180, if the 3 tonsil cases are included, are due to alimentary toxemia, and 139 are credited to pyorrhea alone; hence the importance of oral hygiene. Cases due to gonococcus have been included in this table, because when these patients come to the ophthalmic surgeon they are suffering from iritis and cyclitis, due generally to an infection of the prostate, the remains of an uncured urethritis, which must be dealt with by massage and vaccines if a permanent cure is to be effected.

Tables II and IV record the number of different parts affected; in many patients the disease attacked more than one part. In the septic group, Table II, it will be noticed that the uveal tract is the part chiefly involved, hence the greater number of secondary cataracts; whereas in Table IV the sclerotic and cornea, the retina and optic nerve are more frequently affected.

Though it would appear to be obvious after seeing these tables that sepsis from pyorrhea is an important agent in causing inflammation of the eye, nevertheless the general application of this view is not yet universally accepted. It seems incomprehensible that a surgeon, whose single aim is to avoid sepsis in his operations, can think it a matter of no importance that a person should have a chronic source of sepsis in any part of his body.

The usual objection made is that one sees very bad cases of pyorrhea in people who say that they are enjoying the best of health and who do not complain. These objectors seem to forget that Nature begins to raise a protecting barrier the very moment that the tissues are irritated by bacterial toxins, or are invaded by the bacteria themselves. If the invasion is slow enough, as is the case in pyorrhea, the barrier is efficient and the individual does not appear to suffer. Whereas when the micro-organisms are introduced direct into the circulation there is no time for an efficient barrier to be raised. As long as the patient is in fair health the barrier is capable of doing its work.

Until the medical profession at large recognize the importance of pyorrhea and the gravity of leaving it untreated, one cannot reasonably expect the dental profession to do so either, especially as they are being taught to treat the mouth in a way that makes it impossible to avoid creating sepsis by putting on crowns and building bars and bridges that cannot be kept clean. Until this policy is reversed and everything

is done to enable the mouth to be kept aseptic, the loss of sight, and even total blindness due to pyorrhea, will continue to occur.

The importance of a thorough *examination of all neighboring nasal sinuses* has been dwelt on much of late. There can be no doubt as to the great value of this procedure, and if there is the slightest indication of any nasal difficulty, this organ with its accessory cavities should be carefully gone over. Also in any eye trouble where the diagnosis may be in doubt the possibility of nasal complications should be thoroughly considered. See **Cavities, Neighboring, Ocular relations of**, in Vol. III, page 1810, of this *Encyclopedia*.

A new *biologic test for cancer* has been presented to the medical profession by Emil Abderhalden, of Halle, which, while it may not be of great value to the ophthalmologist, is of sufficient importance to receive a description here.

Time alone can thoroughly prove the accuracy of his test, and only as impartial reports of large numbers of cases examined are offered by reliable workers. It is readily apparent by a casual review of the literature pertaining to the test that the differences in the results obtained are due to some variation as to technic, selection of tissues used as fundaments, unless the test is unreliable. Frankel states that the Abderhalden reaction was not reliable in the cancer cases examined at the research institute at Heidelberg, while Frank and Heimann, Marcus, Epstein, Erpicum abroad, and Lowry in this country report more favorable results.

Apparent errors in the specificity of the test do not appear to be evidenced by malignant conditions failing to give a reaction, as much as the finding of a positive reaction in individuals almost certainly not malignant.

The differences of opinion that arise relative to the findings in the suspiciously malignant cases develop the practical application of the test. The finding of a positive reaction in a known malignant condition is gratifying but of little practical value to the sufferer. The weight of responsibility resting on a positive or negative finding in suspiciously malignant individuals is tremendous. Until further work perfects the technic, a clean-cut, negative reaction carries much more weight than a positive one, because of the many possibilities contributing to an erroneous positive finding.

Dr. C. F. Ball has done much work with the Abderhalden test and the following is a description of the technic in his own words:

"Only distilled water, distilled at the time of making the test, was used, except in a very few instances in the very first of my work. All glassware is carefully washed, drained, and rinsed with alcohol, fol-

lowed by ether; it is then sterilized by dry heat. The entire work has been done in a room never used for bacterio-pathologic work. All apparatus is reserved exclusively for this work. I have used a few of the 579 Schleicher and Schüll thimbles, but practically all of my work was done using the 579A thimbles, selected as follows:

"The thimbles were first well soaked in cold water, then boiled for five minutes. When cool, they were placed on the inner end of the funnel-form stopper of my dialyzing chamber. This was done at first with bare, well-washed hands, but now I use rubber gloves entirely and handle the thimbles as little as possible, rinsing with sterile, distilled water before replacing in my dialyzing outfit, previously filled with 15 or 20 c.c. of distilled water. Cotton plugs were placed and then the entire outfit was sterilized by steam heat. No part of the remaining technic allows of the possibility of contamination of the outer wall, or surrounding sterile distilled water. Chloroform and toluene were added through the side tube provided for this purpose. Sufficient toluene was used to overlie the surface thoroughly. The apparatus was then ready to receive the materials intended for dialysis. New thimbles were filled with 5 c.c. of a 1 per cent. silk peptone (Hoechst) solution, covered with 10 drops of toluene, placed in an electrical incubator for from fourteen to sixteen hours. After removal from the incubator, 5 c.c. of the diffusate were tested with 0.2 c.c. of a 1 per cent. ninhydrin solution. Only those thimbles giving a corresponding faint shade of blue color were reserved for further examination.

"The reserved thimbles were then run, first with 5 c.c. of a 10 per cent. solution of egg albumin, and if any were found to give the ninhydrin reaction they were immediately discarded. By selcting only such thimbles as give a faint blue ninhydrin reaction in the first test, seldom one is found that is permeable to the albumins. New thimbles are never used in an actual test until they have been run at least twice with human serum and test negative, 5 c.c. of diffusate to 0.2 c.c. of a 1 per cent. solution of ninhydrin; examination is run in duplicate with a previously tested and satisfactory set of thimbles and the new thimbles judged accordingly.

"I have always selected thimbles in groups of four, notching the top with one to four notches, and punching in the side just below the notches one or more holes; in any set of four, each has the same hole-punch as one 0 to four 0; or one 000 to four 000. Each set of thimbles is placed in a wide-mouthed container, of 120 c.c. capacity. The bottle was then filled with distilled water and the whole placed in a steam sterilizer for one-half hour. After removal and cooling, 1 c.c. of chloroform was added, and the surface of the chloroform-water was

well covered with toluene. The cork stopper was put in place and the thimbles then set away in the ice-box, kept at a temperature of about 8 C. (46.4 F.). Control experiments demonstrate that only the thimbles barely permeable to the silk peptone solution are suitable for the cancer-test as cancer-tissue is quite readily broken down by the "protective ferment" in the dialyzing thimble.

"Preparation of tissue, selected as previously suggested, must be complete in the removal of all traces of blood and the saving of only that portion of the cancerous material that contains the smallest amount of near-normal tissue invaded. Such tissue is cut up into small pieces about the size of a pea, well washed, and then thrown into a large volume of boiling water, 10 parts by volume, containing 1 or 2 drops of glacial acetic acid, and allowed to boil for just five minutes. The tissue is then drained of its boiling water and again similarly boiled except that no acetic acid is used. The boiling is repeated in this manner for from three to six boilings, until the boiling-water gives not the slightest reaction with ninhydrin, using 1 c.c. of a 1 per cent. solution of ninhydrin to 5 c.c. of the liquor. Any tissue requiring more than five or six boilings is discarded. After the tissue has tested negative to ninhydrin, by boiling in bulk, the tissue is then placed in small quantities—about 15 gm.—in a 60-c.c. Erlenmayer flask, and again boiled. After the contents of the flask have cooled, chloroform is added, and the whole covered with toluene, the mouth of the flask is plugged with cotton, and the tissue then placed in the ice-box in the water in which it was last boiled. Whenever tissue is removed for use, the remaining tissue is similarly treated.

"At least 30 c.c. of blood should be taken from the patient, either by venipuncture or actual bloodletting under strict aseptic precautions, and always using only dry glassware. The blood is usually collected by using a modified Jellinghaus-Losee outfit. Constant rigidity should be maintained in using only blood obtained before the morning meal, or if the blood has to be taken in the late afternoon, the patient should present himself without having eaten dinner: not even a lunch is allowed. The blood is allowed to stand at room temperature in the collecting outfit until the serum separates, which varies from three to twelve hours—usually four to six hours sufficing. Accordingly, blood collected at 8 o'clock in the morning is usually ready for setting up in the afternoon: that collected in late afternoon is ready next morning, but should be kept in an ice-box over night.

"During the time that the blood is separating, apparatus required for the test should be made ready; and the fundaments to be used should be reboiled and made to test negative to ninhydrin, using 1 c.c.

of a 1 per cent. solution to 5 c.c. of the boiling water. In reboiling the tissue, care should be taken to use ten times by volume the amount of distilled water as tissue to be prepared.

"The separated serum is pipetted off from the collecting outfit into a centrifuge tube, and centrifuged at *high* speed until the serum is perfectly clear, and free from any reddish tint or cloudy appearance. One and one-half c.c. of such serum is placed at once in a small test-tube in the waterbath, maintained at a temperature of 56 C. (132.8 F.), for the purpose of inactivating the amount of serum, which is to be used as a control along with the prime fundament to be used with the untreated serum. At the same time that the serum is being inactivated, the dialyzing outfits as described previously are sterilizing. After the outfit has been sterilized and cooled, chloroform is added through the side tube and then sufficient toluene to cover thoroughly the sterile, distilled water surrounding the sterile thimble, keeping it free from all possibility of outside contamination due to the special construction of this apparatus. Each dialyzing outfit is labeled and the formula made up of various fundaments to be used, writing on the label the particular fundament and the amount of serum that each outfit is to receive. Then a small piece, from 0.5 to 1 gm., is dropped through the funnel-form stopper supporting the dialyzing thimble on its inner end, in spaced relation to the wall of the outer container. One c.c. of serum is then added to each (formerly used 1.5 c.c.) except to the one to receive the inactivated serum. After placing the serum, 10 drops of toluene are added, replacing the cotton plug, at which time the entire set is ready for the incubator. They are placed in an electrical incubator, at 37° C. (98.6° F.). Abderhalden specifies in the pregnancy test that dialysis should go on for from fourteen to sixteen hours; experience with his technic in the cancer test indicates that a shorter period, about twelve hours, gives better differentiation of color reactions, and so, better satisfaction.

"After removal from the incubator, the funnel-form stopper supporting its dialyzing thimble and contents is removed. Five c.c. of the dialysate is placed in a calibrated test-tube, to which is added 0.1 c.c. of a 1 per cent. solution of ninhydrin. The test-tube with its contents is then boiled with its fellow in an electrical heating device so constructed that a definite, constant and predetermined heat is applied, boiling the contents of the test-tubes for exactly one minute (author's electric test-tube heater). By thus boiling the dialysates with ninhydrin, the ratio of evaporation is constant for each. After cooling for one-half hour, interpretations are made by the color reactions obtained. If the test has gone on satisfactorily, negative reactions will be

apparent by the entire absence of any color in the contents of its test-tube. Positive reactions will manifest themselves by a distinct, usually not too deep, bluish-purple color in the contents of the test-tube. Such reactions are easy of interpretation as to reactions obtained. The association of all the reactions obtained, together with the particular formula for the test, is necessary for the making of a diagnosis. My most frequently used formula for a set of four thimbles is the following:

"One thimble containing the prime fundament and untreated serum; one thimble containing the prime fundament and inactivated serum; one thimble with either serum or fundament alone, as might be indicated by a suspicion as to the reliability of either one or the other; the fourth thimble contains the secondary fundament, common to any particular series of studies. Invariably my secondary fundament has been a placental protein. In a few instances I have also used muscle-tissue, brain-cortex, and thyroid gland. When the interpretation of the test depends on the meaning of various shades of color reactions, it cannot be considered in any other way than unsatisfactory, and indicates the necessity for a re-examination. Whenever possible, controls should be run using the same formula either with a known normal or malignant. The larger number of my cases were run with a known control, but this was not invariable."

These examples were to show how important a complete survey and general examination of the patient is and one may feel sure that he who fails to avail himself of these helps, robs himself of valuable means for accurate diagnosis.

DETAIL OBJECTIVE EXAMINATION

The first and most important thing to be considered in the objective examination is *the illumination of the patient*. The ordinary examination of the eye for the purpose of making a diagnosis is best accomplished by the use of good, clear daylight rays reflected through a window, in front of which sits the patient. The surgeon stands in front of the patient so adjusting his person that no shadow is thrown on the subject, but in such a position that he can examine the part thoroughly.

The chair in which the patient sits should be of the proper height, so that the surgeon may comfortably see directly into the examined eyes. A special chair is not necessary, but several have been designed for this purpose and are shown in illustrations. A head-rest which may be attached to the back of any ordinary chair, thereby converting it into an efficient ophthalmic chair, is also shown.

Now proceeding to the special examination of the eyes one begins by *observing both eyes simultaneously and comparing one with the other.* The size of the palpebral openings is noted and any inequality is

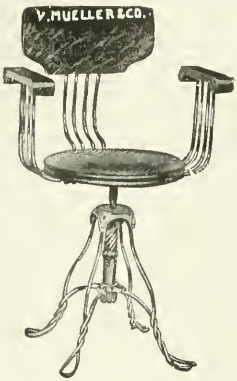

A Very Simple but Practical Examination Chair.

Allison Ophthalmic Chair.

quickly discerned. If an orbital or brain tumor should be present causing exophthalmus or lateral displacement of the globe, these conditions are much more easily detected by a comparative examination of both eyes. Such marked difference as the absence of one eye; a turn-

ing of the globe; the presence of an inflammatory swelling, or the existence of a tumor or ulcer, will immediately be noticed.

Next centering attention on one eye the surgeon first observes the condition of *the eyelashes.* Whether they are present in normal



Mueller Detachable Head Rest.

Ophthalmic Examination Chair with Tilting Attachment.

number and evenly distributed along the margin of the lid. Notice should be taken as to the direction of the cilia. If they turn toward the globe, they are improperly directed (trichiasis) or if they are present in two or more rows (distichiasis).

Search should be made for small, white, downy hairs, which may

grow from any part of the lid margin, and are often found at the inner canthus, where they rub the globe or caruncle at every winking act. "Wild hairs" which are short, thick and black, often cause much irritation. Parasites (phthiriasis oculorum), may be found at times about the roots of the cilia. If the lashes are found matted together with a moist substance, it is at once suggested that some form of conjunctivitis must exist.

After the eyelashes the next step is to examine *the lids.* They should be carefully observed as to color, mobility and thickness. The mouths of the Meibomian glands, at the edge of the lids, in the tarsal cartilages, are carefully examined. A localized inflammatory swelling of the lid will suggest trauma, hordeolum, erysipelas, erythema, sarcoma, an inflamed chalazion, or acute circumscribed edema. A local non-inflammatory swelling may be due to a dislocated lachrymal gland or a chalazion. If it be the latter a hard, round body, like a shot, will be felt. A local, non-inflammatory swelling may also be due to nephritis. A general inflammatory swelling of the lids is met with in trauma, gonorrheal conjunctivitis, and erysipelas. A general non-inflammatory swelling may be caused by emphysema, in which case palpitation will elicit the characteristic crepitation; or it may come from the accidental discharge of a solution which has been thrown into the cellular tissue while injecting the naso-lachrymal duct.

The puncta should be examined for permeability, pressure at the same time being made over the lachrymal sac in order to express from it, through the puncta, any contained fluid.

The contour of the lid may be changed by scars from wounds, ulcerations, or burns. The finger should be passed over the lower part of the anterior surface of the upper, and corresponding portion of the lower, lid, to feel for thickened areas. If present, they suggest tarsitis or occlusion of the Meibomian ducts.

Having completed this general survey of those external parts of the lids which are easily seen, the examiner next proceeds to the *inspection of the conjunctiva lining the inner surface of the lids.* To do this he must evert both lids so as to bring these parts into view. This is very easy of accomplishment so far as the lower lid is concerned. The patient is told to look up and while he is doing so the examiner pulls down the skin of the lid with the tip of one finger in such a manner as to cause the palpebral conjunctiva and the conjunctiva of the lower fornix to roll out into plain view. *To evert the upper lid* the patient is required to direct his eyes downward; the central lashes of the lid are then grasped betwen the thumb and first finger and traction is made a little downward and away from the eyeball. At the same time the

surgeon places the tip of the thumb of the other hand upon the skin of the lid, well back from its edge, so as to be beyond the upper limit of the tarsal cartilage. He now presses downward with this thumb at the same time, turns the edge of the lid upward by means of the lashes held by the other hand. The thumb, against which the lid has now been turned, is removed and the lid held everted by the opposite thumb holding the lashes and edge of the lid against the eyebrow. This procedure is one that is found rather awkward of accomplishment at first, but after a little practice becomes easy and can be done with very little or no discomfort to the patient. Sometimes when lids are small and tight it will be found easier to turn them over a probe or pencil, than over the thumb.

A somewhat different method of everting the upper lid is described as follows:

The patient is told to look down during the whole time required for everting the lid. The surgeon stands behind the operating chair. The forefinger of the left hand is placed upon the upper lid just below the eyebrow and the lid drawn by the finger tip up and away from the eyeball in such a manner that the cilia point upward. The eyelashes are then grasped by the thumb and forefinger of the opposite hand, without touching the globe. The patient is now directed to continue looking downward, the lid is drawn down and away from the globe, while the forefinger, which was in position below the brow, is slipped to the upper margin of the tarsal cartilage and pressed downward. At the same time the lid is quickly turned over the left finger nail.

Carl Hartzell (*Deutsche med. Wochenschr.*, June 29, 1911) describes an invention of his own which he calls an *ectropionator* (see cut), the purpose of which is to enable the operator to evert the upper lid with one hand. It is intended to do its work thoroughly and to expose completely the upper folds of the conjunctiva. Meantime, with the aid of the unoccupied hand, applications, and even minor operations, can be carried on without the necessity of providing an assistant.

Very often on examining the eyes of infants, in whom the lids have become edematous and swollen from crying or other causes, the simple separating with thumb and finger will cause the lids to evert themselves and completely expose the inner surfaces.

In everting the lids of small children the position of the patient and surgeon, described below, will be found of great value:

The surgeon sits facing the nurse, who holds the child firmly in her lap by grasping its hands and legs. The child's body is in a horizontal position, the head being toward the examiner and resting between his knees. By pressing the knees tightly against the patient's ears he

holds the head securely, allowing both his hands to be free for manipulating the lids. Children are often terrified and may struggle, so it is well to be very careful to avoid pressure on the globe. Often by simply waiting until the child becomes tired, one is able to easily examine its eyes. However, in some cases with an affection of the conjunctiva or cornea, producing photophobia, or if there is great swelling of the lids, it may often become necessary to use the ordinary lid elevators. Usually one instrument is sufficient, being introduced under the upper lid, while the thumb of the surgeon pulls down the lower lid. Great care should be exercised in placing the lid hook in position, for, if

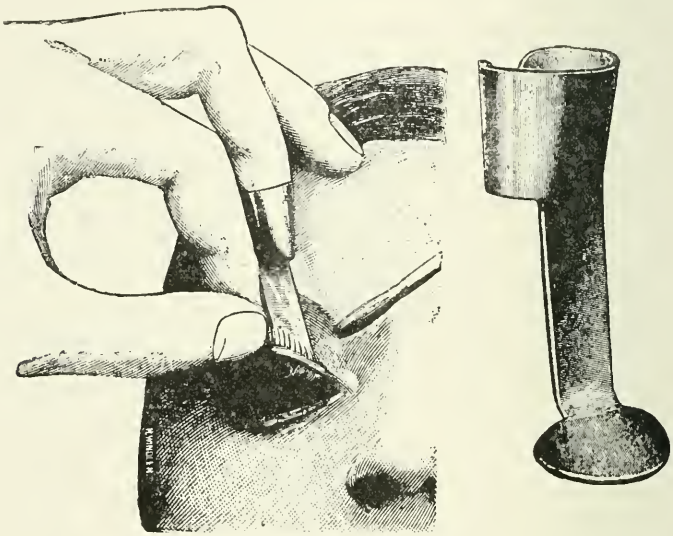

Hartzell's Ectropionator.

the cornea be ulcerated and undue pressure be excited, it may be ruptured and the lens evacuated.

The so-called *secondary eversion of the upper lid* is a manipulation which is often omitted, but it is of great value in some cases.

It exposes the retrotarsal fold and requires some skill to accomplish without instrumentation. The edge of the everted upper lid is pressed firmly against the supraorbital margin with the thumb of the left hand; then push the lower lid upward over the cornea with the right index finger, at the same time exerting gentle backward pressure upon the eyeball.

The best instrument for accomplishing it is the Noyes retractor (see illustration). After turning the upper lid in the ordinary manner

the retractor is passed beneath the everted lid so that the lip of the instrument passes into the upper fornix. We now have exposed a region which is a favorite seat for trachoma and foreign bodies. Papillary tumors of the conjunctiva occasionally grow from this part, owing to the irritation caused by the lodgment of a foreign body.

After thoroughly observing the condition of the conjunctival surfaces of the lids, looking carefully for any change in smoothness, thickness, or secretion of this membrane we proceed to the *ocular conjunctiva.* One first notes if any undue redness is present, and, if present, whether it is greatest posteriorly, in the region of the fornices, or anteriorly, around the corneo-scleral junction.

An outline for *an easy method of diagnosing the commoner forms of inflammations,* which is based very decidedly on the condition of the ocular conjunctiva is given below:

Noyes' Lid Retractor for Secondary Eversion of the Upper Lid.

It happens that the reddened appearance presented by the eyeball (due to the engorgement of otherwise invisible vessels upon a background of the white sclera) is common to most inflammations of the eye. Not only in the superficial but in deep-seated ocular lesions as well, one or all the venous and arterial systems of the anterior segment of the globe become injected and more or less deeply tinge the otherwise whitish globe.

Taking this clinical observation as a starting point and combining with it careful inspection of the eye itself we may readily distinguish the various eye inflammations from one another, and from affections non-inflammatory in character, by means of the following scheme, drawn up after the plan pursued by Fenwick in his small work (1870) on medical diagnosis:

(a) The eyeball is wholly or partially reddened, without discomfort or other symptom. (b) The eyeball is reddened and uncomfortable, but without actual pain. (c) The eyeball is red and distinctly painful.

(a) The eyeball is wholly or partially reddened without discomfort or other symptom. Practically one condition only is included under this heading, viz., subconjunctival hemorrhage. There is no discharge from the eye and close inspection of it shows that the redness is localized as a deep red, smooth, uniform patch, obscuring the scleral vessels.

Except in the recurrent type and in patients over 40 years of age (when Bright's disease or organic heart lesions may be suspected) it is an innocent condition.

(b) The eyeball is reddened and uncomfortable, but there is no marked pain. Here we have to deal with hyperemia of the conjunctiva, a foreign body in the cornea or conjunctival sac, phlyctenules of the conjunctiva, and most of the forms of infection of the conjunctiva popularly known as acute and chronic conjunctivitis. In hyperemia of the conjunctiva the lining of the everted lids looks redder and rougher than normal and than the ocular conjunctiva, there are slight smarting, burning and itching of the lids and, at times, a foreign body sensation. No secretion forms except a little at the inner canthus, which occasionally glues the lid edges together in the morning. Foreign bodies in the cornea or in the sac are always to be suspected when the patient complains of constant scratching and of that peculiar sensation, known to every layman, of a corpus alienum. The sac and cornea should be scanned with a magnifying lens when these symptoms are present. Phlyctenules of or pimples on the conjunctiva are commonly seen on the surface of the globe, surrounded by a patch of blood vessels. Their diagnosis is extremely easy in the majority of cases. In most of the forms of acute and chronic conjunctivitis there is no distinct pain, but smarting, burning and foreign body sensations (not constant) with a mucous or muco-purulent discharge, which is found on the lid edges and at the inner canthus in sufficient quantity to glue the lashes together so that they must be washed apart before the eyes can be opened after a night's sleep. The injection and swelling of the conjunctiva, and a loss of its transparency, is well seen on everting the lids and inspecting the posterior aspect of the globe. Only in long-standing or very acute cases does the redness extend to the margin of the cornea. The tension of the eyeball is normal and the latter is rarely tender to the touch.

(c) The eyeball is red and painful. These symptoms are common to iritis, glaucoma, phlyctenules of the cornea, ulcer of the cornea, scleritis and episcleritis, ocular neuralgia and gonorrheal infection of the conjunctiva.

In iritis the redness is at first confined to the corneal region of the ocular conjunctiva, although in a few days all the vessels of the globe are engorged. There are also marked photophobia and a copious flow of tears; the eyeball is tender to the touch and the pain (in the eye and above it) becomes worse toward evening. The tension of the eye is rarely increased and the pupil is contracted.

The temperature of the conjunctiva is of some importance and

several methods have at different times been suggested for recording it, but mostly these investigations have only been of an experimental, laboratory significance. However, an instrument which would accurately and easily show changes in the temperature of the eye would assist not infrequently in arriving at a diagnosis. Particularly in the two following directions might it prove of value.

a. Indicating changes of temperature which accompany certain inflammatory conditions of the cornea, uvea or other portions of the globe itself.

b. Inasmuch as efforts of accommodation and convergence are often followed by slight injection of the conjunctiva, it is quite possible that with these two couples we may be able to obtain a better idea of the metabolic changes which take place in that complicated process which we call eye-strain.

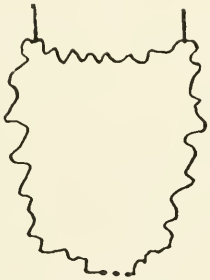

The Thermo-Couple of Lucien Howe.
General plan of the arrangement of two thermo-couples with a galvanometer in circuit.

In a word, the field which thus opens before us for the first time seems to be one ripe and ready for a harvest of interesting facts by the ophthalmologists of the future.

Some students, appreciating the probable importance of this subject, have attempted measurements, but all of them were made with some modification of the mercurial thermometer. One form of this which attracted considerable attention was suggested by Galezowski. It had a flat bulb small enough to pass easily beneath the lid, and the tube extended 8 or 10 cm. at right angles to the bulb; but the glass of the bulb was so thin that the least pressure of the lid produced a rise of the mercury, and of course constant readings were impossible.

Lucien Howe has described (*Jour. A. M. A.*, Sept. 27, 1913, Part 2) an instrument which makes use of a different principle, and which at this time is the nearest approach to a practical one that has been brought forward. As described by the inventor it consists mainly of

a thermo-couple, which is also called the "thermo-electric junction" or "thermal junction."

If two strips of metal of unequal conducting power are soldered together, the line where they meet is of course a "junction." If the free ends of these two strips are connected, and then if the line of their first junction is heated or cooled, that junction becomes a "thermo-couple," or thermo-electric junction. An electric current is then generated throughout the circuit, and if a galvanometer be placed in that circuit the strength of the current will be indicated by the index.

Or again, we may arrange two such couples in the circuit, placing the couples so that they are technically in "multiple" or "parallel," having the galvanometer in series with one of the connections. Such an arrangement is sketched in the accompanying diagram. Then if



The Thermo-Couple of Lucien Howe.
(Actual size.)

both couples are heated or cooled to the same degree at the same time, the electric current developed by each couple neutralizes, as it were, the current which is developed in the other and no change is registered by the galvanometer.

If one of these couples, however, is heated or cooled more than the other, the excess of electric current developed will be shown by the index of the galvanometer. This arrangement of two thermo-couples has been used for some years in laboratories and certain industrial establishments for measuring slight differences of temperature between two mediums.

The following is the general plan of the two thermo-couples which have proved most useful for measuring the temperature of the conjunctiva as compared with that of the mouth:

1. A very fine covered copper wire extends about 8 or 10 feet from one post of a galvanometer.

2. The free end of this copper wire is fused to one end of a composition wire, which is particularly useful for delicate thermo-couples. Several kinds of such wire are on the market. The point of fusion of these two delicate wires forms the first of the two thermo-couples.

3. The other end of this wire is fused with a second piece of copper wire. This junction forms the second thermo-couple.

4. The other end of this copper wire extends about 8 or 10 feet to the second post of the galvanometer.

Theoretically these two couples would be sufficient to indicate on a suitable galvanometer any difference of temperature between them. But practically we know that:



The Thermo-Couple of Lucien Howe.
(Actual size.)

a. The junction of the copper, and of the composition wire must be secure.

b. The two wires must be thoroughly insulated, and not easily injured.

c. They must be so protected as to be easily and thoroughly disinfected.

d. They must "balance" exactly. That is, neither should produce any current in excess of its fellow, when both couples are at the same temperature.

It is desirable, therefore, to glance at the special forms of the thermo-couples which, after numerous trials, have been found most suited for introduction into the conjunctival sac and into the mouth, respectively.

A. The couple for the conjunctiva. This is seen, natural size, in the figure. In making records it is convenient to designate this one as

"Couple A," and to attach its wire to the post of the galvanometer which corresponds to black numbers on the scale.

B. The couple for the mouth. This is also seen, natural size, in the figure. In making records it is convenient to designate this one as "Couple B," and to attach its wire to the post of the galvanometer which corresponds to red numbers on the scale.

Although any variety may be used, the galvanometer found most convenient for this purpose was the D'Arsonval, Type P, mounted on a tripod. Descriptions of the D'Arsonval galvanometer can be found in

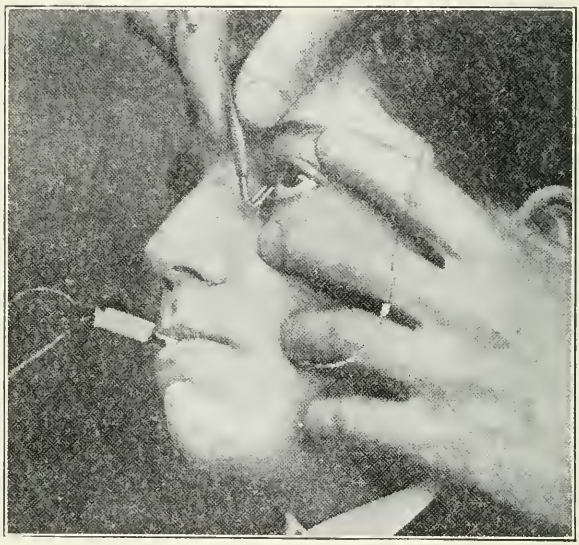

The Thermo-Couple of Lucien Howe.
Method of using the two thermo-couples.

any treatise on magnetism. Any unequal heating or cooling of the two couples produces a current which causes a suspended mirror to turn from side to side. The mirror is viewed through a telescope, and reflects the figures of a scale. This scale on the horizontal strip is 50 cm. long, graduated in millimeters, and numbered 25 red to 0 to 25 black.

According to measurements made with Howe's couples it was found that, 1 mm. of the scale corresponded to about six hundredths of one degree Centigrade (0.06° C.). Now it is not difficult for an observer to distinguish a movement of the index of a half or even a quarter of a millimeter. That is to say, the couples arranged in this way show a

difference of temperature of 0.03° C. or even 0.015° C. This is the sensitiveness expressed in figures.

An illustration shows better what that means. If the hand is placed three or four inches from one of these couples, the radiated heat is sufficient to make a very distinct movement of the index of the galvanometer. If the finger touches one couple the index at once swings over 30, 40, or even more, millimeters. Or if one couple is held in the hand and gently breathed on, the index flies rapidly not only to the end of the scale, but so far beyond as to make any reading impossible. In other words, we have here a method of measurement far more sensi-

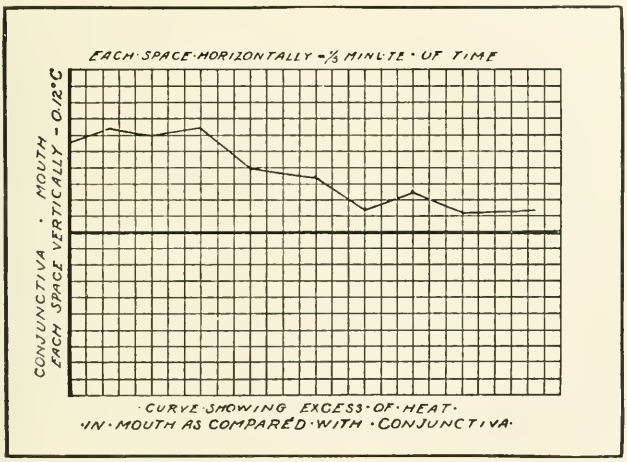

The Thermo-Couple of Lucien Howe.
Chart of variation of temperature.

tive than by any thermometer which could possibly be used. The method of using the apparatus is as follows:

As a preliminary we must make sure that the two couples "balance" each other; in other words, that the galvanometer registers zero when the two couples are in some medium—air or water—in which their temperatures are exactly the same. It is also essential to know how many seconds or minutes are necessary for such a balancing to take place, as this depends largely on the relative thickness of the glass which insulates each thermo-couple, and somewhat on the distance which each is covered. Let us suppose that with a given pair of couples we have ascertained that such a balancing takes place after two minutes and a quarter. Also suppose that we have applied a 5 per cent. solution of cocain two or three times to the conjunctiva to

be examined. The patient being then seated comfortably and conveniently near to the galvanometer, Couple B is placed in his mouth. He is asked to close his lips on it, and allow the glass tube to rest against the side of the tongue, as is done when we use a clinical thermometer. This couple must of course first remain in that position for at least the two minutes and a half, which had been found necessary by previous experiment to bring it up to the body temperature. Having done this, the surgeon takes Couple A with the thumb and index-finger of the right hand, the lid is raised, and the couple introduced gently beneath the lid.

Care should be taken to have the portion which is beneath the lid actually in contact with the globe. If the point is bent forward so as to cause the lid to project and produce an air space between the lid and globe even a few millimeters wide, the effect is seen at once.

While the two couples are thus held in position by the surgeon, an assistant looks through the telescope of the galvanometer to observe the changes in the index, and to record them as they occur. At first the index may show that the mouth registers as much as 1 or 2 degrees above the temperature of the eye. But if care is taken to have the patient keep Couple B gently but constantly against the tongue, and if the operator is equally careful to rest Couple A against the eye, after from three to four or five minutes the temperature becomes gradually more equalized, until, under normal conditions, Couple A, in the cul-de-sac near the inner or outer canthus of the eye, registers from 0.2 to 0.3° C. lower temperature than that of the mouth.

This can be shown on a system of coordinates in which the zero line represents a perfect balance between the two couples, A and B, no matter what the absolute temperature may be. Each division of the abscissa (the vertical line) below the horizontal zero line shows that the index on the scale of the galvanometer has moved 2 mm. toward the black side—in other words, that the temperature of Couple A (the one used for the eye) is 0.12 degree Centigrade warmer than Couple B.

On the other hand, each division of the vertical line above the horizontal zero line shows that the index of the galvanometer has moved 2 mm. toward the red side of the scale—in other words, that Couple B (in the mouth) is 0.12 degree warmer than Couple A.

Each division of the horizontal lines represents one-fifth of a minute. Such a graphic representation of the variation of temperature in one observation is shown in the diagram.

After this necessarily detailed description of the construction and method of using these thermo-couples, the question naturally arises,

What do we learn from them? The results may be briefly stated as follows:

1. We know now and for the first time that the temperature of the cul-de-sac of the conjunctiva near the outer or inner canthus is usually from about 0.3 to 0.4 degree C. lower than that of the mouth. This finding was at first rather surprising, and was naturally attributed to some fault in the instrument or in manipulation. Repeated trials, however, on different individuals seem to establish the fact beyond question. The reason of this is probably that the couple placed in the mouth rests against the tongue, and is protected by that on one side, and the thick layer of facial muscles on the other. On the other hand, the globe of the eye is protected only by the lids, much thinner, of course, than the cheek, and therefore not only colder, but more sensitive to variations of external temperature.

2. The temperature of the conjunctiva immediately over the cornea in six individuals was found to be on the average 0.1 degree C. lower than at the outer or inner canthus.

It will be observed that 36.9° C., or about 98.6° F., can be considered as the normal temperature. In several of the measurements the patients held in the mouth not only Couple B but also a Centigrade thermometer graduated in fifths of a degree, and accurately corrected by the Bureau of Standards. This gave the absolute temperature of the mouth, from which by comparison it was possible to obtain the absolute temperature of the conjunctiva. In these measurements also care was taken that no cold or warm fluids or food had been taken into the mouth for some time previously, as such substances affect the temperature for minutes or even for a few hours.

3. It is possible by this method to measure for the first time to what extent cold or hot applications to the outer portions of the lids really change the temperature of the conjunctiva. It was found, for example, in one case that when pieces of cotton moistened with ice-water were applied to the lids in rapid succession four or five minutes, the temperature of the conjunctiva could easily be reduced 1 or about 1.5 degrees Centigrade.

On the other hand, the difficulty in reducing the temperature below that increased rapidly with each fraction of a degree.

This point is of importance in connection with the treatment of bacterial infections. It is well known that many of the forms which invade the conjunctiva have their vitality lessened in proportion to the decrease in temperature. Practically, however, it is difficult or impossible to produce such a change in the temperature as prevents the growth of these bacteria in the test-tube. This is a phase of the

subject which seems worthy of much more careful study concerning each separate germ. The temperature of the interior of the globe has been measured in two cases in which a practically normal eye was about to be enucleated on account of malignant growths in the orbit. These measurements seem to show that the temperature of the interior of the globe is a little higher than that of the conjunctiva and lower than that of the mouth.

The condition of *the lachrymal apparatus* should next be observed by the examiner. The puncta should be carefully examined as to the presence or absence of a foreign body, such as a stray eye-lash. Notice whether the puncta are directed properly, so as to take up the flow of tears. In the normal position, it is not possible to see the punctum except on lifting the lid away from the eye ball.

Palpation reveals the condition of the tear-sac. If on pressure we cause a discharge of pus or mucus into the conjunctival sac above or, as is less frequently seen, into the nose below, we may feel assured that the sac is diseased. If there is doubt as to the potency of the drainage apparatus, a small amount of warm boric acid solution may be injected into the lower canaliculus from a hypodermic syringe armed with a blunt needle. If the fluid runs freely into the nose we may assume that the drainage system is clear. But if the fluid returns into the conjunctival sac by way of the upper canaliculus, there is either an obstruction or stricture.

Another method of testing the condition of the lachrymal passages is to place several drops of a 2 per cent. fluorescein solution on the conjunctiva and then after waiting several minutes have the patient blow his nose into a clean handkerchief. The solution will, if the passages are clear, have passed into the nose and will be found as stains on the handkerchief.

The accessory lachrymal gland may be seen by drawing the upper lid well away from the globe and at the same time having the patient look downward. Under normal conditions the gland proper cannot be seen or felt.

Having now completed our examination of those structures immediately surrounding the eye-ball itself, we begin *observations of the globe* by turning our attention first to its position in the orbit. By this is meant whether there may be a condition of exophthalmus present. A marked exophthalmus is easily noticed, but a slight one is not readily distinguished, particularly if it involves both eyes. In those cases of slight protrusion where it is a question as to whether a pathological condition is present, accurate measurements should be taken

with an exophthalmometer. These can be repeated from time to time and by comparison of the findings valuable deductions made.

Hertel has devised an *exophthalmometer* which measures the position of the eye-ball accurately and rapidly. The instrument (see figure) is fitted with two movable mirror and scale carriers with sleeves by which they may be slid along a guide bar and accurately set to the outer margins of the orbital cavities of the patient's eyes. The distance between these margins is shown by the scale on the guide bar. Every time a fresh measurement is to be taken the instrument may be quickly set by the scale. The operator looks with both eyes into the left or right pair of crossed mirrors. The lower mirror shows the lower half of the vertical profile of the cornea turned round into



Exophthalmometer of Hertel.

a plane at right angles to the observer's line of sight, whilst the upper mirror forms an image of the scale for measuring the protrusion of the cornea in approximately the same plane in which the profile of the cornea is seen; the two images are accordingly seen without any appreciable amount of stereoscopic parallax. In the event of the corneal apex being situated exactly 20 mm. nearer to the meridional plane than the points where the instrument rests on the orbital margins the plane of the scale image and that of the corneal profile are strictly coincident. The reading gives the distance in millimeters from a frontal plane passing through the points of application on the orbital margins.

The exophthalmometer of Lohmann is shown in figure. It is supported by a spring extending from h, which rests over the glabella, to the occiput. From h the spring p supports a horizontal arm parallel to the plane of the face to each end of which is carried the measuring apparatus proper. This rests against the middle of the outer margin of the orbit, with the millimeter scale above, a mirror, Sp, below, and the index Z moved by a screw. With the instrument in position the eye of the observer is so placed that the index appears to coincide

with its reflection in the mirror. The index is then moved by the screw until it appears tangent to the cornea at its anterior pole, when the protrusion of the eye may be read from the millimeter scale.

The real examination of the condition of the eye-ball now begins by first observing the condition of *the sclera.* In adults this should be of a clear white, but in very old individuals it may become quite yellowish and still be healthy. A bulging of the sclera may indicate either the position of an intra-ocular tumor or it may be simply a

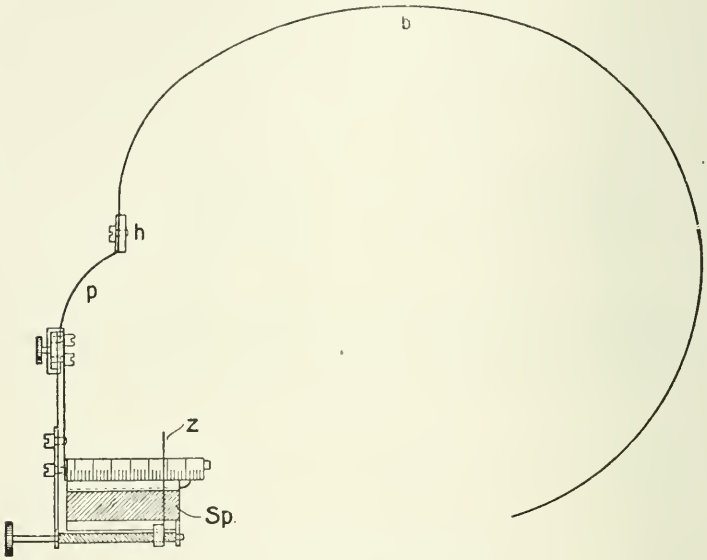

Lohmann's Exophthalmometer.

staphyloma marking the site of an old injury or idiopathic inflammation. If it should be the latter transillumination will show the difference. The subject of transillumination is considered in full under **Diaphanoscopy,** Vol. V, p. 3938, of this *Encyclopedia.*

Proceeding to *the cornea* one first considers its size. The average horizontal diameter of the normal cornea is 11.6 mm. This measurement can roughly be made by simply holding a small ruler in front of the eye and noting at what points the sclero-corneal margins are seen. However, to accurately determine this diameter a special instrument is needed and the one designed by Wessely seems to be very true and easy of operation. In addition to the purpose for which it was invented it can also be used for measuring the distance between the corneal vertex and the apex of the spectacle lens, which is an important datum to know in many prescriptions for glasses.

Since the curved profile of the cornea renders it impossible to apply a straight-edged scale with any degree of accuracy, the plan has been adopted of eliminating errors by measuring the image of an object as seen by parallel rays with the eye applied at the principal focus of a lens, i.e., by what is known as a telecentric arrangement.

When the observation is made through a stop situated in the posterior focal plane F' of a lens it follows that the rays proceeding from the

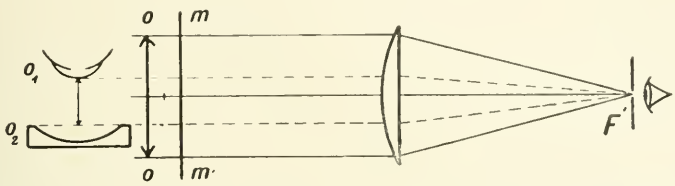

Diagrammatic Chart of Rays through the Keratometer of Wessely.

object to the lens will be parallel to its axis (see figure). If now a scale be placed in front of the object oo a correct reading of the size of the object will be obtained, no matter what its position may be.

The keratometer is constructed upon this principle. The stop (1, see figure) is situated in the posterior focal plane of a +6-diopter lens mounted within the tube (2). The opposite end of the tube carries a vulcanite ring (3), by means of which the instrument may be rested

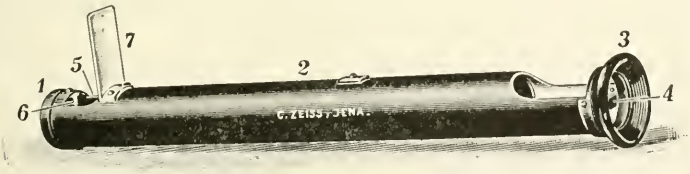

Keratometer of Wessely.

upon the margin of the orbital cavity of the patient's eye. Within the ring a scale (4) divided into half millimeters is so mounted that its upper edge may pass accurately through the centre of the ring. In front of the ring the tube has a large excision through which sufficient light may reach the scale and the patient's eye.

The scale (4) is situated near the anterior focus of the lens, and the same applies to the cornea which is to be measured, and hence both the scale and the cornea can easily be seen magnified 1.5 times by an eye placed in front of the stop (1). The tube has another excision (5) in front of the stop (1). Within this excision the tube carries a

small white mark (6), upon which the patient is required to fix his sight. A white screen (7) serves to illuminate the fixing mark with diffuse reflected light.

A cornea of any diameter may be measured with the instrument. All that is necessary is to rotate the instrument whilst the hard rubber ring is placed upon the fingers which are being used for stretching the eyelids apart. The instrument is also available for measuring the pupils; it may, in fact, be used for measuring the bodies of any shape whose greatest diameter does not exceed 20 mm.

The keratometer affords a particularly simple and reliable means of measuring the distance between the apices of the cornea and spectacle lens. To carry out this measurement it is best to unscrew the vulcanite ring. The observer should then so place himself that the center line of the instrument is at right angles to the patient's line of sight when he is looking straight ahead. For example, when setting an empty trial frame and measuring the distances between the edges of the spectacles and the apex of the cornea we should see the temporal and nasal edges of the spectacle frame as one. With the third and fourth fingers the observer should steady his left hand with which he holds the farther end of the tube upon the patient's temple. In the case of positive spectacles there is generally no difficulty in seeing the apex of the spectacle lens from the side, and then the distance between the apices of the cornea and the spectacle lens may be read off at once. In the case of weak positive glasses, and still more so in that of negative glasses, it is, of course, impossible to see the apex from the side. The difficulty may be overcome by the simple expedient of measuring the distance of the corneal apex from the plane of the frame edges facing the eye, and determining with an ordinary depth gauge the distance between the apex of the lens and the inside plane of the frame edge. The measurement of the vertical distance of the objects O_1 O_2 (shown diagrammatically in the first figure) will not fail to be correct, even though the objects are not in one plane and do not coincide with the scale, since, as was explained above, the rays which proceed from the object and scale are parallel.

At this point it is often advisable to examine the *sensibility of the cornea.* This procedure is best accomplished by gently touching the surface of the membrane with a wisp of cotton twisted to a fine point. If the sensation be normal, the touch should be instantly followed by the reflex act of winking (palpebral reflex), although even when the cornea is insensitive, closure of the lid may occur if the test-object comes in the field of the pupil. This is not due to contact, but represents the retinal lid-closure reflex. In organic anesthesia the

lachrymal reflex is wanting, but is present in hysteric anesthesia. The opposite eye should always be tested as a control.

Slight irregularities on the surface of the cornea are distinguished by the simple method of placing the patient before a window and while the eyes are made to follow the uplifted finger, held about one foot from the face, the image of the window bars reflected from the cornea will be broken as it crosses the spot of inequality. *Placido's disc,* which consists of alternate black and white circles having a hole in the center, may also be employed for detecting corneal inequalities. In using it the patient is placed with his back to the window and the observer looks through the small hole in the center of the disc, at the same time reflecting the disc image on the cornea. If the patient looks in various directions the whole surface of the cornea can be examined and any distortion or breaking of the circles, as reflected on the mirror-like surface of the cornea, will show an irregularity. See **Astigmometer,** Vol. I, p. 660, of this *Encyclopedia.*

Gertz (*Mitteil. aus der Augenklin. des Carolin. Inst. zu Stockholm,* No. 11, p. 1) has attempted to make Placido's disc more sensitive and to graduate it for quantitative examinations. He renders the distortion more evident by using oval discs instead of circles and by having the disc revolve. The discs are furnished with white elliptical bands instead of the circles, and attached to the end of a tube provided with a magnifying eye piece. A graduated arc allows the degree of rotation of the disc to be read off. The inventor states that it is possible to attain very accurate knowledge of the form of the cornea with this instrument, which is cheaper and more convenient than the ophthalmometer.

Minute abrasions and ulcers, if suspected of being present and yet not determined, may be found by dropping on the eye a concentrated alkaline solution of fluorescein (Gruebler's fluorescein, 2 per cent; carbonate of soda, 3.5 per cent), allowing it to be absorbed for several minutes and then thoroughly irrigating the cornea with a boric acid solution. If any portion of the cornea is deprived of its epithelium, or any part of the corneal epithelium is diseased, it will be found to have retained a yellowish-greenish stain, while the healthy epithelium remains unaffected. However, there is one exception in the epithelium in the immediate neighborhood of a corneal ulcer, which, although apparently not involved in the process, will also take the stain to some extent.

The most useful of all examinations of the cornea is that carried on under *oblique illumination.* By it we are not only able to ascertain to a certainty the condition of the surface, but by focusing our point of

light lower and lower we expose layer by layer all parts of the cornea as well as the anterior chamber, iris and lens. This procedure should be carried on in a darkened room with a very clear, bright, artificial point of illumination. The room should have dead black walls and should receive no illumination except that cast by the light used by the surgeon. The light which is now most popular is the electric lamp with a frosted globe; although the Argand gas burner only a few years ago was most generally used. The electric lamp is now made with a rheostat conveniently placed on the bracket so that the operator can easily control the intensity of light.

Hancock has devised a new electric globe which is quite an improvement over the usual type (see illustration).

In making *examinations with the aid of the electric bulb,* which is in general use, much annoyance is caused by the presence of the image of the carbon filament projected upon the part examined, as this interferes with determining exact details. To do away with this confusion Hancock has made the transparent window of the bulb lightly frosted. Through this light frosting sufficient light passes to enable one to make a perfectly satisfactory examination, with the image of the carbon entirely eliminated. A much more effective concentration of light may be obtained by covering all but the lightly frosted window of the bulb with some dark material, such as a bronze or black composition.

The Woolf condenser (see cut), owing to its unique construction, eliminates shadows and reflections of the lamp filament by means of a sliding focusing bar arrangement.

The condenser can be easily attached to any electric light socket or can be turned to one side without detaching when the non-frosted or filament part of the lamp is desired for direct illumination.

A patented shield is also provided which clamps on the reflector to eliminate side illumination.

The Phillips electric condenser makes use of the Tungsten globes and is mounted on a weighted base allowing complete condenser to stand alone. With the lamp furnished, which has special spot filament, the outside is arranged so as to give four different degrees of illumination by simply turning the lens holder to the desired place.

The bracket which carries the light should swing freely and allow the lamp to be quickly placed in any position. The "University Illuminating Fixture" (see cut) is designed to supply a light-carrying arm, which can be easily adjusted within a wide range and which will remain in any position without fastening.

It consists of a vertical rod, which is fastened to the wall by means



The Modified Electric Bulb of Hancock.

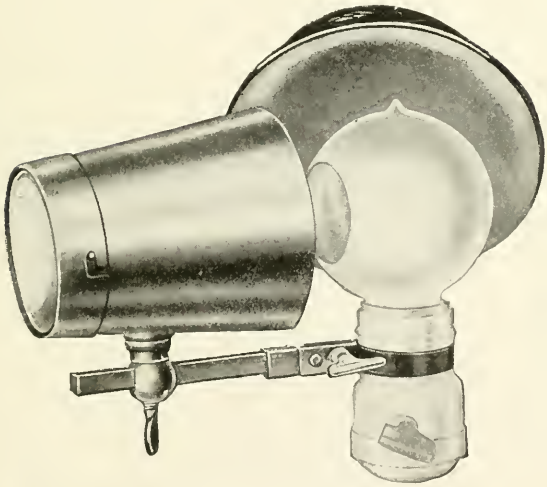

The Woolf Condenser.

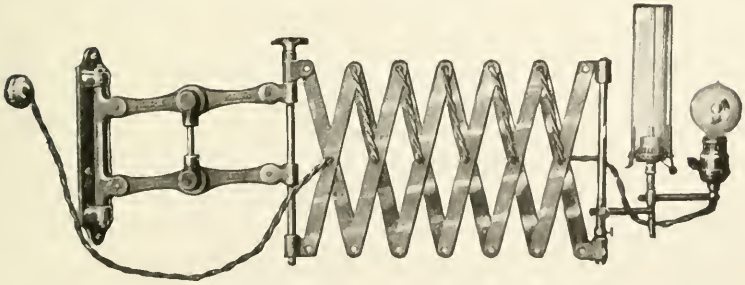

Adjustable Lamp Bracket with Both Gas and Electric Illumination.

of two offsets and a light-carrying arm which is connected to it by means of a special double slide carrier.

This double carrier consists of two short sections of square rod, each of which has been drilled longitudinally, and these are fastened to-



University Illuminating Fixture.

gether by means of a pin, which permits free movement, except that on one of these blocks, a stop, or pin, is mounted to limit this movement.

The vertical rod passes through one member of this double carrier device and the light-carrying arm through the other, permitting the device to be raised or lowered on the vertical arm, and the light-carrying arm to be moved in or out, remaining at any height within its range of movement securely without fastening.

To adjust the arm for height, it is only necessary to raise the light-carrying arm sufficiently to take the weight off the pin. When the proper height has been reached, it is merely necessary to allow the arm to drop back—it is maintained in position by its own weight.

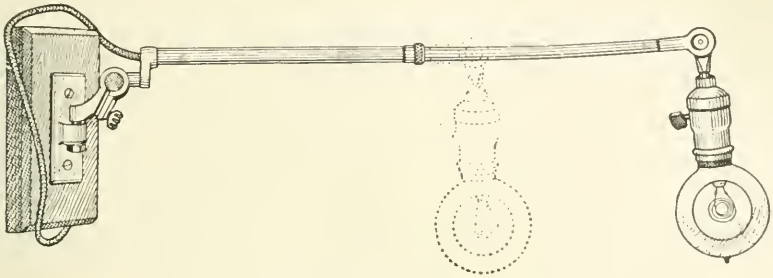

Woolf Telescoping Ophthalmic Lamp Bracket.

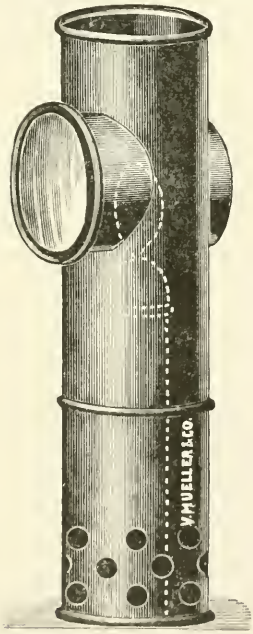

Priestley Smith's Condenser.
(For examination of the external parts of the eye.)

The Woolf telescoping lamp bracket (see illustration) is particularly adapted for eye work, where an adjustable but secure light is desired. It is 14 inches long, and can be extended to 24 inches.

By means of a double joint and thumb screw, it can be quickly fastened and securely tightened in any desired angle or position.

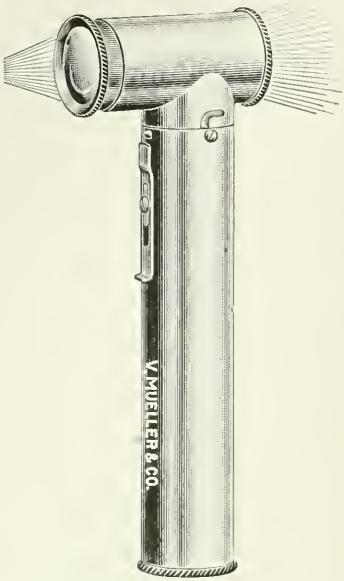

Fowler-Mueller Condenser.
(Much the same as Priestley Smith's instrument except it uses electricity instead of a candle.)



The Electric Hand Lamp for External Examination of the Eye as Used at "Moorfields."

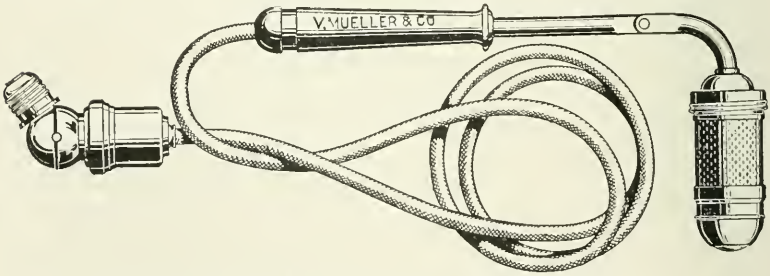

Portable Nernst Medico Lamp for Direct Illumination.
(It gives a very clear and steady white light.)

In hospital work or large clinics where it is impractical to take each patient to the dark room, *hand lamps* are used, being either held by the surgeon himself or his assistant. These hand lamps are fitted with condensers built in as a part of the instrument so that it is only necessary to use one lens when making an examination; the one lens being that one through which the eye is observed. One of the earliest designs of portable lamps with condenser is that of Priestley Smith (see cut). The source of illumination is an ordinary candle which is so

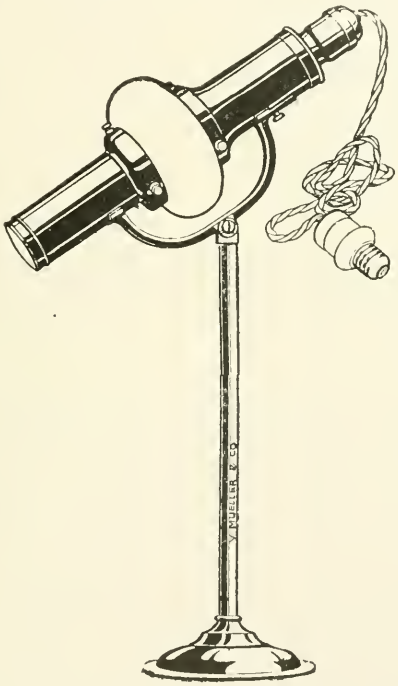

Nernst Lamp Equipped with Stationary Base.

held by a spring, that the flame is always in the proper position behind the lens. A more modern design of the Priestley Smith lamp is the electrically lighted Fowler-Mueller model (see cut). The Nernst lamp for the oblique illumination is now used and gives a very bright and clear illumination. The portable hand model is shown in cut.

A very compact and handy portable light is the "Ideal Fountain Light" (see illustration), which is made in the shape and style of an ordinary fountain pen. A Tungsten bulb is mounted in one end and the battery is in the handle. The light may be carried in the vest pocket the same as a fountain pen.

Jean Staehl (*Beiträge für Augenheilkunde*, December, 1912) states that he finds oblique illumination with the Nernst light yields much better results than with the ordinary light. Very minute lesions on the cornea and iris can be recognized by the aid of a binocular loupe with this light. Since using it he has observed that which had not previously attracted attention, an appearance of droplets on the posterior surface of the cornea associated with iritis; or, when iritis was not present, disappearing under the use of atropin. By this improved illumination he is also able to recognize the most minute iridodialysis, or other marks of injury to the iris, including lesions of the posterior layer, such as appear by transillumination. He has also seen minute defects of the corneal epithelium in cases of catarrhal conjunctivitis; and has found recognizable remains of persistent pupillary membrane in a much larger proportion of cases than had heretofore been recognized.

The Ideal Fountain Light.

By means of a strong convex lens of a two or three-inch focus, light is concentrated on the eye in such a manner that the apex of the cone of light corresponds to the part to be examined. The source of illumination should be about eighteen inches to the side of the patient, several inches in advance, and on a level with the eye. The lens is held by its margin between the thumb and index finger, so that its surfaces are at right angles to the direction from which the light proceeds, and steadied by means of the little finger placed against the side of the patient's face.

Powell has lately designed a new *adjustable condensing lens* which greatly facilitates this method of examination. The instrument (see cut), consists of a band to fit over the second or third finger of the left hand with an adjustable arm—made with double joints to permit of movements being made in any direction. To this arm is attached the lens—of 13 D. or 16 D. focus—so arranged that the light can easily be refracted into the eye, leaving the first finger and thumb free to hold the eyelids open, and the right hand perfectly free to work with.

After having examined one eye, without moving the supporting finger, we turn the patient's head slightly toward the light and illuminate the other eye. The light may be placed on either side; if on the patient's right, we use the left hand for holding the lens; if on the

left, use the right hand. To examine deeper than the surface of the cornea, the lens is brought nearer the eye, so that the apex of the cone of light corresponds to the deeper structures which one wishes to explore. At the same time he is manipulating the illuminating lens

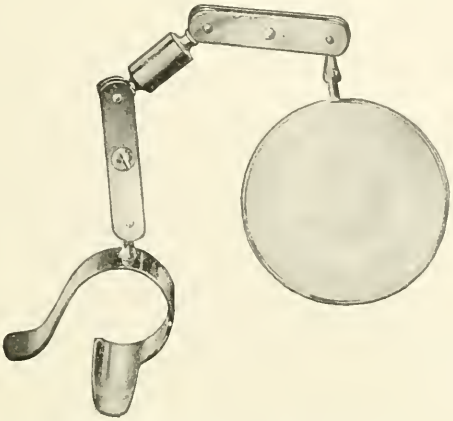

Powell's Adjustable Condensing Lens.

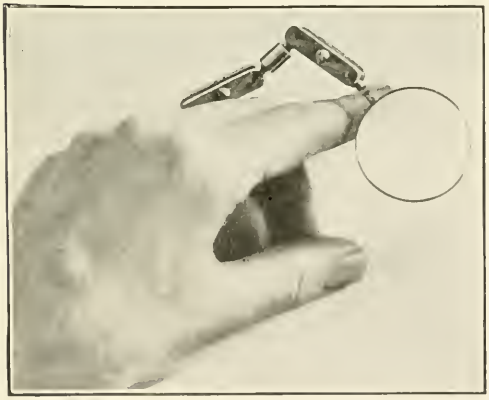

Method of Using Powell's Adjustable Condensing Lens.

with one hand the examiner is holding the seeing lens in the other. This lens should be of the same focal distance as the first and is held between the thumb and forefinger.

Several of the commoner types of condensing lenses are described and illustrated in Vol. IV, page 2771, of this *Encyclopedia*, under the heading **Condensing Lens.**

The *corneal loupe* is a lens, properly mounted, by which the cornea is strongly magnified, and which should be used with oblique illumination. These instruments were formerly made to be used by only one eye, but we now have many models of binocular magnifiers which are very efficient. The binocular apparatus possesses the great advantage of giving us our sense of perspective. The one designed by Berger, of Paris, is optically correct and very comfortable. It is made so that if desired it may be attached to an electric head light, as shown on p. 3304, Vol. V of this *Encyclopedia*.

Berger's Binocular Loupe Attached to Electric Head Light.

The Beebe binocular loupe consists of a strong straight temple open cell spectacle frame, to which are mounted cells for holding spheroprismatic lenses. Each of the cells carrying the lenses is attached to one end of a steel spring, the other end of the spring being attached to the inner edge of the spectacle eyewire. The cells are connected by a bar having a knurled thumb-piece in its center. The ends of the bar have a right and left hand thread and run through threaded tubes on the lower edges of the cells. By means of this bar thus threaded the lenses may be separated or approximated, as desired, for the purpose of producing binocular vision. The bar also holds the lenses in perfect alignment.

The cells are mounted at an angle so that the line of vision is at right angles to the plane of the lenses, which are + 7.50 ⊂ 5° prisms, base in.

Among the advantages claimed by this instrument are the following: Great magnifying power with a large and perfectly flat field



Zeiss Binocular Magnifiers.

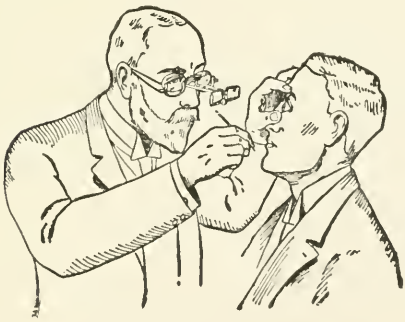

Beebe Binocular Loupe.

—there being no distortion. Absolute and comfortable binocular vision. Great working distance between lenses and object viewed. No obstruction to the view of surrounding objects. May be used in connection with a reflecting mirror or other illuminating apparatus. May be worn over spectacles or eyeglasses; or correcting lenses may be inserted in the open cells of the instrument.

The sphero-prisms are adjustable horizontally for the purpose of

obtaining comfortable binocular vision—regardless of accommodation or convergence.

The Zeiss binocular telescopic magnifier is also shown and is a thoroughly satisfactory instrument. It is a combination of simple magnifiers with a prism telescope. Such a combination furnishes magnifying powers ranging from 2 to 30 diameters, whilst the instrument can be held a very considerable distance away from the object. This is a quality which greatly enhances its utility in the hands of medical men

Zeiss Electrically Lighted Binocular Telescopic Magnifier Attached to Head Band.

and, in fact, all observers to whom a long working distance is an important consideration.

For the finer and more thorough examination of the cornea some means of higher magnification must be employed. The most perfect method is the use of a regular corneal microscope. Czapski's binocular instrument is one of the latest and most complete. See Vol. V, p. 3390, of this *Encyclopedia.* The binocular vision in it is obtained not by a division of light passing through a single objective, but by a combination of two microscopes, each complete in itself. Each of the component microscopes consists of objective and eye-piece in combination with a Porro prism.

The use of the Porro prism permits of a much shorter tube length and secures a larger field than would be possible otherwise, except by a much more bulky and inconvenient design.

Pupillary distances between 56-76 mm. (2¼ to 3 inches) may be

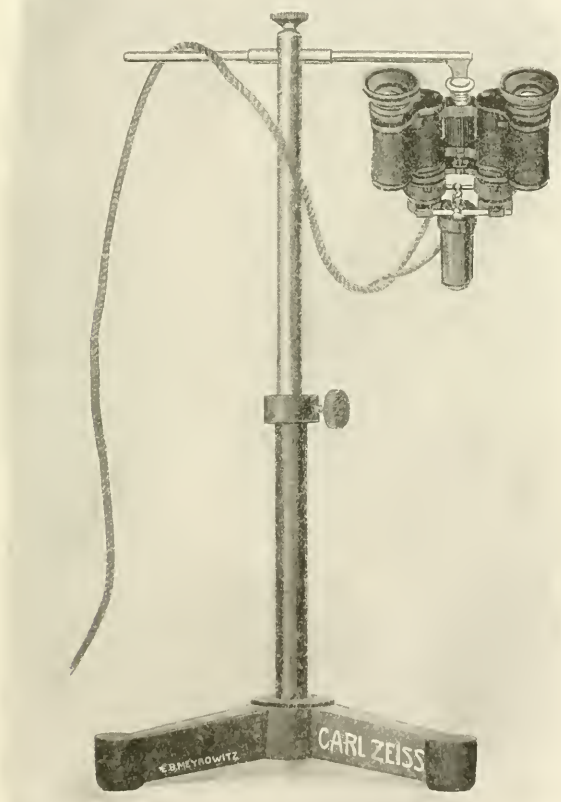

Largest Size Zeiss Electrically Lighted Telescopic Magnifier.

obtained by means of the eccentric movement imparted to the eye-pieces by rotating the casings of the Porro prisms to which they are attached.

The pairs of objectives are mounted on slides and the mounting of one of the lenses is provided with a screw thread to facilitate the

securing of an equally sharp focus with both lenses where inequalities in the power of vision of two eyes require compensation.

The double tube with its illuminator is carried on an upright column, and by means of a double joint may be rotated vertically or horizontally and clamped in any position. A rack and pinion movement serves to raise or lower the instrument and a second similar movement is provided for focusing. The instrument rests on a substantial metal tripod.

The lighting attachment, which is independently adjustable, consists of a small 6-volt lamp mounted in a tube with a reflector.

The base and head-rest are provided with a movable bed-plate on which the tripod of the microscope rests. This plate, and with it the stand, is moved forward and backward directly by hand and from side to side by a milled head, which operates a rack and pinion movement.

H. S. Gradle has devised an *attachable corneal microscope to be used on an ophthalmometer.* See Vol. V, p. 3389, of this *Encyclopedia.*

An ophthalmometer consists of an ocular, and objective and an intervening birefringent prism. By removing the prisms we have left a tube containing an ocular and an objective—in other words, a microscope. To accomplish this the truncated corneal tube of a Hardy ophthalmometer was removed from the anterior part of the ophthalmometer and there was substituted another similar tube, but containing only the objective lens. This gives a microscope with a magnifying power of from six to eight diameters. The illumination is accomplished by the addition of an arc to the anterior end of the microscope tube. This arc bears a simple eight candle power electric globe. The rays are condensed upon the eye by a focusing lens in the end of the light tube.

A very complete and elegant corneal microscope is the instrument of Zeiss. It is of the binocular type and has a very neat and practical head-rest for the patient.

Among the types of simpler corneal microscopes is Koller's corneal loupe (see Vol. V, page 3387, of this *Encyclopedia*). The advantage of combining condenser and magnifying glass in proper relative positions is obvious, for whatever object is then brought into the focus of the magnifying glass it receives its proper illumination from the condenser. In this instrument a 1-inch lens has been used, at one side of which a parabolic reflector is attached, so that its axis passes through the focus of the lens, intersecting the optical axis at an angle of 80 degrees—a small incandescent lamp in the focus of the paraboloid acts as source of light. The illumination is to come from the temporal

side, and, therefore, is made reversible for use on either eye. The enlargement obtained is 12-14, compared with ordinary reading distance; the field of vision is very large; the handling of the instrument perfectly simple.

Luedde (*Arch. of Ophth.*, XL, p. 373) thinks the corneal microscope would be more useful if better illumination were provided. To effect this he has used a 6-volt Tungsten lamp, attached by a ball-and-socket joint to an extensile arm. With this it becomes possible to use the higher powers of the instrument, 36 to 65 diameters, with advantage. He also finds the adjustment much assisted by placing it on plate glass, where it can slide freely in any direction. These improvements make it practical to study clinically the circulation in the conjunctiva and limbus. Magnified 65 diameters the blood-corpuscles have a perceptible disk, and their movements in the smallest vessels, with irregularities of caliber, become significant of changes in blood-pressure, and early arterio-sclerosis.

To secure oblique illumination of the cornea Emanuel (*Klin. Mon. f. Augenh.*, September, 1912, p. 359) has resorted to a concave mirror 50 mm. in diameter and 80 mm. focal distance attached to a head-band by a universal joint, which allows its adjustment to focus the light on the point desired, leaving both the surgeon's hands free.

The *anterior chamber* should be examined as to its depth, the clearness of its contents, and the possible presence of a foreign body or an exudation. The depth is observed by noting the relationship of the iris to the posterior surface of the cornea. If the chamber be shallow and the iris is bulging forward, this fact is often best seen by looking at the eye-ball from the side. Normally the anterior chamber is shallower in infants and in the aged than in middle life.

An instrument for accurately measuring the depth of the anterior chamber has been described by Hegg (*Arch. of Ophth.*, September, 1907, p. 710). It compares the position of the edge of the pupil with that of a virtual image formed by reflection from the cornea, the position of the latter being known by measuring the corneal radius of curvature.

In a healthy state the aqueous humor is absolutely transparent and therefore not seen at all. In disease, however, it may be mixed with pus, blood or lymph, when it becomes opaque. Fluids in the anterior chamber gravitate according to the position of the patient.

After completing a thorough inspection of the cornea and anterior chamber, the surgeon should begin his *examination of the iris*. The color of irides is found to vary greatly. Blue and gray are the predominating hues in northern countries; brown is found next in fre-

quency; while the various mixtures produce yellow and green shades. Absolutely black irides are never encountered; but dark irides, taking into account the whole population of the world, are of the most frequent occurrence. The color of the iris of all new-born children is a light grayish-blue (de Schweinitz). It is only as the pigment later becomes formed and deposited, that the iris assumes its permanent color. The location and amount of pigment decides the shade of the iris. If the pigment is deposited more freely in the posterior layer than in the stroma, the blue iris is evident. If, however, the stroma receives the major amount of pigment the iris is brown or dark-brown. Piebald irides are often seen and are due to an irregular deposit of pigment, sometimes appearing as one triangular patch or several irregular spots of dark color. This condition is sometimes temporary. Some of the very small, dark segments in piebald irides much resemble foreign bodies and have even been diagnosed as such by competent surgeons.

Discoloration is an important indication in disease of the iris and should always be carefully looked for. If one iris presents a more greenish hue than its fellow, it may be taken as a sign of beginning iritis or cyclitis. It is to be remembered, however, that in health we occasionally find two irides in the same individual, of an entirely different color. If tremulousness of the iris can be elicited by having the patient move the eye rapidly about, it indicates a lack of support and is found when the zonula is relaxed or the lens absent, dislocated or shrunken.

The pupil next commands attention and in it is found a part of the eye the examination of which is most important. The size is first noted and this varies greatly even in health. Exposure to light or darkness causes variations in its size as well as the performance of the acts of accommodation and convergence. Also its width depends on the quantity of blood in the vessels of the iris, the elasticity of the iris-tissue, and certain mechanical conditions. According to Schwarz, the normal pupil may undergo fluctuations in diameter amounting to 0.3 mm., even when the chief factors are practically constant. In general, the pupil is smaller in eyes with a hyperopic refraction, in old age and in the new-born; while in myopic eyes and in the eyes of youth they are found larger. Men usually have narrower pupils than women. In absolutely normal eyes, with the accommodation at rest, the pupil varies in daylight from 2.44 to 5.82 mm., the average diameter being 4.14 mm. (Woinow). The position of the pupil is a little to the nasal side of the center of the cornea.

The pupils of both eyes in health should be the same size when exposed to the same degree of illumination. In very rare instances this

is not true, for slight inequality has been seen in healthy persons, and may be a congenital condition.

In addition to the factors already mentioned which influence the size of the pupil, the adaptation of the retina to light must be taken into account, as Schirmer has shown. The pupil is allowed to "adapt" for three minutes, as the eye is exposed to clear daylight coming through a large window one metre distant. Under such conditions a difference in width of 0.25 mm. has been determined. For the physiological size of the pupil thus obtained Schwarz prefers the term "adapted width of the pupil." With the patient in the above position, and after waiting the three minutes, the exact measurement may be fairly well made by holding a ruler before the eye and noting the number of millimeter spaces the pupil occupies. The chief objection to this method is that the distance subtended on the rule is less than the diameter of the pupil, in proportion as the distance from the observer's eye is less to the rule than to the pupil (Jackson).

Many instruments known as *pupilometers* have been invented for accurate measurement of the pupil's size. The simplest design is made of a small, round sheet of black metal, with holes of different sizes punched in it. The instrument is held close to the eye and rotated until the hole is found which matches the pupil in size. Priestley Smith's keratometer (which is described later in this section, under perimetry) may be also used for this purpose. Haab has constructed a practical pupilometer, which consists of a number of black discs, varying from 1.5 to 8 mm. in diameter, arranged in a perpendicular row, with which the pupil is compared.

Maddox (*Ophthalmoscope*, June, 1907) has suggested a simple instrument for comparing the diameter of the two pupils which can also be used for measuring the distance between them. This consists essentially of two mirrors parallel to each other, and perpendicular to the surface of a slide rule, to which they are fastened; but crossing the rule at an angle of 45 degrees, as shown in the figure. In using this instrument it is held in front of the eyes, as shown, A, representing the right; B, the left eye of the patient, and C, the observing eye of the surgeon. A, has the lower half of its iris reflected from the first mirror at m, and again reflected from n, where the surgeon sees it in close apposition with the upper half of the left eye B. The slide is pushed out or in until the two halves exactly correspond. In this position the size of the two pupils may be accurately compared; while the distance between the mirrors, read from the scale, is equal to the distance between the two pupils. For accuracy the scale must be held parallel to the plane of the pupils. This is insured by a mark

on each mirror, seen at n; the rule being in the proper position when the two marks appear superimposed.

This instrument of Maddox gives dependable results irrespective of the distance it is held in front of the patient's face.

Le Plat (*Ann. d'Oculist.*, September, p. 201) has devised an instrument, somewhat similar, with an arm intended to keep the surgeon's face at a fixed distance from that of the patient, and thus

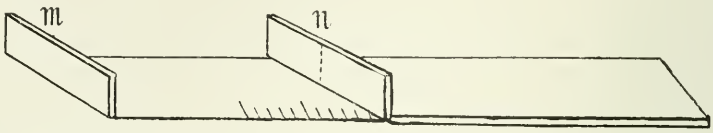

Maddox's Instrument for Measuring the Intraocular Distance and Comparing the Two Pupils.

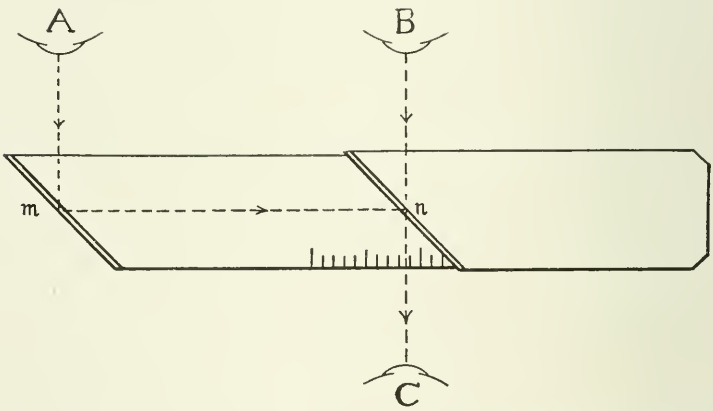

Maddox's Instrument for Measuring the Intraocular Distance and Comparing the Two Pupils.

(A and B represent eyes of the patient and C the eye of the observer. The broken lines indicate the path of the rays coming from A, reflected at m and n, and coming from B direct to C.)

secure accuracy. It has scales indicating the distance between the pupils when the visual axes are parallel, and also when they are converged to a distance of one-third of a meter.

To measure the diameter of the pupil Contino (*Ophth. Year-Book*, Vol. IX, p. 23) uses a horizontal microscope, placed in a plane parallel with the patient's face. To avoid shadows on the eye, the image of the pupil is reflected into the microscope by an ordinary cover glass, inclined at 45 degrees, or a reflecting prism. The measurements are accurate to a tenth of a millimeter. A mathematical demonstration

of the relation between the real and apparent size of the pupil shows it to be 1 to 1.117, when the radius of corneal curvature is 7.8 mm.

A simple clinical method of measuring the diameter of the pupil (first employed by A. Fick) has been described by T. A. Williams (*Med. Record*, December 24, 1910) and depends upon the principle that a small aperture in a card placed a short distance from the eye appears as a circle, the diameter of which equals that of the pupil. If two holes are used it is evident that if the circumferences of the two circles appear exactly to touch, the distance between the apparent centers will equal the diameter of either, as it consists of half the diameter of each. That is to say, it will equal the diameter of the pupil. Now, it is found experimentally that when the two holes are separated by a distance equal to the diameter of the pupil, the apparent images just touch. So that it is very easy to measure the pupil by placing before the eye a series of holes at varying distances from one another.

Accordingly a scale is constructed consisting of perforations in a card placed apart respectively one, two, three, four, five, six, seven and eight millimeters. The diameter of the patient's pupil is then easily ascertained by the distance between the two holes of which the apparent images most nearly touch when he looks through them at a distant object.

A very clever pupilometer has been invented by De Surel (*Rev. Gen. d'Ophth.*, July, 1905) which he calls the "correscope." See Vol. V, p. 3539, of this *Encyclopedia*. The instrument consists essentially of two diverging threads, so placed in a frame as to allow them to be held in front of the eye. When the instrument is in position it is moved up or down, until these threads are just tangent to the two sides of the pupil. The point on the scale opposite to the centre of the pupil gives the pupil diameter.

A binocular pupilometer has been described by Ohm (*Centrabl. f. prakt.*, May, 1907). In it the image of a light line is superimposed upon the image of each pupil; and the images of the two pupils are brought together by a series of reflecting prisms. The length of the light line is accurately adjusted to the diameter of the pupil by a lever, which, passing over a scale, indicates the pupil diameter with great exactness.

Bordier and Nogier (*Rev. Gen. d'Opht.*, December, 1907) have devised an instrument for measuring the diameter of the pupil subjectively, by the contact of diffusion images furnished by two parallel polished needles reflecting a bright source of light.

The observance of the *mobility of the iris* under different stimuli,

usually called pupil-reflexes or pupil-reactions, should be carefully noted. Ball has very clearly classified the normal pupillary-reflexes. He says that the contraction reflexes are: (1) the direct light reflex; (2) the consensual light reflex; (3) the convergence reflex; (4) the cerebral cortex reflex, and (5) the lid-closure reflex. The dilatation reflexes are: (1) the direct "shade" reflex; (2) the consensual "shade" reflex; (3) the relaxed accommodation reflex; (4) the sensory reflex, and (5) the psychic reflex. Ball has also described very clearly the methods for eliciting each of the above reflexes.

Direct light reflex.—The patient is placed in front of a window facing the light. He is told to look at a distance. The examiner covers both eyes for a moment; on uncovering, the pupils should be found larger, but should immediately contract. Again both eyes are covered, and after a moment the right is uncovered, and the pupil contracts.

Consensual light reflex.—The procedure just described is carried out and after uncovering the right eye, the left is also uncovered. It is found that the right pupil becomes still smaller than it was before, while the left pupil is also contracting.

Convergence reflex.—The patient is told to focus on a distant object. A pencil is held six inches from his nose, and he is told to look at it quickly; the pupils contract. (This test is often called the "accommodation and convergence reaction," but it is more closely connected with convergence than with accommodation.

Cerebral cortex reflex.—This reaction was first described by Haab, who speaks of it as follows:

"If in a room illuminated only by a lamp or candle flame, the light is placed so that it will shine laterally into a person's eyes while he looks directly forward into the darkness, a marked contraction of both pupils takes place whenever the attention is directed toward the light, with no change in the position of the eyes. As long as the attention is directed to the light and fixation of the eyes on the dark wall is maintained the pupils remain contracted, but as soon as the attention is transferred to the point of fixation they dilate, although the quantity of light entering the eye has remained constant and all movements of accommodation and convergence are excluded."

The lid-closure reflex (palpebral reflex of the pupil; Gifford's reflex; Galassi's reflex; Westphal-Piltz reaction) was discovered by von Graefe. When the lids are forcibly closed, the pupil contracts. Gifford inserts a speculum and tells the patient to close his eyelids. The pupil then contracts. This test is used to tell whether the sphincter of the iris is paralyzed.

The reflexes described above are all *contraction reflexes.*

The dilation reflexes are, most of them, produced under reduced illumination.

Direct shade reflex.—The eye is simply protected from the light and the pupil dilates.

Consensual shade reflex.—One eye is covered, protecting it from the light, and the pupil of the other eye dilates.

Relaxed accommodation reflex.—The patient is made to look at some object held very close to the nose (about six inches) and then to focus on a far object. As the accommodation is relaxed the pupils dilate.

The sensory reflex (skin reflex, or pain reaction).—When any sensory nerve is stimulated—by tickling or by pinching the skin—both pupils dilate.

The psychic reflex.—This is seen in certain mental states, such as terror or anger.

An iris-inaction has been described by Wernicke which is of great value in localizing the lesion causing hemianopsia. The test is ordinarily made in the following manner:

The patient is seated in a dark room with the source of light from behind him. The examiner then reflects a weak light from a plane mirror onto the eye under examination. At the same time with the other hand he reflects a strong ray of light from a concave mirror, into the pupil, from various directions; care being taken that the light falls obliquely and is not diffused over the entire cornea. If when the beam of light is thrown on either the blind or seeing side of the cornea, a contraction of the pupil is observed, the conclusion is that the lesion is back of the primary optic centers. But if the ray of light causes no contraction when thrown on the blind side, but does cause contraction when thrown on the seeing side, the lesion is in front of the primary optic centers.

While the above method of observing this phenomenon is probably the one most widely used, other procedures have been suggested.

Ahlström and others use an electric light encapsulated except for a 0.25 mm. diameter opening which gives a narrow cone of light to be thrown into the eye. Friedlander and Kempner use a lens system to focus the rays at 4 cm. distance from the opening. Similar instruments have appeared in this country.

Wolff used his electric ophthalmoscope to flash with corrective lenses a sharp image of a section of filament onto a definite part of the retina, at the same time observing the pupillary reaction. Heddaeus made an ingenious but apparently not very popular departure in using two lights of equal intensity exposed alternately without interval at equal distances from the fixation-point and from the eye.

Hess introduced the methods of hemikinetic illumination of the retina and of concentric illumination about the macula, both of which render the dispersion light reaching the macula as nearly constant as possible.

Sachs, unaware of Hess' work, at the same time was using a modification of the same principle. The patient observed the center of a large bright reflecting white mat surface. One half, then the other half, was quickly covered by a black curtain while the pupillary reaction was noted.

The Wilbrand method, described by A. Saenger (*Ophthalmic Record,* August, 1910) is best carried out as follows: The patient is requested to fix a white point on a large black surface and direct his attention to it. In this way all other impressions on the retina are excluded. The patient takes his seat at a distance of 30 to 50 cm., immediately in front of the white point. Suddenly two prisms of equal degree are brought before both eyes, the apices being turned towards the hemianopic defect. In this manner the white point is directed toward that side of the retina which is not perceptive. The bases of the prisms must be parallel.

If a cortical hemianopia exists the patient will quickly change the direction of sight and move the eyes until the fovea is directed to the object. This proves that there exists a reflex independent of the cerebrum, and on the opposite side, that the optical route between the retina and corpus geniculatum laterale is free. If the disease is situated in the tractus opticus the eyes make no movement to fix the object, but remain quiet.

The latest and most complete method proposed is that accomplished by aid of the apparatus described by Walker. (*Jour. Am. Med. Ass'n,* Sept. 5, 1914.)

A diagram of the necessary light control is shown in figure 1. The lights, AA′, are new 60-watt tungsten filament lamps selected from a large stock as nearly equal in all measurements as possible. From the wiring scheme it will be seen that they are connected in parallel. One side of each is directly connected to one side of the house current (110 volts). The other side of each lamp is likewise connected to the other side of the house current but must first travel through a set of resistances. The whole current first passes through a rheostat, B, whereby it may be varied in five steps from nothing to full strength. From the rheostat, the current then passes to the fixed bar of the sliding contact, E. This sliding contact, together with similar contacts D and F, may be moved laterally in contact with the edge of a slate slab C measuring 1 by 12 by 8 inches and wrapped with No. 26 B & S

gage (0.016 inch diameter) German silver wire, the interval between the turns of the coil being about 0.2 cm. This size of wire was found by experiment to have the necessary resistance to regulate the individual lamps, and still would not burn out under the contacts, with ordinary care. From the contact the current divides, passing through a variable amount of resistance to contacts D and F, and thence through their individual fixed bars, and on to their respective lamps. If now we wish to decrease the intensity of the light A, we have simply to move the contact D farther out or to decrease A′ move the contact F farther out. If now with either of these contacts at any distance we

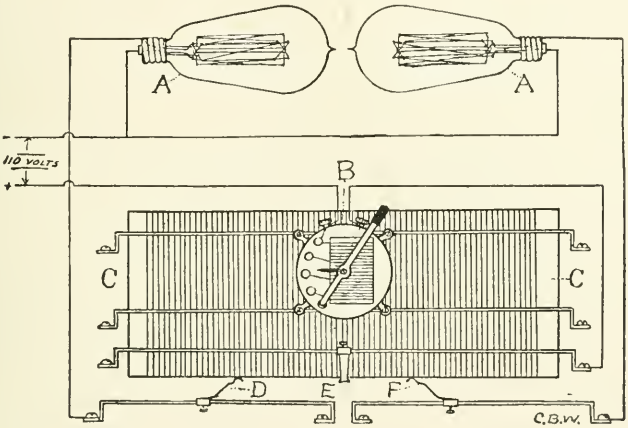

Hemiopic Pupillary Apparatus of Walker.

Fig. 1.—Diagram showing method of controlling lighting current in hemiopic pupillary apparatus; AA′, 60-watt tungsten lamps; B, rheostat controlling house current; C, slate slab wound with German silver wire; D, E, F, sliding contacts controlling current supplied to each lamp.

wish to produce further change in the relative light intensity, we may simply move the contact E between the two contacts D and F until the desired point is reached without adding extra resistance but merely readjusting that already in use. Thus, if necessary, we can throw the whole or any part of the resistance on the slab C into the circuit of either light or divide it between them in any ratio. For purposes of measurement, the slab resistance is divided into ten divisions (points) each way from the center.

These two lights are encased end to end in the diameter of a heavy tin drum of about the size of an ordinary snare drum (14 inches diameter by 6 inches depth). Access to the interior is allowed by two doors in back. The inner surface of the drum is enameled white, and

has two movable partition wings of the same curvature as the circumference so that when not in use they can be made to lie flat against the curvature of the drum. When it is desired to prevent one light from contributing more or less to the other, these wings may be turned inward to a corresponding degree or may be moved until they touch the axle for maximum effect. This axle in the center of the drum is

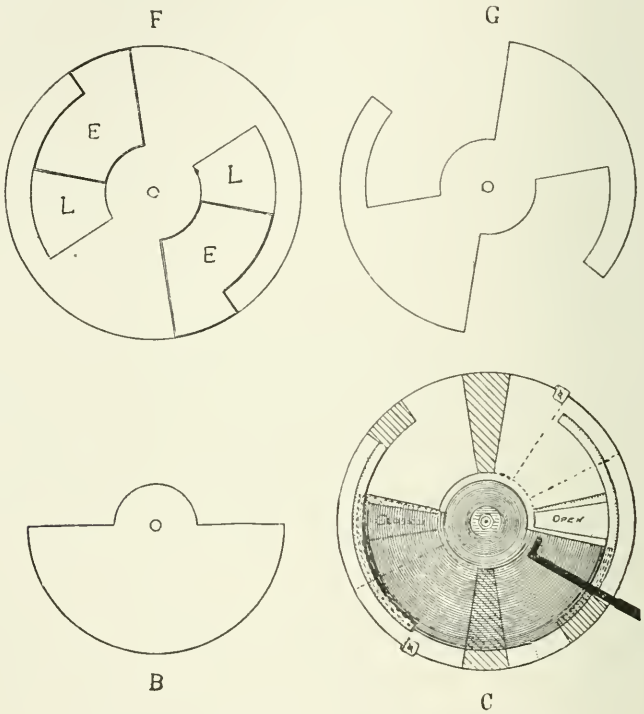

Hemiopic Pupillary Apparatus of Walker.

Fig. 2.—Plan of rotary shutter, assembled in C from segments F, G, and B, in the position where the equal areas L and L′ are cut down to about one-half full size.

hollow and acts as a hub posteriorly to receive the fixed axle on which the whole drum may be revolved, but anteriorly it has two large holes bored in it to transmit light to the fixation point, and still farther forward acts as an axle for the movable segments of the rotary shutter, which makes up the front of the drum.

The rotary shutter segments (fig. 2) were cut of heavy tin, although a similar weight in sheet brass would probably have worked up with less tendency to warp. The first disk, F, has two equal openings L and

L′, the shape being such as to give the maximum area for the minimum movement of the shutter. The inner margin of each area is on an arc of 1 inch radius from the center and the outer margin on an arc of 5½ inches from the center, at maximum opening an arc of 45 being subtended. On the quadrants, E and E′ is placed another segment of size and shape to fit the interval left by the next superimposed segment G. Thus a smooth surface is provided for the shutter to move on below, and above the proper level is obtained on which to solder an overhang under which the shutter may pass and give a light-



Hemiopic Pupillary Apparatus of Walker.

Fig. 3.—Patient in position.

tight closing. The back of this disk carries two plates of milk-glass covering the openings. The anterior end of the hollow axle also has a milk-glass window on which is marked a letter A and a dot, serving as a fixation point.

The next superimposed segment, G, serves mainly the purpose of symmetrically regulating the size of the lighted areas, but at the same time it carries two circular arms extending along the outer margins of the lighted areas, forming a smooth course on which the edge of the shutter may travel under cover of another overhang providing a light-tight margin. This disk is not fixed to the drum as the first one is, but is free to rotate when the clamps holding it to the first disk are loosened. The shutter is a semi-circular disk, B, actuated by a jointed hand lever, as is shown in the assembled shutter C drawn in the position where the lighted areas L and L′ have been cut down to about one-half their full size.

To eliminate any asymmetry that may be due to reflection from the

patient's face, a wide, short cone, truncated to fit the patient's eye, is provided on an adjustable support, so that the distance from the fixation point can be varied within any desirable limits, from 10 to 20 inches usually giving satisfactory illumination. A patient in position before the instrument is shown in figure 3.

Before making any tests, in order to avoid as much as possible any psychic or accommodative changes or any tendency to loss of fixation, the patient is familiarized with the movements of the shutter, until the shifting of light areas ceases to be of interest. The room is then darkened to exclude all asymmetrical light, and with the shutter at mid-position or entirely open on the blind side, so that light adaptation may be kept equal, or as low as possible before the test is made, the patient is placed in position before the instrument with one eye covered, and the light is gradually increased until the movements of the iris can be accurately followed. This light strength varies slightly, depending on the color of the iris; it is greater for the darker irises. The patient is now told to sit back and close the eyes before proceeding with the observations, in order to increase the dark adaptation, which has a tendency to increase the difference in reaction, and to avoid fixation fatigue. Previously, of course, the lights have been photometrically balanced by means of the sliding contacts and further adjusted to the normal eye so that the pupillary reaction is the same from both lights.

Observation of direct pupillary reactions may be made with the unaided eye, or a short-focus telescope may be used. A very simple aid is made by rolling up a tube of stiff paper which will hold a magnifying glass in one and fit snugly about the observer's eye at the other end, thus at once cutting out shifting and somewhat confusing illumination on the observer's eye, and enlarging the pupillary movements. This tube may be held in the mid position to avoid asymmetrical reflections. Observation of the consensual pupillary reaction may be effected directly if all light from the instrument is screened off and limited to the eye under examination, by a heavy black conical curtain. Light is then admitted to the room until the movements of the consensual pupil can be followed, but without the use of the curtain the consensual pupillary reaction can also be observed objectively with the monocular pupillometer or subjectively with the entopic pupillometer previously described.

The rate of movement of the shutter has considerable effect on the resulting pupillary reaction. This holds true for the normal eye as well as for the hemianoptic eye. In general, on the normal eye if this change is made slowly from one light to the other no reaction may be

noted if the accommodative and psychic reactions are not active. These latter reactions are very noticeable the first time a young person sits down to the instrument and simply fixes attention on the central point. If now the pupil is carefully observed with no change in light distribution one often notices in the course of the first minute or so decided variations in the size of the pupil. A noise or a spoken word may cause a distraction of attention or relaxation of accommodation with corresponding exaggeration of the normal hippus that may be noted for a time in absolute silence. These changes become reduced to a minimum as the patient becomes more and more at ease. In older persons whose accommodative reflexes are no longer active these reactions are much less noticeable if present at all. If a distant fixation point were observed through the hollow axle the condition would doubtless be better if it were not for the liability of the test-lights near at hand to stimulate accommodative reactions as they flash into view.

When these reactions are quiescent there may be no pupillary reaction if the lights are slowly changed, but if the change is suddenly made, we notice a quick pupillary contraction followed by a somewhat slower dilatation to the former size. This may be repeated on the return change if the interval is two or three seconds or more. As the interval is decreased to the neighborhood of one second or less the pupillary contraction and dilatation becomes less until the interval is of such length that the pupillary reaction apparently does not have time to take place, either on account of the time required for transit of the reflex arc or for light adaptation phenomena. While it might be due to a combination of the two the interval is such as to favor light adaptation as an explanation. Symmetry of distribution on both sides of the macula is not necessary. The same thing happens if the lights are turned into the vertical position and a point a short distance out on the horizontal line through the center is taken as an eccentric fixation point. These reactions obtained on the normal eye are the same from either light when the instrument has been adjusted. This same reaction may be elicited when the two lights are placed in the seeing field of a hemianoptic eye. But in any case, if the eye is allowed to fix a very short distance—a centimeter or less toward either light, for instance—so that asymmetry enters, a difference in pupillary reaction is noticeable.

In examining hemianopic cases the most satisfactory interval of alternation seems to be that which gives the maximum noticeable pupillary movement and seems to be about the same interval (2 or 3 seconds) as that at which the pupillary bounce is most active in the

normal eye. The rate of change from one light to another is made as rapidly as possible for the same reason. In some cases in which the hemiopic pupillary reaction is marked, however, it is difficult to mask it with any kind of a shutter movement. Again, when the reaction is not marked, blinding the macula may be resorted to as a means of intercepting the reaction. A piece of heavy black paper having a circular hole an inch or two in diameter is held over one of the light areas and the patient told to look steadily at the center of this spot of light until looking at the center of the instrument fixation can still be maintained in spite of the blinding.

In order to get an idea of the magnitude of a hemiopic pupillary reaction, aside from measuring the pupillary sizes, two methods were used which gave relative results: first, the amount of resistance necessary to cut one light down to the point at which the reaction was the same from one dim light and one bright light. With the second method, the size of the areas was cut down until the consensual reaction could not be made out with the pupillometer on the other eye with any degree of certainty.

In addition to the use of the shutter with the lights in fixed position one light may be exposed and the whole drum rotated so that the light may pass back and forth from blind to seeing field at constant distance from the point of fixation performing concentric rotation tests, as was mentioned previously. Concentric rotation of one light entirely in the seeing field, however, may give a psychic as well as light adaptation contraction of the pupil; so that this movement must be repeated several times with patients in order to reduce the psychic element as much as possible by thorough familiarization with the procedure.

Krusius (*Arch. f. Augenh.*, April, 1907), has devised a little instrument especially suited to testing the ordinary reactions of the pupil. It consists of a box that is fastened to the head, with the patient's eye at one aperture, in a second aperture a small electric lamp, and a third opening permits the surgeon to watch the reactions of the pupil. A monocular form is particularly fitted for testing the consensual reactions. He has also suggested a binocular pupillometer, useful in testing all the reactions of the pupil.

See also **Bach's pupil-reflex tests** in Vol. II, Page 730, of this *Encyclopedia*.

The pupillary area, which is next examined after completing the investigations of the pupillary reactions, should be first scrutinized by oblique illumination. Search is made for posterior synechia or any evidences on the anterior capsule of that condition having pre-

viously existed. The latter would be shown by pigment-spots or points of exudation on the capsule.

Proceeding deeper the surgeon examines *the lens substance* itself by oblique illumination. In order to do this satisfactorily it is necessary to have the pupil well dilated. One or two drops of a 4 per cent. solution of cocaine instilled into the eye, is a very satisfactory mydriatic for this purpose, as its action is only for a short time. Opacities or foreign bodies are looked for. Opacities when seen by oblique illumination appear grayish on a black background. When later we observe them with the ophthalmoscope they take on a much different appearance, being black on the red fundus reflex. Foreign bodies are often seen, but usually they soon set up a rapid swelling of lens substance which obscures them. Occasionally, however, a small body may lodge in the lens substance and remain there for years without giving rise to any trouble.

The examination of the lens is also performed by the surgeon with the aid of the ophthalmoscope. This will be referred to later when a description of the use of the ophthalmoscope is given.

If the lens is quite clear, some of the anterior part of the vitreous may be seen by the oblique method but the real practical and valuable observations of the vitreous body must be done with the aid of the ophthalmoscope.

The intra-ocular tension is of great importance and should be determined in every eye examined. As a rule it is increased in glaucoma, intra-ocular tumors and sometimes in iritis. It is decreased, as a rule, in detachment of the retina, perforation of the globe, liquefaction of the vitreous humor, and in pseudo-neuroepithelioma.

When observing the tension of an eye the usual method followed is that simple procedure of palpating with the index fingers, much in the same manner as one detects fluctuation in any part of the body. This method is quite satisfactory in most cases, and the trained observer, after long experience, is able to detect the slightest alteration from normal; whether it is an increased or decreased tension. Although there are several instruments which are now in quite general use for calculating the exact intra-ocular pressure, still all oculists should be able to make intelligent and fairly accurate observations by the old procedure. The patient should always be seated, for if standing the swaying of the body is very apt to confuse the observer and cause erroneous impressions to be transmitted to his finger tips. The physician stands immediately in front of the patient and directs him to look down or, as is found more advantageous in some cases, he is told to "look at his feet." The tips of both index fingers are then placed

on the lowered eyelid and the middle and ring fingers are allowed to rest lightly on the brow; now by alternately directing pressure downward onto the eyeball by first one finger and then the other, the exact condition is determined. It should always be remembered to exert the pressure downward and not backward, for a backward pressure would to some extent only press the globe into the orbit and the results arrived at would be incorrect.

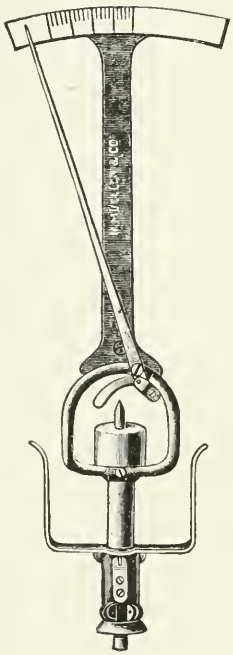

Schiötz Tonometer.

Some prefer to have the patient look up and then pressure is exerted on the lower lid; but this method is not in general use and is certainly not as satisfactory as that above described.

The condition found in one eye should always be compared with that existing in its fellow and if there be any doubt the results should be contrasted with those obtained by examining the normal eye of an individual of the same age. Schweigger has advised that in some doubtful cases it is of advantage to place the finger tips directly on the sclera. This method has not proved to be of any particular advantage, however, and in any case where it might be called for, it would be more advisable to resort to the tonometer.

The findings by the palpating method, just described, are expressed very simply. Tn. indicates normal tension and departures from normal are expressed by the symbols + 1, + 2, + 3 and — 1, — 2, — 3; the

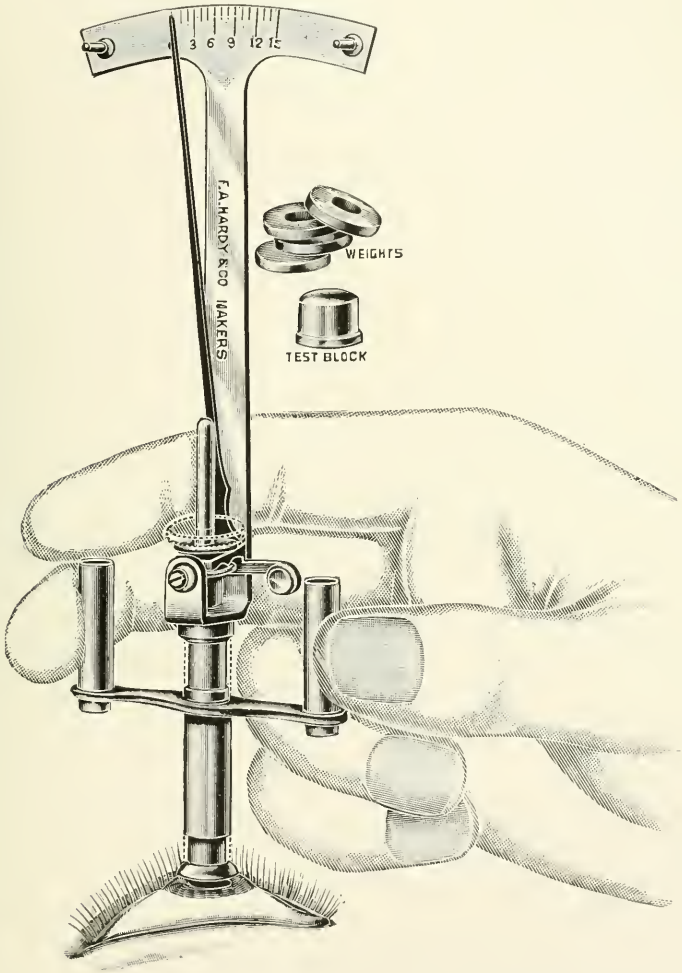

The Schiötz Tonometer as Modified by Gradle.

plus sign showing increased tension (hypertony) and roughly translated, + 1 means tension noticeably increased, + 2 greatly increased and + 3 hard as stone, or absolute glaucoma. The minus indicates diminished tension (hypotony); — 1 meaning a noticeable decrease, — 2 great decrease and — 3 absolutely soft.

The introduction of the tonometer of Schiötz has given a great impetus to the clinical study of intraocular pressure. One way in which this has been manifested has been the devising of different instruments to serve the same purpose. The Gradle tonometer is essentially the Schiötz instrument with these modifications. The corneal foot-plate and stylet are smaller, and the radius of curvature of the foot-plate is 7.6 mm. instead of 8.4 mm. These changes make it possible to fit the

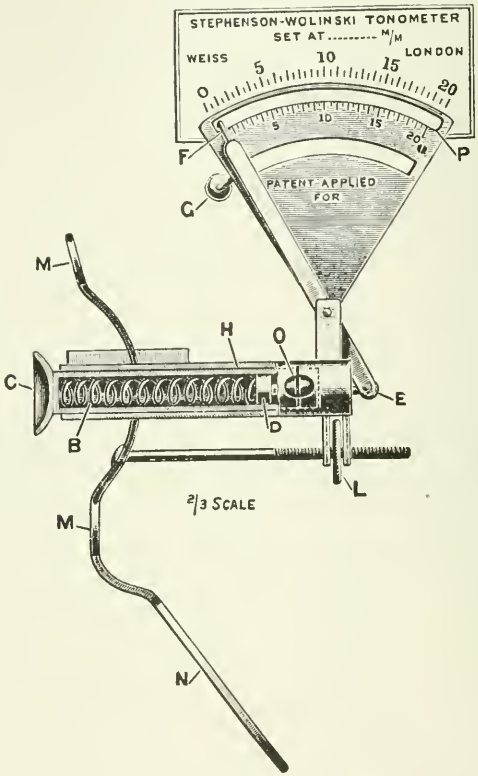

Stephenson-Wolinski Tonometer.

foot-plate more accurately to the average corneal curve in the pupillary area. The stylet is so attached that it cannot be dropped out of the tube in which it slides, and the four weights are each 1 gram, being added to each other when the resistance of the hardened eyeball makes a heavier weight necessary.

A totally different tonometer is that devised by Stephenson (*Ophthalmoscope*, IX, p. 632), with the assistance of Wolinski. This instrument may be understood by the examination of the cut. It is applied

on the closed upper lid with the patient in the ordinary sitting posture. There is a handle (N) for holding the tonometer in position on the patient's face, and a milled head (L) for adjusting it to eyes of varying depth. A spiral spring is contained in an inner tube (B), at the end of which is a concave cup (C), to fit the patient's closed lid. (B) is inclosed in a second tube (H), toward the distal end of which is an aperture (O), and an indicator shown by a vertical line intersecting the hole. The spring is actuated by a jointed lever (E), provided with a buffer end (D) where it comes into contact with the spring. The approximately vertical arm of the jointed lever (E) is provided with a handle (G) and a pricker (F). By moving the handle (G) along the slot provided for the purpose, more and more weight is brought to bear on the spring (A) through the jointed lever (E). As soon as the intraocular tension is equalized by the pressure on the spring, the fact is indicated by a movement of the zero line in the aperture (O). The exact weight is then pricked off on the chart, by a slight movement of the pricker (F).

The cup (C) is placed on the patient's closed lids, the metal supports (M) in contact with the supra- and the infra-orbital regions. The next step is to adjust the instrument, or, in other words, to lengthen or to shorten the tube by means of the milled head (L) until the vertical red line, seen in the hole (O), comes to occupy the center of the aperture. The reading is taken by pulling the handle (G) outward, until the zero line, seen in the aperture (O), is just broken. This shows that the compression of the spring within the tube is about equal to the pressure within the eye. The amount indicated in millimeters of mercury, is read off from the graduated arc (P), and simultaneously recorded on the paper chart by means of the pricker (F).

The tension recorded by this appliance appears to include three components: first, the tension of the orbicularis palpebrarum muscle; secondly, the intraocular tension properly so called; and, thirdly, the recession of the eyeball into the orbit. The first and third factors being fairly constant in the same patient, the variable intra-ocular pressure would be recorded by the tonometer.

The idea of measuring the intraocular tension by the amount of pressure required to flatten a fixed portion of the convexity of the eyeball, has been made use of by Coburn in his ophthalmo-tonometer (see cut). The essential part of the apparatus is a glass tube (G) protected by a fenestrated brass sleeve (B). Two centimeters from one end of the tube (about 6 mm. in diameter) it is drawn down to about 1 mm. diameter and then expands to the original size, again diminishing to 3 or 4 mm. The large end of the tube is covered with a thin

rubber diaphragm (R). The upper end (H) is connected by a rubber tube to a mercurial manometer (M). Between the manometer and the instrument already described is a 3-way tube (F) one branch of which leads to a rubber bag (L). The brass sleeve which surrounds the glass tube has a window through which the constricted part of the glass tube can be seen. At the back of the instrument is a sliding knob (K) which moves a pointer in the sleeve. The method of using is as follows:

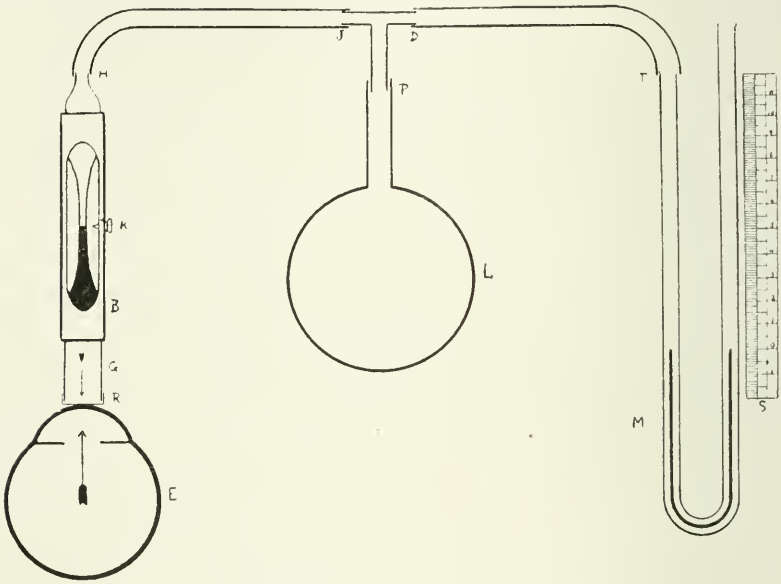

Ophthalmo-Tonometer of Coburn.

(1) The tube is filled with colored water to the lower end of the constricted part of the glass tube.

(2) Press the end of the instrument against a flat surface and adjust the index so that it marks the top of the fluid in the tube. This adjustment is made to indicate the height of the water in the tube when the diaphragm is a plane.

(3) Apply the diaphragm to the eye firmly so that the surface of the ocular tissues barely appears to dimple. The curvature of the eye causes the diaphragm to be pushed inward, making the fluid rise in the tube. The relative volumes of the tube and its constricted part are such that a small pressure on the diaphragm causes a marked change in the height of the water indicator.

(4) Press the rubber ball until the level of the fluid in the tube

returns to the marker, indicating that the elastic drum has been pushed back to its normal position (a plane), pressing the ocular structures also back to a plane, the area of which is equal to that of the end of the tube. The pressure as shown by the manometer will then indicate the ocular tension.

While fixing the normal intra-ocular pressure as 13 to 26 mm., Lübs (*Klin. M. f. Augenh.*, September, 1912, p. 371) finds that in three-fourths of the adults tested it varied from 18 to 31 mm.; but that in normal individuals the pressure of both eyes was the same. Age appears to have no influence on it. He used the 2 per cent. holocain solution to produce anesthesia; because the cocain solution reduces the intra-ocular pressure from 1 to 4 mm. in normal eyes; and may cause an outbreak of glaucoma by the mydriatic action on an eye predisposed to glaucoma. In normal eyes atropin has no influence on intra-ocular pressure. But pilocarpin and eserin, in .05 per cent. solutions, reduce it 3 to 8 mm. in about one and one-half hours. The subconjunctival injections of salt solution always increased intra-ocular pressure 3 to 8 mm. The return to normal occurred in three or four hours. In highly myopic eyes he found normal tension. In diseases of the cornea and uveal tract the tension varied. After cataract extraction it returned to normal in about four weeks. In simple glaucoma the tension may vary from normal to 100 mm. and is reduced by iridectomy.

Erdmann has confirmed most of the above observations. He found local anesthesia necessary for the accurate measurement of the tension. He also used alypin in a 2 per cent. solution for the purpose. He secures fixation of the eye by having the patient hold up his hand of the same side and look toward it. Heilbrun (Graefe's *Arch. f. Ophth.*, LXXIX, p. 552) places the normal ocular tension at 12 to 27 mm. He also finds it equal in the two healthy eyes of the same individual. Errors of refraction do not affect it. As to cocain, atropin, saline injections, and following cataract extraction, his results were similar to those since recorded by Lübs. Simple retinal detachment is not always attended with diminished tension, nor are intra-ocular tumors with increased tension. In simple glaucoma he believes there are always times in which the tension is elevated above what is normal for the individual.

Wegner (*Arch. f. Augenh.*, LXVIII, p. 290) from tests of 100 normal eyes, concluded that the tension of the eyeball diminished slightly with age. But the average for those under 25 years was only 24 mm., and the average for the whole series was 21 mm. So it seems that his observations are scarcely opposed to those that show no change

of intra-ocular tension with age. Kayser (*Klin. M. f. Augenh.*, July, 1911, p. 106), in a large series of elderly patients, found the tension of normal eyes to run between 22 and 25 mm. It was reduced (6 or 8 mm.) by electromassage, but soon returned to its former condition. Tension was also reduced by the pressure bandage. In a case of juvenile hydrophthalmos it was only 14 mm.; and in two cases of keratoconus, 11 and 13 mm., respectively, Cecchetto (*Clin. Ocul.*, XII, p. 739) in fifty persons with normal eyes, between 20 and 30 years of age, found the average tension to be 18 mm., considerably lower than Wegner's average for all ages. In posterior sclerochoroiditis with myopia (eleven cases) the average was only 13.2 mm.; but under treatment rose to the normal.

Luedde (*Am. Jour. Oph.*, XXIX, p. 289) urges great accuracy in the first measurement with the tonometer—care to see that the stylet is free, and the foot-plate properly placed, and that no pressure is made on the eyeball—gives more accurate results than to average differing successive readings. The repeated application of the instrument tends to bring down the tension. To prevent injury to the cornea he applies a droplet of oil to the end of the stylet or plunger; and suggests this may prevent any resistance to movement from fluid drawn into the tube by capillary attraction. He is inclined to recognize as glaucomatous certain cases in which the tension does not rise above the general limits for the normal, although too high for the individual: and he reports cases in which increased tension occurred secondary to other conditions. Diminished tension was found by him in iritis, central choroiditis, keratitis, persistent mydriasis after perforating injury of the sclera and optic atrophy.

It is a well-known fact that external pressure on the eyeball raises the intra-ocular pressure. During the time the tonometer is applied on the eye, a slight pressure with the finger or a faint attempt to close the lids is sufficient to modify the tonometric measurement, and a high intra-ocular pressure is recorded.

The four recti muscles and two oblique, besides their main function of moving and rotating the eyeball in all possible directions, exert a certain pressure on the eye by the constant muscular tonus, which is inherent to a normally acting muscle.

It has frequently occurred that, when two ophthalmologists palpate the same eye, the first examiner finds the intra-ocular pressure high, while the other pronounces it normal. With the Schiötz tonometer this has also been noticed. If the tonometer is applied on the eyeball several times consecutively, the instrument registers at the end a lower intra-ocular pressure than at the beginning. It has been found

that in normal eyes the intra-ocular pressure invariably decreases during the time the weight of the tonometer presses on the eye, and that this amount of decrease may readily be made out by simply watching the indicator of the tonometer moving to the right one or more divisions of the tonometric scale.

M. J. Schoenberg, in an able article published in the *Archives of Ophthalmology*, Vol. XLII, March, 1913, considers the relationship of tonometric findings to *intraocular drainage*. In this article he states that since Prof. Schiötz's second article on tonometry (*Arch. f. Augenheilk.*, vol. lxii., 1909) a number of very valuable contributions discussing various questions in connection with the intraocular pressure has appeared. Some of the questions have been partly cleared up, but many have been left untouched. One of these is the following: What is the normal rate of drainage of intraocular fluids in animal and human eyes, and how is this rate of drainage affected in glaucomatous eyes?

All who have had experience with the tonometer have observed that when this instrument is continuously applied on the eye for a certain length of time, or at very short intervals, it registers a gradually decreasing o. p. (intraocular pressure)—i. e., the eye becomes gradually softer. The rational explanation of this phenomenon is that the weight of the tonometer expresses a certain amount of fluid from the eye, thereby reducing the hardness. It is interesting to note that this fact has not been utilized in studying the drainage system of the normal and glaucomatous eyes. If by applying a weight on the eyeball, it is possible to express from this organ a certain amount of fluid, it is evident that there are channels in the eye through which this fluid is expressed.

It is almost universally admitted that the intraocular fluids are constantly renovated by a continuous slow flow of liquid which enters the eyeball and also by a continuous, just as slow, exit of liquid.

Wessely even figures out that the aqueous humor is drained and completely renovated every two hours. As the intraocular pressure is maintained at a certain level by the constant volume of the contents of the globe, it is obvious that this constant intraocular pressure is possible only as long as the amount of liquid entering the eye does not exceed the amount leaving it. In eyes in which the draining function is more or less interfered with, there is a loss of balance between the two main factors (in and outflow) regulating the intraocular pressure. The ocular fluid cannot leave the eye at the same rate as it does normally and the fluid contents of the eyeball will have

a tendency to increase in amount, consequently the intraocular pressure will increase also.

Supposing that a weight would be constantly applied on an eye with its drainage system in good order, that weight will gradually express from that eye a certain amount of fluid in a certain number of seconds. If the same weight is applied on an eye with its draining system partially obstructed (simple glaucoma), it will take a longer time to express the same amount of fluid. Finally, if the same weight is applied on an eye with its drainage entirely obstructed (absolute glaucoma), no matter how long we wait no fluid is expressed from that eye. Imagining that instead of the weight we use the tonometer, we readily see how we can judge at the same time the amount of fluid expressed from the eye by reading off from the tonometric scale the degree of decrease of intra-ocular pressure when the tonometer is applied steadily for a certain time.

In a normal eye the tonometer shows that the intraocular pressure is gradually decreasing at an average which we call normal; in an eye with an impaired drainage the weight of the tonometer still expresses fluid but at a much slower rate, and in an eye with absolute glaucoma the weight of the tonometer produces no decrease of the intraocular pressure.

From the above it is seen that the tonometer may be utilized for the measurement, not only of the intraocular pressure, but also of the index of ocular drainage.

The index of ocular drainage may be defined, in general terms, as the rate or rapidity with which the ocular fluid may be expressed by the weight of the tonometer applied on the eye.

Schoenberg, after much investigation, has become convinced that the mere measurement of intraocular pressure, while very helpful in the diagnosis of certain cases of glaucoma, is a procedure which may be incomplete and misleading unless the index of ocular drainage is measured at the same time. It is misleading in those cases which have only occasionally a high intraocular pressure. If the tonometer happens to be applied during one of the intervals when the o. p. is not above the normal limit, we may be induced to believe that the eye is normal. In fact, clinicians no longer rely upon a single examination. In suspicious cases, they have the o. p. measured repeatedly. It is not improbable that in some cases the examinations should be made during the intervals when the intraocular pressure is not high. In such cases, the mere taking of the o. p. with the tonometer is a crude and incomplete procedure.

K. Heilbrun (*Arch. f. Ophthalm.*, vol. xxix., 1911) and Stock

(*Beilageheft zu Klin, Monatsbl. f. Augenheilk.*, 1910) have each published histories of patients who had low intraocular pressure during attacks of glaucoma. Heilbrun says: "The tension, which lies within the normal limits, may be abnormally high in cases which have had an abnormally low intraocular pressure before." The mere satisfaction of proving that the intraocular pressure of an eye is below 27 mm. Hg., i. e., within normal limits, is sometimes deceiving and such an examination is incomplete. On the one hand, a low intraocular pressure does not exclude the presence of glaucoma, because the examination may happen to be made during an interval of nonirritability or because the original o. p. of the eye, when normal, was very much lower than the one now found. On the other hand, the measurement of the o. p. is interesting only in so far as it reveals the condition of the safety devices which such an eye possesses for keeping its draining system in good order. In other words, the measurement of the intraocular pressure alone throws some light upon the condition of the drainage system of the eye. This light is very dim, however, because the drainage capacity may be impaired to some degree and still the o. p. may not exceed the normal limit. Therefore, a correct idea about the normal condition or about the state of impairment of the mechanism regulating the intraocular pressure, can be obtained only when we consider both the intraocular pressure and the index of drainage of the ocular fluids. The elucidation of this point is of great importance in the early diagnosis of glaucoma, when the various complaints of the patient are vague and indefinite and the information furnished by a most careful examination is very doubtful.

The question of intraocular drainage measured on the eye in perfect physiological integrity (not on eyes punctured by a canula) has not been studied. The normal rate of drainage in human and animal eyes, the index of drainage in glaucomatous eyes at various stages, the influence of myotics, mydriatics, and cycloplegics on the drainage of ocular fluids, and the effects on the drainage of various surgical operations on the eye are some of the problems concerning the question of intraocular pressure.

As to the *method of examination for the index of ocular drainage*, a correct technic is necessary and all possible precautions must be taken in order to avoid errors. The method used in examining the rate of ocular drainage is as follows:

An assistant fixes the head in such a manner that one eye is directed as nearly straight upward as possible. Another assistant, with a watch before him, records the initial intraocular pressure shown by the tonometer and the exact time in seconds at which the examination is

begun. He then notes the number of seconds it takes the handle to move from the one division of the tonometer scale to the next one. The examination ends when the handle of the tonometer does not move while the instrument is applied for over 120 seconds.

Normal eyes have an ocular pressure and a rate of ocular drainage varying within relatively wide limits; glaucomatous eyes have some impairment in the function of the draining system. It is safe to suppose that in incipient or prodromal glaucoma, the drainage system may be undergoing slight alterations which, though too small to raise the intraocular pressure above the upper limit of the normal, yet sufficient to be discernible by the measurement of the rate of ocular drainage. There are patients with eyes in a condition of latent glaucoma in which the intra-ocular pressure is within normal limits—about 15 to 26 mm. Hg. The diagnosis in such cases can be cleared up to a certain extent by the measurement of the rate of ocular drainage.

By *visual acuity* we mean the power of the eye for distinguishing size and shape. The refraction of the eye and visual acuteness are frequently confounded. They are two entirely different things, however, and should be clearly distinguished from each other, although in practice we are accustomed to determine them together. The refraction is simply the function of the dioptric apparatus; while visual acuity is a function of the nervous apparatus of the eye.

To determine the acuteness of vision, we determine the smallest retinal image the form of which can be distinguished.

The visual acuity depends on five primary conditions:

First. Sensibility of the retina.

Second. Adaptation of the retina.

Third. General illumination.

Fourth. Sharpness of the retinal image.

Fifth. Intensity of the illumination.

The results of numerous experiments have shown that the two points of a retinal image, in order to be clearly distinguished from each other, must be separated by a distance of 0.00436 mm. Such a retinal image corresponds in the normal emmetropic eye to a visual angle of 1′.

Therefore, it is a measurement of the visual angle for objects that establish visual acuity. In order to obviate the influence of the power of accommodation or the necessity for glasses for focusing near objects, we determine the visual acuity by always measuring the visual angle for distant objects. Another advantage, as pointed out by Snellen, is that this method of determination uses larger figures, as distant test-objects, which are more easily constructed than the small ones that are required as tests for shorter distances.

As Snellen states in Norris and Oliver's *Diseases of the Eye*, full visual acuity must be looked upon as that which is found after correction of any abnormality of refraction. It has become the custom, however, to add "with refraction," to the term, "visual acuity," if the result has been obtained with the aid of lenses. If the test has been made with parallel lines, the influence of astigmatism may have been excluded by placing the lines in the direction in which they are most distinctly seen. All that is then necessary is to determine the spherical glass which gives the best distant vision.

It is only by excluding all disturbances caused by want of transparency or by abnormal refraction that a correct conclusion as to the perceptive power of the retina can be arrived at.

The successful study of *test types* must be founded on an absolutely clear understanding of the restricted meaning of the term "visual acuity" as used in ophthalmic practice. This restricted meaning is clearly indicated in the following sentence of Landolt's: "In the determination of that which we in practice term 'visual acuity' we endeavor to exclude as far as possible the color sense and the light sense . . . We, therefore, employ no colors, but only black and white, . . . and a constant illumination." The measure of the visual acuity is given by the size of the smallest visual angle under which a test object can be perceived, using black-white contrast and the most favorable illumination. The only test object whose dimensions can be exactly stated in terms of a visual angle are dots and gaps (minim. sep.). Strictly speaking the visual angle is the angle at the apex of a cone with a circular base. Hence a round dot is the only object whose dimensions can be stated with absolute accuracy in terms of the visual angle subtended. Under constant conditions of contrast and illumination the visibility of a round dot depends solely upon the size of the visual angle it subtends. Therefore a round dot, black on white or vice versa, is theoretically the best test object that can be used for the determination of visual acuity.

The dots are arranged in groups (see figure) and the person tested is required to tell the number of dots in each group. This is a very practical illiterate test and if a series of groups, graduated so as to be distinguished at different distances, are prepared, it is applicable to the illiterate and to persons of all nationalities.

Fridenberg (*Arch. of Ophth.*, XXXIX, p. 227) has made use of this system in what he calls a *stigmometric card test*. He uses dots arranged in groups, the visual acuity being shown by the ability to count the number in each group. For the near tests the different groups correspond in visibility to the Jaeger test type. In the distance test, instead

of dots, squares are used, each square and intermediate spaces corresponding to the Snellen minimum separabile of one minute; the number to be counted in each group varies from one to five. Different arrangements of the same number of dots or squares give a wide variety to the group forms; so that only actual seeing of separate dots gives indication of their number.

L. Wolffberg in Graefe's *Archiv. für Ophthalmologie,* Vol. 77, p. 409, points out that in using a dot as test object one complies with the principles that visual acuity is to be tested by determination of the power of perceiving an interruption of continuity. For a dot is noth-

Simplest Test Card.
(This series of dots is large enough to be counted at five meters.)

ing but an interruption of the continuity of the surface on which it is printed. He has constructed a table (see figure) in which the test object is a cross consisting of four black squares arranged about a white square of equal size. In one of the black squares is placed a white dot whose diameter is one-third that of the square. The person examined is required to state in which of the four black squares the dot is situated. Comparative tests with this table and a very accurately constructed ring table gave almost identical results, showing that the two tables were practically equivalent.

Wolffberg's Cross-Point Figure Test for Visual Acuity.

At the International Ophthalmological Congress in 1909 the report of a special committee was adopted, which recommends a mode of expression for the degrees of acuteness of vision which can be used in all languages and which aims to give us an official international standard of acuity. The test type endorsed by them is the invention of E. Landolt, and he (*Archives d'Ophtalmologie*, 1909) reviews this report. He states that their report resolves itself into two matters, viz.: the principles underlying the expression of the visual acuteness and the type of test-material recommended by the committee.

On the first point they laid down six general principles: the test to be based upon the minimum separabile, or the capacity to perceive

an interruption to continuity; the test to be made by means of a black ring upon a white ground, the ring to be broken at one part for a space equal to the width of the limb of the ring, which is one-fifth of its diameter; the visual acuteness to be expressed in relation to the smallest angle under which this can be deciphered, or in other words to the maximum distance at which this can be done; a visual angle of one minute to be the standard of comparison; the mode of expression to be either in decimals or as a fraction ($v. = \frac{d}{D}$); and, lastly, the eye to be tested only at a distance from the test object.



Landolt's Broken Ring Test.
(Adopted as the international standard for testing acuity of vision.)

Landolt expresses full concurrence with their decision, and satisfaction that the Committee should have affirmed the principle which regards the degree of visual acuteness as proportional to the distance at which the type is recognized, and not to the square of that distance, as has been advocated by some.

In the choice or construction of the vision test it is highly desirable that the object should be one not capable of being merely guessed at, recollected, or arrived at by exclusion, as might be the case with letters, which have the further disadvantage that they are familiar to the literate but unfamiliar (and therefore more difficult to discern) to the relatively illiterate. The test object should, in addition, be of such a character as to require only direct and simple answers, a desideratum which has told greatly hitherto in favor of letters as tests. It is further essential that the examiner should be able to control and keep a check on the replies of the person examined.

These demands are all met by the use of the interrupted ring test, for it adapts itself to the principle of the minimum visibile: it is the same for all persons and in all positions; race, instruction and educa-

tion have little or no influence on its efficiency. Question and answer are of the simplest, for a slight movement of the hand will show the position of the aperture, and the whole is so readily regulated by the examiner, who can, if he wishes, rotate the "type" into different positions without any change in its aspect or in its meaning or its visibility. On these grounds, both theoretical and practical, the interrupted ring test object has commended itself highly to the Committee.

Secondly, the scale recommended has great advantage in its simplicity. One can either, using one size of type, discover the maximum distance at which this is visible to the patient, or, employing objects of different size, place the patient at a certain fixed distance. The latter is naturally the method practically always adopted, and to represent the acuteness of vision enjoyed one employs the scale of 0.1 up to 1.0 or 2.0. It is constructed on the basis of $v. = \frac{d}{50}$, d being the distance at which the patient reads the "letter."

Landolt criticises very unfavorably, however, the action on the part of the Commission of placing, side by side with the proper test object, Arabic figures constituting a second test. Now whatever argument can be brought forward against letters applies with even greater force against figures (numerals): they are less familiar than letters to the majority of persons, and even if they are in general terms international the precise form of the numeral is certainly not universally identical, the figures by no means carry out the principle of the minimum separabile, and they are not equally clearly visible even under the same visual angle. They may be convenient as mere test objects, but are without value from a scientific point of view.

It is to be hoped that the broken ring test will become more and more generally used and finally be understood by all ophthalmologists as the scientific standard for testing visual acuity.

The popular method, however, and the one which no doubt will always continue in use for daily consulting-room practice, is the use of the same cards of test-letters employed in making the test lens examinations.

Edward Jackson, in an article read before the Section on Ophthalmology at the Sixty-Fifth Annual Session of the Am. Med. Assn.' stated that the cards of test-letters in common use are admirably adapted to the subjective determination of errors of refraction; but as a test for visual acuity they probably afford the poorest and most inexact standard on which any scientific observations are now based. As a standard for visual acuity, test-letters belong to the stage of

mental and scientific development when the standard for length was "three full grains of barley corn taken from the middle of the ear," or "the distance a man can walk between sunrise and sunset."

As a help in the subjective measuring of refraction they are superior to any substitute that has been proposed and are not likely to be given up. But as a scientific standard they possess two essential defects:

1. The different letters when made as uniform as possible are visible from very different distances. This makes them unsuitable for a scientific standard.

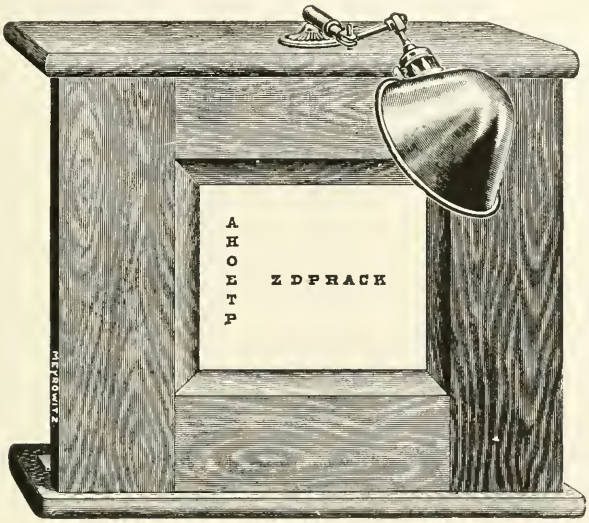

The Grow Unlearnable Test Card.

2. They can be readily committed to memory by all who are sufficiently familiar with them to make them a convenient test. This lessens their value as a practical test.

To set off this latter objection, Grow (*U. S. Naval Med. Bull.*, July, 1911) has devised what he calls an unlearnable test-card (see illustration). It has six lines of letters, ten in a line, conforming to the Snellen standard of 20 feet, and three lines of smaller letters. This card is hidden except as a part of a single row of letters is revealed through a vertical or horizontal opening; not even the examiner himself can know what letters are exposed except by actually reading them.

A test type cabinet on somewhat the same principle has been invented by Chas. Wray. It consists of a compact pedestal on one side of which are mounted square blocks, set in holes. These blocks are so pivoted that they may be turned with either one of four faces external and

as all of these four faces contain different letters printed on their surfaces, it is possible for the examiner to expose an innumerable number of combinations to the patient.

The most universally used test is that suggested by Snellen. The letters used are of various sizes, so constructed as to subtend an angle of five minutes at the distance at which they should be seen by the normal eye. Each part of the letter and each space are equal to one-fifth of the whole and subtend an angle of one minute. The largest letter is of such size that it should be read at 200 feet, or 60 meters, and those following decrease in size so that they should be read at 100, 70, 50, 40, 30, and 20 feet, or their corresponding values in meters, respectively.

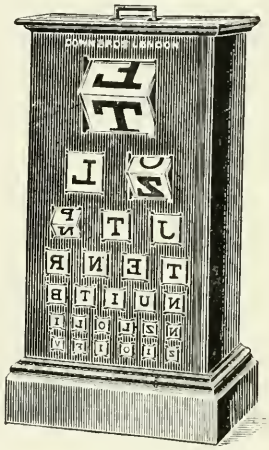

The Combinations Test Type as Suggested by Chas. Wray.

Each eye should be tested separately, and the result expressed by a fraction in which the numerator corresponds to the distance the patient is seated from the test type and the denominator the distance at which the letters should be read by the normal eye.

If the patient seated at twenty feet from the test type reads the letters numbered 20, then $v. = \frac{20}{20}$ or is normal. If he cannot read smaller letters than those numbered 50 (letters which should be seen by normal eye at 50 feet), $v. = \frac{20}{50}$.

If the patient seated at twenty feet is unable to read the large letter

which should be seen at 200 feet, he walks toward the chart until the distance is reached at which he reads this largest letter. If, for example, it is ten feet, then $v. = \frac{10}{200}$, the numerator being the farthest distance from the chart at which he can read the largest letter.

Landolt's Test Types.

Many modifications of the Snellen test types have been suggested. One card is made with the letters white and the background black. Landolt has designed a chart which, while somewhat resembling the Snellen chart, is based on the Landolt broken ring test (see illustration).

The "Alternating" test card of Meyrowitz consists of a heavy cardboard chart mounted in an oak frame. The lines below the 70 feet appear through openings in the front, and either of the two sets may be made to appear by means of a pull on the lifting device through the cord and handle.



Test Chart with White Letters on Black Background.

Moorfields Test Types.

The Kuparoid test type is a transparent type that can be mounted on glass by merely first soaking the chart in water, and then smoothing down until air bubbles are removed.

By mounting this type on a window pane, the uniform natural illumination of daylight is secured, leaving the test letters in sharp relief.

Seitz Test Chart for Children and Illiterates.



Wolbart's Hebrew Test Type.



Snellen's Test Chart of Numbers.

Wendell Reber's Kindergarten Test Chart.

Alternating Test Card.

This is a most valuable accessory for hospitals and schools. The letters are quite opaque and the chart is not affected by atmospheric changes.

The letters are also arranged with complementary colors of red and green as a binocular vision test.

Boettcher has invented a series of what he terms geometrical test-types. In addition to German (Gothic) reading tests, these contain sets of square figures with a notification of the distance at which the figures of each size may be recognized and counted by a normal eye. The objection to these tests is that it is not stated what is assumed to be the normal standard of vision.

In those affections that reduce the light-, color- and form-perception capacity either of the retina, optic fibres, central radiations or visual centers, but especially in the early stages of optic atrophy or in certain forms of chorio-retinitis, the ordinary letters (or other characters of the black and white test-types) may show that the patient has normal or nearly normal vision. Bjerrum has suggested that in suspected cases of this sort the visual acuity be also measured with black letters (or other characters) with a gray or gray-brown background. In the normal individual the central volume will be almost as good $\frac{6}{9}$ as with the more clearly printed black on white, but those with retinal or optic nerve disease will show vision reduced to $\frac{6}{18}$ or even less.

Sherman (*Trans. Amer. Ophth. Soc.*, XII, II, p. 658) calls attention to the use of diffraction gratings placed with a variable obliquity to each other, so that they give rise to alternate bands of light and dark. These have been used as a laboratory test by Dr. Ives. With uniform illumination the perception of the alternating bands becomes a constant test for visual acuity. The direction of the bands can be varied and used to check the answers of the person tested.

Weiss has made a pocket test type (see illustration) which contains eight different Landolt broken rings and can be folded into a very small space.

In case the examining room is not of sufficient length to allow the patient to be the proper distance from the card, the distance may be doubled by using a mirror to reflect the test card into the patient's eyes. In this case reversed letters are required and a chart is shown with letters so arranged.

J. N. Rhoades (*Ophthalmology*, July, 1912) in an article on the use

of mirrors to lengthen the distance of the test card from the patient, says that during the last few years there has been a growing tendency among refractionists to get away from the classic six meter distance of test cards. Some operators have suggested twelve meters, and a few even eighteen. Most refractors find it next to impossible to place their cards even twelve meters away on their own territory. Hence, some have gone so far as to get permission to erect cards in their neighbors' windows; or, defying the elements, have placed them on their neighbors' outside walls.

It will be seen by following the accompanying diagram that eighteen meters can be obtained by hanging an ordinary test card on the wall of a twenty-foot room. If a favored operator has a thirty-foot room

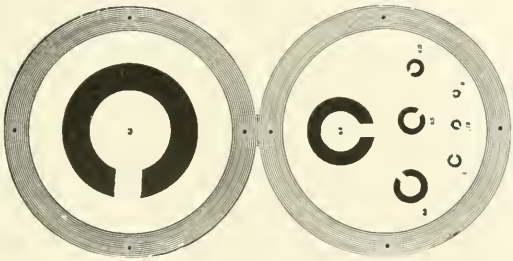

Landolt's Portable Folding Pocket Test Types.

he can project his test cards 27 meters away, or, as it were, across the widest street. It is true that most of the cards would be useless at that distance, as not more than "D. L. N." in the old "E" card could be seen that far away.

There are many refractors who do not have rooms which are even six meters long. It is to these that the catoptric system of projecting the test card is a necessity. The fact of the matter is, that a room six feet square will answer admirably for refraction by the use of two mirrors. Of course, a card in such a small room would need to be artificially illuminated, but it will be found that such a card will be twice reflected by mirrors practically without reducing the illumination.

It is a well-known fact that in a room ten feet wide one mirror will throw a card which has been placed on the opposite wall, ten feet back of it. This, to be sure, places the card twenty feet in front of the patient, but, all are aware that there must be a special card used, owing to lateral inversion. The room, too, as has been said, must be at least ten feet wide, while with two mirrors any size

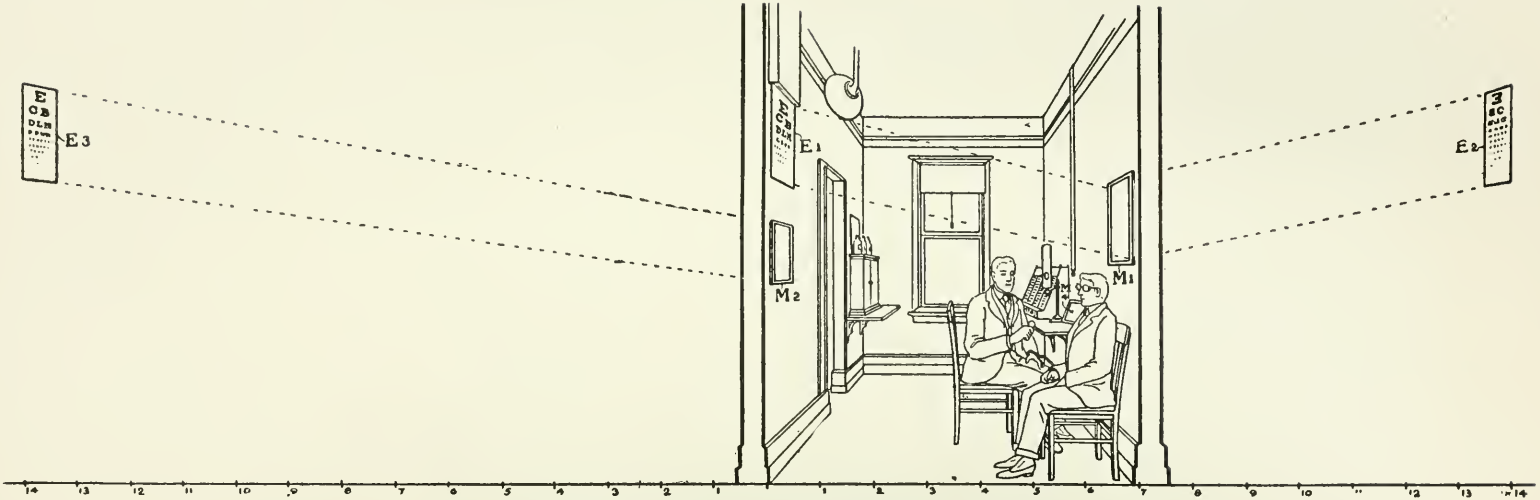

Tripling the Distance of Test Cards by Catoptrics.

room down to four or five feet will do, and any ordinary test card will answer the purpose.

Glancing at the diagram it will be noticed that the test card has been thrown thrice its distance in front of the patient. It goes without saying, that this distance applies to any size room and to most any distance desired. The accompanying cut has been drawn to scale to represent a room seven feet square, which, allowing for the comfortable seating of the patient, places the "E" card just twenty feet in front of him. Describing the illustration, it is barely necessary to say that mirror No. 1 throws a lateral inverted image of the test card "E" No. 1 behind it equal to its distance before it, as seen at "E" No. 2. Now, mirror No. 2 throws this lateral reversed card "E" No. 2, which is fourteen feet in front of it, back to "E" No. 3, as seen in the left of the cut, which is fourteen feet back of No. 2 glass. It will be noticed that "E" No. 3 is erect. It will also be seen that the patient is sitting approximately six feet in front of No. 2 mirror, which added to the fourteen feet the card is behind the mirror makes it just twenty feet away for the testing distance.

The test most used for illiterate patients is that made up of figures resembling the Snellen "E." These figures are turned in different directions (much as the Landolt rings) so that the openings point either up, down, left, or right.

An instrument, which he calls an acutometer, for testing the acuteness of vision independently of the recognition of letters, has been devised by Black (*Ophthalmoscope,* IX, p. 7724). On a white ground is shown a black stripe the width of which can be varied. This line is interrupted by two white squares, the position of which can be changed. The test is made by finding the narrowest stripe and smallest squares visible by good light, at a known distance. An index on the instrument indicates the distance at which they should be just visible to the normal eye.

An object test card, or kindergarten card for visual tests has been devised by Reber (*Jour. Am. Med. Ass'n*, December 16, 1911, p. 1993), using objects likely to be recognized by young children, and conforming as nearly as practicable to the test letters used at 6 meters. Bouchart (*L'Opht. Prov.*, VIII, p. 161) has presented a series for which he claims a normal progression by more regular intervals than others in use, approached most nearly by that of Parinaud.

Maddox advises a test card in which the terminal or initial letters indicate the distance at which they should be visible (*Ophthalmoscope*, X, p. 322). His series begin with the letters "Y" and "X," which he points out are most valuable in detecting oblique astigmia, but a

single letter of each size is given until the last line or two. This allows the patient to read quickly down to the working line. The same ideas have been worked out in his series of near test-type. On this card are also placed two of the Landolt broken rings, four sets of parallel lines to test astigmia, and two spots of green to test for

One of the Simplest Methods of Illuminating Test Charts.

color scotoma. The card is one that can be readily carried in the pocket and used in the patient's home.

Pardo (*La Clin. Ocul.*, XII, p. 565) has tested the effect of looking at test-type obliquely. This causes distortion of the letters, and diminishes the area of the type, in proportion to the cosine of the angle, that the visual line makes with the chart. He finds that the diminution in visibility depends chiefly on diminution of area, the distortion of the letters making little difference. Thus, when the

angle was 15 degrees (75 degrees from the perpendicular) the acuity was reduced to 5/12. The decrease in area of the image would account for its reduction to 6/12, leaving only 1/12 due to distortion.

For the recognition of *inequality of visual acuity in the two eyes*, Martin (*Rec. d'Opht.*, XXXIII, p. 119) finds the deviation of the amblyopic eye on near fixation both convenient and reliable. The point of fixation being brought toward the eye, one or the other pres-



Mortimer Frank's Parabolic Reflector for Illuminating Test Types.

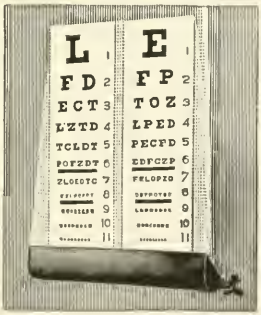

"Opticians' Reflector" for Illuminating Test Types.

ently deviates. He found this was always the amblyopic eye, even in cases in which the difference of acuity was only 1/10.

The *system for lighting test charts* is of great importance, for it can be readily seen that the same illumination should be used in every case. One of the simplest forms (see illustration) consists of a wall bracket equipped with an electric bulb and reflector, so arranged that the light is thrown directly on the card.

Stargardt has chosen a Nernst lamp for this purpose, which throws an illumination of 400 candle power. This, he states, gives a constant,

equal illumination and also avoids the effect of glare from the background.



Test Card Cabinet with Reflector as Used in Wills' Eye Hospital.

A more uniform standard for the illumination of test types has been sought by C. H. Williams. A simple photometer has been devised by him, consisting of two developed glass negatives, cut in strips about six inches long by three-fourths of an inch wide, placed face to face

and mounted in a metal case. The film on each negative increases in density in geometrical ratio from a clear end to the opposite end, which is densely shaded. This photometer slides in a metal case that has a sighting hole punched through both sides of it. This case is held with the hole in front of the eye and the glass slide drawn out so that denser and denser portions are looked through until the light to be tested is just extinguished. These photometers have been care-

Meyrowitz Mirror Cabinet for Test Cards.

fully graduated at the Harvard College Observatory, to conform to those used in astronomical work.

Mortimer Frank's system of parabolic reflection (see illustration) for illuminating test types is constructed on scientific principles and affords a most even and perfect illumination.

The Opticians' Reflector (see illustration) is much in use, but the lighting is not uniform and the lower lines of the chart receive more brilliant illumination than those at the top.

The test card with reflector as used in Wills Eye Hospital (see cut) is a very successful arrangement. It consists of six of the most popu-

lar distant test cards on extra stiffened boards with numbered leather pulls for adjusting the card to any position desired, where it is held by the compensating weight attached to each card. The new style shed light, containing two tubular electric lamps encased in a black metal box lined with mirrors, produces an even and bright illumination on the entire length of the card through its ground glass window.



Black's Testing Cabinet No. 1.

The Meyrowitz mirror cabinet (see illustation) consists of an open box containing the test type set in a frame of mirrors 4 inches deep, and the illumination is by a 20-C.P. tantalum lamp. The light from the lamp is perfectly diffused by the mirrors and the card is evenly and softly illuminated as with daylight.

Nelson M. Black has devised two rather elegant testing cabinets. Cabinet No. 1 (see illustration) is 21 by 32 by 7⅞ inches, and is painted dead black. The left half is divided into seven compartments. The upper contains an astigmatic chart, the next two compartments contain letters for 6/VII ½ vision; the next three have 6/VI letters and the last 6/V. The right side has four compartments. The upper contains letters for 6/LX, 6/XXX and 6/XX vision, the second com-

partment letters for 6/XV, 6/XII and 6/X vision, the next compartment 6/XII letters. The fourth compartment is fitted with an iris diaphragm for muscle testing and Williams lantern for testing color

Black's Testing Cabinet No. 2.

vision. The inside is white enameled and the compartments divided by means of bright tin, which refract and reflect the light thoroughly. The large compartments are lighted with two 10-c.p. incandescent lamps, the next smaller compartment with one 16-c.p. lamp, and the

small divisions with one 10-c.p. lamp each. The lamps illuminating the various compartments are each turned on and off by a switchboard at the operator's side. The intensity is regulated by a rheostat, so that the illumination may be controlled at will. The type in each compartment is separate and distinct from that in the other compartments and the letters are black, painted upon opal glass, in accordance with the most approved measurements. Cabinet No. 2 (see cut) is made with an iron standard to place on the floor, or with brackets by which it may be attached to the wall. A wooden frame holding four different porcelain test types, inside of which, so as to evenly illuminate the



No. 1050.

The Hardy "20th Century Testing Cabinet."

type, are placed electric lights. The cabinet revolves, bringing a different type into view at the will of the operator. It is supplied with a wheel controlled by a cord that runs back from the cabinet to the operator, so that the type may be revolved without his leaving his seat.

The "Hardy 20th Century Testing Cabinet" has the advantage of enabling the operator to expose only one line of type at a time to the patient without moving from his seat, thus doing away with the possibility of misunderstanding as to what the patient sees.

The cabinet itself is made of wood with a dead black finish, and is hinged at the top so that the inside may easily be gotten at to change lights, charts, etc. The one end of the strip of paper on which the type is printed is fastened in a clip on a roller and the other end is fastened on a duplicate roller on the other side of the opening. These rollers are controlled by counterweights, permitting the chart to be stopped at any point without fastening in any way. The type may then be

exposed in front of the opening, as desired, by a cord operating the roller. This cord may be placed wherever desired and the cabinet operated from any part of the testing room. The cabinet is made in two styles—first, wired for electricity, and second, with an extension back into which a kerosene lamp may be fitted. The cabinet is supplied with English, German and illiterate type, in addition to the color testing device and muscle test.

The Rogers Cabinet (see illustration) is equipped with a switchboard controlling the lights for the various lines and tests. Any one or all of the openings can be illuminated as desired.



The Rogers Cabinet.

The left hand side of the cabinet contains three openings, the upper one being a preliminary test to get the visual acuity of the patient. Next in order comes the astigmatic dial and muscle and railroad tests, with iris diaphragm. The right-hand side contains seven openings, all separately illuminated. The six smaller ones have duplicate lines of type which can be instantly dropped in or out of position when desired. After ascertaining by means of the preliminary test type the visual acuity, the proper line of type on the right side of the cabinet can be illuminated for the completion of the test. The railroad test contains a slide with red and green glass for making the different color tests.

The outside dimensions of this cabinet are 29 by 30 by 7 inches. Size of switchboard is 10 by 8½ by 4 inches. The cable is about 1 inch in diameter, and, as mentioned above, can be made any desired length.

Seligmann has constructed the following apparatus: Nine different sizes of Schweigger's test types are painted on milk glass, which can be easily kept clean and allows of a uniform illumination. The larger letters are arranged in a circle, the smaller ones in two concentric

circles. They are placed on revolving discs in a flat box with nine round holes, which can be covered by lids. The single types can be made to appear in the holes in rapid succession. The illumination is furnished by electric lamps behind the discs.

When the patient's vision is so poor that he is unable to recognize the large letter at any distance, the distance is obtained at which he is able to count the examiner's fingers held against a black background. Suppose he is able to do this at ten inches or twenty-five centimeters, then V = "counting fingers" at that distance. If he is unable to count fingers, the hand is moved in different directions in front of the eye, and the patient required to tell in what direction it is moved.



Worth's Ball Visual Test for Young Children.

If he is able to do this, V = hand movements. If there is inability to distinguish hand movements, the eyes are alternately covered and uncovered, and if he is able to perceive the difference between light and darkness, V = light perception (p. 1.).

Apart from its scientific interest, it is often of great practical importance to be able *to estimate approximately a young child's visual acuity*. Worth accomplishes this by means of five ivory balls varying in size from one-half inch to one and one-half inches in diameter. The child is first allowed to handle the balls with both eyes open. Then one eye is covered by a pad, or, if he wears glasses, by a piece of cotton wool stuffed behind the lens. He is then asked to go and pick up the balls as they are thrown on the floor to a distance of six or seven yards, one by one, beginning with the largest. By spinning the ball in the fingers as it is thrown, it may be made to "break" on touching the floor, so that it does not go quite in the direction in which

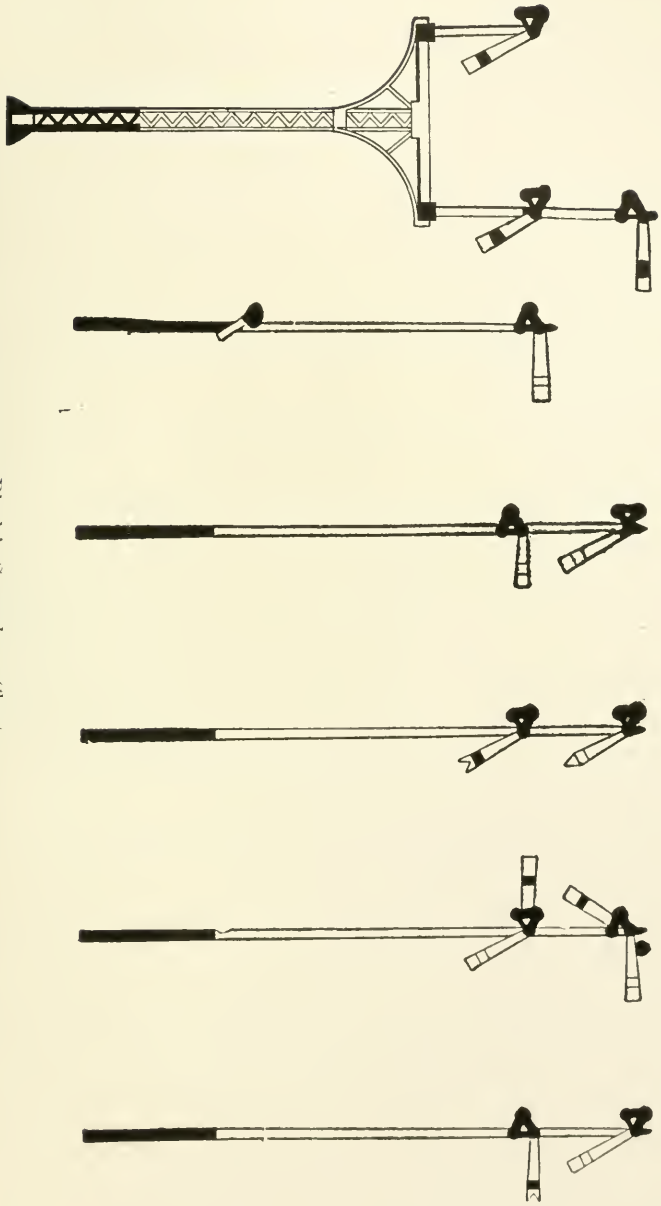

Black's Semaphore Charts.
(For testing the vision of railroad employes.)

it appeared to have been thrown. It is easy to tell, by the way in which the child runs for the ball, whether he really sees it before he starts or is only going to look for it.

Black has described a method especially designed for *testing the visual acuity of railroad men* (see illustration). The set consists of five cards, representing a 20-foot standard semaphore pole and arm seen at one-half mile (2,640 feet), with actual colors for the "Distance" and "Home" signals, and placed on a neutral grayish background which corresponds to the average tint of the horizon. By the aid of these charts one is able to judge almost exactly as to the practical value of the eye-sight of the individual.

The advisability and necessity of examining the eyes of children attending the public schools is now generally recognized by principals and teachers everywhere.

Frank Allport has proposed a test card which furnishes a simple method whereby the eyes of each pupil may be quickly examined by the teacher, a record made, and, if an apparent defect exists, the parents notified. This system has been annually employed in many cities of this country, and is rapidly being adopted by boards of education throughout the United States and other lands. See Vol. V, p. 3204 *et seq.* in this *Encyclopedia.*

For making these tests a card of test letters has been planned, with complete instructions on each card. These cards are printed upon 6-ply Peerless board, 11 by 27 inches, with a metal eyelet hole for hanging. The lower section, or that part of the card containing instructions and information regarding their use, is made so as to readily be detached from the main body of card.

The object of this is to allow the examiner to have before him these instructions while examining the pupil, with the test letters hanging at the proper distance on the wall.

A time-saving device to be used on all test cards has been suggested by Holbrook Lowell. It consists of a strip of gummed green paper, 1 cm. wide, is pasted just below the $\frac{20}{50}$ line on the test-type card, and a strip of gummed red paper, 1 cm. wide, just below the $\frac{20}{30}$ line. It is found that patients usually will voluntarily say that they can read the letters either above or below the red or green line. There is no confusion when you ask a patient to read either just above or just below one of the colored lines. Experience shows that these colored lines, besides fixing the patient's attention on the letters you wish



Disc or Hall Charts for Testing Vision of Railroad Employes.

The center areas of the charts are colored red and green for various indications.

him to read, give a useful hint as to the patient's color perception. By comparison with the newer test-type cards, having lines indicated by the large numbers, it has been found that this device of the colored lines is very much less confusing to the average patient.

In testing near vision the patient is seated in a good light and each eye is tested separately. Useful test types consist of the various sizes of ordinary printer's type, technically called Jaeger's test types, the smallest corresponding to diamond print. More scientific and accurate are those corresponding with Snellen's distance types. The



Allport's Vision Chart for Schools.

former are numbered 1, 2, 4, etc., according to the size of the type. If these are used and the patient reads the finest print at the ordinary reading distance, 10-13 inches, V=Ji; if he reads that numbered 4, V=Jiv, etc.

Many modifications of the Jaeger types have been proposed. One of the most useful of these is that in which all the letters are capitals. For children and poorly educated individuals it is of much value.

A test of value in estimating the near vision of a musician is made up of different sized bars of music (see cut).

Another original chart is also shown consisting of common fractions of different sizes.



The Jaeger and Snellen Test Type for Testing Near Vision.

Near Vision Test Types.

(This test is convenient for examining musicians as to their ability to read music at various distances; the four selections comprising the four most common sizes of music type.)



Near Vision Test Types.

(The characters consist of a series of common fractions; the large figures showing the average visual angle subtended by the individual parts of each line at a distance of 20 inches.)

The examination for the *detection of simulation of blindness* is one which relies much on the cleverness of the examiner as to its ultimate results. Many patients have made a study of the various methods of detecting malingerers and it becomes necessary for the operator to so vary the regular routine methods as to fool or confuse the patient. Many cases therefore become quite a problem and are very difficult. See **Blindness Simulated,** Vol. II, p. 1176, of this *Encyclopedia.*

One is first led to suspect simulation by the lack of agreement between the results of functional testing and of the objective examination; an eye, for example, which is alleged to be perfectly blind

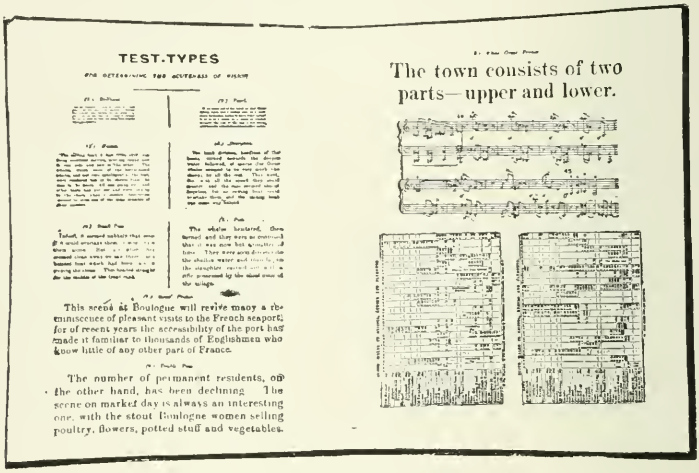

Reid's Modified Jaeger Chart for Testing Near Vision.

presenting no pathological changes of any sort. Or the tests of the individual functions give contradictory results, inasmuch as the visual acuity, the field of vision, the color sense, etc., do not stand in the right relation with each other and with the result of the objective examination. Various methods of examination have been proposed for furnishing a certain proof of simulation, and many plans for apparatus to confuse the malingerer have been invented.

Complete blindness of both eyes is rarely simulated; much oftener it is simply unilateral blindness that is alleged; and still more frequently a feebleness of sight actually present in one eye is exaggerated.

In case of an alleged complete blindness of one or both eyes we regard in the first place the reaction of the pupil to light. If this is well preserved, it will always afford a strong ground for suspecting simulation, although there are rare cases in which in the presence of actual blindness the pupillary reflex for light is still retained.

Schmidt-Rimpler recommends the following procedure: The patient is made to look with the blind eye at his own hand, which he holds in front of him. A blind man will do this without hesitation, since he is informed of the position of his hand by the sense of feeling; a malingerer will perhaps look purposely in the wrong direction.

Simulated unilateral blindness can be discovered in the following way: A lighted candle is brought in front of the good eye and is slowly carried toward the side of the blind eye. The patient is detected if he declares that he still sees the candle at the moment when it is just concealed from the sound eye by the bridge of the nose.

Another test with the candle is to place it about twenty feet away from the patient and place a prism of 6 degrees, base upward or downward, before the sound eye; if he sees double it is an indication that the vision is good in both eyes.

With the lighted candle in the same position, cover the supposed blind eye. Then produce monocular diplopia by moving a 6 degree prism, base upward or downward, until the apex corresponds to the center of the pupil. Next uncover the blind eye and at the same time move the prism until it covers the entire pupil. If now there is still double vision (binocular diplopia) it is evident that both eyes see.

Another simple way to fool the pretender is to place a strong convex lens (12 D.) before the good eye and a weak convex lens (0.25 D.) in front of the supposed blind eye, and direct the patient to read the distant test types; if he succeeds, it is proof of malingering, since it is impossible for him to see with the sound eye when covered by the strong lens.

In feigned binocular blindness a close watch must be kept on the patient when he thinks he is free from observation, and the following test may be applied: Place a lighted candle in front of the patient; hold a 6 degree prism base outward before one eye; if both eyes see, the one covered by the prism will move inward in order to avoid diplopia; on removing the prism it will move outward, the other eye remaining fixed.

The instrument of Fridenberg (see p. 1179, Vol. II, of this *Encyclopedia*) is designed for the detection of simulators and is simple. The principle of the instrument is to reflect the image of a test card in such a way that it can be seen by only one eye at a time, and a quantitative demonstration of vision can be made without the subject of examination obtaining any clue as to which eye is being tested.

The mirror is mounted on a horizontal arm in such a way as to permit of varying its distance from the test card, and of presenting it alternately to either eye by revolving the bearing through an arc of

180 degrees. The lateral tilt of the mirror can be changed at will, and is indicated by a pointer on a horizontal scale. When the pointer is at 90 degrees, the plane of the mirror is at right angles to the line of vision of the eye on the corresponding side, and this eye sees its own image. The test card on this side, however, is not normal to the mirror, and its reflection is seen only by the opposite eye, which the subject presumes to be unconcerned in the visual act, as it does not appear in the mirror.

By switching the mirror over to the opposite side of the arm, a similar double test can be applied, so that in all eight variations are rapidly obtained. The mirror can be adjusted laterally to correspond exactly with the interpupillary distance and correcting glasses inserted in the trial frame, if necessary.

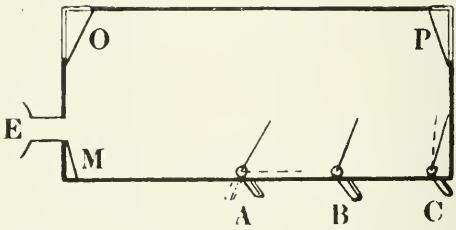

Bouchart's Arrangement of Mirrors and Test Type to Detect Simulation.

The test is simple, rapid and exact, gives no clue to the simulant, and can be demonstrated without theoretical explanations to the members of a commission or jury.

The *tubes of Gratama* for detecting simulators have been modified by Koster with the result of making an instrument complete in itself and not requiring the use of test cards at 20 feet distance. The letters are placed 75 cm. from the patient's eyes and the card is rigidly connected with the tubes. The card contains two separate rows, one of letters and one of numerals, and graded to indicate tenths of visual acuteness. The rigid connection of the test types with the tubes prevents any interference with the test by the patient changing the position of his head. The tubes are pressed against the brow and cheek, openings in the proximal end adjusting them for different widths between the pupils. The sliding panels in the ends toward the test types can be so adjusted that the patient sees either the right row of type with his right eye, and the left row with his left; or the reverse of this, the visual lines crossing each other between the end of the tube and the test type. The patient being unable to tell which eye he is using, necessarily breaks down in any pretense of blindness or poor sight.

The *method of Bouchart for detecting simulation*, while rather complicated and requiring somewhat extensive apparatus (see cut), is very trustworthy and will almost surely cause a simulator to contradict himself. Three of the mirrors, A, B, and C, are movable. The eye being placed at E sees the test type O reflected from mirror A, the distance from the eye being 40 cm. Then without the patient's knowledge, mirror A is dropped against the side of the box, and the reflection coming from mirror B is 60 cm. from the eye. In the same way mirror C is used, giving a reflection 100 cm. distant. Again, by slightly

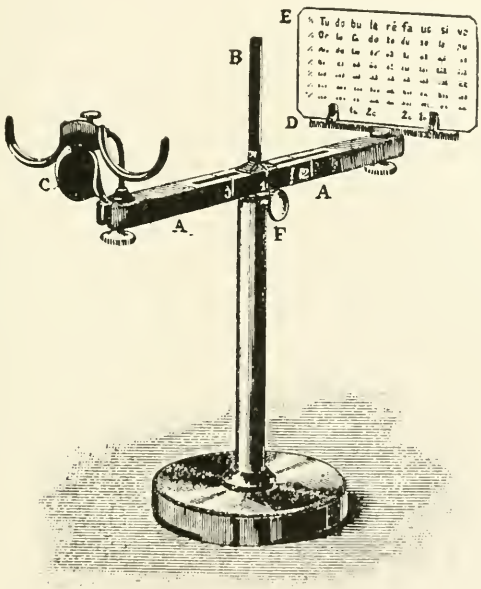

Autosymoptometer of Armaignac.

changing the inclination of C it is made no longer to reflect O, but instead the reflection of P from the fixed mirror M removing the test type in effect to 150 cm. The patient has no way of knowing which image he is looking at. The largest line reflected from A gives vision of 1/15. Reflected from M and C it gives vision of 1/4; and to read the smallest line, in the last case, vision is normal.

Another instrument working on somewhat the same principle has been suggested by Armaignac and called by him, "autosymoptometer with mirrors." It consists of a box, containing two mirrors that can be turned at different angles. According to the angles at which the mirrors are placed, the patient looking through two openings in the

side of the box, sees with one or both eyes the reflection of an eye or two eyes, or the reflection single or double, of a cross or black circle. A table accompanying the instrument shows what is actually visible by each eye or both, for different positions of the mirrors. The number of combinations is such that it is quite impossible for the simulator to conceal his pretense.

Armaignac has also designed another instrument to be used in the detection of pretended blindness which compares the vision of the two eyes simultaneously. This one he terms an "autosynoptometer with a slide." (See cut.) The arm AA at one end C a fixation plate and lenses; at the other end a card upon which short rows of words are printed in type which grows progressively smaller from above downward. The slide in the center carries an upright rule, B, which shuts off from the right eye one row of words, and from the left eye another row. The particular rows thus cut off are determined by the relative distances of the slide from the eyes and card. Thus with the slide at 1, the row marked 1D at the bottom shut off from the left eye is seen only by the right, and the size of the letters read in this column gives the acuteness of vision for this eye. If the slide be pushed to 2 the line marked 2G at the bottom is shut off from the right eye and read only by the left, giving its visual acuteness.

In most malingerers an inability to see out of one eye is the customary complaint. To determine the truthfulness of such statements, one of the most satisfactory and ingenious tests devised, is the colored letters " F R I E N D " alternate red and green, which are rendered invisible by looking through glasses of complementary colors. (See cut.) These letters are only visible when held up so that light may shine through them, preferably day light.

The patient is seated a few feet from the chart, and the glasses above referred to are placed before the eyes. Both eyes are allowed to be used in order to disconcert the individual, using a red glass before one eye and a green glass before the other. If able to read the entire word, blindness is absent. If the eye before which the green glass is placed is blind, the green letters will be suppressed by the red glass of the other eye, and the red letters will be intensified, so that the patient will spell only the word R-E-D. If blindness is absent, fusion of the images of both eyes will occur and the entire word F-R-I-E-N-D will be seen.

The findings of the first test may be verified by reversing the test frame which is provided with an X bridge for this purpose, when blindness will be indicated by the patient reading the word F-I-N in green letters.

The reading of the entire word indicates malingering, and will at once satisfy any judge or jury as to the merits of the case in question.

Roche, to discover exaggeration of unilateral amblyopia, has a series of 100 cards, each carrying a single test letter. These are presented to the patient, one at a time, by reflection in a mirror so that he will be unable to judge with which eye he is seeing the letter. To facilitate use of the mirror symmetrical letters like "V" or "H," are employed.

For more extensive consideration of this subject see **Blindness, Simulated,** Vol. II, p. 1176, of this *Encyclopedia.*

For *the detection of defects in the color sense,* the method devised by Holmgren is most generally used. A number of skeins of wool, comprising different shades of green, red and their confusion colors (gray and brown) are placed before the patient, who is first given a

Colored Chart for Making the "Friend" Test for Malingerers.

skein of green colored wool. This is called the test skein and he is required to pick from the pile of wools in front of him the skeins of the same color, not the same shade, as the one he holds in his hand.

If there is any defect in his color-vision the patient will select a number of the confusion colors (chiefly grays), with perhaps some green tints. If he accurately chooses all green the investigation need proceed no further; he has normal color-sense—is not color-blind. If, however, he fails, he is given a rose-colored skein and again told to choose skeins of that color. He is now likely to match the rose with browns, purples, dark-grays or even greens. Finally, to find out what variety of color-blindness he has, he is given a deep-red skein when he will probably choose the dark-browns and greens. The great majority of color-blind people are defective in red and green and, consequently, are said to have red-green blindness, although all varieties, from simple green to total color-blindness, exist.

With this test it is almost impossible for one who is color-blind to escape detection. The person under examination should not be allowed to name the colors; only to select those colors resembling the test-skeins in his hand.

Thomson's modification of the Holmgren test is probably the most convenient method of making the test. The skeins of wool are attached to a stick and as the patient chooses a certain skein he reverses it to the other side of the stick.

For many years the Holmgren colored worsteds have been used by the railways and marine service of the United States and most foreign countries to test the color-sense of their employees. When properly used, according to directions, this test has proved to be practicable and reliable. The most serious objections to it are:

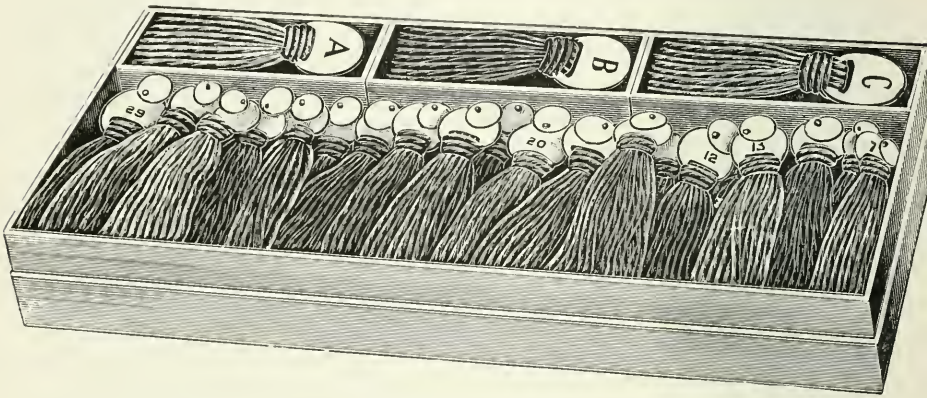

Holmgren Color Test.
(Skeins of wool are numbered as suggested by Thomson.)

1. The worsteds become soiled by constant handling so that the more delicate shades can hardly be distinguished one from the other.
2. The method of recording the skeins selected by the candidate is laborious and liable to lead to error.

In order to overcome these objections Jennings (*Jour. Am. Med. Assn.*, Sept. 19, 1914) has constructed a test in which the worsteds are not handled and the candidate makes a permanent record of his own color-sense. It consists of a square box (see illustration) divided into an upper and a lower half, each half having a lid—virtually two shallow boxes with bottoms joined together. The upper side of the box is marked "Test No. 1 Green," and contains a color board made up of all the different colors, shades and tints likely to be mistaken by the color-blind for green. The lower side of the box is marked "Test No. 2 Rose," and contains a color board made up of all the different colors likely to be mistaken by the color-blind for rose. The color boards, like the box, are absolutely square and each contains sixty-four

patches of worsteds of various colors and shades, making a total of 128 colors used in the test.

In each patch of colored worsted is a circular opening in the color board which is for the purpose of registering the particular patch of color chosen by the candidate. This he does by inserting a pointed pencil of wood or metal through the opening and punching a hole in the record sheet which had previously been placed beneath the color board. The position of the patches of color and the circular openings have been arranged in an absolutely symmetrical design, so that when the box is turned in any one of four positions the same appearance is presented and it is impossible to say which is top or which is bottom. The openings of the color boards are so arranged that the records of both the green and rose tests are made on a single sheet.

The cover marked No. 1 is removed, the color board lifted out, a record blank inserted and the color board replaced. Care must be taken to see that the mark "top" in the box, "top" on the back of the color board and the top of the record blank all correspond. The box is now turned around several times until all sense of direction is lost.

The green test skein fastened to the inside of the box cover is placed at a distance of two feet and the candidate is given the pointed pencil and requested to look along each row of colored patches and when he sees the test color or one of its lighter or darker shades, he is to place the point of the pencil in the opening and punch a hole in the paper beneath. Having completed Test 1, the cover is replaced and the box turned over, exposing Test 2, the rose. The record blank having been inserted and the rose skein displayed, the test proceeds as before. The advantages claimed for this method are:

1. The candidate makes a permanent record of his own color sense.
2. The soiling of the worsteds by constant handling is avoided.
3. The worsteds are divided into two groups: in the first group are placed all the colors mistaken for green by the color-blind; in the second group are placed all the colors mistaken for rose by the color-blind.
4. The comparison of colors by placing two or more together is avoided.
5. The large number of colors used, 128, gives free scope in the detection of all cases of color-blindness.
6. The small size of the color patches, while ample to show the color to the normal eyed, may lead to the detection of a central color scotoma.

7. The tedious method of recording the color-sense by pulling out a concealed bangle and writing its number on a blank is avoided.

8. An important color cannot be lost.

9. On account of its symmetry it is absolutely impossible for any but those with a perfect color-sense to pass the test.

10. It is the only method by which uniform results can be obtained whether the examination is made by the physician or by the layman.

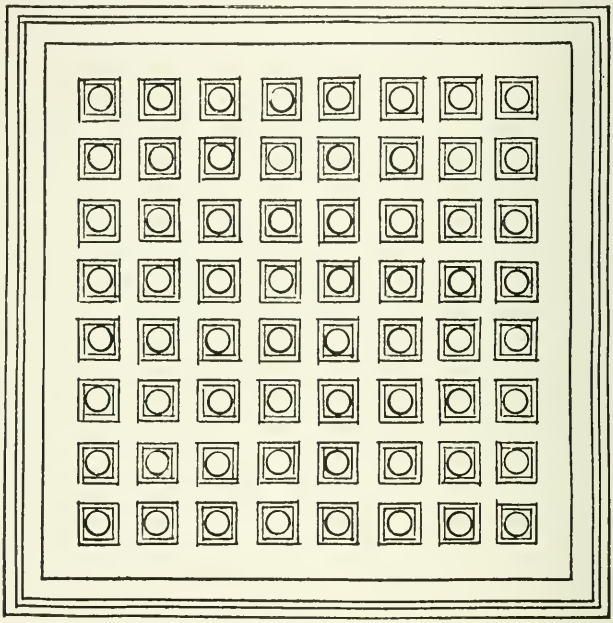

Jennings' Self Recording Color Test.

11. Two or more records of the examination can be made at the same time and the official at headquarters is able to see exactly what colors have been selected to match the test skeins.

Birch-Hirschfeld (*Trans. Thirty-Eighth Ophth. Cong.*, Heidelberg, p. 350), has devised a cabinet into which light is admitted through two slits, which can be covered, one by green glass, the other by red, or red and blue. Ground glass is placed at the bottom of the cabinet, and a rod in such position that half the glass will be screened from one slit, the other half from the other, so that the ground glass appears half red and half green. The widths of the slits can be varied, thus varying the illumination of the ground glass. An opening on one side permits the patient, and on the other side the surgeon, to look at the

ground glass. The color-blind fail to properly recognize the colors seen.

A projecting polariscope for testing color perception is suggested by Tomlinson (*Trans. Ophth. Soc. United Kingdom,* xxxi, p. 35). The light from a Nernst lamp is polarized by reflection from blackened glass, set at the proper angle, and falls on eight strips of mica. A projecting lens receives light from the mica, and at its focus is placed an iceland spar prism, to serve as the analyzer. As the prism is turned the colors projected on the screen vary.

Lanterns for detecting color-blindness have been designed by William Thomson, Charles H. Williams and Edridge-Green. These instruments have mainly been devised to, as nearly as possible, imitate the conditions under which employees will be required to use their color perception. See Vol. IV, p. 2411, of this *Encyclopedia.*

The Thomson lantern consists of an asbestos chimney, which can be placed on the kerosene lamp in universal use on railroads, or over an Argand or other gas light, electric lamp, or spring candle-stick. Two discs, four inches in diameter are so placed upon the chimney as to permit of their being partly superimposed. The lower disc contains seven glasses in apertures one-half inch in diameter, having the white, red, green and blue colors in general use on railroads. This may be considered the "examination in chief," whilst the upper disc, when combined with the lower by turning one or both, furnishes the "cross-examination." The upper disc has two apertures, one one-twelfth of an inch, the other one-half inch with white glass. The other five have one white ground glass, one deep London smoke, one pink, one green, and one cobalt-blue glass.

The combination of the white ground and the smoke glass with the reds and greens of the lower disc enables all atmospheric conditions to be imitated, and the lights to be diminished in brightness and tint. The use of the small opening enables size and distance of signals to be imitated.

The upper disc has its seven openings marked by the letters of the alphabet, and the lower by the numerals from one to seven. The examination should be made in a darkened room, and the results reported on a blank, the details being used when requisite. The patient examined is expected to call or name the colors and to recognize them when being seen in 1 minute at 20 feet.

Rumble's test card for color blindness (see illustration) is made up of discs of cardboard on which are transparent colored spots. By revolving the discs the spots appear in holes made in the outer envelope of cardboard enclosing the discs.

The patient is seated about ten feet from the card which must be well illuminated by day light shining through the transparent colored spots.

First test. Turn large disc and require patient to say when any color appears which he thinks is green or a shade of green, as he compares it with the one shown above it. Hesitation in selecting, or the choice of other than shades of green, proves a defect in the color-sense.

Second test. To determine whether it is red- or green-blindness, turn the small disc so rose is presented and proceed as in the first test.



Rumble's Test For Color Blindness.

If green shades are matched with rose it is green-blindness; if blue is chosen it is red-blindness.

Third test. Present red with the small disc, and the red-blind will select darker shades, while the green-blind will choose lighter ones.

Violet-blindness will manifest itself in a tendency to select blue in the first test and red or orange in the second.

F. H. Verhoeff (*Ophthalmic Record*, June, 1913, p. 299), has described a simple attachment for hand electric lights, to be used in testing color-vision (see cut).

The attachment here shown was made from a thermometer case, with a piece of thin, hard rubber for the perforated disc, and attached

to the lamp by a section of an eye-dropper bulb. The screens for the openings were made of photographic film stained, after fixing, in carbol-fuchsin, light-green and methylene-blue, respectively, and fastened on with balsam. A thin piece of white celluloid is placed in the tube to diffuse the light.

Nothing, in the opinion of Edridge-Green (*British Med. Jour.*, July 6, 1912), has retarded the knowledge of the subject of color-blindness more than the statement (attributed to Holmgren) that in any test for color-blindness names were not to be used. He has never come across a man who was a candidate for an employment in which he had



Perforated Rotary Disc Attachment for Testing Color Vision, as described by F. H. Verhoeff.

to distinguish between red and green light, and who on examination called green "red" and red "green" through color ignorance, and who was really able to distinguish between these colors and had a normal color-sense. Many adhere to the statement that names should not be used, and the writer therefore analyzes the difference between matching and naming colors to show that the use of color names is a necessity and that no test for color-blindness can be efficient which ignores them.

Edridge-Green has ascertained the percentages of color-blindness in men, and finds that about 6 per cent. are definitely color-blind, whilst 25 per cent. have a diminished color perception compared with the other 75 per cent. The 6 per cent. when examined with his lantern made mistakes between the red, green and white lights, when they were clearly distinguished as different by the other 94 per cent., and any onlooker would say that they were rightly rejected, and it would not

be safe for them to be in command of a ship in which it was necessary for them to distinguish between these three lights.

Many color-blind men, he asserts, will pick out the wools to match all five test colors as accurately and easily as a normal-sighted person, so that, after a long, tedious examination he would not have suspected they were color-blind; but upon examination with his lantern, lasting less than half a minute, red has been called green, nothing or white; white has been called red or green, and green has been called red or white.

The *pseudo-isochromatic plates of Stilling* consist of a series of plates (10 in number). Each plate is divided into four squares each containing small, irregular, colored spots, distributed among which are other spots in a confusion color, made to conform to an Arabic figure. The plates are held in front of the patient, in a good light, and he is required to distinguish the tracings. See **Color sense.**

EXAMINING THE EXTRA-OCULAR MUSCLES.

Three conditions are to be investigated when examining *the motility of the eyes.*

First (when the eyes are at rest), we note the relation of the optic axes to each other.

Second, we examine the ability of the eyes to preserve the proper relationship of the optic axes so that binocular single vision always remains present. This will be spoken of as the "fusion power."

Third, we ascertain the voluntary power of the eyes to rotate in various directions.

Each of the above three groups require their own separate tests and these will be described under the different headings.

The Position of rest.—The chief function of the coordinating centres controlling the fusion power is to keep the optic axes parallel and thereby avoid diplopia. In order to determine if the natural position of the eyes in a given case is parallel with the optic axes, we must abolish, for the time being, the power of fusion. One way of doing this is by the *prism test.* A test object, which may be a candle, or other round luminous body, is placed twenty feet from the patient.

It is well at this time to speak of two improvements on the simple candle or small electric light. One is the apparatus of Frank (see illustration) which consists of a box containing the source of light. Facing the patient is a hole in the side of the box with arrangements made for placing lenses or different colored glasses in the aperture.

The "Curtis Motion Target" is an ingenious instrument the purpose of which is to provide a fixation point that will practically rivet

the attention of the patient without causing him to put in force any accommodation. It is large enough to be easily seen at the usual distance (twenty feet) without accommodation. The various colored circles of this novel and peculiarly attractive target seem to start in

Frank's Light for Muscle Test.

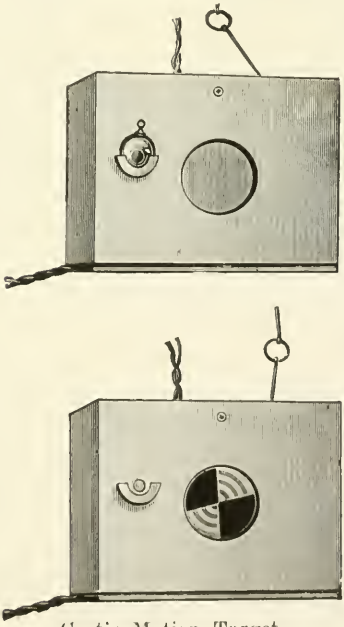

Curtis Motion Target.
(To be used as the fixation point in making muscle tests.)

its center and to radiate toward the periphery, constantly getting larger and larger until they finally disappear. Immediately a new one is started, and it, like its predecessor, radiates outward and finally disappears. These constantly changing colored spiral circles practically rivet the attention of the patient, causing him to hold his eyes

perfectly still and to forget, for the time being, that he is having his eyes examined.

If a 5° prism, base down, is now placed over the patient's right eye, the image of the light is thrown on the lower part of the retina of that eye and the light itself appears displaced upward. If one light appears directly above the other we know that the vertical planes of the eyes are still parallel. Removing the first prism we next place an 8° or 10° prism (or one strong enough to cause diplopia), over one eye with base in. We now ascertain if the patient sees the two lights on the same level. If one is higher than the other we know the eyes have deviated vertically.

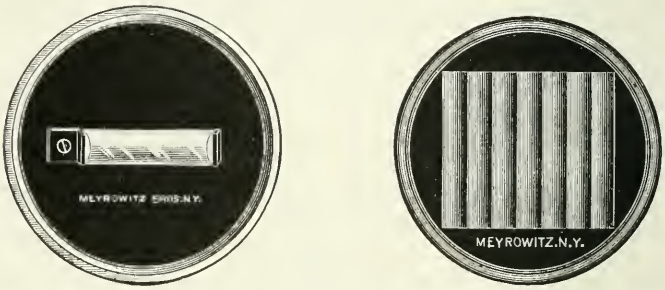

Maddox Rods.

The *red glass test* is based on a similar idea. A red glass is placed over one eye, and the tendency to fuse a red flame and a white one being much less than to fuse two white ones, the patient may see two lights if the optical axes are not parallel. The fusion power in this test is, however, not entirely abolished, and the test is not as delicate as the preceding. Absence of diplopia does not show a normal balance with this test, but it is of value from a practical point of view in that the patient can describe the relation of the images more accurately by their color, and also when diplopia is present the lateral and vertical deviations are shown at the same time.

The *Maddox rod* (see illustration) consists of a glass rod or series of rods closely touching each other so as to produce the optical effect of a very powerful convex cylinder. When placed before one eye the flame appears with that eye to be a narrow band of light. There being no tendency to fuse this band with the plain light as seen with the other eye, the two eyes assume the position of rest. By turning the rod in different axes one may arrive at the actual relationship of the two visual axes.

James Thorington has demonstrated a new test which is thought to be an improvement on the plain Maddox rod.

This test consists of a truncated prism (see illustration) ground in two 7 degree prisms separated by an interval of plain glass 3 mm. wide. It is made in colorless, ruby-red or cobalt-blue glass. It is a delicate and exact test for muscular insufficiencies, producing the combined effect of the Maddox rod and double prism in one piece of glass, with the very important addition of a central light as a starting point.

The cone test consists of a strong convex lens, which is placed over one eye and causes the flame to be seen by that eye as a circular disc of light. To avoid prismatic displacement the lens is covered with hard rubber, except a very small opening at the centre (see figure). If the

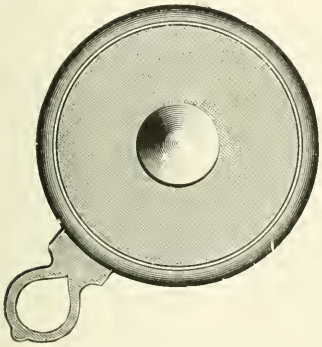

Cone Muscle Test.

Thorington Muscle Testing Prism.

optical axes are parallel the patient sees a circular body of light, and directly in the centre the candle light. Displacement of the light from the centre shows deviation of the eyes.

Duane's test consists in having the patient fix a distant candle with both eyes, at the same time the examiner places himself so that he may distinctly watch both of the eyes of the one under examination. While the eyes are fixing the candle the examiner interposes a card first in front of one eye and then the other. The eye behind the screen, no longer being stimulated by the image of the candle flame, assumes the position of rest.

If the visual lines in this position are divergent we can see the eye turn out behind the screen and if we then withdraw the card the eye, in again fixing the flame, makes a distinct movement of redress inward. If the eye deviates in behind the screen, with a movement of redress outward when the card is removed, we know that the position of rest

must be one of convergence and the same reasoning holds good of vertical deviations, the movements of deviation and redress being up and down; while if no motion of the eye can be detected either behind the card or when the card is withdrawn, the visual lines are practically parallel and the position of rest nearly normal. If the eyes deviate outward behind the card we can, by placing a suitable prism, base in, over the eye, so change the direction of the rays from the flame that on the withdrawal of the card they fall on the macula without the necessity of any movement of redress; while if the prism is too strong the movement will be reversed, the eye turning outward instead of inward when the card is withdrawn. Duane considers that if a distinct reversal of the movement of redress occurs with a 10° prism there will be no perceptible movement in either direction with a 7°, 8° or 9°, and that the 8° is therefore very nearly the mean deviation.

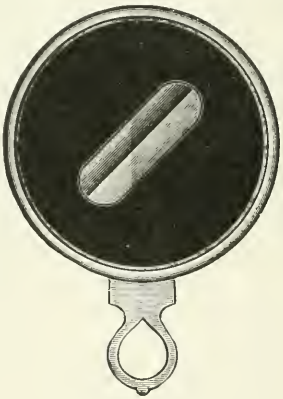

Maddox Prism.

Using the candle flame as an object as before, we place before the one eye a Maddox rod with its axis carefully horizontal and over the other a similar rod with axis vertical. From the first the eye gets the impression of a vertical band of light, while the other eye sees a horizontal one. If the vertical planes of the two eyes are exactly parallel in the position of rest, these bands should intersect at right angles. If the vertical planes are not parallel, the angles of intersection will not be right angles, and one eye or both must evidently have been rotated wheel-fashion, either intorsion or extorsion.

Instead of a candle flame we may use as a test object a chart containing a single vertical line. If we place over either eye a prism, base in, strong enough to cause diplopia, we shall see two vertical lines instead of one, and if no torsion exists, they should be perfectly

parallel to each other. The defect of this test is that many individuals have a tendency, if they cannot fuse the lines, to make them parallel by action of the obliques, and the eyes are therefore not in a position of rest.

Double prism test. The Maddox prism (see illustration) is composed of two prisms in a trial ring, so arranged that their bases touch, their line of junction passing exactly through the centre of the ring. If this is placed before one eye, so that this line passes horizontally in front of the centre of the pupil, it will cause a monocular diplopia, and

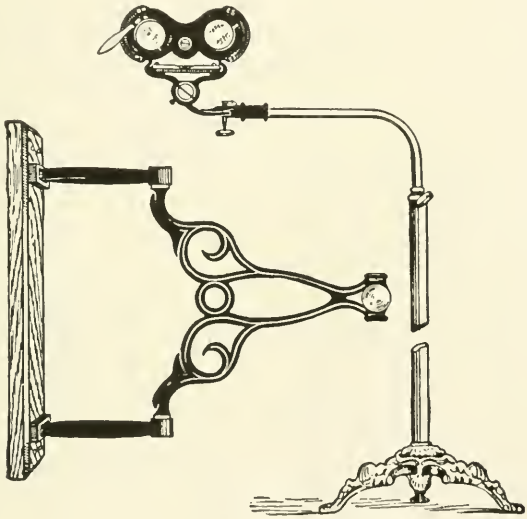

Improved Stevens Phorometer.

the horizontal line used as a test object will appear as two parallel lines. If, now, the other eye be uncovered, it sees a single line which, if no torsion of either eye has taken place, should be between and parallel to the other two lines.

An easy way of measuring the amount of muscular error is to place prisms of increasing strength before the eye, at the time of making the red glass test, with base in, out, up or down, as the case may require, until orthophoria is established.

Stevens phorometer is a valuable instrument for measuring muscular insufficiency, consisting of two rotating discs, each carrying a prism of 5°. Each disc is connected by a cog wheel and moves in unison. A scale, increasing from the center each way from 0° to 8°, gives the strength of the refracting angle of the prism used (see cut). After leveling the instrument, if testing for hyperphoria, the pointer is

fixed at 0° and the patient looks straight through the prisms at the light placed at 20 feet. He sees two images, and if they are on a level, the muscle balance is normal. If one image is higher than the other, the prisms are rotated until the images are made level. The pointer then indicates the form and amount of the manifest hyperphoria. In examining for esophoria and exophoria the pointer is to occupy the vertical position. Normally the two images will be seen

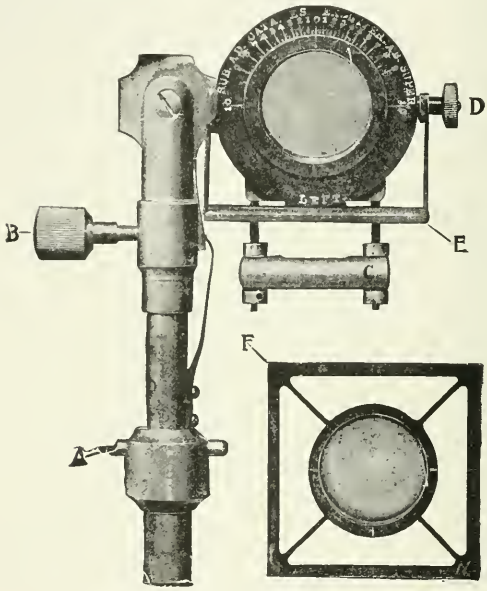

Savage Monocular Phorometer.

on the same vertical line. If one is displaced to the right or left the adjustment is made as before until the images occupy the same vertical line, and the amount of insufficiency is read off by the scale on the side.

Savage has designed a monocular phorometer (see illustration) based on the principle that the image in one eye should be undisturbed during the testing of the various ocular muscles.

All tests given so far are to determine if the eyes are in a state of equilibrium for distant vision. The following tests are to ascertain their state for near work.

The cover test or screen test is performed by having the patient look at some small object held about fifteen inches away from the eyes. A card is placed alternately over one eye and then the other, while the

surgeon observes the position and movement of the eye at the instant of uncovering. A movement inward indicates that the eye has deviated outward (exophoria). A movement downward means hyperphoria.

In *the fixation test* the patient is told to observe the surgeon's finger, which is slowly advanced to within three inches of the patient's nose. If one eye turns out, there is exophoria. This test is a rough one, and its chief value is in determining which of the interni is the weaker.

Stevenson has described a near vision muscle test which is very practical. It consists of an apparatus (see figure) which presents one prism base upward and one base downward to the patient. This causes him to see the card doubled and in such position that the

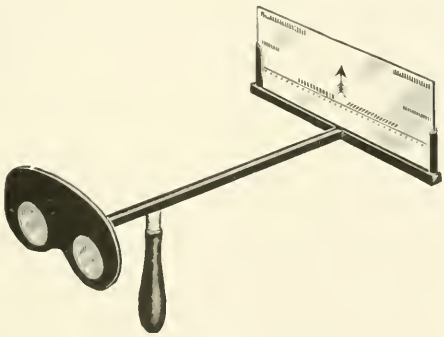

Stevenson's Muscle Test.

arrow will point to a number on the scale, which will show the degree of deviation present.

Maddox has described an ingenious near vision phorometer.

It will be seen by the illustration that it takes the form of a hand instrument to be held by the patient. It has two eye pieces of neutralizing colors, attached to a rod 33 cm. long. At the other extremity is a disc, opaque except for two designs which are made translucent and of neutralizing colors. The horizontal consists of a green scale with figures above. This is intersected at right angles by a red dotted vertical line. The amount of any existing esophoria or exophoria can be immediately measured, being indicated by the dioptric divisions on the scale. By turning the scale to the vertical, hyperphoria can at once be measured. If the patient is asked to place the dotted line in the vertical position, a scale at the back will show the amount of any existing cyclophoria.

Another invention by Maddox is an improved test for near muscle

balance, called the "wing test," which is not so dependent on conditions of light as the rod and the near vision phorometer made from Snellen's principle of neutralizing colors. This apparatus contains no lenses.

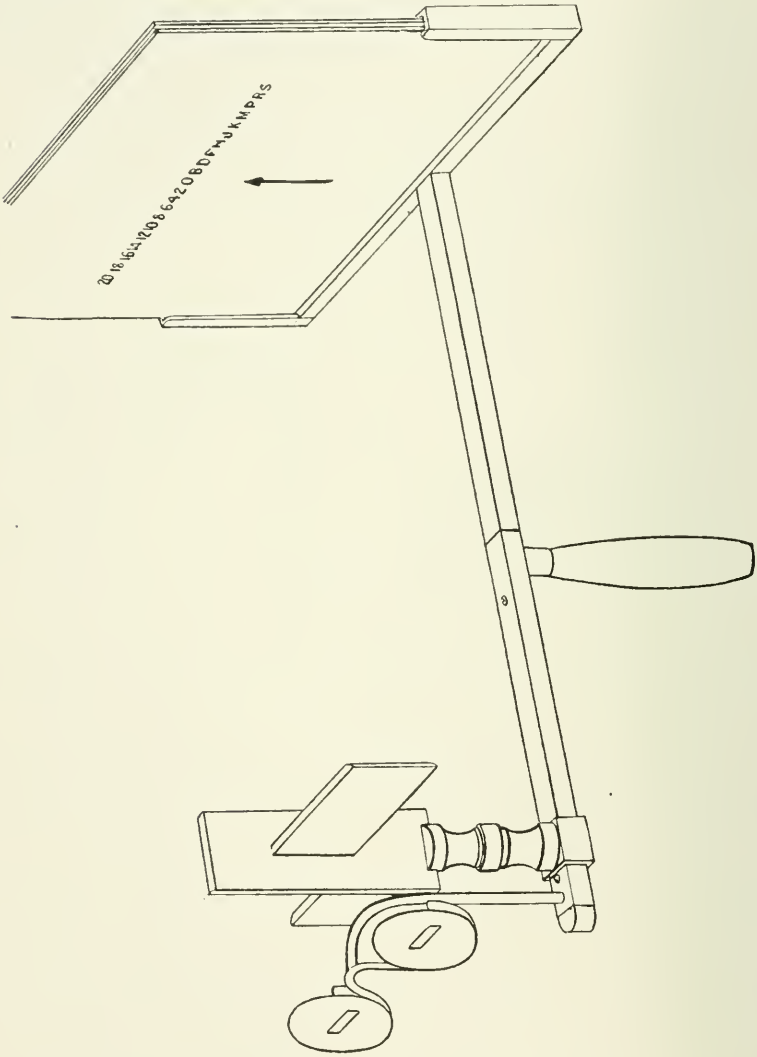

The "Wing Test" as Used for Measuring Horizontal Heterophoria.

For measuring horizontal deviations it employs the tangent scale on a card with an arrow at zero. This is placed on a sliding frame like a stereoscope. The eyes are dissociated by two horizontal rect-

angular "wings" in place of prisms, the lower edge of one being about on a level with the upper edge of the other.

Thus the field of vision is cut in two horizontally and these fields glide tangentially against each other's edges in a direction opposed to the deviation of the seeing eyes. The patient looks through two horizontal slits in an attached eyepiece, and the wings are carried on a pillar allowing of swinging around so as to transpose the fields for verifying the test. To measure hyperphoria a similar arrow is used, pointing horizontally toward a vertical line of figures; and the column carrying the wings pushed to the middle of the base and revolved so that the wings are replaced by a vertical broad bar.



The Walton Phoria-Meter.

For cyclophoria with vertical lines a line is employed on the card and a rubber band is strung across the card parallel to the line. Now place the wings longitudinally and away from the observer's eyes; the printed line will be seen with one eye and the thread with the other. The elastic band is fixed in a groove on one edge of the card and the free end is rolled into a position of parallelism with the line. The degree of lack of parallelism may then be read off the scale which is printed on the unfixed end. This in millimetres is the numerator of a fraction, the denominator of which is the breadth of the card in millimetres. And this fraction multiplied by 100 gives the cyclophoria in prism diopters. The use of this instrument shows that the measurement of cyclophoria by vertical lines nearly always differs in amount from its measurement by horizontal lines. This variation is due to what Helmholtz describes as the difference between the apparent and the real vertical meridians of the retina.

A second factor enters where there is oblique astigmatism, and in these cases the discrepancies will be less when the meridians of maximum curvature diverge, and will be increased when they converge above.

The Walton phoria-meter is another near vision muscle test which is shown in the illustration. To use the instrument have the patient hold it in front of his right eye with the green light on chart vertical. Have light on the left side so it will illuminate the chart, also the red and green arrows through the opening shown in the side of tube. The patient will readily explain the position of red and green arrows, as it is related to the diagram on the chart, which will indicate immediately the amount of imbalance.

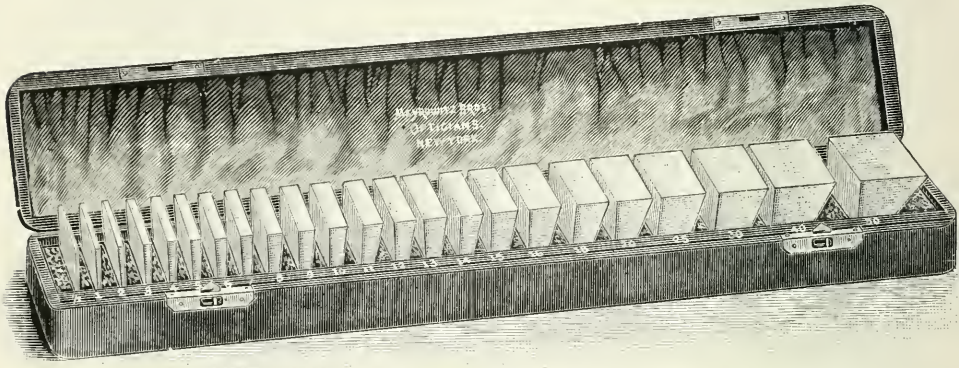

Prism Case and Prisms.

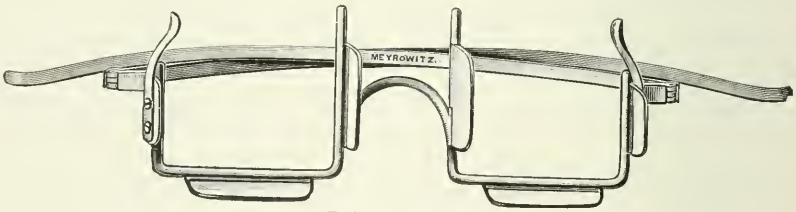

Prism Frame.

Fusion power and its measurement. We know that in all cases where the visual axes at rest are not parallel there will be a diplopia for distance. Diplopia at the near point would regularly occur whenever the eyes were not in a position of equilibrium at that point. In other words, every conceivable lack of balance of the extrinsic ocular muscles, and every refractive error, would produce more or less diplopia, unless nature had provided some means of compensating for her defects. This compensation is provided by the fusion power which is presumably in abeyance in normally-balanced eyes, but which, in the presence of diplopia, imparts an extra stimulation to the muscles necessary to correct it.



Gould's Prism Battery.

(Consists of 20 pairs of prisms, running from 1 to 20 degrees, arranged in reversible bars so that their bases may be turned either in or out.)

While the determination of the position of rest and equilibrium depends on our power to abolish fusion, the series of tests of the compensatory power of the eye depends on its highest stimulation. No matter how good the condition of the muscles, fusion will not occur if the retinal stimulation be so slight that the image in one eye can be easily suppressed. To bring out the utmost fusion power the vision in each eye must be made as perfect as possible.

The convergence test is ordinarily done by finding the strongest prism before one eye, the base being toward the temple, with which the patient can see a flame single at twenty feet. The examination is begun with a 10 or 15 degree prism, the strength being increased until double vision occurs. Normal adduction is from 30 to 50 degrees.

Risley's Prism.

Divergence tests are made in a similar manner, except the base of the prism is held toward the nose. The abduction is found to vary in normal eyes from 5 to 10 degrees. The relationship between the adduction and abduction is the most important point to ascertain, and it should be—as 3 to 1.

Batteries of prisms, mounted on a frame have been proposed for making these tests and one designed by Gould is shown.

The Risley rotary prisms are made up of two prisms rotating in opposite direction by means of a set-screw on their frame. When their apices coincide their strength is 30 degrees, and when the apices are opposite they neutralize each other. This great time-saving apparatus, which is shown in the illustration, is used by placing it in an ordinary trial frame and proceeding as with the single prisms of different strength.

The *Hardy-Van Slyke dynamometer* is a very efficient instrument for testing the dynamic power of the extrinsic muscles. It may also be used for exercising the muscles as well. The name dynamograph would be as appropriate as dynamometer, as it practically registers

automatically the strength of each extrinsic muscle tested, so that its power may be compared with the power of its united opponents. See illustration under **Dynamometer** in this volume.

The phoro-optometer (see illustration) is one of the newer instruments which combines in one practically all the devices for making muscle tests, as well as a trial frame for refraction. It is very ingenious and a great labor-saver.

The clinoscope is an instrument which has been devised by Stevens for measuring the torsion of the eye ball. Stevens, in describing this instrument, states that several subjects of much importance in physiological optics have presented difficulties to investigators, and

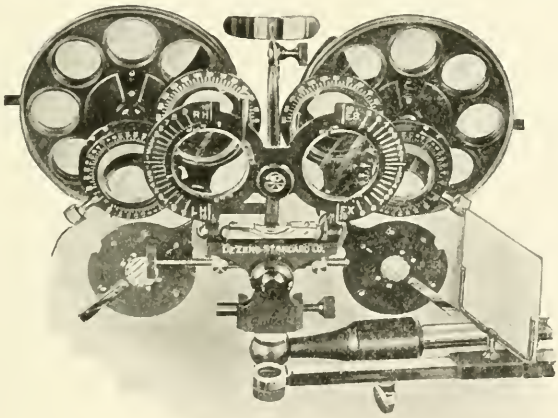

The Phoro-optometer.

have been viewed from radically different standpoints by distinguished authorities, because of the absence of definite and sufficiently accurate methods of examining the phenomena on which the investigations have turned. Among these controverted questions is that of the actual direction of the apparent horizontal and vertical meridians of the retina.

The doctrine of a declination of the vertical meridians, as indicated by the experiments of Volkmann, and as accepted by Helmholz, has not been received by some other investigators with unquestioned assent.

Researches of Stevens in this interesting field have led to the construction of an instrument of precision, which will prove of value in this inquiry and in inquiries allied to it.

The instrument, called the clinoscope, consists of two cylindrical

tubes, each about three centimetres in diameter and fifty centimetres in length. The tubes are mounted on a brass platform, which holds them firmly in the same horizontal plane, at a distance of 6.5 centimetres between the centres at a fixed point. The attachment to the platform permits the tubes to be adjusted in parallelism, in convergence, or in divergence in the plane of the platform. The platform is attached by a movable joint to the upright standard, so that the instrument may be given any desired dip; and a scale and pointer



Clinoscope of Stevens.

indicate, as in the case of the clinometre, the dip with respect to the horizon.

The tubes are caused to rotate upon their longitudinal axes by means of thumb screws, as seen in the figure, and the pointer and scale above the tubes mark the rotation with accuracy.

At the proximal end of each tube is a clip, in which, if desired, the observer may insert a glass for the correction of his refraction, or any glass from the trial case. At the distal end is another clip and provision for maintaining the precise position of the diagrams to be used in the investigation. These diagrams are haploscopic figures,

calculated to aid in the various experiments which may be made. These may be varied according to the wish of the investigator.

The second figure represents two pins, one to be seen by each eye. As the trained observer looks into the tubes, the two tubes and the two pins blend as one, and the head of the long pin now appears in the middle. An adjustment of the tubes by rotation on the long axis will show the true direction of the meridian, vertical or horizontal, according to the position of the diagrams, of each eye upon the scale above the tubes.

For testing the ability of the eyes to rotate upon the antero-posterior axis (torsion), a straight line running across each disc (see fig.) is the

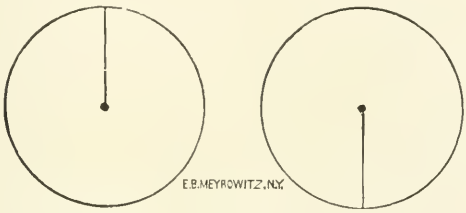

Pins, Seen in Clinoscope of Stevens.

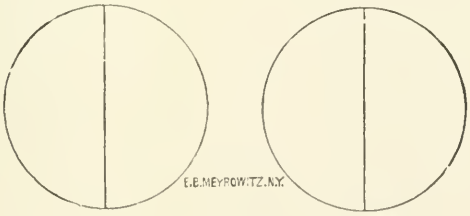

Lines, Seen in Clinoscope of Stevens.

most useful figure. The lines may be placed vertically or horizontally. It will be found that the rotating ability is much greater when the lines are vertical.

The clinoscope is primarily an instrument for physiological research, but as a practical instrument it has been found of much value in determining the declination of the meridians in paralysis of the eye muscles, and in anomalous adjustments of the eyes in respect to the horizontal visual plane; and those who may be interested in determining the power of torsion, or who hope to increase the torsional ability by exercise, will find the clinoscope a correct measure in the first case, and an efficient aid in the second.

Voluntary motions of the eyes. These consist of movements of the eyes to one side or the other, or up and down, or combinations of these

movements. When the individual gazes at objects directly ahead, the optical axes are kept parallel by the fusion instinct, but in the extreme rotations, an impediment is presented before one eye in the shape of the nose or cheek or brow so that binocular vision is impossible and the extreme rotation occurs without the usual limitation interposed by the necessity of binocular vision. As the rotations of the eye in these conjugate movements are much greater than in any other, since they can be made of each eye singly without regard to the other, and since they are voluntary, their movement is the truest test of the individual muscles of the eyeballs.

The linear measurement is a rather crude test which will only detect the gross variations from the normal and can only be applied to the lateral rotations.

The patient is directed to first look as far to the right as possible and then to the left as far as he can. The surgeon notes whether the margin of the cornea passes or falls short of the respective canthi. Or a little more accuracy may be attained by placing a mark on the lower lid showing the position of each margin of the cornea.

The measurement of motility by the aid of the perimeter is a much more exact method. When using the perimeter for this purpose the result is usually spoken of as the "*field of monocular fixation.*"

Casey Wood has described a method for accomplishing this result with the perimeter which is very simple and easy to carry out. In describing his method in the *Journal of the Am. Med. Assn.*, Nov. 28, 1896, he states:

"Instead of using objects attached to the carrier on perimeter arm I have used an exceedingly simple device whereby the rotation of the globe in any direction is rapidly measured. It may be used by all persons who can read Jaeger XII at 50 centimetres, and may even be employed for others whose visual acuity at that distance is considerably less. Four strips of unglazed parchment paper have printed on them words of two letters placed between, as well as below, figures representing the degrees of latitude on the perimeter arc. These strips are, together, placed in position on the arm of the perimeter, the patient's head being in the primary position (I usually do not consider any elaborate fixation necessary) and he is asked to read the lower line, as far away from the centre as possible. This accomplished he is requested to give the figure placed above the words just recognized and to try and read, farther out, additional letters on the figure line. Each word beyond represents about one degree on the scale and the number of words so read, added to the previous figures, gives the limit, in degrees, of the field in that direction. As each quadrant of

the circle is passed over a slip of paper is removed, revealing the next paper, whose lettering, being different, suggests nothing to the person under examination. I have found that instead of making the vertical letters face up and down one can accomplish the purpose of distinct vision by printing them with a type of a bolder face, thus providing for those rare cases in which it is desired to test the muscles of an eye that cannot read Jaeger XII or thereabouts.''

The most accurate method of determining the rotations of the eyes is by means of the Tropometer. This instrument is the invention of G. T. Stevens and is shown in the figure on p. 1415, Vol. II, of this *Encyclopedia.*

It consists essentially of a telescope in which the inverted image of the examined eye is found at the eyepiece, where, either as an aerial image or as an image upon the ground glass, its movements can be accurately observed. A graduated scale in the eyepiece permits every movement of rotation, in any direction, to be exactly measured. A prism or a diagonal mirror at the objective end of the telescope permits the observer to sit at the side of the observed. By means of a head-rest and an adjustable stirrup with a wooden bar, which the observed holds closely between the teeth, the head may be held firmly in the primary position. This position is indicated by the two buttons at the extremities of the guiding rods.

In order to master the method of using this instrument the operator must first thoroughly understand the scale as illustrated. The long line between and at right angles to the shorter line divides two similarly graduated scales running in different directions; the larger circle represents the outer border of the cornea, the edges of which are in contact with the two strong lines; the interval between each pair of short lines of the scale is ten degrees of arc, commencing at the strong line in each case. If now the head of the person examined is held firmly in the primary position and the eye caused to rotate strongly in a given direction, the arc through which the border of the cornea passes may be accurately read upon the scale. In the figure the curved dotted line represents a new position of the border of the cornea.

Suppose that the person examined has been directed to look strongly upward, then the cornea has moved down the scale and reaches the point in this example of 40 degrees, that being the measure of this rotation. By means of the small lever the scale can be placed horizontally, vertically or obliquely, and by means of the two graduations measurements in opposite directions can be made.

If it is desired to determine the upward rotation the border of

the cornea is made to coincide with the strong line which appears in the upper part of the scale at the right hand.

The adjustment is made by means of the milled head at the side of the standard. As the eye rotates up, the image moves apparently down. In determining the downward rotation the strong line at the lower left-hand side of the scale is taken as the point of departure.

For lateral rotation the scale is turned to the horizontal position and the corresponding strong lines used as before.

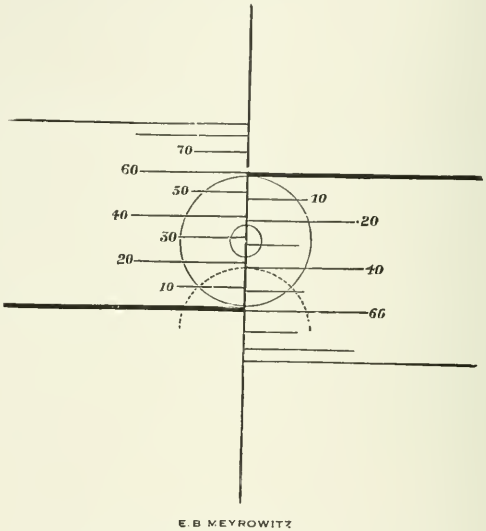

Graduated Scale of Stevens' Tropometer.

In order to adjust the upper border of the cornea on the line, it will generally be necessary for the examiner to place the left hand upon the forehead of the patient and make gentle traction of the upper eyelid by the thumb. This application of the hand to the forehead is advisable in all measurements, as by this means the examiner is able to detect even a slight movement of the head, which would vitiate any measure of the rotation. In adjusting the head to the head-rest, the teeth should be closed and the line of the upper lip just below the nose should be in a vertical line below the glabella or ridge just above the root of the nose.

The *measurement of fatigue of ocular muscles* has been treated very carefully by Lucien Howe in the *Journal of the American Medical Association,* Sept. 21, 1912, Section 2, Page 1023. He states that the object of this study is to obtain a record written by the ocular

muscles themselves of the fatigue which they develop under various circumstances. This, with the expectation that the data thus furnished will enable us to separate more clearly the factors which, when grouped together, have been called "eye-strain."

The autographic records referred to were made by a modification of the ergograph. This is a piece of apparatus well known to physiologists, and described in all of the text-books on that subject.

"More than twenty years ago an Italian, Mosso, measured the fatigue produced when a given group of muscles contracts repeatedly. To the last phalanx of one of the fingers he attached a sort of glove, from which a string extended horizontally over a pulley, and to the other end of which a weight was attached. Each contraction of the finger required a given amount of work to lift the weight. The extent and character of these contractions were registered on a receiving drum.

"Such tracings made by the leg muscles of the frog, or of some other cold-blooded animal, usually give the most typical pictures.

"Although these tracings are familiar to every student, there is one point about them, not always mentioned in the text-books, that is of clinical importance. It is known among physiologists as the 'Treppe,' or 'staircase.'

"As long ago as 1865 Ranke said: 'Everyone knows that the first twitch of a muscle is not its greatest. With stimuli uniform in strength, the later contractions are stronger than the earlier ones—a phenomenon the reason for which has heretofore been wholly obscure.'

"The term, 'ophthalmic ergograph,' is apparently the best for an instrument which measures the fatigue of the ocular muscles. It is nothing more than a combination of some appliance for producing fatigue of those muscles, together with a revolving cylinder or drum on which the degree and frequency of the muscular contractions can be registered.

"The most common form is an arrangement by which prisms are adjusted to the revolving drum. Such prisms measure only the fatigue of the extra-ocular muscles when the point of fixation is a candle, point of light, or similar object situated at least 6 metres distant. In this way efforts of accommodation in emmetropic eyes are eliminated. When the prisms are turned with their bases out, and measurement therefore is made of the action of the adductor groups, the arrangement can with propriety be called an adductor, or 'convergence ergograph.' Or, if the prisms are turned with their bases in, up or down, the same instrument becomes an abductor or divergence ergo-

graph, or a superductor or subductor ergograph, according to the direction of the prisms.

"The convergence ergograph is constructed as follows: A pair of Crété prisms (the original form of the Risley prism) is fastened by two clamps to the upright which supports the revolving drum. A delicate rod of brass is attached, near one end, to the pointer which slides over the drum. The other end of this rod, extending horizontally

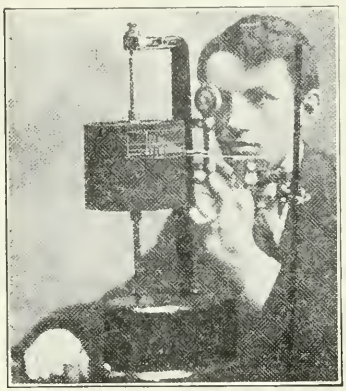

Ophthalmic Ergograph in Use.



Revolving Prisms as Arranged by Crété for Use in the Ophthalmic Ergograph.

outward toward the drum, terminates in a point which records when there is blackened paper on the drum. Or, if a suitable pen is made fast at the end, this pen records when there is white paper on the drum.

"The blackened paper having been attached to the drum, the tracing point is made to touch the paper, and the drum is revolved once to mark the zero line around the drum. The pointer on the handle which slides along the scale is then pushed up to the mark indicating a prism-strength of 10 degrees, and a second horizontal line is run

around the drum. Other horizontal lines are made to indicate a prism-strength of 20 or 30 degrees. Or, if great exactness is desired, we run other horizontal lines also at 5, 15, 25 degrees, or even at shorter intervals.

"The person under examination is placed opposite a distant candle-flame, or preferably a point of light in a Thorington chimney. The head is held steady, or if the subject is restless we may make use of the ophthalmic head-rest. It is better, however, to do away with this or any superfluous appliances whenever possible. The drum is then moved into place. Experience has shown that the most convenient position for the subject is with his right eye looking through the prism, which is then arranged to measure adduction. As he does so he should see the distant light distinctly, and there should, of course, be nothing to obstruct the view with his other (uncovered) eye.

"All preparations having been thus completed, the lever of the drum is released and the reading begun. The individual under examination himself, or the one who is directing the experiment, then slowly pushes up the pointer which is on the handle of the prism-case, thus increasing their strength. At the same time the examiner asks the subject to note whether he sees one light or two. As long as only one light is seen, the index is pushed up slowly but regularly. The moment two lights appear, the subject says 'two.' The pointer is drawn down promptly, the strength of the prisms at once reduced to zero, and the subject sees only one light.

"Again, a second time the pointer is pushed up slowly and regularly, thus increasing the strength of the prism until the subject says 'two.' Immediately the pointer is drawn down, the strength of the prism reduced to zero, and the subject sees only one light. This is done a third, fourth, fifth time, and so on. Not infrequently we find that a group of muscles which appears to be practically exhausted, suddenly and for some unknown reason seems to regain strength and the power of overcoming stronger prisms returns in response to renewed effort. Usually, however, the fatigue returns sooner than before, and sooner with each succeeding return of strength. These variations in power are examples of a Treppe.

"At first glance it may seem incongruous to associate an apparent excess of strength with a pathologic condition. But as spasm of accommodation can be distinctly diagnosed by appropriate tests, and as Schmidt-Rimpler and others consider that certain degrees of such spasm are quite common, so do we meet occasional instances of spasm of accommodation with esophoria of quite high degree. And in these cases, when we take tracings with the convergence ergograph, we are

apt to find a condition of 'excessive convergence with the fatigue long delayed.'

"In insufficient convergence with rapid fatigue we find a low power of convergence which promptly shows fatigue and soon passes into a condition of exhaustion.

"Another type is that in which the power of convergence is small at the beginning. The fatigue begins promptly, but, unlike the last, does not pass on to exhaustion. On the contrary, we have the same ability to continue short contractions for a long time as is found often in strong and healthy subjects.

"Also, we have unusual variations in the same individual at different times, apparently as the result of treatment."

Variable pathologic tracings are sometimes found. "In some of these we find that the first few contractions point to the strong-muscle type. But as the contractions are repeated, the muscle soon begins to 'run down.' In other words, the condition is suggestive of that in which an apparently strong man succeeds in lifting a rather heavy dumb-bell, but after one or two efforts fatigue shows itself. Such muscles are weak rather than strong.

"This condition is usually associated with one in which an apparent fatigue is followed almost immediately by the ability of the muscle to contract, at least for a few times, with considerable strength. Such muscles furnish examples of the Treppe.

"This ergographic method of measuring ocular fatigue gives us entirely new and apparently important data concerning the continued action of different groups of muscles. It shows us, for the first time, how fatigue occurs under normal conditions—what different types we may expect and what variations are not unusual.

"We can now measure and record not only the initial strength of certain groups of muscles, but how long a given action can be continued without marked fatigue. In this way, by resolving the complicated problem which we call 'eye-strain' into its different factors, there is more hope of solving it."

It is always of importance to ascertain if the patient under examination has true *binocular vision.* The best known test for this faculty is the "*bar reading test of Javal.*" It is performed by having the individual read a book, and at the same time a pencil or, as Priestley Smith suggests, a thin strip of metal, is held midway between his eyes and the printed matter. Reading can then proceed without interruption, only, if both eyes are employed, for if he is fixing with one eye alone there will be a certain point where the line of vision of that eye will be interferred with. At that point there will be a hitch in

his reading which would not occur if he were using the other eye at the same time, for that eye would have a clear view of the letters which the first eye cannot see.

Roche (*Annales d'Oculistique*, January, 1908), furnishes us with a test for binocular vision which, by its very simplicity, is likely to disarm all suspicion on the part of the patient. It is carried out as follows:—

Take a board 33 centimetres or more in length—an ordinary blotting-pad does very well—and place it horizontally on a level with the patient's eyes, with one edge resting on the bridge of his nose. Then at a distance of 25 centimetres from the patient's eyes, place a small pellet of paper or a crumb of bread on the upper surface of the pad,

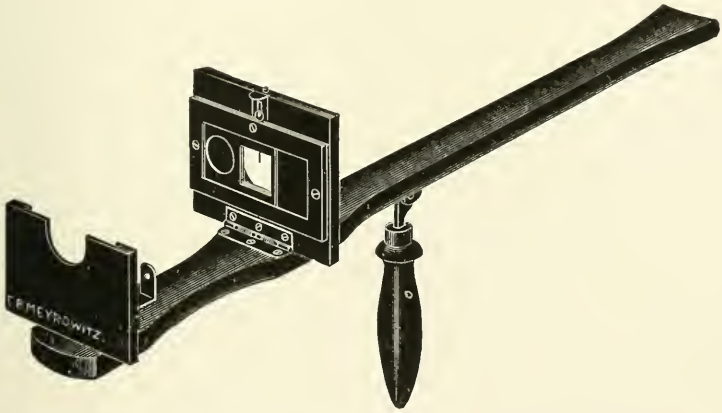

Diaphragm Test for Binocular Vision. (Bishop Harman.)

and request the patient to touch it by bringing the point of a pencil or knife vertically down on it. Anyone possessing binocular vision can do this with the greatest ease, but those having only monocular vision will inevitably fail.

As the one-eyed may accidentally succeed once or twice it is well to repeat the experiment several times, varying the position of the pellet on the board.

It is easy to detect deliberate deception by the fact that the point of the pencil is then brought down haphazardly on different parts of the board, whereas the genuine one-eyed would always bring it down on a line joining the pellet and the pupil, i. e., the point would always fall in front of or behind the pellet, never to the right or to the left of it.

The Bishop Harman test (*Ophthalmic Review*, April, 1909), is the

reverse of the bar-reading test. Instead of a bar which the patient's eyes must negotiate, there is a screen with a single hole in it; through this hole the patient can look with both eyes; quite naturally, and without suspecting the manner in which his vision is being dissected.

The test rests on a phenomenon that occurs to every one many times daily; when a window is looked through the man with binocular vision sees more widely than he who has but one eye. To demonstrate the

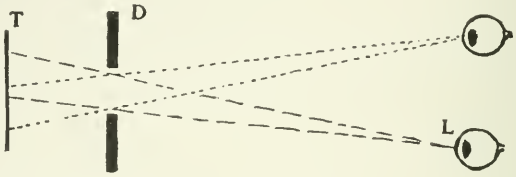

Diaphragm Test for Binocular Vision. (Bishop Harman.) T, Test card; D, Diaphragm with hole.

principle of the test the following experiment may be made: Stand facing a wide view, hold up both hands, palms toward you, six inches from your face, and on a level with the eyes, the hands being separated so that the little fingers are distant from each other three fingers' breadth. It will be found that the hands cover the eyes, yet a perfectly clear perception of the view is obtained. But if one eye be closed half the view is lost, for the right hand obscures the direct

Diaphragm Test for Binocular Vision. (Bishop Harman.) T, Test card; D, Screen with hole; P, Position of patient, who looks in direction of arrow; H, Handle.

vision of the right eye and the left hand that of the left eye; but the eyes see cross-wise through the space between the hands. The paths of the vision and the manner in which right and left monocular and binocular vision is arranged are shown in the accompanying figure.

The instrument made to apply this test in practice is very simple, but a series of most varied and surprising tests may be made with it. They are so simple that the operator is not likely to be tied up in examining a patient, yet they are so subtle that when an expert is sub-

mitted to the test he can only escape confusion by stating simply what he sees.

A length of wood like a flat ruler 44 cm. long is fitted with a rack at one end to receive the test cards, and a screen measuring 9x6 cm. fixed at 11 cm. from the rack. In this screen, or diaphragm, a hole is cut; it is either square or round and measures 1.7 cm. square or diameter. A moveable pin is fixed to the diaphragm so that it can be projected into the hole as a point of fixation in certain experiments. A handle is fixed beneath the base board.

In use the patient takes hold of the handle with both hands and places the free end of the rule (this is washable) against the upper lip just beneath the nose. The surgeon stands facing his patient and holds the other end of the instrument to keep it steady. When the instrument is in position the patient is asked to look either through the hole, or at the pointer projecting into it, according to the test desired, and to tell what he sees through the hole.

There are three sorts of test cards: 1. Printed matter, of any size from diamond in set paragraphs to canon in paired capitals. 2. Black or colored squares variously disposed. 3. Pictures for children. A number of test cards are issued with the instrument but the surgeon can make and vary them indefinitely.

The diaphragm which is composed of the screen with the square hole is most generally useful; for the reading tests particularly, and when we wish to demonstrate the presence of binocular vision where it is denied. When the patient looks clear through the hole at the test, the margins of the hole are seen doubled, the square becoming an oblong; this change escapes remarks save by the most observant. On the other hand when it is desired to demonstrate weakness of binocular vision or in fusion experiments the round hole is the better, as reduplication of the circle and overlapping of the two images is very noticeable.

The test is of value for the following purposes:—

1. To determine the equality of visual acuity in the two eyes.

2. To determine the presence, the absence, or a defect of binocular vision.

3. To exercise the vision in squinting eyes.

4. To detect malingerers feigning monocular blindness.

5. To demonstrate certain physiological phenomena connected with the perception and suppression of images.

A paragraph of printed matter is put in the test rack, the patient is desired to read it. The plan of the instrument is such that three kinds of vision are required to pass the test. The right half of the

test is read by the left eye, the left half by the right eye, and the middle strip by both eyes. If the patient can detect no difference in the clearness of the letters on the card the eyes have equal vision. The test is very delicate. Further, this cannot be passed unless there be good balance of the oculo-motor muscles.

The preceding test when small type is used is the most delicate one of this nature, a small degree of latent squint will prevent a man from reading the paragraph accurately. The phenomena produced by the various orders of latent squint can be best shown by the use of the test card with a single line of letters or figures. The man with good binocular vision reads 1234 with the right eye, 6789 with the left, and 5 with both eyes.

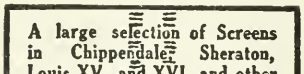

Diaphragm Test for Binocular Vision. (Bishop Harman.)
(The dotted lines indicate the overlapping of the crossed images of the square hole.)

Diaphragm Test for Binocular Vision. (Bishop Harman.)

In latent convergence (esophoria) the middle letters are overlapped and are suppressed so that the man reads something like this:—

126789

In latent divergence (exophoria) the middle letter is reduplicated, and the man reads:—

12345 56789

In latent vertical displacement (hyperphoria) the parts of the line of letter seen by each eye are on different lines or levels, thus:—

12345
56789

All these phenomena can be seen by the surgeon himself who has perfect binocular vision, when he causes disturbance of his muscles

by putting a prism before one eye, or more simply by displacing one eye slightly by gentle pressure with one finger. It is astonishing how readily this simple device displays latent irregularities in the muscle balance of the eyes.

In the case of children suspected of squint, their capability for binocular vision can be ascertained by the diaphragm test more easily and at an earlier age than by any other means. There are a series of bold and simple drawings of familiar objects supplied with the instrument. The child looks at a pair of pictures through the hole of the diaphragm, if they are named promptly there is good evidence that the vision of one eye is not suppressed.

Monocular alternate fixation and binocular fusion can be practised through a series of graded tests, from colored patches, pictures, and large letters to small print. When one eye by reason of disuse has a lesser visual acuity than the other, the superiority of the better eye can be reduced by paralyzing the accommodation of that eye with atropin, by shading the half of the tests to be seen with that eye, or by placing such a glass before that eye as will reduce the vision to an equality with the weaker eye.

As a detector of malingering the test may be used in the following manner: There are test cards with squares printed thereon, colored, red and green, or black for use with the color-blind. The squares are printed right and left, any number may be used, but one each side is enough and the patches are on different lines so that they cannot be fused by convergence.

The cards are reversible, so that the red and green ones can be exhibited four different ways: red to right, to left, above, or below.

One of these cards is put in the rack, and the patient asked what he sees. (1) He may be told to look through the hole, then he sees the patches as they are on the card and must name them. Suppose, an extreme improbability, the man knows the patches are seen by crossed vision, and correctly evades naming the patch seen by the pseudo-amaurotic eye: yet he does not escape, for the surgeon watching the man's eyes will see the coordinate movements of the eyes as he looks from one to other area of crossed vision. A man truly blind of one eye does not do this.

(2) He may be told to look at the pointer and so converge, then he gets homonymous diplopia for the patches and one appears above the other. When seen in this latter fashion it is impossible for the patient to guess whether one or other eye, or both eyes, sees the patches; even the cards may be changed so that the red is seen by the right and left eyes alternately, yet the change will not be detected.

The tests are so good that there is no objection to the patient seeing all the test cards laid out on the table before-hand. During the testing the surgeon has the man's eyes under perfect observation, at the suggestion of a wink on the part of the man the test can be dipped and obscured.

Lastly, even when the eyes differ considerably in visual acuity the test with colored patches can be used successfully, for color can be perceived when form is obscure.

There is one test with this instrument in which very curious results may be obtained. On one half of a test card is drawn a cross of St. George, on the other half is drawn a cross of St. Andrew. The crosses are placed in such relations that when the test is in position and the pointer is set in the round hole of the diaphragm and the two eyes are fixed upon it, the images of the crosses are superimposed and fused.

Diaphragm Test for Binocular Vision. (Bishop Harman.)

Now for a moment the fused images of the crosses present the appearance of a star of eight points. But it will be found that this appearance is not constant for the whole time of the observation; there succeeds an alternation in the perception of the images seen by the right and left eyes, so that as though by an electric flashing sign the crosses of St. George and St. Andrew pulsate upon the screen. The experiment can be varied by the use of a variety of geometrical figures, parts of circles, etc.

The effect is very curious, and the seemingly definite rhythm of the alternation suggests some reason for the phenomenon. There are two possible explanations: 1. That fixation is not constant, and that unconsciously it falls off, but is renewed when the fading of the images occurs. 2. That since in perfect binocular vision the two maculæ and the two halves of the brain have learned to view and perceive but one object of fixation at a time, the brain is now incapable of retaining constantly the perception of two dissimilar objects seen by the two maculæ. The brain does it for a moment, at the instant of the first attempt, but then the image of one and then of the other object is perceived and suppressed in turn. We may suppose the visual apparatus reverts to a primitive separated condition!

Ophthalmometry. In 1854 Helmholtz first described *ophthalmometry* in his paper "Über die Accomodation des Auges." This article gave a detailed description of the ophthalmometer as well as results of investigations conducted with the aid of the instrument. This original ophthalmometer described by Helmholtz is really a modification of one of the forms of the heliometer and consists of a telescope having in front of its objective two plates of glass, with parallel plane surfaces, placed side by side, so that each plate corresponds to one-half of the objective. So long as the two plates lie in the same plane, only a single image is seen through the telescope; but when the plates are rotated in opposite directions, the rays emanating from the object are separated into two bundles, and two images are seen, the distance which separates these two images increasing with the angle through which the plates are turned. When the rotation of the plates is such that the two images of a linear object are seen exactly in contact, end for end, the distance by which the two images are separated is exactly equal to the length of each image; the amount of displacement of the two images may then be calculated from the angle made by the plates with the axis of the telescope.

This method, which was originally employed by astronomers in the measurement of small angular distances, as in the case of double stars, has the special advantage that it does not require complete immobility of the object to be measured.

The *first practical ophthalmometer* was constructed by Laurent and consisted of a small inverting telescope mounted on a tripod, one of the feet of the tripod sliding in a groove in the board which serves as a base for the instrument. The telescope can be adjusted to the level of the examined eye, by means of a set screw situated in the sliding foot, which lowers or raises the telescope. The lateral adjustment is attained by moving the whole tripod from side to side on the board. A doubly-refracting prism placed between two convex lenses makes up the compound objective of the telescope.

Ophthalmometry was really brought to its position of a fixed science and its true importance shown by the investigations and inventions of Emile Javal and his pupil H. Schiötz. They developed an instrument which could be used in an ordinary consulting room and which would almost instantly record the difference between the horizontal and vertical meridians, as well as measure and register the radius of curvature of the cornea.

There are several different models of ophthalmometers in use today but they are all based on the same optical principle as the original

ones. An understanding of this principle makes the operation of any ophthalmometer clear.

For all practical purposes the anterior surface of the cornea may be considered as a convex mirror and we know that reflections from a convex mirror are reduced in size. The reflection of a white disc or circle in a concave mirror would be perfectly round, but larger, while in the convex it would be smaller, but still round. If, however, the mirror were more curved in one meridian than in the other, the reflection of the circle would be no longer round, but oval, and the greater the difference in the curve, the more oval the reflection. The disc of Placido is based on this principle and was used for diagnosing astigmatism, very early in ophthalmology. The patient was seated with his back to a window while the observer held the disc in such a way that he could see its reflection in the cornea and watch for any distortion through the aperture in the centre. This would show plainly any irregular astigmatism and also any high degrees of regular astigmatism, but the flattening of the circle was so slight as to be imperceptible in slight variations. The next step was to place in the aperture a prism so arranged that the observer would see a double reflection, the edge of one disc just touching the other. If the reflections were perfectly round, by rotating the instrument one circle would seem to roll around the other with their edges in perfect contact. If, however, the reflections were even a trifle elliptical, they would separate in the meridian of sharpest curve and overlap in the flattest. Even the slightest overlapping or separation would show some corneal astigmatism and it only remained to work out the details for observing and measuring the amount of variation to give us the ophthalmometer. Two illuminated mires are used to indicate the location of the periphery of the imaginary circle and as the instrument rotates, if the circles separate, the mire with the step overlaps on the parallelogram and each step of the overlap indicates 1 dioptre of corneal astigmatism. In order to make the results accurate, a convex lens of known strength is mounted in the barrel so that no clear image can be secured except when the lens is at the exact distance from the cornea.

A portable ophthalmometer has been invented by Thos. Reid, of Glasgow. It consists essentially of an aplanatic convex lens of known focus, a rectangular prism neutralized in its centre by a smaller prism, one side of the rectangular prism being adjacent to the lens, and the circular or other disc being opposite the other side in the principal focus of the lens. When the instrument is placed in front of a convex surface to be examined, with the disc turned toward a luminous body, a virtual image of the disc will be formed at a virtual focus of the

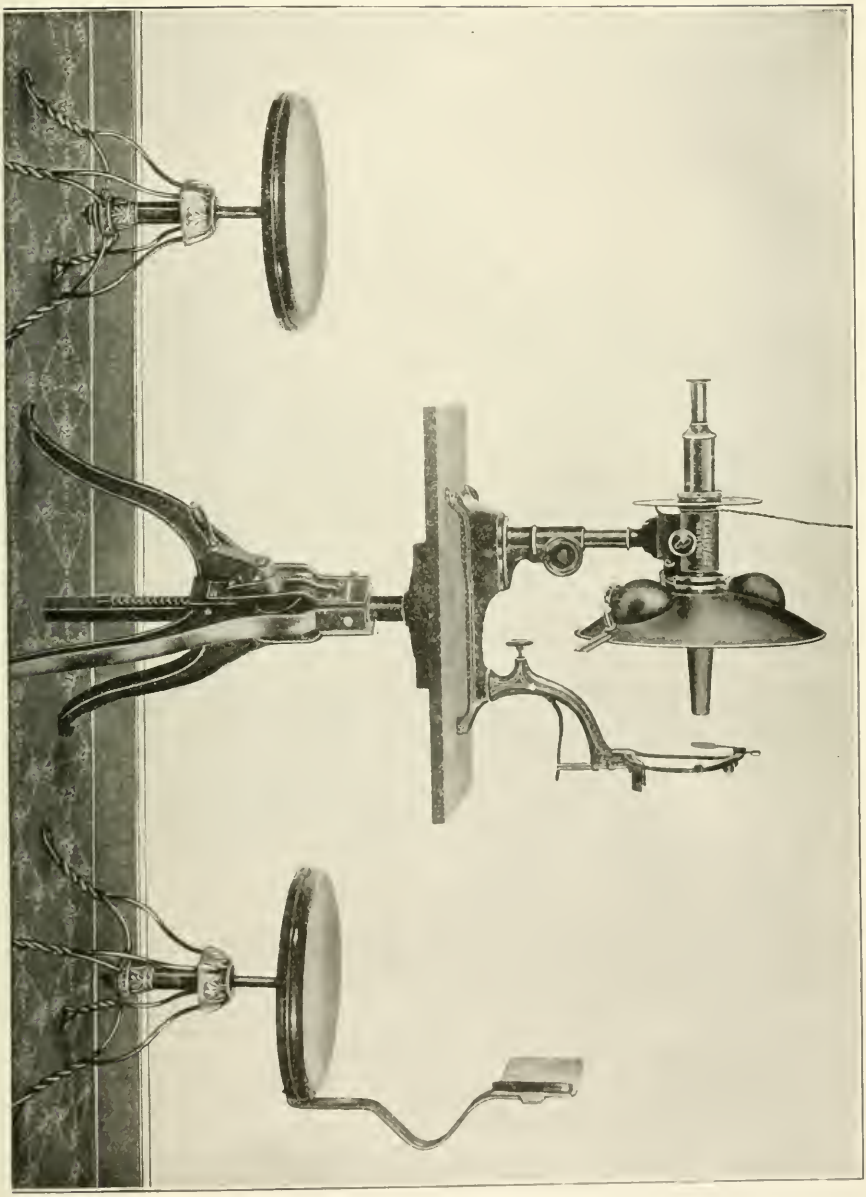

Ophthalmometer in Position; Showing Chairs for Patient and Examiner.

convex reflecting surface. This image will only be seen distinctly by the emmetropic eye, through the neutralized portion of the prism when the focus of the lens in front coincides with the virtual focus of the convex surface. The instrument is held in the observer's left hand, which rests on the forehead of the patient, the disc being directed to a luminous source to the right of the observer.



The Hardy Ophthalmometer.

To successfully operate the ophthalmometer, it is necessary to use the instrument very carefully and precisely. Many incorrect estimates as to the value of ophthalmometry are due to opinions being based on results obtained by inexpert hands. The operation of an ophthalmometer is not a mere mechanical procedure which one person may do as well as another. It is a procedure which requires skill and study, and in which one becomes more proficient after prolonged use; the same as one gradually becomes skilful in ophthalmoscopy by continued practice.

The following rules apply to the use of any of the newer ophthal-

mometers and should be carefully carried out when making an examination.

The illumination is first to be considered and on a clear day the light from a window with northern exposure is sufficient; but bright sunlight should not be used as the bright reflection might cause a reflex closure of the patient's lids. All ophthalmometers today are provided



The C. I. Ophthalmometer.

with electric illumination; either arranged to come from four electric globes and be reflected from the mires or the mires themselves are directly illuminated by globes placed behind them. When light from a window is used the patient's back should be toward the window and no source of light should be in front of the patient.

The cross hairs in the tube should next be brought into distinct view by the examiner. This is done by turning the ocular eye piece to the right, when the observer is myopic, and to left when he is hyperopic.

The further the eye piece can be turned to the left, and a clear view of the cross hairs maintained, the better it is. If there be any dirt in the tube it will be shown by irregularities in the calibre of the hairs.



The "Universal Ophthalmometer."

Place the patient in an easy position, seated and facing the instrument. Then have him place his chin on the chin-rest and his forehead against the head-rest, with his eyes wide open and upon a level. By sighting through the transverse slit just above the telescope, we can adjust the head so that the patient's eyes are exactly horizontal. One eye is now covered by the small shade and the patient is told to look directly into the tube with the free eye. The operator will now focus the eye by sighting along the upper side of the tube, through the

notch, at the centre of the cornea. Next look through the tube and by moving the instrument forward and backward, raising and lowering it by aid of the thumb screw, bring into the field of the telescope, a distinct image, on the cornea, of the disc and mires. A doubling of the disc and mires will be found, due to the prism in the telescope. No attention is paid, however, to the two images far out at the sides, the two in the oval space being the only ones of importance.

The observer now proceeds to the "primary position." This is the point at which the transverse lines, dividing the mires into halves, become exactly coincident so as to form one continuous line. This means (when there is any astigmatism) that we have found one of the axes of the astigmatism. The other axis, in the majority of cases, is 90 degrees from this. It is, therefore, at right angles to it and is the secondary position. If there be no astigmatism present, the transverse lines are always opposite and coincident. If there be irregular astigmatism present, the transverse lines are never coincident and cannot be made so. The start to find the primary position should be from that point at which the long indicator is at 0 degree. If we find the transverse lines are coincident at this point we need proceed no further for the primary position is obtained. If not coincident at zero, the tube is turned from right to left very slowly, until the lines exactly coincide, providing this occurs before 135 degrees are reached. If 135 degrees are reached and the lines have not become coincident, go no further in that direction. Turn the long pointer back to 0 degree and proceed from left to right toward 45 degrees. The lines must necessarily become coincident before 45 degrees are reached. The primary position cannot possibly be farther than 45 degrees on either side of 0 degree if a case of regular astigmatism is being examined. The cross lines of the mires being coincident, we carefully note the position of the long pointer and it becomes only necessary to approximate the mires to be ready for the next step.

The telescope is next turned from the first position to the second position which is obtained by rotating to the left until the long pointer moves 90 degrees to the left of the primary position. It is now found that the mires have either overlapped, meaning astigmatism with the rule, or have separated, signifying astigmatism against the rule.

For example, if the primary position was 90 degrees and the mires have overlapped two steps we would conclude that two degrees of astigmatism with the rule were present, and would note: + 2.00 D. cyl., axis 90° or — 2.00 D. cyl., axis 180°.

But if the mires have separated two steps and if the primary position, for example, should have been 30° we know that there are present,

two dioptres of astigmatism against the rule and record + 2.00 D. cyl., axis 30°, or — 1.00 D. cyl., axis 120° To ascertain the exact number of steps to which the separation of the mires is equivalent, the mires are moved so as to exactly approximate while the instrument is in the second position. It is then rotated back to the primary position and the mires overlapping, the amount of astigmatism can be read off as in astigmatism with the rule.

On the upper surface of the arc carrying the mires, is a graduated measure to show dioptres of refraction. It does not give the hyperopia and myopia of the eye, but simply indicates the corneal curvature. On the clamp of each mire there is a mark which enables one to read at a glance from this graduated arc the total refraction of each meridian of the cornea. It is well to record at least the total refraction of one meridian, preferably the one of least refraction.

If so desired, the astigmatism can be read from the graduated arc by measuring alternately the meridians of greatest and least refraction of the cornea.

The radius of curvature of the cornea is recorded in spaces on a graduated scale, placed on the right of the inner circle of the arc. These spaces number from 6 to 10, each space being divided into ten equal parts. The reading is in millimetres and the amount is indicated by a mark on the clamp of the traveling mire.

One of the newer alterations found in some of the ophthalmometers is an arrangement whereby both mires are made to move at the same time by turning a thumb screw, fixed on the graduated arc.

There are several factors which operate against absolute accuracy in the results obtained by ophthalmometry. If the anterior and posterior surfaces of the cornea were exactly parallel, and its substance of the same refractive index as the aqueous, we could consider the cornea and aqueous as practically a single powerful convex lens, and the ophthalmometer would be a very exact means of estimating its power. This, however, is not the case. The cornea we well know is thinner in its centre and even the anterior surface is more convex at its centre than at the periphery. It is also not infrequent for both surfaces (anterior and posterior) to have separate astigmatisms of their own. The aqueous humor also possesses a slightly lesser density than the cornea, causing a slight refraction to take place between the two. Therefore, even under the most favorable conditions, the examination is liable to result in a regular error of from one-half to one dioptre. In fact this discrepancy has been noticed so regularly that Burnett has formulated a rule which in the main is correct, and which if adhered to would minimize mistakes. As formulated by Burnett

the rule states: "For the total subjective astigmatism, subtract 0.50 D. from the corneal astigmatism when it is with the rule, and add 0.50 D. if the corneal astigmatism is against the rule."

In *irregular astigmatism* the ophthalmometer becomes a very valuable assistant in finding the axes of the meridians of least and greatest corneal curvature, as well as the amount of astigmatism. In these cases it is impossible to bring into a continuous line, the two lines bisecting



The Souter Ophthalmometer.

the mires, but the overlapping and separating of the mires gives a clue to the axes of the meridians of greatest and least curvature.

It is sometimes extremely difficult, or may even be impossible, to measure the vertical meridian of the cornea of patients with deep-set eyes, overhanging lids or long lashes.

In making the examination we often notice the mires separate and then overlap again, at times when the apparatus is entirely stationary. This is due to movements of the eye under examination, causing dif-

ferent parts of the cornea to come into view. As it is hard for many individuals to hold the eye perfectly quiet for a prolonged length of time, it is always best to make ophthalmometer readings as rapidly as possible.

A new ophthalmometer designed by Souter has been announced by Meyrowitz (Special Bulletin, August, [illegible]) which it is claimed can be used for measuring not only the astigmatism of the cornea, but also both anterior and posterior surfaces of the lens. The optical system consists of the birefringent quartz prisms and achromatic objectives of Javal and Schiotz. The prisms may be moved to or from the eye according to whether the cornea, or anterior, or posterior surface of the lens is to be examined. This has the effect of altering the doubling value.



Mire of the Souter ophthalmometer.

The mires are of a new design, specially adapted to this work. In measuring the lens surfaces, the glass front of the mire is raised as shown in the picture. This discloses lamps with circular filaments which are intercepted by a tongue of metal at one point of their peripheries, forming letters C with the openings toward each other. This is the image greatly magnified by the cornea which is seen on the lens.

The method of measuring the lens curvatures is almost identical with the procedure for measuring corneal astigmatism, and the instrument is provided with three scales, indicating respectively the corneal, anterior surface and posterior surface readings. The amount of the astigmatism can be estimated by the overlap or separation of the mires, or by reference to these scales.

The instrument has been put to a practical test in over 1,000 actual refractions, and the manufacturers state that it has been found entirely dependable.

Refraction. A reliable means of determining not only the kind of refractive error but the amount of it is by retinoscopy. Its ordinary

[illegible]

[illegible]

[illegible]

As soon as the direction of the shadow has been determined convex glasses, if the patient is emmetropic, myopic less than one diopter or hypermetropic, and concave glasses if the patient is myopic more than one diopter, should be placed in the spectacle frame in front of the patient's eye and increased in strength until that glass is reached which reverses the movement of the shadow.

The two principal meridians of the eyeball, usually the vertical and horizontal, should in this way be worked out separately. If the same lens reverses the shadow in each meridian we have simple hypermetropia or myopia, as the case may be. If it is a hypermetropia, say of three diopters, it is recorded as follows:

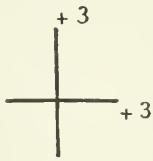

Skiascopy Results in Simple Hypermetropia.

If myopia, as follows:

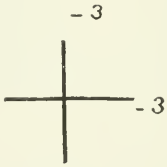

Skiascopy Results in Simple Myopia.

As the observer is one metre distant from the eye under examination (the distance of the point of reversal of a myopic eye of one diopter) that amount should be subtracted from the result in hypermetropia and added to the result in myopia. In other words, in the skiascopic result, the hypermetropic eye is over-corrected and the myopic eye under-corrected one diopter in each meridian. The results should then read, to give the real state of things:

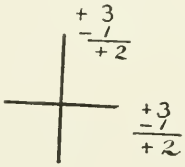

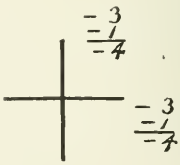

In the first instance the patient is farsighted to the extent of two diopters; in the latter myopic four diopters. If a spherical convex lens

of + 2 diopters, or a spherical concave of — 4 diopters were placed in the trial frame before the eye, the full amount of the hypermetropia or myopia would be corrected and the correction would, in each case, make the patient emmetropic and give him the best vision.

We have seen that in regular astigmatism the refraction in the two principal meridians is unequal. When, therefore, the point of reversal is found in one meridian, that at right angles to it is still uncorrected. The lenses should now be adjusted so that the shadow in this other meridian is reversed. The difference between the two meridians gives the amount of the astigmatism.

In the retinoscopic result the meridian of least error corresponds to the axis of the cylinder employed to correct it, and this, in the majority of hypermetropes, is in the vertical meridian, usually indicated by 90 degrees; while in myopia it is in the horizontal meridian (or at 180 degrees).

In simple astigmatism the reversal of the shadows might be represented as follows:



Skiascopy Results in Simple Hypermetropic and Simple Myopic Astigmatism.

Adding —1 (the point of reversal of a myopic eye of one diopter at one metre) to each meridian the formula to be placed in the trial lens in front of the eye would read:

+ 1 D cyl. ax. 90°
— 3 D cyl. ax. 180°

In compound astigmatism the reversal of the shadows would be as follows:



Skiascopic Results in Compound Hypermetropic and Compound Myopic Astigmatism.

Adding —1 (the point of reversal of a myopic eye of one diopter at one metre) to each meridian the formula to be placed in the trial frame in front of the eye would read:

+ 1 D sp. + 1 D cyl. ax. 90°
— 3 D sp. — 1 D cyl. ax. 180°

In mixed astigmatism one meridian is myopic (usually the vertical) and that at right angles to it is hypermetropic (usually the horizontal) a concave lens, say of 2 D being used to get the reversal of the shadow in the former while a convex lens, say of 3 D is used for a like purpose in the latter meridian. The skiascopic result would read as follows:



Skiascopic Results and Correction in Mixed Astigmatism.

Adding —1 D (the point of reversal of a myopic eye of one diopter at one metre) to each meridian, the result should then read to give the real state of things:

The lenses to be placed in the trial frame before the eye may be either one of the following:

1. Using crossed cylinders, as follows:

— 3 cyl. ax. 180°
+ 2 cyl. ax. 90°

2. Using a convex sphere and a concave cylinder:

+ 2 D sp. — 5 D cyl. ax. 180°

3. Using a concave sphere and a convex cylinder:

— 3 D sp. + 5 D cyl. ax. 90°

In mixed astigmatism the sum of the two results gives the amount of the astigmatism, because a convex or concave spherical lens placed in front of the myopic or hypermetropic meridian produces just as much more myopia or hypermetropia, as the case may be, in that meridian, and requires the addition of a concave or convex cylinder of such strength to correct it.

The axonometer (see illustration) has been invented by Thorington, to aid in finding the exact axis subtended by the band of light while studying the retinal illumination, after the meridian of least ametropia has been corrected.

In using this instrument, it is placed in the opening of the trial frame, and accurately adjusted, so that the cornea of the eye to be refracted occupies the central opening. When the lens is found which corrects the meridian of least ametropia, and the band of light appears distinct, turn the axonometer slowly until the two heavy white lines

accurately coincide, or appear to make one continuous line with the band of light. The degree mark on the trial-frame to which the arrow-head at the end of the white line then points is the axis for the cylinder.

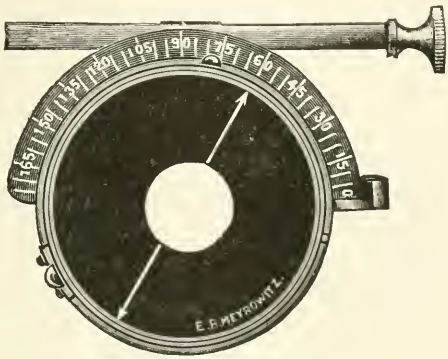

The Axonometer.



The Macnab Retinoscope.



The "Standard" Electric Retinoscope (De Zeing).

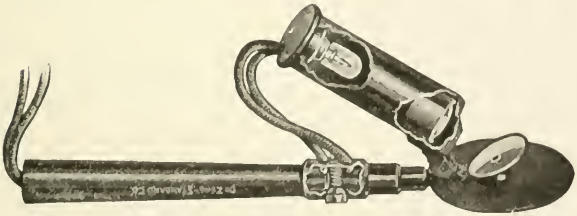

"Regular" Electric Retinoscope Equipped with Thorington Plano Mirror.

A *new retinoscope* has been described by Angus Macnab (see figure) in which the mirror, instead of being plane or spherically concave, is

cylindrical, and the effect on the illuminated area of the fundus is to produce a band of light instead of an image of the lamp.

By means of milled wheels the mirror is allowed to rotate and the band of light on the fundus can be made to lie in the axis of the astigmatism when such is present.

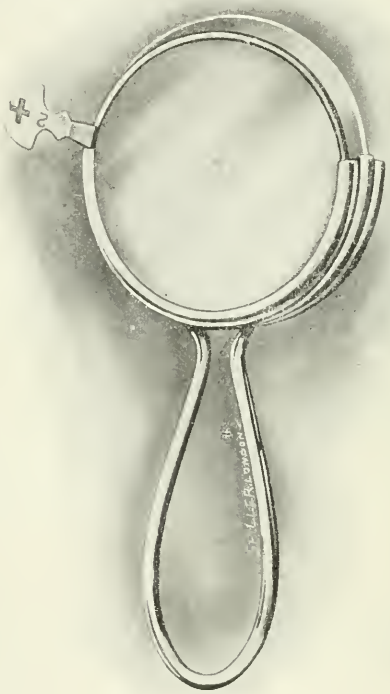

The Simplex Retinoscope.

It is claimed that after very little practice the location of the axis can be made to within five degrees, a matter of great importance in examining young children.

Electric retinoscopes of several different varieties have been designed and are gaining much in favor. They are much easier of manipulation than the ordinary instrument and two models are illustrated herewith.

The simplex retinoscope is a convenient form devised by William Ettles, F. R. C. S. As shown in the accompanying illustration, it is a neat little instrument with looped nickel-plated handle attached to

three grooved holders, in the centre one of which is fixed a plane mirror $1\frac{1}{2}$ inches in diameter.

By placing a plus 1.50D sphere, in the front cell, the mirror acts as a concave mirror of 33 cm. focus. The light having undergone two refractions and the observer being accommodated by the glass (one refraction) for the indirect image, it forms an admirable ophthalmoscope for indirect examination.



Würdemann Skiascope.



Marple's Skiascopic Racks.

Any focus of the mirror can be obtained by putting one lens in front and a neutralizing lens behind. Thus a plus 2.00D = 25 cm. and minus 2.00D behind gives clear vision.

The observer can always correct his own ametropia with the necessary lens in the front cell. If he likes a weak convex mirror he can put a minus 0.50D in front, and so on.

A time-saving method of doing retinoscopy is by the aid of batteries of lenses, mounted in frames, and held in front of the patient's eyes by the patient himself. They afford the convenient means of changing lenses before the patient's eyes; the examiner simply directs the patient to move the rack up or down as desired. A ridge along each side protects the lenses from coming in contact with the patient's face, while



Geneva Retinoscope and Ophthalmoscope Combined.



The "Wigmore" Roll Top Test Cabinet.

permitting the lenses to be brought as close as possible to the eye. Two models of these instruments are shown.

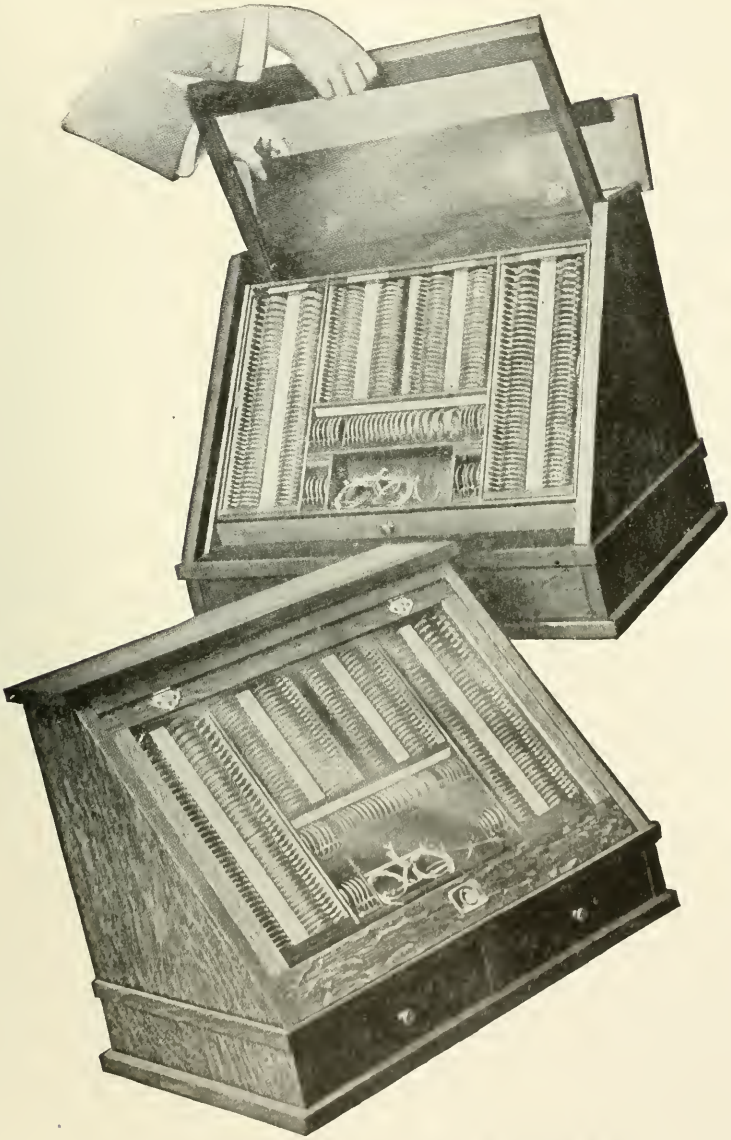

A Convenient Trial Case made by F. A. Hardy & Co.

R. W. Doyne (*Ophthalmic Record*, July, 1910) has designed a set of trial lenses for use in the dark room while making retinoscopy tests.

These lenses are set in frames made with various marks on the rims and handles of different shapes, so that by merely feeling the rims or handles one is enabled to ascertain the strength of glass used, thus obviating any necessity for examining the lenses by sight.

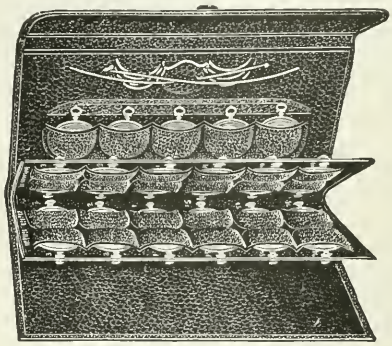

Folding Pocket Trial Case.



McCormick Portable Trial Case.

Several retinoscopes have been designed during the past few years, which have the retinoscopic mirror fitted to a stationary apparatus which also contains a series of lenses, a source of light, and a head-rest for the patient. They are also so made that they may be used for ophthalmoscopic examinations. One of the latest models, the Geneva, is illustrated.

After completing the objective refraction of the eyes the surgeon corroborates his findings by the subjective test, that is, the use of the trial frame and lenses.

Attention is first drawn to the matter of lens trial cases. These outfits are now made in most complete and elaborate style. They contain all the different apparatus needed, including trial frames, prisms, colored glasses, diaphragms, lenses, etc., all neatly and compactly arranged in proper cases. The "Wigmore" cabinet shown in the illustration is one of the very complete outfits. Several other trial cases are



The "A. O. Co." Traveling Style Trial Set.

shown, among which is a practical folding pocket case, containing an assortment of the most commonly needed lenses.

Messrs. C. W. Dixey & Son, of London, have constructed a trial case set in accordance with the specifications of Ernest Clarke, which contains spherical and cylindrical lenses in eighths of a dioptre to 1.00 D., in quarters to 5.00 D., and in half dioptres to 20.00 D. This extensive assortment of lenses, together with prisms, etc., is contained in a case, measuring 26 by 22 inches.

As a valuable addition to the completeness of the trial lens set, the folding tinted lens combination (see figure) is an important asset.

The recognized value of tinted eye-glass and spectacle lenses has led to their general employment, and oculists are frequently consulted as to the proper shade to be worn. The set of "fronts" making up the trial set illustrated herewith, are of great value in assisting the physician and his patient in determining what color gives the best result in any particular case.

The frames, four in number, are of hard rubber and contain one pair each Amber No. 1, Amber No. 2, Euphos No. 1 and Euphos No. 2. When not in use, the set can be folded into small compass.

Folding Tinted Lens Set.

The first lenses used for ophthalmic purposes were numbered according to the radius of curvature of the tool on which they were ground, both surfaces having the same curvature. With the glass commonly employed in them it happened that for such a lens, the number indicating the radius of curvature in inches also indicated approximately the number of inches of the principal focal distance. In such a system the strength of the lens was necessarily expressed by a fraction—one divided by the focal distance of the lens. Thus, the 18-inch lens had a strength of 1/18.

In combining lenses in practical work, it becomes necessary to add and subtract the strengths of the lenses combined. Such calculations must be made repeatedly for every eye that is tested, and the difficulty

of adding and subtracting fractions make it a matter of serious importance.

Minor objections to the old system of numbering were the variations of inches in different countries, and the irregular intervals in the series.

In order to avoid these objections *the dioptric or metric* system of numbering lenses was adopted. In it the unit is a diopter—the focusing power required to bring parallel rays to a focus at a distance of 1 metre. Each lens is numbered by its strength, in whole numbers or in decimal fractions, which can be added or subtracted like whole numbers. A lens which has a focusing power that will unite parallel rays at 1 metre being called a 1 diopter lens. A lens having twice this strength is called a 2.D. lens, and has a focal distance of ½ metre. One having only a quarter of the unit of strength is a 0.25 D. lens, and has a focal distance of 4 metres; and so on throughout the series.

In *using the test lenses* they are placed before the patient's eye, in the test frame, to find the lens or combination of lenses with which he sees best. This might seem to be a very simple procedure not requiring any special skill, and yet to arrive at accurate results one must exercise great care, system, skill, and good judgment.

Many different styles and shapes of *trial frames* have been made. A successful frame should be as light and as comfortable as possible. It should be so constructed as to allow of free adjustment in every direction.

One of the newer designs is that described by F. T. Rogers and shown in illustration. This frame consists essentially of two steel plates joined at the center by extension pieces which are toothed inside to form a double rack. By placing a pinion between these two racks, we secure an adjustment for the interpupilary distance, but in addition to this, the pinion may be pushed up or down in the rack to bring the bridge to the required height. These details are easily comprehended by a reference to the cut.

The rack and pinion being carefully made and adjusted, the two sides or eyes of the trial frame are rigidly held in their true relation with regard to each other. The trouble experienced with many frames in that the axis scales soon lose their true value, has been absolutely removed from this frame. In spite of its solidity and rigidity, the frame is light in weight.

To accommodate every possible combination of lenses, each of the cells is arranged to securely hold four lenses, the main body holding two lenses of any foci (except the very strongest), with pins in front holding the third lens and a cell in the rear holding the fourth lens.

Another frame which is very efficient is the "Tosswill," which can be best understood by consulting the illustration.

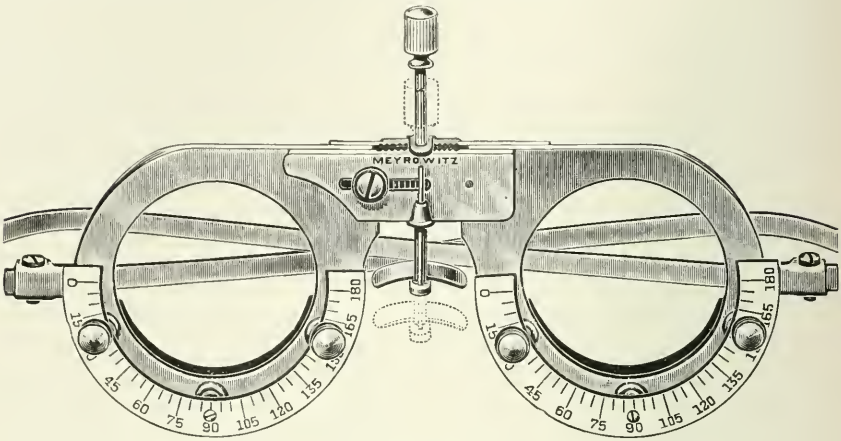

Rogers Trial Frame.

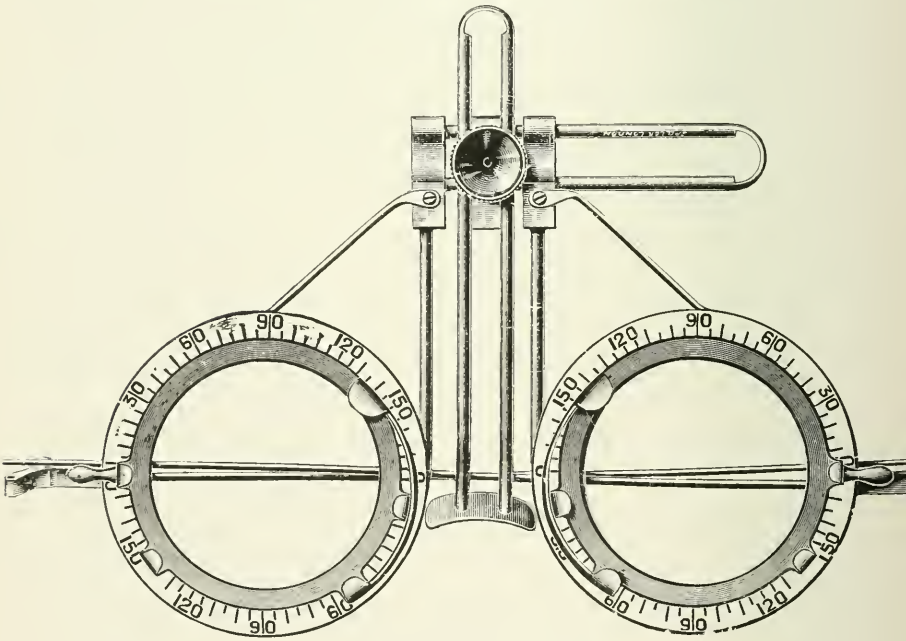

Tosswill's Trial Frame.

The "California" trial frame is one which is a distinct departure in its construction from the frames now in use. By consulting the illustration it will be seen that in place of resting on the nose and

ears, the frame is hung in front of the eyes from a head band, which extends over the top of the patient's head.

The "Light Weight" trial frame is made of a white composition which is a close imitation of ivory, with the scale markings engraved



The "California" Trial Frame (Baers).

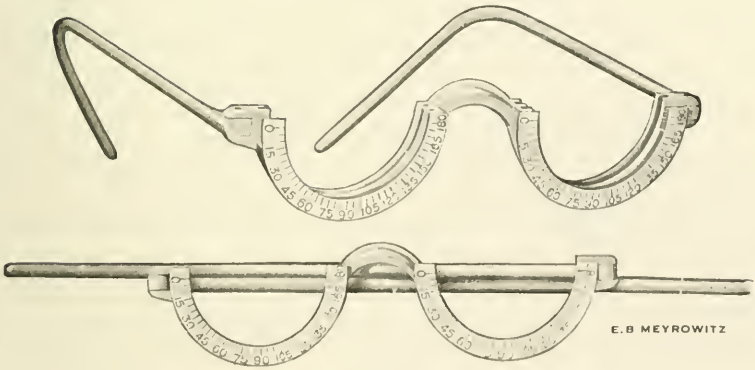

The "Light Weight" Trial Frame.

thereon and filled in black. It is very light in weight and comfortable to the patient.

Several instruments have been invented to take the place of the trial frame and test lenses. They contain batteries of lenses so mounted that they may be revolved into place in front of the eyes to be ex-

amined. In addition they are usually equipped with all muscle testing apparatus.



The De Zeng Refraction and Muscle Testing Apparatus



The Ski-optometer.

Two of these instruments are illustrated: the De Zeng, which has rather large discs containing many lenses, and the "Ski-optometer," which has fewer lenses that work on a neutralizing principle to secure the many different lenses needed in estimating a refraction.

A number of different instruments for estimating refraction have been designed, which are founded on entirely different principles than the use of the test lenses or combinations of lenses.

At the present time none of them has to any great extent been brought into general use by physicians. Three of these instruments—the "Punctumeter," the "Ophthalmo-Axonometer," and the "Dioptrometer"—will be described and illustrated and the claims advanced by their inventors will be given.

The punctumeter (see illustration) was first designed by J. G. Huizinga, but the instrument now in use has been greatly modified by F. A. Hardy & Co. The instrument is what its name implies, a point measure. With it the punctum remotum (far point of distinct vision) and the punctum proximum (near point of distinct vision) are quickly found. If an eye has two puncta remota (astigmatism) it locates each of them and the meridians in which they lie.

The makers claim that myopia, hyperopia, presbyopia, astigmatism and the amplitude of range of accommodation can all be measured and recorded in diopters and fractions of a diopter, thus doing away with distance measurements. It consists of a tube ten centimetres long, into one end of which is inserted a plus lens. Two cells for holding trial lenses are attached to the other end of the tube, one of them being graduated, enabling the operator to place the axis of cylindrical lenses in the proper meridians. A bar upon which is mounted a sliding target operated by a rack and pinion is attached to the end of the tube carrying the lens. This bar also carries a supplementary slide which can be fixed at any point on the bar by a set screw.

The bar is square and is graduated on three sides, the graduations being equal (a new feature in optical instruments). For every unit of motion a unit of refraction is shown. The graduations are in diopters and fractions of a diopter. At 0 on the right side of the bar is established an absolute infinity, 0 being located at one principal focus of the lens, and when operating the eye is placed at the other principal focus. Myopia, hyperopia, astigmatism and the amplitude of range of accommodation are read on the right side of the bar, the graduations being 0 and the lens representing myopia (near sight) and those beyond zero hyperopia (far sight). The top of the bar is graduated in years, from the age of twenty to that of sixty, the amount of normal accommodation for each of these years being shown on the right side of the bar opposite the year.

The left side of the bar (stamped reading glasses) is graduated to show the dioptric power of a plus lens required for reading or near

work, the graduations being for a distance of one-third of a metre. They are by eighths of a diopter from 0 to 3D, and by half diopters, from 6 to 10D, and by whole numbers, from 10 to 18D, enabling the operator to refract cases requiring lenses of any power from 0 to 18 diopters.

The amount of accommodation possessed by minors at different ages (from 10 to 20 years) is stamped upon the top of the bar.

In speaking of the *Ophthalmo-Axonmeter* the inventor states that the instrument is a simple, scientific apparatus, constructed in accordance with sound optical principles, designed to reduce the subjective chart tests to the acme of simplicity and accuracy, and to prove all tests.



The Punctumeter.

Its principle is two-fold:

1. The scaling down of the distance type and fan chart to a range of a few feet, and still preserving the requirements of the standard visual angle.

2. The substitution of the focal length of the lens for the actual lens, itself.

Its mechanism is as follows (numbers refer to cuts):

1. (1) is a three cell, monocular trial frame made to be revolved by (3) and scaled on (2).

2. A plus 8. D. Lens in the observing telescope (4) makes the far point of an emmetropic eye scale at 12.5 centimetres from the optical centre of the lens, and this far point is scaled as (zero) on the upper beam (5).

3. A dial (7) made to be revolved in order that the fan and type chart (7-2) and cross perpendicular line chart (7-1) may be alternated before the telescope (4), at the will of the operator, is ranged over a dioptric scale on (5).



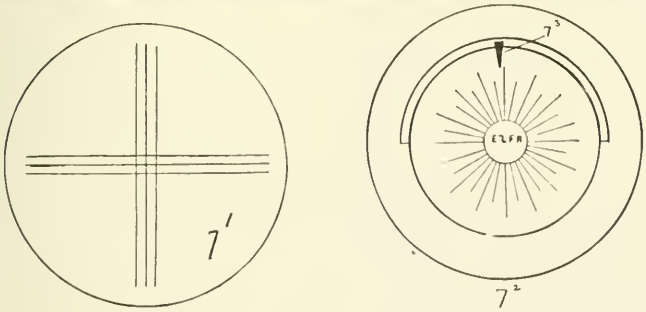

The McLaughlin Ophthalmo-Axonmeter.

4. Fan and type chart (7-2) and cross perpendicular line chart (7-1) are scaled down to coincide with the 12.5 centimetre distance. An emmetropic eye at the telescope will read the type at zero and the fan will appear uniformly black.

5. By sliding the dial (7) backward and forward, according to the gradations engraved on the beam (5), plus and minus correction is obtained of the dioptric values indicated.

Upon the above simple basis, the instrument is operated for the detection of and estimation of refractional errors, precisely as one would use the 6 metre type and trial case, merely sliding the dial instead of changing the lenses before the eye.

In the estimation of astigmatism, as soon as the most convex meridian is found, by means of the fan chart, and registered by the axis indicator (7-3), the other side of the dial is turned (with one set of the cross lines on the same axis as the indicator), and it will be found that the cross lines present the two main visual meridians of the observing eye. When the focii of these two meridians are found, by means of the linear scaling on (5), the correction is, of course, the difference between the two focal points as scaled on (5).



The Rogers Dioptrometer.

While it does not purport to be all sufficient (no monocular testing instrument ever can be this, for the obvious reason that all monocular tests must be verified with binocular verification at the trial case) it does claim to prove all diagnoses by means of standard test lenses when placed in the cells (1) at the eye, as by this measure the far point of any aberrant eye is shifted to the normal far point on the scale beam (5).

The inventor of the "Rogers dioptrometer" states that the scientific principle upon which the non-magnification of the instrument depends is best understood by assuming that within the outer housing there are twin opera-glasses reversed and placed end to end, so that the magni-

fication of one of them is exactly neutralized by the reduction of the other, and this relationship is not violated by any adjustment.

Its astigmatic measurements are made by means of a pair of cross-cylinders, perpetually at right angles to each other, but which are rotatable for axial positions and separable for introducing cylindrical values. The lenses are all of such value as to make the scales in centimetres, but they are scored and read in the standard units—diopters.

Since any position of the combined cylinders does not magnify, different positions of the two for the measurement of astigmatism do not distort the object. Astigmatism is not only measured perfectly, but the corrected chart is symmetrical, as it appears to a normal eye.

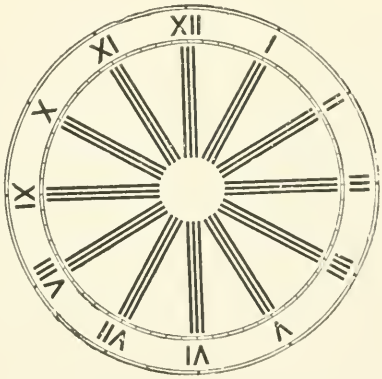

Clock-face Astigmatic Chart.

In beginning the refraction of a patient the first procedure is to properly adjust the trial frame to his face. The frame should always be placed as near as possible to the patient's eyes and the centres of the lenses should be opposite the centres of his pupils. When a spherical lens placed before an eye improves the vision, it should not be changed for another unless the vision is made better by having its strength increased or diminished by placing in front of it another sphere (plus or minus) of lens strength. Spheric lenses are always tried before using cylinders, and the vision brought as low as possible with a sphere before combining a cylinder. After the spheric lenses have improved the vision as much as possible, *the astigmatic chart* may be brought into use as a guide to recognize the astigmatism.

Many forms of astigmatic charts have been devised but they all work on the same principle and are for the purpose of finding the position of the principal meridians. As a rule, the most distinct lines correspond to the most ametropic meridian.

F. H. Verhoeff has described two new astigmatic charts which differ in some important respects from the sun-ray figure, the various charts of green and the radiating lines in groups of three of Wallace. One of the new charts is intended solely for determining the axis, the other primarily for estimating the amount, of astigmatism. Chart 1

Pray's Astigmatic Letters.

Diamond Astigmatic Chart.

consists of a series of wide lines (width 3.75 mm.) radiating from a common centre and placed at 15 degree intervals. These lines are crossed by concentric narrow lines (width 1.1 mm.), forming a series of circles separated from one another by equal intervals of 6.5 mm. The diameter of the disc is 31 cm. The wide radiating lines are designated by numbers 1, 2, 3, 4, 5, 6, corresponding on the right semi-

circle to the figures on a clock face and on the left semicircle to these lines extended. In a chart as published the vertical line above is marked 12, but this number has been replaced by 6 to secure uniformity and avoid confusion.

Chart 2 consists of a disc pivoted at its centre to a square of white cardboard. Two wide lines (width 3.75 mm.) intersect at the center of the disc to form a right angle. Two sets of fine lines of varying lengths are drawn parallel to one of the wide lines and similar sets

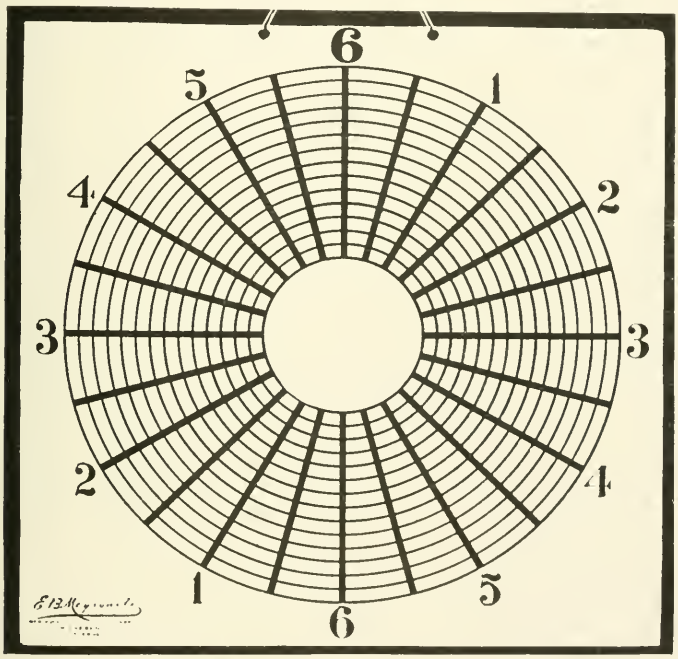

Verhoeff's Astigmatic Charts. Chart 1.

are drawn parallel to the other wide line in such a manner as to form a series of squares separated from one another by a uniform interval of 6.5 mm. Short marks on the white cardboard indicate axes from 0 to 180 degrees at the usual 15 degree intervals.

In examining a patient without cycloplegia the lines are blurred with a suitable sphere, either + or —, in accordance with the spherical error in the case. The patient's attention is then directed to Chart 1 and he is asked to select the blackest or most sharply defined of the wide lines. The selection of this line is rendered easier by the fact that the fine lines crossing it are precisely the ones that are most

blurred. Conversely, the wide line at right angles is seen to be especially blurred in contrast to the sharply outlined fine lines crossing it.

The patient is then directed to view Chart 2, which has been rotated to bring one of the wide lines in the axis as determined by Chart 1. This line will then stand out distinctly against the blur of the fine lines crossing it and, conversely, the other wide line will appear faint in contrast with the sharply outlined fine lines at right angles. Con-

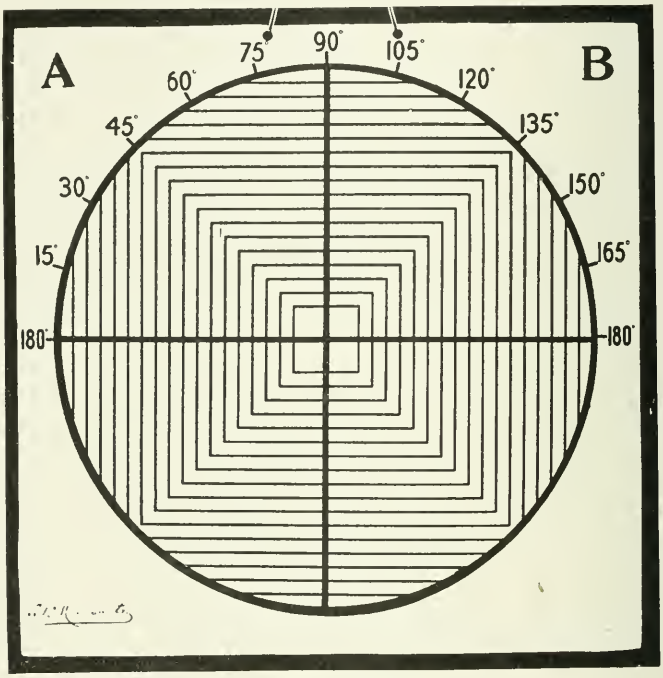

Verhoeff's Astigmatic Charts. Chart 2.

eave cylinders of varying strengths with axes at right angles to the sharp wide line are brought successively before the sphere until the patient is convinced that the two wide lines have been equalized. He is now asked to confine his attention to the quadrants of fine lines and requested to state whether they, too, present a perfectly uniform appearance. As a rule, one pair of sections will be selected sharper than the other, despite the fact that the wide lines appear absolutely uniform. The addition of a + or — .12 cyl. will almost invariably be all that is required to make the chart appear absolutely uniform.

At this point the patient's vision will be found in the neighborhood

of 6/viii. The sphere is then altered to bring the visual acuity up to normal or a little above. Finally, the patient's attention being confined to the lowest line of letters, it will often be found that these can be appreciably sharpened by a slight change in the axis of the cylinder.

Chart 2 may also be used for determining the axis of astigmatism by rotating the disc back and forth until the more distinct of the two lines reaches a position at which it appears most distinct to the patient. Another method, first suggested by Verhoeff, is to rotate the chart until the two wide lines appear equally distinct. The axis will then lie half way between the two lines.

In using Chart 2 Green has sometimes found it a little difficult (especially with children and unintelligent adults) to get patients to understand precisely what they are intended to look for. In such cases he compares the chart to a pie divided into four slices, and asks whether the right and left slices are the blackest or the upper and lower ones. As a further aid toward designating the lines or quadrants when the axis is away from the vertical Verhoeff has placed the letters A and B on the cardboard of the chart to the right and left. He has also found it of advantage to mount Chart 1 on a larger card than that furnished by the publisher in order to designate the lines by larger numerals.

Some patients find it very difficult to concentrate their attention on the quadrants of fine lines, being unable, apparently, to disregard the vivid impression of the wide lines. For such individuals a chart similar to Chart 2, but without the wide lines (the axes being indicated by inconspicuous marks at the periphery only), would be of value.

C. N. Spratt has recorded the comparative results obtained with the use of the charts without cycloplegia and again after the instillation of homatropin 2 per cent. every ten minutes for a period of one and one-half hours. His report, based on the examination of 126 eyes, mostly in the young and middle aged, is as follows: In 75 per cent. there was no difference in the amount of astigmatism before and after cycloplegia. In 20 per cent. the astigmatism after cycloplegia was .25 D. (or less) greater than before cycloplegia. In four cases there was an apparent difference of .37 D. and in one case of .5 D. In the myopic cases 66 per cent. gave the same result before and after cycloplegia. Thirty-four per cent. were undercorrected from .12 D. to .37 D. without cycloplegia. In the hyperopic cases 42 per cent. were fully corrected without cycloplegia; the remainder were undercorrected from .12 D. to 1 D.

Green has had these charts in daily use for the past two years and

has found them eminently satisfactory, so that he has to a large extent discarded others. He is convinced they furnish the best subjective method of determining astigmatism as to axis and amount and are deserving of a wider use than has hitherto been accorded them.

The apparatus designed by Ransom for the one line astigmatic test is very ingenious. It consists of a case 9 inches square by 3 inches deep, actuated by a motor clock, in combination with a dry battery and electric magnet. It is all contained inside the case, complete in itself, and needs no city current to run it. Necessary apparatus, wire and push button are furnished with the instrument, which has simply

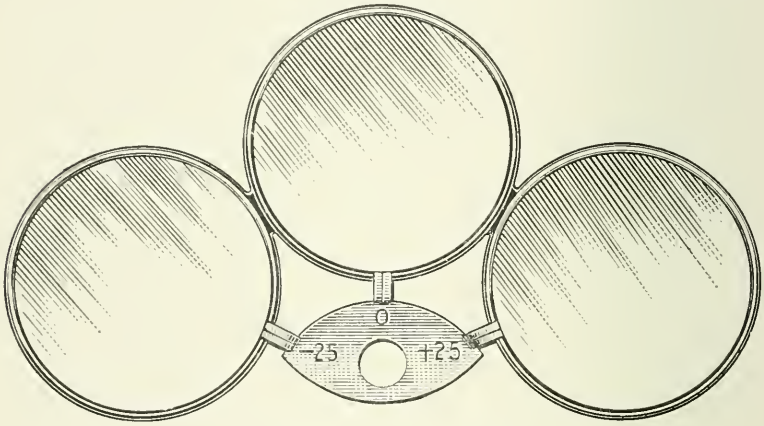

Three Lens Test of H. P. Lakin.

to be hung on the wall, connecting wire extended, the push button placed by side of the operator, and it is ready for use. On the face of the instrument is a paper dial, with a single rubber band stretched across its center. This dial is attached to the spindle of the motor, and will revolve as the operator presses the button, or may be moved through an arc of as little as two degrees, or as many revolutions as the case may demand, in order to locate the defective meridian.

After making sure of the amount of astigmatism present and its axis we may make doubly sure of our result by several methods.

H. P. Lakin has designed a three-lens instrument (see cut), made in both spheres and cylinders, consisting of a plano in the centre and a plus lens on one side and a minus one on the other. These sets are made in strengths of 0.12 D., 0.25 D., and 0.50 D., and are used as a final confirmatory test. The patient is allowed to wear the combination obtained by any means, and asked to read the lowest line possible on the test-card. Then taking the spherical set, pass in succession before

the correction in the test-frame the plus, plano and minus lenses, having the patient read with each, giving an indication, according to which of the three gives best vision, to increase, let alone or decrease the spherical portion of the combination. Make the alteration indicated, and so continue until the plano gives best vision, showing an indication to leave the spherical portion unchanged. Then taking the cylindrical set, hold it so that the axis of the first lens is coincident with that of the cylinder in the test-frame and pass the three test-lenses before it in a similar manner. Make the alteration indicated and so continue until the plano gives best vision, indicating no further change of the cylindrical portion. The examiner may next further confirm his findings by use of the crossed cylinder.

The crossed cylinder (see illustration) was first described by Edward Jackson, but despite its great utility it has not come into as general use as it should. T. B. Schneideman has lately written very clearly on the use of this instrument, and in his article states that the crossed cylinder, as its name implies, is a pair of cylinders of equal strength, one convex, the other concave, placed at right angles to each other. Such a pair of crossed cylinders is, of course, equivalent to a sphero-cylinder. Two such combinations of different strengths made upon the following formulæ are desirable: —0.25 sp. ⁻ +0.50 cyl., and —0.50 sp. ⁻ +1. cyl. These are equivalent to a pair of 0.25 and 0.50 cyls., respectively, one plus, the other minus, placed at right angles to each other. The direction of one axis (the other being, of course, at right angles), and the strength of the cylinder is to be marked upon the glass.

The crossed cylinder is intended to determine the cylinder required in cases of astigmatism. It is to be used as follows: A correction, more or less approximately the right one, is placed in the trial frame. The approximation may be arrived at by the shadow test, ophthalmometer, trial lenses, stenopaic slit, astigmatic chart, etc.

Before proceeding to examination with the crossed cylinder, the approximate correction before the eye in the trial frame is to be tested with plus and minus spheres to make sure that no improvement can be made by changing the sphere.

The crossed cylinder is then held before the eye under examination with one of its axes parallel to the axis of the cylinder in the trial frame, and then turned so as to cause the other (opposite) axis to occupy the same direction. The person under examination is asked to state which of the two directions gives the better vision, i.e., with the plus or minus axis parallel to the axis of the trial cylinder. The latter is then to be changed in accordance with the person's state-

ment. If he states that the vision is better when the plus axis of the crossed cylinder coincides with the plus axis of the trial cylinder, the latter is to be replaced by a stronger cylinder; if the minus axis so coinciding is preferred, the trial cylinder is to be weakened.

If the trial cylinder is concave, the crossed cylinder gives similar indications, i.e., to strengthen or weaken the cylinder according as the correspondence of the minus or plus axis of the crossed cylinder gives the better vision.

After every change made in the strength of the trial cylinder as suggested by the crossed cylinder, the sphere of the trial combination must be re-tested with plus and minus spheres to determine whether it is to be increased or diminished.

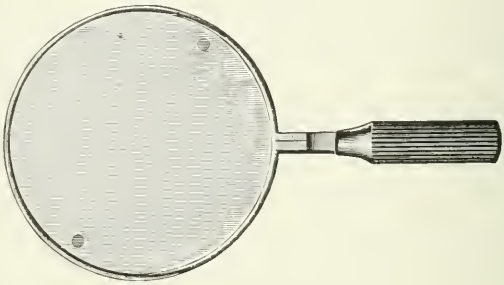

Jackson Crossed Cylinder.

The axis of the trial cylinder is also to be re-tested after any change made in the sphere or cylinder. The examination with the crossed cylinder is to be repeated in the way just described after any change made in the sphere or cylinder until the crossed cylinder leaves the sight unchanged in either position, or when this is not attainable, until the change suggested by it in one direction is, after such change has been made, to be again reversed, i.e., the cylinder is now in equilibrium. The crossed cylinder now indicates that the true cylinder required is midway in strength between two successive ones of the trial case.

Where the best approximate correction is a sphere only and no cylinder seems required, the crossed cylinder is also of use. Held in different positions it may suggest that one meridian is somewhat different: a weak cylinder, say a + 0.25 or — 0.25, is placed in the position indicated, the crossed cylinder will show whether it is to be retained, increased or rejected. Both plus and minus cylinders may be tried successively in axes indicated by the crossed cylinder.

If the approximation is a cylinder only and no sphere seems re-

quired, this cylinder is to be tested with the cross cylinder as before; plus and minus spheres are to be tried after any change in the strength of the cylinder just as if a sphere formed part of the correction. A sphere may be accepted when the correct cylinder has been found.

Of the two crossed cylinders the stronger is useful where the astigmatism is considerable, the changes it indicates being greater. Even in cases where the difference between the meridians is considerable the weaker crossed cylinder may be employed in the final determination.

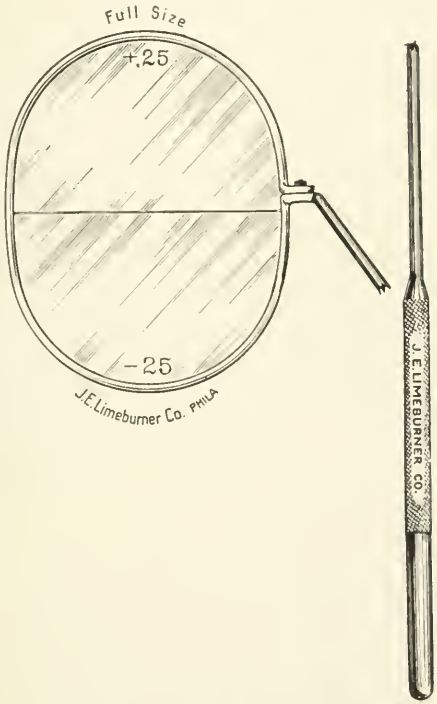

The Rhoads Double Cross-Cylinder.

It is to be borne in mind that the person under examination is not asked whether the crossed cylinder improves the vision—it may even make it worse—but which of the positions is the better, or less bad.

An illustrative case may serve as an example.

Suppose the true refraction of an eye to be expressed by the formula + 1.75 sp. ⊂ +1. cyl. ax. 90°, and that a + 2.25 sp. ⊂ +.50 cyl. ax. 90 has been placed before the eye as an approximate correction; although neither this sphere nor cylinder is the true one, one meridian is corrected by them, namely, that of 180° (being +2.75), and no

sphere is capable of improving this combination, but both plus and minus spheres will make the sight worse.

The crossed cylinder in its two positions will give the following results respectively: (a) With the plus axis of the crossed cylinder parallel to the axis of the trial cylinder (+.50) we have + 2 sp. ⊂ +1 cyl. ax. 90°, and (b) with the plus axis of the crossed cylinder at right angles to the axis of the trial cylinder we get +2.50 sp. The first being nearer the true correction, will be preferred as giving the better vision. Making the change indicated, the trial cylinder (+0.50) is strengthened somewhat being replaced by a +0.75 cyl., the combination now being +2.25 sp. ⊂ +0.75 cyl. ax. 90°. Plus and minus spheres held before this will indicate that the sphere is to be reduced; replacing the 2.25 sp. by a 2 sp., and re-examining with the crossed cylinder the two following combinations result: (a) With the plus axis of the crossed cylinder parallel to the axis of the trial cylinder we get +1.75 ⊂ +1.25 cyl. ax. 90°, and (b) with the crossed cylinder in the opposite position, +2.25 ⊂ +0.25 cyl. ax. 90°. The first is evidently the better. Making the change indicated we have +2. sp. ⊂ +1. cyl. ax. 90°. Trial by spheres now indicates that the spherical portion of the combination is to be reduced to +1.75. The crossed cylinder would now show no preference, held in either position, nor can the combination be improved by plus or minus spheres.

As mentioned before, the axis of the cylinder is to be re-tested after any change in the sphere or cylinder. For the sake of simplicity, we have assumed that the trial cylinder has been correctly placed in the example.

The Rhoads double crossed cylinder is an improvement on the ordinary crossed cylinder, in that when using it one is not required to twist the instrument before the patient's eye, thereby not giving him an instant of clear vision without either cylinder. The illustration shows clearly how this is accomplished by having two lenses mounted in one frame.

OPHTHALMOSCOPY.

In taking up the subject of examination of the eye by aid of the ophthalmoscope it is well to first speak of the ophthalmoscope itself and describe its various forms.

The first ophthalmoscope was invented by Helmholtz in the year 1851 and was a very crude affair when compared with our complex, highly accurate ophthalmoscopes of today.

Helmholtz's apparatus consisted of three plates of clear glass placed one behind the other and held before the eye under investigation.

(See figure.) The glass plate, PP, was so placed that the rays of light from L, are partly reflected from the surface of the glass into the pupil of the examined eye A. The rays were then reflected from the fundus, a, back through the pupil to the glass. Here some of the rays were again reflected back to L, but some of them penetrated the glass and entered the eye of the observer B, where they were focused on the fundus b. Later Helmholtz improved the reflecting power of his instrument by lining the posterior surface of the glass with mirror coating leaving a round hole in the plate or at least through the coating, allowing the examiner to see through it.

An improvement was made in the form of mirror by Ruete. He rendered the light more intense by using a concave mirror, thereby causing a convergence of the rays and allowing a greater quantity of light to pass through the pupil into the observed eye.

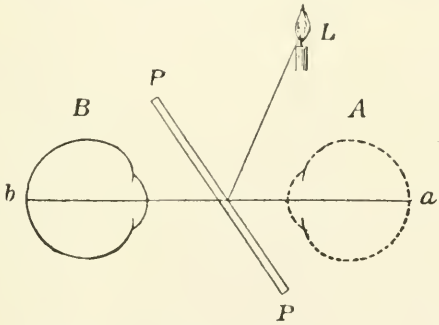

Principle of Helmholtz's Ophthalmoscope.

Probably one of the most generally used ophthalmoscopes today is that designed by Morton. It is shown in illustration. The Loring model, which is also shown, is a popular and accurate instrument.

George S. Crampton (*Trans. Coll. Phys.*, Phila., Apr. 17, 1913) has demonstrated a simple modification of the Loring ophthalmoscope which has proved a great convenience in routine ophthalmoscopic examinations, especially in hospital clinics. After the author had used it for a couple of years he discovered that William Zentmayer had devised the same thing and had used it in his routine work for a longer period.

A strong plus lens of, say, 16 diopters, replaces the minus one, and the other minus lenses are all moved around one position, the highest or minus eight being eliminated. This change can only be made in ophthalmoscopes in which the lenses are held between two discs which are fastened to one another by screws. The numbered disc is turned

over and its plain side is engraved to correspond to the change. As all of the figures can be stamped with one blow of a die it would, no doubt, be more advantageous to purchase the new model than to bother having an old one engraved.



The Morton Ophthalmoscope.

In use the examination is started with the plus sixteen in place, then, after examining the anterior media, the plus and minus lenses are brought into use without removing the ophthalmoscope from the eye. As the high plus lens passes by, it momentarily blurs the fundus details and one can easily tell with which lens he is working by remembering the number of changes he has made into the plus or minus. Thus the dial need not be read except occasionally. After a week's

use one becomes accustomed to the change and would not return to the old type.

The Paxton ophthalmoscope is a popular student's instrument, being quite simple and consisting of a wheel containing 19 lenses, with four extra lenses in segment, in front of instrument. It also has the revolving mirror fitting similar to the Morton's, with concave mirror and revolving angle mirror for direct examination.

The Lawford ophthalmoscope is similar in construction to the Paxton on a smaller scale. The wheel contains 11 lenses and 2 extra on segment in front of instrument; the swinging mirror fitting is the same as the Paxton, with large concave mirror and small revolving angle mirror for direct examination.

The "Juler's" ophthalmoscope, consisting of a wheel containing 24 lenses enclosed in a metal case, and propelled by a wheel conveniently placed over the handle. It has the swinging mirror fitting similar to

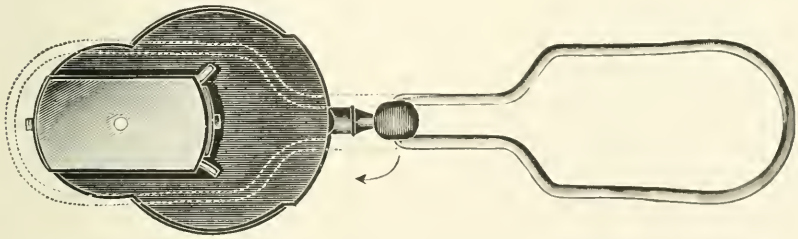

Loring Ophthalmoscope with Folding Handle as Suggested by Gamble.

"Morton's" with large concave mirror and small revolving angle mirror for direct examination.

"Lindsay Johnson's" ophthalmoscope is similar in principle to the "Morton," but has an improved driving arrangement which allows the lenses to be brought opposite the sight hole with more rapidity. It has the swinging mirror fittings as in the "Morton's," and is made with either two or three mirrors.

A new ophthalmoscope has been designed by George R. Hare, which is made either with the ordinary reflecting mirror or with an electric lighting system, in which the handle contains the battery. The form or outline of this instrument is such that it "fits the face." In other words, the narrowest part comes opposite the broadest part of the operator's nose. All other generally employed instruments are approximately circular in form and the broadest part of the instrument is always in unpleasant contact with the examiner's nose.

A so-called "bimanual ophthalmoscope" has recently been devised

by Tanner. At the upper end is a hook which is placed over the phalanx of the ring finger or little finger of one hand, which is rested against the brow of the patient. At the lower end of the handle is another hook, in which is placed the middle finger of the other hand. By drawing the two hands apart, the instrument is made to remain very steady. The thumb of the upper hand operates the main disc of lenses which run from —8 to +7 D. The second disc contains 0.5 and 16 D. each concave and convex, turned to the proper lenses before placing to

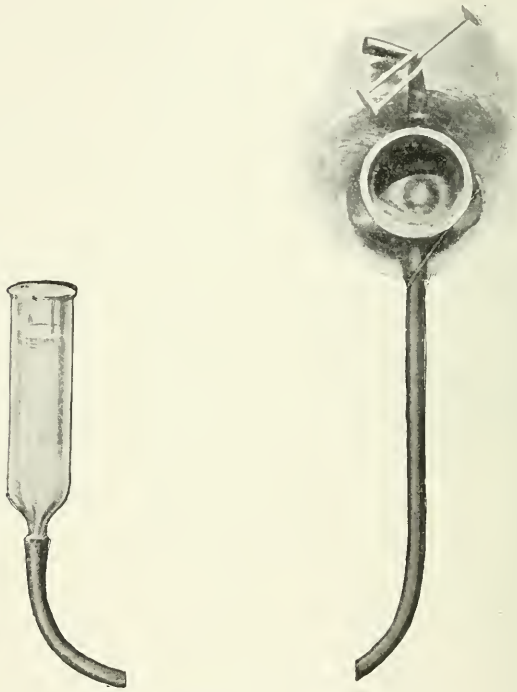

Rayner Batten's Hydrophthalmoscope.

the patient's eye. The instrument can be placed in position before the patient's face and the surgeon's eye subsequently brought to the sight hole. Tanner claims that his instrument is much easier to use than the ordinary type and that the unskilled investigator can, with very little practice, see the fundus.

The *hydrophthalmoscope,* an instrument for the examination of the fundus of the eye under water is of greater antiquity than the ophthalmoscope. Mery and La Hire in 1709 observed that the fundus of an eye could be seen in animals under water. Czermak in 1851

invented an instrument which he called an "Orthoscope," because under water he could see straight into the eye.

Professors Arlt and Coccius modified and made more convenient forms of instruments to obtain the same end, but although they all explain the advantages of this method of examination, it has never established itself as a recognized method and the instruments must have gone to the "scientific rubbish heap."

However, Rayner D. Batten in the *Ophthalmoscope*, February, 1910, Page 92, has described an instrument (see illustration) for this purpose which is quite simple and practical. It consists of a metal eye-cup with a plane glass fitted into it, and two short metal tubes soldered on to its upper and lower surfaces, to which rubber tubes for the supply of water and the exit of air can be attached.

The supply tube is connected by a rubber tube about three feet long to a reservoir, which can be raised or lowered. The exit tube has a short piece of rubber tube fixed to it which can be firmly closed by a clip.

In order to apply the instrument to the eye, the reservoir should be half filled with hot water with a few drops of glycerine added.

The glycerine can be mixed with the water and the temperature lowered by allowing the water to fill the cup and to run back into the reservoir.

This solution, if really warm, is hardly felt by the eye; but the eye is particularly sensitive to cold, so that unless the solution is really warm, a sharp contraction of the lids occurs when the water touches the cornea. The reservoir should be given to the patient to hold in the hand opposite to the eye under observation and the cup applied to the eye.

The upper edge of the cup should be applied so as to engage and to raise the upper lid. Fit the cup well into the nasal margin of the orbit and gently pull down the lower lid, so as to expose the whole of the cornea. Steady the cup gently with one hand so as to press it slightly into the orbit and open the clip with the other hand. Then direct the patient to raise the reservoir above the level of the cup; when the water rises to the upper level of the exit tube, close the clip and direct the patient to lower the reservoir about nine or ten inches below the level of the eye. This gives sufficient suction to keep the instrument in place.

When the cup is properly applied, the eye remains open, as the cup acts as a lid retractor so that the fundus of the eye can be fully examined under its new conditions without the aid of an ophthalmoscope.

Electric ophthalmoscopes are in very general use now. They are made to operate either from a battery carried in the pocket or handle of the instrument, or they are connected through a rheostat to the regular street current.

Marple has modified the electric apparatus first described by Dennet so that it may be used in connection with any model of ophthalmoscope.

As now made, it consists of a tubular hollow handle, having mounted at its upper end a small mirror, which makes an angle of 45 degrees

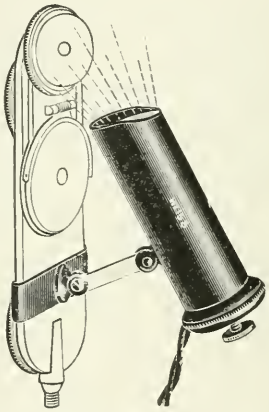

Haile's Electric Lamp Attachment for a Morton Ophthalmoscope.



The "Standard" Electric Ophthalmoscope.

with both the long axis of the handle and the line of vision. At the upper end of this tube, close to the mirror, a small convex condensing lens is mounted.

Inside of the handle, mounted on a rod that can be moved up and down, is a small lamp. The purpose of this adjustment is to permit proper focusing of the illumination. When the lamp is moved to a point corresponding to the focal point of the condensing lens, the emergent rays are parallel. From a point beyond or nearer the focal point, the rays are divergent or convergent, respectively. The adjustment can be made easily while the instrument is in use.

This adjustable illumination makes it possible to use the instrument in the indirect as well as the direct method, and for detecting minute opacities in the media it is superior to the ordinary reflecting ophthalmoscope, as it is possible to get just the kind of light needed. The corrugated band around the handle controls the light.



Set of Electrically Lighted Eye Examining Instruments, including De Zeng's Ophthalmoscope and Retinoscope and Würdemann's Transilluminator.

The U-shaped mirror secures the greatest possible reflecting surface, and has an aperture with no upper edge to reflect light into the examiner's eye. It illuminates the lower part of the fundus perfectly.

In using the instrument in the direct method, the lamp is first moved up as far as possible by means of the corrugated band. For use in the indirect method, hold at the usual working distance and move

the light up or down until the reflection on the patient's head is a long, narrow bar of light; interpose the lens, and a good inverted image of the fundus is obtained.

Another portable attachment for the ordinary ophthalmoscope, to furnish electric light, has been described by Hailes (see illustration). A tube containing a small electric light is attached by a double-jointed bracket, which allows it to be turned so that it can be used

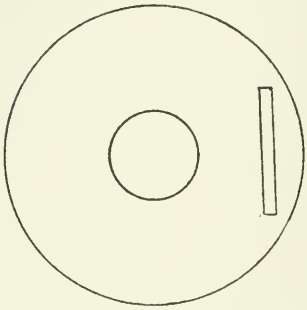

Gullstrand's Ophthalmoscope. (Fig. 1.)

Diagram of pupil showing a slit-like portion through which the eye is illuminated, and central circle through which emergent rays give a monocular view of the fundus.

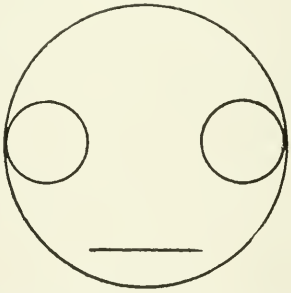

Gullstrand's Ophthalmoscope. (Fig. 2.)

Diagram showing slit below through which the eye is illuminated, and circles on right and left of pupil through which emergent rays give binocular view of the fundus.

for oblique illumination of the eye, or folded down to economize space in carrying the instrument.

The "Standard" electric ophthalmoscope is shown with battery enclosed in the handle. This is a very satisfactory ophthalmoscope and on account of its long handle is easy to hold in position.

The most aggravating obstacle encountered by the surgeon in the use of the ophthalmoscope is the corneal reflex. Many different plans and apparatuses have been brought forward for the elimination

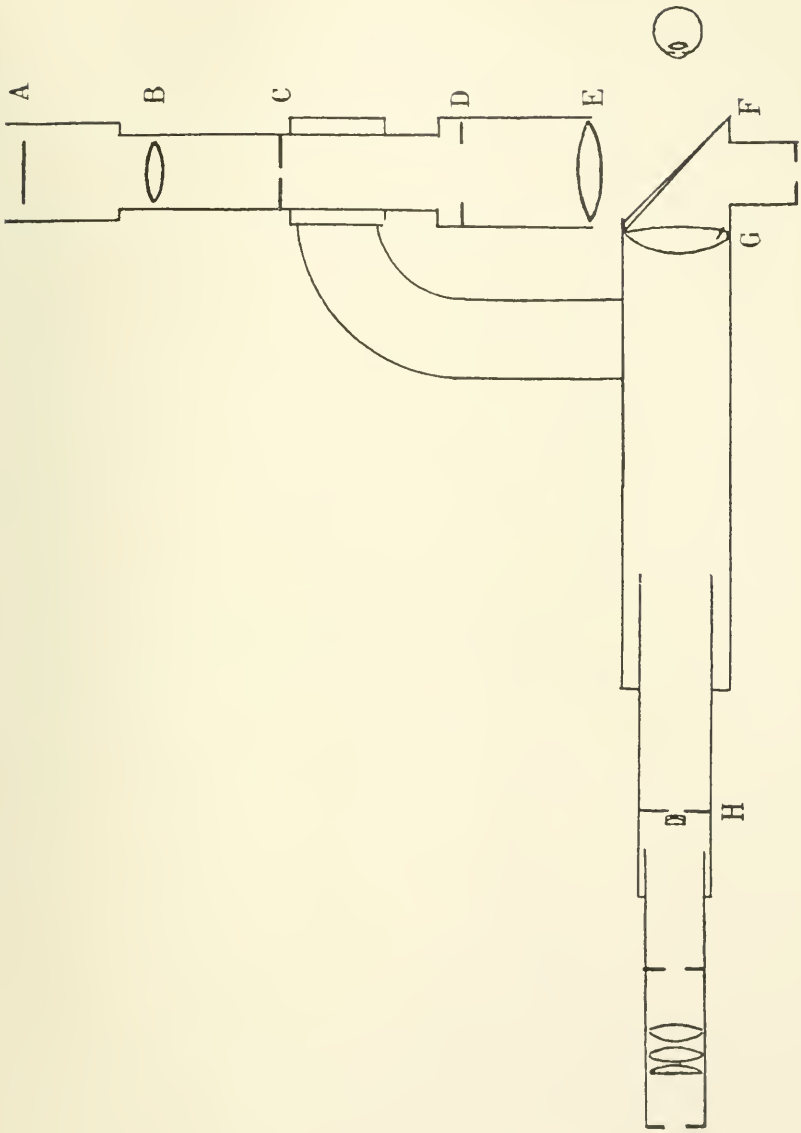

Gullstrand's Ophthalmoscope. (Fig. 3.)

A, filament of Nernst lamp; B, condensing lens forming image of filament on slit C; D, diaphragm; and E, convex lens with focus at C completes illuminating apparatus; F, glass-plate reflecting light into patient's eye; G, object lens receiving light from patient's eye through glass-plate forms inverted image which is magnified by eyepiece H.

of this troublesome feature. The experienced ophthalmoscopist learns, after long use, that by shifting the position of his mirror he can throw the reflex to one side, or diminish it so that he can see past it. Thorner used one-half the pupil to throw the light into the eye, and the other half to transmit the light from the fundus of the observed eye to the eye of the observer.

Gullstrand has constructed a reflexless electric ophthalmoscope, which illuminates the eye-ground with a pencil of rays that enters only through a peripheral part of the pupil, thus leaving the centre of the cornea free. In this instrument the illumination of the patient's eye is by a Nernst lamp through a slit-like space 1.5 mm. wide, at the periphery of the pupil; and the light emerging from the observed fundus is received through an opening 2.4 mm. in diameter opposite the centre of the pupil. The relative positions of the spaces for entrance and emergence of light in an 8 mm. pupil are shown in fig. 1. This is what Gullstrand calls his centered method of reflexless ophthalmoscopy. It has the advantage of utilizing for the emergent rays the most perfect part of the ocular dioptric surfaces.

When the attempt is made to utilize the periphery of the dilated pupil for this purpose the irregular astigmia present necessarily causes the image to be less perfect. When, however, he makes his instrument a binocular ophthalmoscope Gullstrand is compelled to use ocentric or eccentric spaces, as shown in fig. 2, in order to get the maximum of stereoscopic effect. The general plan of Gullstrand's instrument is shown in fig. 3, which shows it arranged for monocular use. For a binocular ophthalmoscope he places behind the lens G, a diaphragm with two openings with centres 16 mm. apart, and back of these the prism ocular of the Czapski loupe. He reflects the light into the eye, not with silvered glass, but with a plate of glass, the sides of which are inclined at an angle of one-quarter degree to superimpose the doubled reflections from the two surfaces of the plate.

The De Zeng electric amplifying ophthalmoscope consists of an ophthalmoscopic mirror, a telescope, a miniature electric lamp and condenser, so connected and mounted as to form a small, hand, self-luminous amplifying ophthalmoscope.

The position of the mirror with respect to the light source directs the illuminating rays into the eye under observation in a line parallel with the optical axis of the telescope. The light emanating from the observed eye, in passing through the telescope to the observer's eye, causes the objects in view to be magnified in accordance with the amplifying power of the telescope, times the usual magnification as seen with the ordinary ophthalmoscope while employing the direct

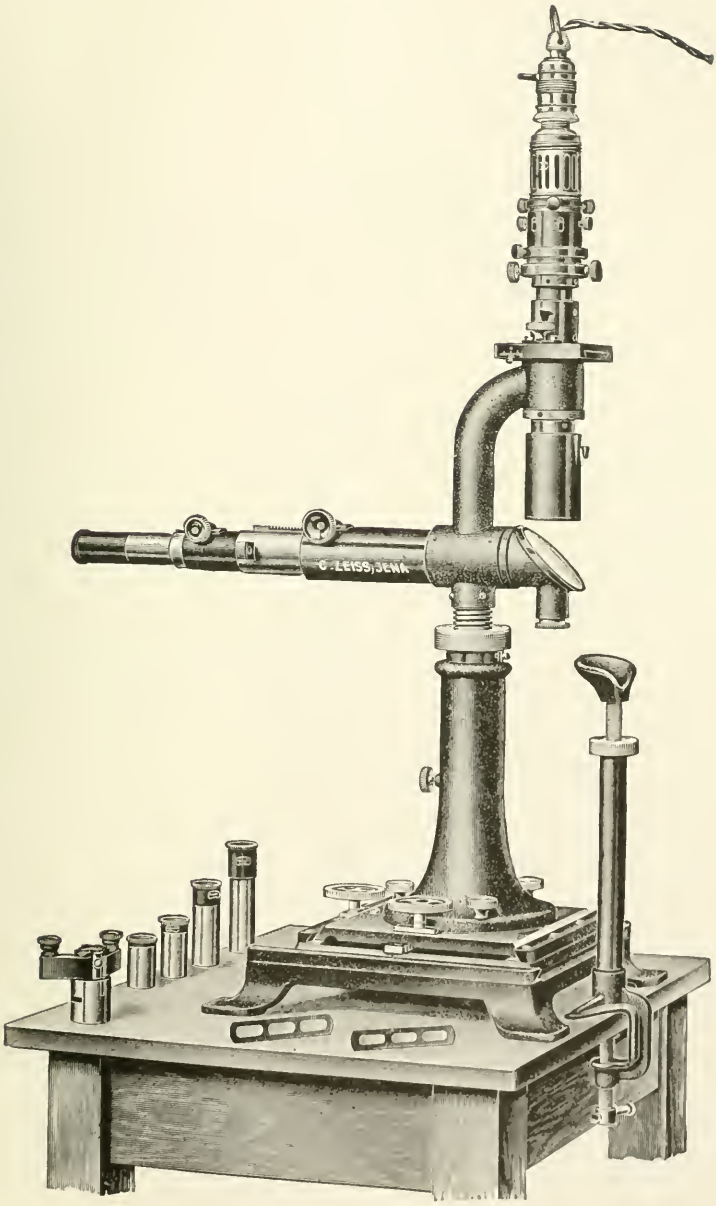

Gullstrand's Large Ophthalmoscope.

method of examination. If the fundus of the normal eye is viewed under a magnification of 14 diameters when the direct method is employed with the ordinary ophthalmoscope, the same fundus would be seen under an amplification of 42 diameters if observed through a 3-diameter amplifying telescope.

The telescope has an amplifying power of 3 diameters, and is provided with a graduated focusing adjustment for estimating the ametropia. The telescope, therefore, obviates the necessity of neutralizing lenses in the ordinary ophthalmoscope, since, by the relative adjustment of the objective and eye-piece, all of the spherical equivalents in both plus and minus can be quickly and accurately obtained. There are three styles of mirrors employed. The circular mirror with central aperture is best adapted to all working distances beyond two inches, the half mirror to very close range, and the small mirror to close range with large pupil.

The electric lamp attachment is reversible and can be turned over so as to always stand at the temporal side when in use.

The mirror-holder is slightly adjustable and should be so set as to direct the light exactly parallel with the axis of the telescope; otherwise the illuminated area will be to one side of the field of view and nothing will be seen.

The condenser between the light source and the mirror is made adjustable to permit of more or less concentration of light as desired.

The ophthalmoscope should be steadied when used at close range by means of the adjustable support secured at the handle. Entirely satisfactory results can only be obtained when the observed eye has a well-dilated pupil.

Examination of the eye by aid of the ophthalmoscope may be divided into four divisions.

1. Ophthalmoscopic examination for determining the refraction of the eye.

2. Ophthalmoscopic examination with the instrument at a distance for exploring the media of the eyeball.

3. Indirect ophthalmoscopy, for a general examination of the fundus with low power magnification.

4. Direct ophthalmoscopy, for examining minutely the fundus with a greater magnification.

It is not the purpose to enter minutely into the use of the ophthalmoscope at this point. The reader is referred to the article in this *Encyclopedia,* under the heading **Ophthalmoscopy** for a complete exposition on the subject.

The examination is always to be made in a darkened room. If

absolutely dark, with black walls, it is much better. The light, if an ordinary ophthalmoscope is used, should be steady, clear, and bright. Most of the lamps described for examining the eye under oblique illumination, may be also used with the ophthalmoscope.

The mercury lamp, in which a brilliant light almost devoid of red rays is generated, has been used by some as a source of illumination

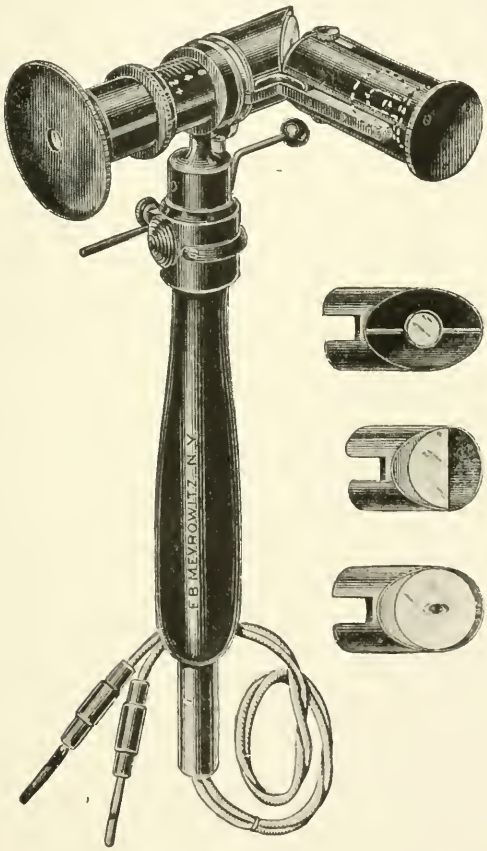

De Zeng's Electric Amplifying Ophthalmoscope.

for examining the fundus. Mayou has reported that when using this light the general color of the fundus is green: the disk having a white centre with green edges. The retinal vessels appear purple and the choroidal vessels a deeper purple. A retinal reflex, most marked along the vessels and rather indefinite at the macula is seen over the whole fundus. A better perspective of the eye-ground is gained, the different depths of the retina, choroid and sclera being more evident.

Mayou suggests that this light may prove of much use in the differential diagnosis of retinal and choroidal disease.

The varying intensity of illumination used in ophthalmoscopy to bring out differences of appearances in the fundus, particularly faint opacities in the different media, is an important aid in many cases. The light source should have a candle power capable of from 3 to 20. A general survey with an extremely moderate illumination first and then of gradually increasing intensity allows one to clearly differentiate between the views obtained under both conditions.

The position of the light is several inches to one side and back of the patient, and on a level with the patient's ear, so as to illuminate the outer half of the eyelashes of the eye to be examined as well as the tip of the patient's nose.

The patient should be seated in a light chair that can be easily moved about. He is instructed to keep both eyes open and stare into vacancy, in the direction indicated by the surgeon. In the examination of the optic disc of the left eye, the patient should be told to look slightly to the right, and for the right eye to look to the left.

If one has not mastered the use of the ophthalmoscope it is well to have the pupils of the patient dilated with a solution of cocain or homatropin. All well-qualified oculists should, however, be able to thoroughly examine the fundus of an eye through an undilated pupil.

The ophthalmic examination for the determination of the refraction of an eye, can never be a very accurate procedure and results obtained in this manner should never be entirely relied on.

If the patient be hyperopic and the eye entirely at rest, the rays from his retina will diverge on leaving the cornea, and to render them parallel will require such a convex lens as would cause parallel rays to be focussed on his retina.

If the patient be myopic, the rays from his retina emerge convergent, and are focussed in front of the surgeon's retina. By placing before the eye a concave lens of just the proper strength to correct the myopia, these rays are rendered parallel, and the surgeon is able to focus them on his retina.

The measurement of refraction can be made with the ophthalmoscope, with approximate accuracy, only after long practice.

In *making the examination with the ophthalmoscope at a distance*, the instrument is held about 12 inches from the patient's eye. The corneal reflex is first seen, as a small bright image of the source of light and the pupil, previously black, becomes occupied with a red glow—the fundus reflex—which varies in hue according to the brightness of illumination and color of the fundus. The examiner next

searches the media of the eye for any opacities, which appear as black dots or masses. These opacities may be definitely located by having the patient move his eyeball about, and observing the directions of movement of the opacity.

In making *the indirect ophthalmic examination* the examiner holds the instrument against his own eyebrow with one hand and a + 20 D. lens with the other hand in front of the patient's eye. He then focuses the reflected light from the concave mirror of the ophthalmoscope at a distance of about 18 inches, through the 20 D. lens, upon the fundus through the dilated pupil. The examiner will accomplish this more readily if a + 4 D. lens be placed in front of the eyehole of the mirror.

The Indirect Method of Using the Ophthalmoscope.

He now sees an inverted image of the ocular fundus and an outline picture. Having taken this "bird's eye view" of the background, the surgeon lays aside the 20 D. lens and approaches the mirror as close as possible to the pupil of the patient and makes the *direct ophthalmoscopic examination.* The view by the direct method is much enlarged and the fundus is in the erect position.

The nerve head is first examined and then by having the patient look in all directions a complete inspection of all parts of the fundus is made.

Gifford (*Ophthalmoscope*, V. 11, p. 193), adds his testimony to that of Haab regarding *indirect illumination of the fundus in direct ophthalmoscopy.* The essence of the method (first used by Nagel) is to throw the edge of the illuminated area on the point to be examined, instead of throwing the centre of the illumination upon it—in other words, "directing attention not to the centre of the illuminated area, but to its periphery." He thus brought out distinctly

spots in the retina, especially "drusen," not readily discernible in any other way.

Burdon-Cooper (*Ophthalmoscope,* V. 11, p. 729), holds that this method is valuable by enabling the observer to vary the intensity of the illumination, which ranges from the brightest to the faintest possible, as we pass from the centre of the illuminated area. He would call it "eccentric illumination." Under feeble illumination the apparent brightness of the less refrangible color (red) diminishes most rapidly; tending to render more striking differences not perceptible by "centric illumination." He also calls attention to the more acute perception of light and colors by the para-fovea than by the fovea. On account of this, looking a little aside from the point to be observed will bring out differences in color or brilliancy, not perceptible when the point is directly looked at. He advises "eccentric vision" with "eccentric illumination."

Alexander has demonstrated that by the use of a concave lens held close to the patient's eye, one can increase the visible area of the fundus. Both the illumination and magnification is diminished; therefore a very strong light must be thrown into a well-dilated pupil. The image thus obtained may require a convex lens before the examiner's eye to render it clear.

There is very little advantage gained over the image seen by the ordinary indirect method, except that the magnification intermediate between that of the ordinary erect image and the ordinary inverted image is more readily obtained; and, to one accustomed to use the erect image, there is no reversal of the relations to cause confusion.

In the ordinary direct ophthalmoscopic examination it is only possible to view the choroid and retina covering the posterior half of the eyeball. Any point a little in front of the equator is usually inaccessible to inspection. Trantas has found, however, that on pressing in the sclera over them, the ciliary and retro-ciliary regions of the fundus can be brought into view in the pupil. To examine the temporal portion of the right eye the lamp is placed on the right, the eye turned strongly in that direction, and pressure made on the temporal portion of the ciliary region with the tip of the finger. To examine the nasal portion of the right eye the light would be placed on the left, the eye turned somewhat toward the nose, and pressure made on the nasal side of the eyeball. It is needless to say that the pupil must be fully dilated, and in some cases it is better to cocainize the eye and make pressure directly on the sclera. However, good results can usually be obtained by pressure being made through the lid. The direct method of ophthalmoscopy is to be always em-

ployed, using a + 4 to + 8 D. lens at the sight hole. In high hyperopia the lens will be slightly stronger and in high myopia weaker. But the refraction of this part of the eye varies comparatively little.

Trantas has pointed out, after a study of one hundred and seventy-five cases, that the normal appearances seen at this region vary greatly in different eyes. The pigmentation is dark, but variable. The outlines of the processes and posterior boundary of this region, are not constant in form. Many such examinations must be made before one can recognize with certainty the slighter variations from the normal.

The principal lesions are seen as trophic spots, pigmented areas, mixed pigmentation and atrophy, and hemorrhages. These lesions are almost constantly found in persons suffering from alcoholism. Among syphilities, atrophy and pigment disturbances are common. The same is true of patients suffering from tabes, or hereditary syphilis. Congenital malformations and traumatism affect this region, as well as atrophies due to myopia. Hemorrhage into the vitreous may be traced to its source from the vessels of this tract. In some cases of partial opacity of the lens, pigmentated spots and atrophies have been demonstrated in this part of the globe, although not found in the posterior portion of the choroid.

Perimetry. Alfred von Graefe suggested a method for the more exact determination of the position of appearances seen with the ophthalmoscope, and other ophthalmologists have employed the perimeter for this purpose. What might be called an *objective perimeter* has been worked out by Reitsch (*Klin. m. f. Augenh.*, January, 1913, p. 51).

To avoid an important objection to the use of the ordinary perimeter, the revolving semi-circular arm is made very narrow, with projecting teeth. Fixation in the axis of the instrument is secured by looking through a ring at a white disk; and this fixation apparatus is mounted on a rod that slides in the axis of the instrument, and can be pushed close to the patient's eye to provide exact direction in high myopia. The fixation of the eye and head is provided for by two supporting or fixing plates, one of which is adjusted to the lower margin of each orbit.

With the eye thus fixed the observer examines it by the ordinary method of indirect ophthalmoscopy. When a point is found which it is desired to localize, the perimeter arm is turned until this point is seen between two of its teeth. Noting which these teeth are, the number of degrees from the axis is known; and the direction of the semi-circle can be read off from the small graduated circle around the axis of the instrument. In the cut, representing the instrument,

the axis rod carrying the fixation point is represented on the right, and the fixing plates against which the margins of the orbits are pressed on the left. To the left of these fixing plates is attached a small semi-circle. This is for the purpose of marking upon the sclera the position of the point localized, as in the case of a nonmagnetic foreign body, seen with the ophthalmoscope, and which it is proposed to extract.

The fact that different parts of the fundus image can be brought to the same apparent position by shifting the object lens, is known to all who use the indirect method of ophthalmoscopy. To avoid the error that this would cause in localizing a point of the fundus image Reitsch uses an object lens on which the optical centre is marked

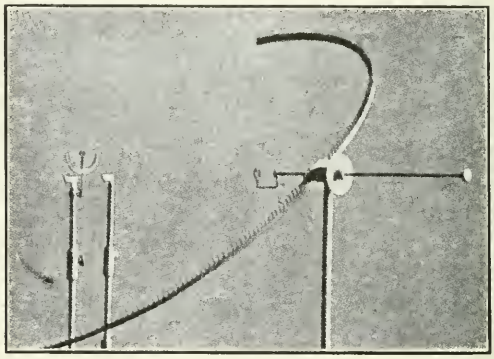

Objective Perimeter of Reitsch for Ophthalmoscopic Localization.

by cross lines. The point to be localized can be brought to this centre which gives its true direction.

If the visual axis of one eye is directed to a stationary point, not only is the object "fixed," visible, but also all objects contained within a given space, the size of which, is in proportion to the distance of the fixation point of the eye. This space is called *the field of vision,* and the objects within it imprint their images upon the peripheral portions of the retina. The function of sight capable of being performed by that part of the retina surrounding the macula is called indirect vision in contradistinction to visual acuity and refraction, which pertain to the macula in the act of direct vision.

The *simplest method of roughly ascertaining the visual field* is the following: Place the patient with his back to the source of light, and have him fix the eye under examination (the other being covered) upon the centre of the eye of the observer, which is directly opposite

his own, at a distance of two feet. Then let the surgeon move his fingers in various directions midway between himself and the patient, on a plane with his own face, until the limits of indirect vision are determined, controlling, at the same time, the extent and direction of the movements by his own field of vision. This method suffices to discover any considerable limitation, and, in the event of such discovery, should be supplemented by a more exact procedure.

Instruments for measuring the distance of the examining hand, or test object held in the hand, from the visual axis have been invented. One of these is the *compimeter of Aubaret* (*Ophthalmic Year Book*, Vol. IV, 1907). It is modeled much on the order of a self-coiling tape measure, with an index on the back indicating the number of degrees the test object is drawn from the visual axis. On the face is an ebonite disk marked with the different meridians and circles for taking the centre of the field. The instrument's chief advantages are its convenience, simplicity and portability, its weakest point is the difficulty of getting a proper uniform background for the test object.

The blackboard method of measuring the field is quite accurate up to 45 degrees, beyond which this method ceases to be dependable, because on a flat surface the object is too far away from the eye; rays perpendicular to the visual line coming from a peripheral object would be parallel to the blackboard, and could not arise from it, nor from any object passed across its surface.

In carrying out the blackboard method the patient is placed 25 cm. from a blackboard, which may be conveniently ruled in squares, and fixes the eye under observation upon a small white mark. The observer then moves the test object—a piece of white paper 1 cm. square, affixed to a black handle—from the periphery toward fixation, until the object is seen. If eight periphery points are marked and afterward joined by a line, a fair map of the field of vision will be obtained which may be transcribed on a chart. See also Vol. II, p. 1005, of this *Encyclopedia*.

The best and most accurate method of investigation of the periphery of the retina is by means of *the perimeter*. This instrument is either a hollow hemisphere or a metallic band representing one meridian of such a hemisphere. The latter is a graduated arc turning on a central pivot and bearing a movable disc. A recording apparatus registers the point at which the test object is seen in different meridians.

Many different models of perimeters have been described, one of the popular ones being McHardy's. (See cut.)

This instrument is made according to the principles of McHardy and is a very practical and durable self-registering perimeter. It has

a revolving quadrant with a radius of one-third metre. The chin-rest is adjustable, and the quadrant has telescopic adjustment. The test object is moved by a carrier, worked by cords and a milled head. A steel point follows each movement of the test object, and the various positions are recorded by pressing the chart secured in the holder against this point. The objects consist of colors on a circular wheel, in front of which are various diaphragms; thus any color may be used

McHardy Self-Registering Perimeter.

with a number of sizes of the object. There is also a candle holder and candles for the light test.

Black (*Ophth. Rec.*, V. 22, p. 136), has attached an electric lamp for fixation and an electric light test object to the McHardy perimeter. With this instrument the field can be taken and recorded in a dark room; assuring uniformity of conditions, and preventing the patient's being attracted to other objects. The test may vary from a point to 10 or 20 mm. in diameter. The transilluminated colors are pure

spectral colors, something hard to obtain when pigment-colored papers are used.

George R. Hare has described a perimeter (see cut) which is automatic. All motions of the object carrier are transmitted to the recording and marking device with absolute accuracy, and the examiner is relieved of any observations, except that of determining the limit of the field.

The instrument consists of a semi-circular arc revolvably mounted on a stand, of which the chin-rest and guide for eye are integral parts.



Brudenell Carter's Perimeter.
A simple apparatus, which, however, is quite accurate when carefully used.

Revolving within the main shaft, on which the arc is supported, is another shaft extending through to the arc, by means of which the object carrier is operated through rotation of the hand wheel. Attached to this shaft is a circular plate (not shown in cut), having upon its face a spiral track. Operating in this track is the recording pin, the movement of which is limited by means of a slot in a covering disk to a motion to and from the centre along one radius. The operation of the object carrier is, therefore, as follows:

When the hand wheel is rotated, the object carrier is made to move along the arc to and from the centre, imparting to the recording

pin, through the rotation of the disk with spiral track attached to the shaft, a motion similar, but reduced in range to lie within the limit of the perimeter chart. When the arc is moved into a different meridian the entire recording mechanism moves with it. When a record is desired it is merely necessary to press the chart, which is carried on a flat plate hinged to the stand, against the steel recording pin; a puncture on the chart, corresponding to the position of the color carrier, is thereby made.

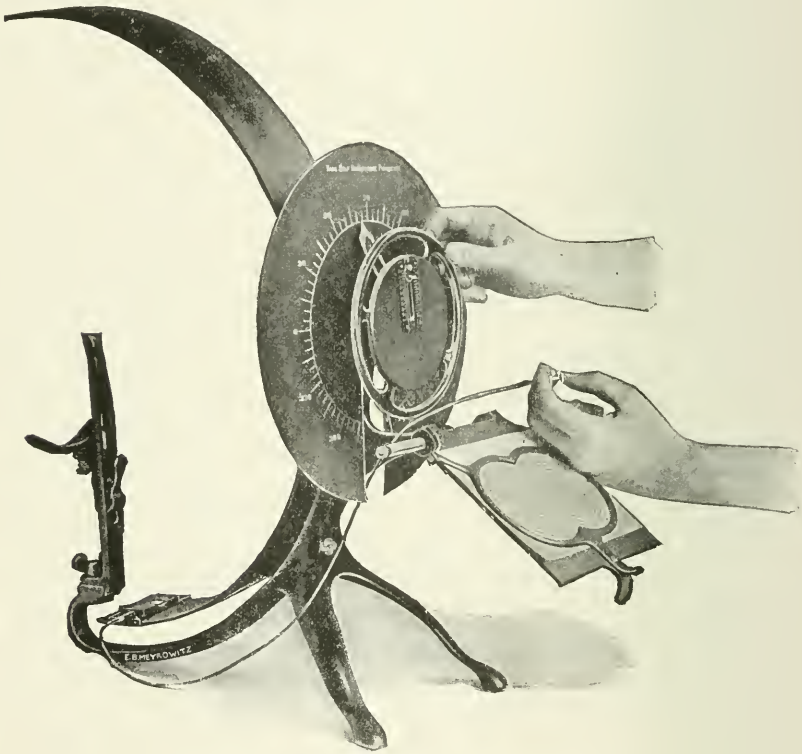

Automatic Perimeter Designed by George R. Hare.

The large disc or shield shown in the cut serves both as an axis indicator and to screen movements of operator's hands. This disc is readily removable, making the instrument available for the measurement of the degree of strabismus by the angular method. The position of the movable object in degrees from the centre is shown on the scale alongside the slot in which the marker moves.

Another most important feature is that the colors exposed in the carrier are changed by means of a flexible shaft, extending backward

and manipulated by the operator back of the shield or disc. It is possible, therefore, for the examiner to make a change in the color of the object exposed without giving any clue to the patient; by means of a revolving diaphragm the colors may be shown in four different sizes—circles of 1, 3, 5 and 10 mm. diameter.

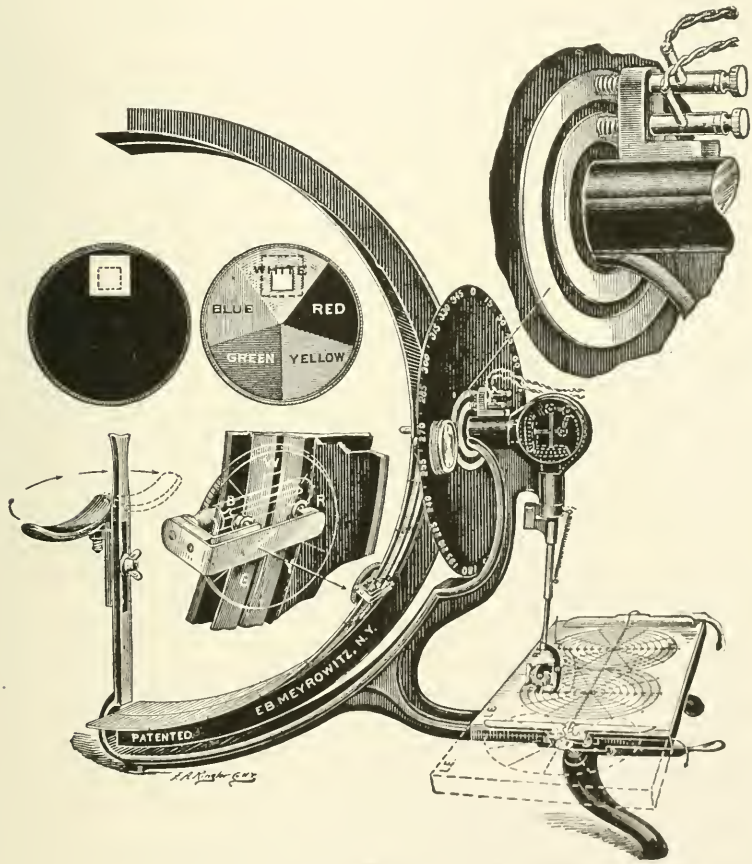

Skeel Electric Self-Registering Perimeter.

The old method of changing buttons or rotating the color carrier by introducing the hand into the field was an interruption to the examination and distracted the patient's attention, so that each time a new start had to be made. With the present method of changing the colors, the entire examination can be gone through much more quickly, because there need be no interruption, nor is it necessary for the operator to introduce his hand into the field.

The chin-rest is adjustable for right or left and for height. The operating shaft is pierced through its centre, permitting the operator to keep the patient's eye under constant observation.

The charts are "double," i. e., both right and left eye records printed on one chart; the normal field being outlined. The charts are held firmly in place by a frame clamp with marks to indicate when they are in proper position to receive the automatic record.

The Skeel perimeter (see cut) has also been equipped with a device for illuminating the colors, as well as the central white spot, by means

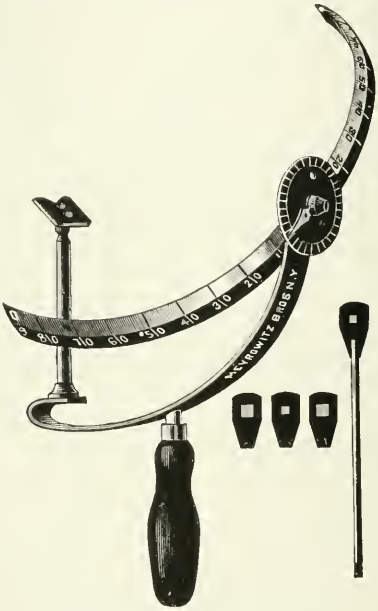

Schweigger's Hand Perimeter.

of small electric lamps adjusted behind the rotating color disk and central point, the electric current being carried to the lamps by a small trolley which has been adjusted to the back of the perimeter arc. The current is carried to this trolley through the black dial by the pressure of two contact points against two metal rings as indicated in the cut.

The instrument may also be used as a deviometer by removing the caps from the illuminated targets. These afford two spots of light with which the angle may be determined in the regular way.

Perimeters which can be easily carried to the bed-side of the patient, or to different wards of a hospital, have been devised. The one

described by Schweigger (see cut) is quite simple and is used much in the same manner as an ordinary perimeter, except that it is held in the observer's hand while in use.

An even smaller and simpler instrument is that of Dana. (See cut.) A glance at the illustration will show its simplicity as well as demonstrate its method of use.

A perimeter, particularly designed for hospital use, where it is often desired to examine the fields of bed-ridden patients, is described in Vol. II, page 921, of this *Encyclopedia.*

A perimeter built on the plan of an umbrella is described by Reber and McCool (*Ophthalmoscope,* IX, page 500). It gives the advantage of an almost hemispheric surface. The boundaries of the field may be marked out by pins, with white, red, green or blue heads. It may

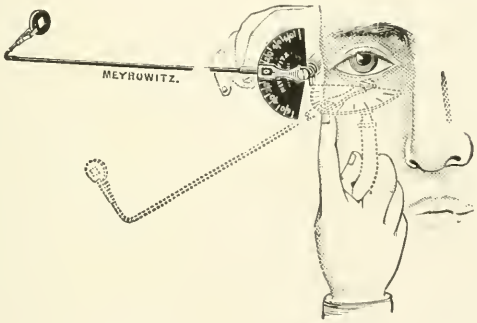

Dana "Pocket" Perimeter.

be folded like an ordinary umbrella, making it very portable; and it is found more convenient at the bed-side than Schweigger's hand perimeter.

The relation between peripheral visual acuity and color-sense has been investigated by Rönne (*Klin. M. f. Augenh.,* February, 1911, p. 154), with reference to their prognostic significance in optic atrophy. A complete study of the visual field includes mapping the isopters, or lines of equal visual acuity. Where these lie close together a rapid fall of function is indicated. A change in them at such a point indicates positively a change in the condition of the eye. But if the isopters are widely separated, less reliance can be placed on their slighter apparent changes. Apparent asymmetry in hemianopic fields may indicate hemiamblyopia, with unappreciated differences in size of object, illumination, or the attention of the patient. In eight cases of stationary optic atrophy, Rönne found agreement between peripheral

vision and color fields. Of sixteen cases of progressive atrophy some showed proportion, and others disproportion. The latter was taken to indicate more fibers recently attacked and therefore a worse prognosis, more rapid progress. In fourteen cases of simple or chronic glaucoma, he always found peripheral visual acuity proportional to color-sense.

The *method of using a perimeter* as here described applies particularly to the McHardy instrument, but as all perimeters are so nearly alike in principle it can be almost equally as well used for any model: One eye of the patient is bandaged. The other is to be directed constantly at a small, white disc placed at the centre of the pivot. The test object (a white disc) is then to be carried to the end of the arc and is made to approach the centre slowly. As soon as the patient sees it, he announces the fact and the surgeon registers the point. The surgeon then continues to cause the test object to slowly approach the centre asking the patient to tell him if he sees it clearly until it reaches the fixation point. This part of the examination is very important and is for the purpose of discovering the presence or absence of scotomata. The same procedure is followed in the upper, lower, inner, outer, and oblique meridians. To make the examination exact, at least three meridians should be tested in each quadrant. The points registered are joined by a continuous line, and thus a map of the visual field for white is obtained. The field for colors is tested in the same manner, a colored test object being substituted for the white one. The apertures of the McHardy perimeter permit the use of a test object of different sizes, 1, 2, 5, 10, 15, and 20 millimetres square. See also **Color interchanger** in Vol. IV, page 2399, of this *Encyclopedia*.

Walker (*Jour. Amer. Med. Assn.*, V. 61, p. 227) states that the mechanical perimeters lack accuracy when the defect approaches closely the centre of the field, and are time-consuming especially for taking the color fields. He proposes for use with the simple perimeter, or against a plain background, disks mounted one on each end of a slender black handle. These disks, he thinks, should be circular, and graded according to area. In his series they run from 16 sq. cm. to 1/64 sq. cm. in area. He also offers what he calls a color interchanger, with a series of openings giving different colors, either of which can be used as the test object. To cover the eye not being tested he has a special blinder, which may be used plain, or may have an opening, and a tube through which the untested eye may be made to fix. This blinder is supported by a spring passing back over the head; and may be accurately applied to either orbit.

An ingenious apparatus has been devised by Prof. V. Szily and described by Herczogh, which assists in taking the field of an eye which is so amblyopic as to be incapable of accurate fixation. It consists of a funnel-shaped tube of hard rubber, which can be attached in the proper position to any perimeter. Through this the better eye fixes. This secures the fixation of both eyes, while excluding the better eye from all except central vision. The field of the amblyopic eye is then taken in the regular manner.

To facilitate the examination of the field of vision, particularly in reference to investigations to show the existence of even the smallest scotoma, a method has been proposed by Bjerrum. The method consists in making use of white objects which subtend a very small visual angle. The examinations are made at a distance of two metres, at which distance the blind spot instead of measuring 2.5 cm., as on an ordinary perimeter, measures 20 cm. in diameter; and everything else is in the same proportion. The examination is begun in the ordinary manner (at 30 cm.), with the 10 mm. disc, and then continued at two metres' distance with a 3 mm. disc. In the first case, the visual angle approximately is 2 degrees, in the second it is 5 minutes. The normal boundaries in the second examination are 35 degrees outward; 30 degrees inward; 28 degrees downward; 25 degrees upward.

The *apparatus of Sym and Sinclair for making the Bjerrum test* gives us a most satisfactory method of detecting and mapping small or relative scotoma in the central portion of the visual field. It consists of a screen of dead-black velvet fastened on a light wooden frame seven feet square, the velvet turning over the edges of the frame so that no tacks shall show, and the frame being so braced that no cross bars shall come in contact with the velvet to lessen the uniformity of its surface. The fixation point is placed at the centre. The different meridians are indicated by velvet covered buttons at the edge of the screen. The boundaries of the field or scotoma are marked by black headed pins stuck through the velvet. Their distance from the centre of the field is measured by a scale; marked on one side for a distance of two metres between the patient's eye and the screen, and on the other side for a distance of one metre. A black linen cover fastened to the top of the frame keeps out dust when the screen is not in use, and when thrown back helps to shut off all light transmitted from behind the screen. The test objects may be the ivory discs proposed by Bjerrum, or pieces of pure white paper supported by a rod covered with black velvet. The patient's eye should be opposite the fixation point and steadied by a firm head-rest. With practice the necessary examination can be made in fifteen minutes or less. The

result of such an examination should be recorded on a chart printed on a much larger scale than the ordinary diagrams for recording the visual field.

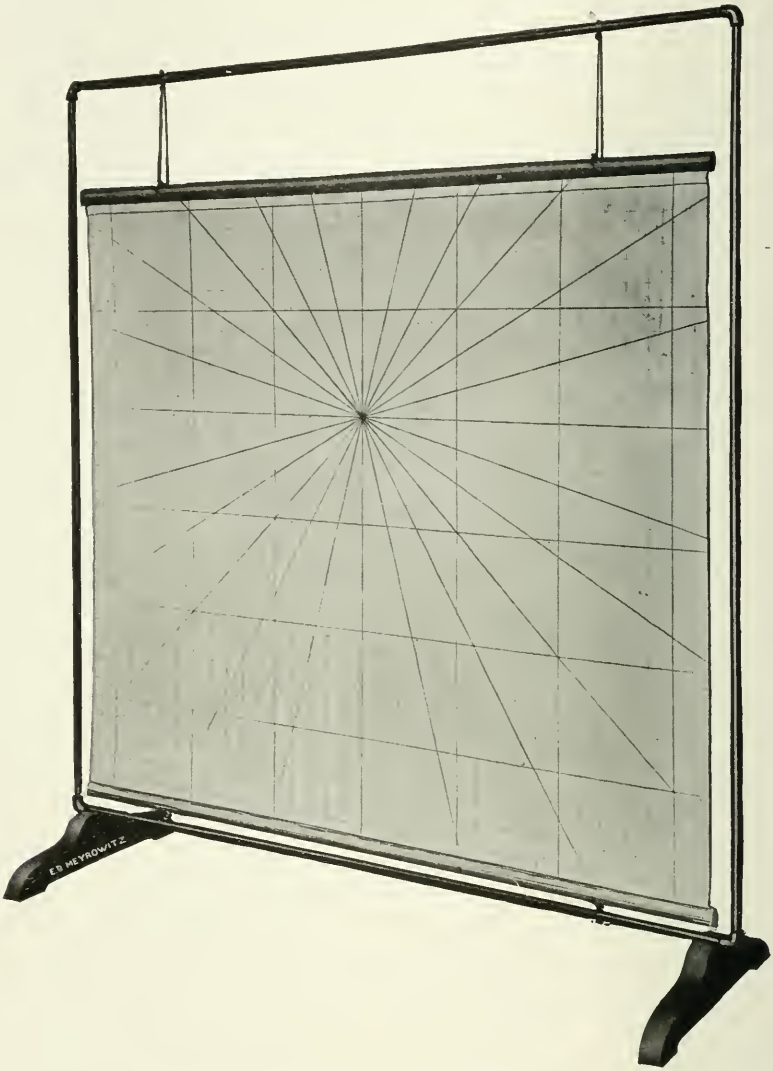

Bjerrum Tangent Plane Screen Designed by Alexander Duane.

A somewhat similar screen has been employed by Alexander Duane, and is described by him in the *Archives of Ophthalmology*, Vol. XLIII, No. 6, 1914. In this article he states that the tangent curtain (see

illustration) consists essentially of a curtain, black on one side and white on the other. The front or black side is made of outing flannel and this is stitched onto the rather stiff, unbleached muslin that forms the white backing. On the white side is drawn a perimetric chart consisting of a series of lines radiating from a common centre; each line forming an angle of 15 degrees with its neighbor. The surface is further divided by light and heavy perpendicular and horizontal lines into a checkerboard of two-inch and ten-inch (or 5 cm. and 25 cm.) squares.

The black surface, or front of the curtain, is marked only by a white pin indicating the exact position of the centre of the perimetric chart on the white or reverse side, by a vertical and horizontal black seam representing the vertical and horizontal meridians of the chart, and by a series of short, red strokes along its edge, each indicating the terminus of one of the radiating lines on the reverse side. This useful feature of the apparatus is borrowed from Syms and Sinclair.

The frame on which the curtain is stretched runs up and down in an outside frame so that the white pin, which indicates the centre of the perimetric chart, can be brought just opposite the eye of a patient seated in front of the instrument. The curtain frame is raised and lowered by a pair of cords which run over little pulleys set in the outside frame and which are attached to a horizontal rod at the back of the curtain. The ends of this rod engage in a series of hooks on either side of the outside frame. By pulling on the rod the curtain is raised, and by engaging the rod in the hooks the curtain is set at any desired height.

The outside frame is 6 feet 6 inches high, and 5 feet wide. The curtain itself is 5 feet high, and 4 feet 5 inches wide, giving, if the patient is seated at 30 inches, a lateral range of 41 degrees, an upward range of 35 degrees, and a downward range of 52 degrees. If the patient is seated at sixty inches, the lateral range of the curtain is 23 degrees, the upward 20 degrees, and the downward 33 degrees.

The whole apparatus is strong, light, and portable, so as to be readily shifted from one part of the room to the other. It can be used advantageously as a screen to shut off a corner of the office or, when not in use, can be set against the wall.

The material of which the curtain is made is such that, no matter how often it is perforated with pins, no marring marks remain.

The apparatus is used regularly at two distances, 30 inches (0.75 metres) and 60 inches (1.50 metres), and corresponding to this there are two sets of record cards, shown respectively in figs. 2 and 3. It is convenient to have a tape measure about five feet long, one side

of which is marked with the tangents of arcs of 5 degrees, 10 degrees, etc., to a radius of 30 inches and the other side with the tangents of

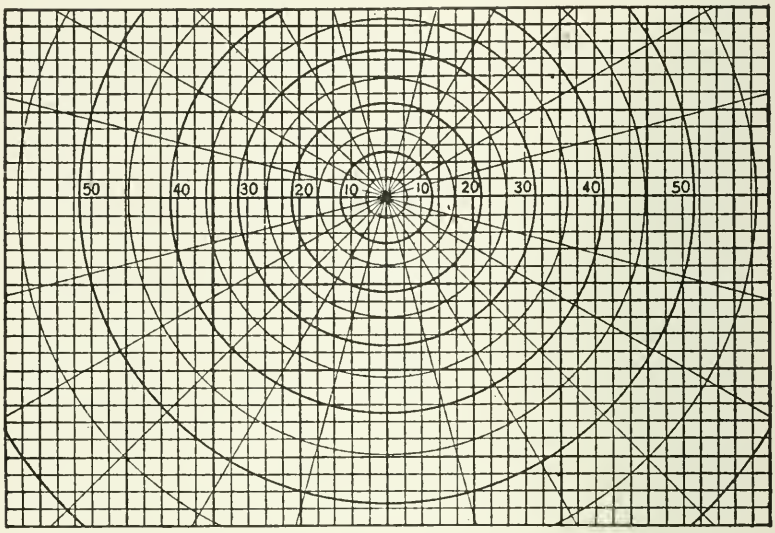

No. 1 Card for Use with Duane Tangent Curtain.

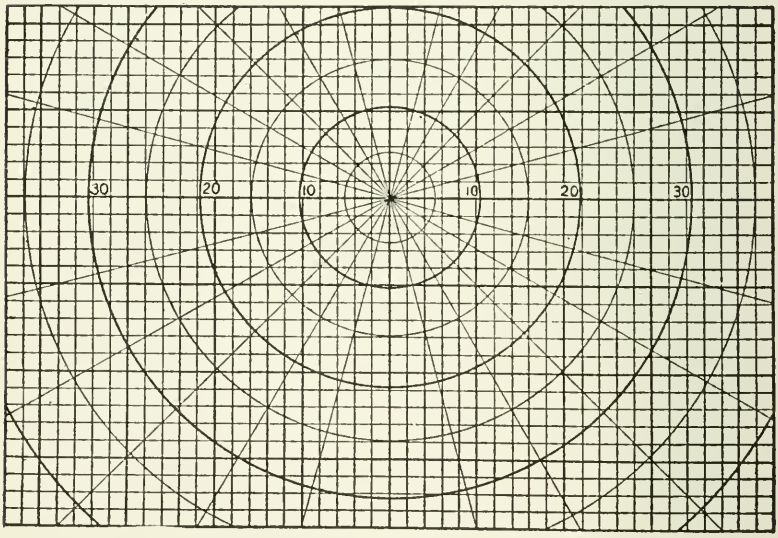

No. 2 Card for Use with Duane Tangent Curtain.

the same arcs to a radius of 60 inches. This can be used to measure the distance, in degrees, of the test object from the central pin. It is

particularly of service when for any reason the test object has to be carried beyond the limits of the curtain.

The curtain can also be used at any other distance, e. g., one metre, provided he who uses it has a card or record blank marked for this distance. However, the distances given, viz. 30 inches and 60 inches, have proved best adapted for the various uses to which the curtain is applied.

The tangent plane is used for the following purposes:

1. To delimit central and paracentral scotomata and enlargements of the blind spot.—For this purpose the 60-inch distance is used. The patient is seated at this distance from the curtain, the black side of which is turned toward him. The curtain is raised or lowered until the white pin representing the centre of the perimetric diagram is just opposite the eye to be examined. The other eye is covered. Then directing him to look steadily at the central white pin, we carry our test object from the periphery of the curtain to its center along each meridian in succession. The marginal strokes at the edge of the curtain help greatly in doing this, as they indicate where each meridian terminates. The points where the test object enters the scotoma and where it emerges from it in each meridian are indicated by thrusting pins into the curtain. Different colored pins may be used to differentiate partial from absolute scotomata, or to differentiate color scotomata from scotomata for white. They may also be used to differentiate two or more records taken in succession, when for any reason it is desirable to leave them on the curtain. It is advantageous to have small and dull-colored pins, so that when inserted in the curtain they shall not be obvious to the patient nor distract his attention.

Enlargements of the blind spot are plotted in an entirely similar manner. In delimiting these and also scotomata, it has been found convenient to use two objects (e. g., two white-headed hat-pins) simultaneously. These are carried from opposite sides of the scotoma toward each other until the patient says both are extinguished. Then the two are gradually separated until the patient says he is just aware of both at the opposite margins of the scotoma. The position of each is then marked by a pin. The distance between the pins will then represent the diameter of the scotoma in the given meridian, and will show the precise length of the diameter even when the eye wavers, so that we cannot be certain just where the two extremities of this diameter really are.

All sorts of test objects may be used, according to the character of the scotoma. Often it is useful to apply test objects of different sizes

and determine the comparative magnitude of the scotoma with each. As pointed out by the English observers, fine bits of blotting paper, which will stick to the fuzzy surface of the black cloth wherever they are laid on it, form an excellent test. A number of them can be rapidly shifted till they form a ring just outside of the limits of the scotoma, which is thus accurately depicted.

2. To delimit the field of vision.—The tangent plane cannot be used to delimit the visual field except when the latter is pretty contracted. When this is the case and particularly when we are dealing with a somewhat contracted color field or with a hemianopsia, it is very serviceable. In this case we set the patient at 30 inches, but otherwise proceed as already described.

3. To plot the field of fixation.—The tangent plane may sometimes be used instead of the perimeter or tropometer, for plotting the monocular field of fixation. The patient is then seated 30 inches from the curtain with his head immovably fixed and with one eye covered. The other eye should be precisely opposite the white pin and on a level with it. This eye is then made to follow the test object (a pair of fine parallel lines on a small card) as far as it can in each meridian. The limit of the excursion in each case, which will be signalized by the blurring and running together of the two lines, is marked by a pin thrust into the curtain. Whenever the limits of the field extend beyond the limits of the curtain, the tangent tape already mentioned may be attached to the center pin and measurement made along it in any given meridian beyond the curtain margin.

4. To plot diplopia and the field of double vision.—Here again the patient is placed 30 inches from the curtain, but now with both eyes open. A red glass is placed before the right eye and the head is adjusted so that when the eyes are directed at the centre pin, they are on a level with it and looking straight ahead. A small electric light is then carried over the curtain in the six cardinal directions of the gaze, viz., right, left, up and right, up and left, down and right, down and left; and the point where diplopia occurs in each meridian is noted by thrusting in a pin. The limits of the field of single vision are thus delimited. In the region in which diplopia occurs, the situation of the double images is similarly indicated. The patient sees two lights, a red and a white. The red image belongs to the right eye and the white image to the left. A black pin is thrust into the curtain at the site of the candle itself, and a light-colored pin at the site of the other image. This latter is evidently the false image and, if it is red, we know that the left eye is fixing; if it is white, we know that the right eye is fixing. In the former case, we mark the situation of this

false image with a white pin; in the latter case, with a blue pin. In the great majority of cases the patient fixes with the eye not covered with the red glass: and, therefore, by shifting the red glass from one eye to the other, we can often get him to alternate fixation. In this case, too, we put in a black pin at the site of the light (indicating thus the image of the fixing eye) and mark the site of the false image by a white pin when this image corresponds to the right eye, and by a blue pin when it corresponds to the left eye. We then have on the curtain a black pin with a white pin at some distance from it in one direction and a blue pin at a greater or less distance from it in the other direction. In this case the situation of the pins indicates not only the relation of the double images and their degree of separation, but also the change produced in the amount of diplopia by changing fixation from one eye to the other. It shows, in other words, the relation between the primary and secondary deviation.

In plotting the field, or the limits of the scotoma, or the situation of the double images, the diagrams, which are made by the pins stuck into the curtain, are transferred to one of the cards already referred to; to card No. 1 if the patient was at 30 inches, and card No. 2 if the patient was at 60 inches. The plot may be made from either the front or the back of the curtain. In the latter case we have the diagram on the back of the curtain to aid us. It is then easy to see in which particular square of the diagram a pin protrudes and mark its situation on the corresponding square of the card. Only we must remember that as we are now looking at the back of the diagram, instead of its front, we must, when we transfer it to the card, either reverse it, putting on the right side of the card the marks that appear on the left side of the curtain, and vice versa; or else we transfer the diagram just as it is and mark the left side of the card "right," and the right side "left."

In plotting from the front of the curtain, we use the vertical and horizontal seams intersecting at the central pin. Along these we measure either with the tangent tape or with an inch rule, determining thus the height in degrees or inches, of each pin along the horizontal seam and its distance, right or left, from the vertical seam. We then transfer our measurements to the proper card. In doing this, we obviously do not have to reverse our plot, the right hand of the card now representing the right hand of the curtain. But, in any case, we should mark the card so as to show clearly which part of the diagram corresponds to the patient's right hand and which to his left.

However made, the card diagrams are an exact representation of the original diagrams on the curtain. Records made at different times

are readily comparable and indicate clearly the progress of the case. The network of squares and circles on the cards gives us a double means of measuring and comparing our results: the squares giving our measurements in inches or centimetres; the circles, the same results in degrees of arc.

Other methods for the discovery of *scotomata* have been described in which the result is accomplished by the aid of the scotometer.

The one described by Priestley Smith (*Trans. Ophth. Soc. of Unit. King.*, Vol. XXVI) was mainly designed for the detection of sector scotoma in glaucoma. A 2 cm. square piece of blotting-paper, or a small cutting of gray wool, is placed upon a disc covered with a black cloth, upon the back of which the degrees of the circle are marked. The patient's distance from the disc is fixed by a movable handle and knob to be held against the cheek below his eye. The test is placed 25 degrees from the centre of the disc, the eye being fixed upon its centre, and the instrument is slowly rotated. If it does not disappear or grow dim, the scotoma of glaucoma is probably not present, because as Bjerrum has shown, these defects are usually sector-like and therefore would be crossed by the test in its rotation.

Bardsley (*Trans. Ophth. Soc. United Kingdom*, Vol. XXVIII), has also lately invented a new scotometer. To the patient it presents a dull-black, concave surface of the segment of a sphere, with the fixation disc at the center, and the movable test object. Through a small opening in the fixation disc the surgeon, hidden behind it, watches the fixation of the patient's eye, moves the test object by a button, and reads off the distance from the fixation point on one scale, while the meridian in which the test object is being used is indicated by a scale on the circumference. The instrument is expected to show with more ease and accuracy the scotomas of glaucoma, retinitis pigmentosa, toxic amblyopia, etc.

Hayeraft's scotometer (*Lancet*, August, 1911), requires mention. It was devised for mapping out the blind spot. The ground is a black metal plate, on which a nail carrying the test object can be moved by a screw, horizontally or vertically. The position of the test object may be registered by pressing the nail on a sheet of paper carried at the back of the instrument. He has demonstrated that the margins of the blind spot are color-blind, the colors being recognized in the following order: blue, yellow, green and red.

To overcome the practical difficulties of mapping a central scotoma, or the blind spot, Fridenberg suggests a black background covering 10 degrees to 15 degrees, that could be attached to the ordinary perimeter. He also proposes a stereoscopic attachment to use binocular

fixation; and a small electric light of variable color for the test object.

A scotometer for measuring central scotoma has been devised by Hird (*Ophthalmoscope*, X, p. 142). The ground is of dull black, with a circular opening of 10 mm., which can be narrowed to 5, 2 or 1 mm., by a sliding diaphragm. By a milled wheel, either white, red, green or blue is brought to the opening. The thin diaphragm, fitting closely to the color circle, throws no shadow on its margin. The instrument can be carried in the vestpocket.

Holloway (*Am. Oph. Soc.*, XII, p. 966), suggests a jointed stick for use in taking the field by Bjerrum's method. The test objects, disks of paper, are gummed to the end of the rod. The stick may also be used with a hand perimeter; or without a perimeter, for rough testing of the field. Fleischer (*Klin. M. f. Augenh.*, July, 1912, p. 62), calls attention to the Bjerrum method as though it were not generally known and used in Germany. He urges its value in the early diagnosis of glaucoma.

The size and position of the blind spot with reference to the fixation point, have been investigated by Van der Hoeve (*Arch. of Ophth.*, XL, p. 30). In 100 eyes of young persons 18 to 20 years, emmetropic to within 1 D., he found that the centre of the blind spot was distant from the fixation point 15 degrees, 4 minutes in the right; 15 degrees, 24 minutes in the left eyes, in the horizontal direction; and 1 degree, 33 minutes right, 1 degree, 48 minutes left, vertically. Its horizontal diameter was 5 degrees, 40 minutes right, 5 degrees, 46 minutes left. Its vertical diameter 7 degrees, 21 minutes right, 7 degrees, 32 minutes left. He also noted the failure of color perception when passing into the blind spot, as demonstrated by Haycraft. This ring of failing color vision was, however, only ⅛ to ¾ of a degree wide.

For a rapid test for central scotoma Snydacker (*Arch. Ophth.*, XL, page 149), has placed on the ordinary test chart small squares of red 2½ mm. and 5 mm., and green, 3 mm. and 6 mm. When the patient cannot recognize the colors of these at 6 metres, it is pretty good evidence that the central color perception is subnormal; and careful investigation by other tests is called for.

To map scotomas Tomlinson (*Trans. Ophth. Soc. United Kingdom*, XXX, page 111), has arranged what he calls a scotomograph. It consists of a tube or casing, to one end of which the eye is applied, while the other contains a small point admitting light. The source of light is kept fixed with the other eye. Within the tube a hinged mirror reflects the light into the eye, as though it came from a second point at the virtual image of the hole. The relations of the different points

are shown in the cut. By changing the inclination of the mirror the image reflected by it is moved to different distances from the centre of the field. By revolving the tube around its axis the mirror image is made to describe a circle. Connected with the mirror is a small needle, which may be made to perforate a diagram by pressing a pneumatic ball, such as is used to operate a camera shutter.

Holth (*Annales d'Oculistique,* September, 1908), makes use of an ingenious apparatus for the diagnosis of central color scotoma which consists of an ebony plate sixteen cm. long and two cm. wide, in which, four cm. apart, are three red objects, ten mm. in diameter on one side of the plate and 5 mm. in diameter on the other side. The colored objects are formed by filling in depressions in the plate with sealing wax and polishing it down to a surface even with that of the plate. This is easily kept bright by washing with soap and water. In using

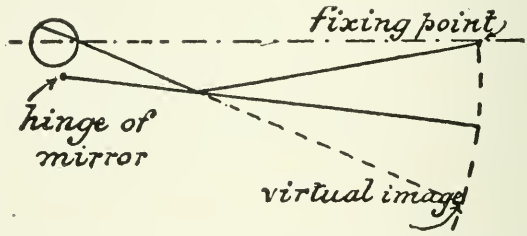

Diagram of Tomlinson's scotomograph, showing how the hinged mirror gives a reflected image which serves as a test object, the point of light being used as the fixing point. The angle to which the mirror is swung determines the angle to which the virtual image is removed from the fixing point.

the instrument it is held horizontally thirty cm. before the eyes of the patient, who sits with his back to a window and fixes the central object. In the early stages of alcohol or tobacco amaurosis the object on the temporal side is more or less decolored. When the scotoma is absolutely central the middle object is decolored. In the paracentral scotoma of the later stages of tobacco amaurosis the middle object is affected as well as the temporal one. In the case of red-green color-blind patients, bluish-grey was used for the color objects.

As a time-saving method of examination, and in order to detect slight color scotomata which might be present in eyes that present no fundus changes and have normal vision, Snydacker (*Archives of Ophthal.,* March, 1911) has made use of small colored squares which he has placed on his test chart. He uses red squares 2½ mm. and 5 mm. in size and green squares 3 mm. and 6 mm. in size, the test being made at 6 metres. When a patient cannot distinguish the smaller

squares, the author is suspicious of a color defect and makes a careful perimetric examination. He cites several cases where he has detected slight central color defects when he might otherwise have overlooked them, and concludes that this test is a valuable and time-saving aid in the detection of central color scotomata for red and green. See also **Cruises central color scotometer,** Vol. V, page 3572, of this *Encyclopedia.*—(A. S. R.)

Exanastomosis. (L.) A form of anastomosis.

Exangeia. (L.) (Obs.) Dilatation of a blood-vessel.

Exanopsiâ. (L.) From disuse—as in a functional amblyopia due to causes preventing employment of the eyesight.

Exanthemata, Ocular complications of the. The eye symptoms and lesions that accompany or follow the eruptive fevers, especially those of the better known contagious and infectious exanthems, will be considered each under its own separate heading. Here it is proposed to speak of but one, albeit serious, aspect of these infections, the occurrence of optic neuritis, especially in measles, scarlet fever, influenza and typhoid fever.

Dutoit (*Archiv f. Augenheilk.*, Vol. 71, p. 1) has summed up the matter as regards the exact etiology. He finds that in the chronic infectious diseases, chiefly syphilis, tuberculosis and influenza, this is well worked out, while the eye complications of acute infectious diseases are rarely mentioned in literature. He attributes this to the fact that acute infectious diseases, especially of children, are mostly treated at home and therefore are not systematically examined with the ophthalmoscope. A certain number of such cases escape observation, as they frequently occur in children who generally do not complain of defect of function. Also, infectious optic neuritis occasionally affects only one eye, so that the impairment of vision may not be noticed. Finally, the favorable course of exanthemata contributes to its apparent latency.

Uhthoff believes that in cases of optic neuritis after measles, scarlet fever and typhoid, meningitic complications through increased intracranial pressure may cause choked disc, which arouses the erroneous impression of a specific optic neuritis. Dutoit says that this can be easily decided by lumbar puncture, and other diagnostic methods of internal medicine and by certain peculiarities of meningitic choked disc (e. g., involvement of the intermediate zone) in comparison with papillitis from infectious or toxic causes. The analysis of the urine is very important in deciding the etiology of some forms of toxic papillitis, and even more in optic neuritis with such endogenous infections as albuminuria, diabetes mellitus, etc. Rise of temperature is

also a determining factor in separating infectious optic neuritis from toxic neuritis.

As a proof of his views, the writer reports the clinical histories of two cases of optic neuritis after measles, one after scarlet fever, and one after typhoid. The optic neuritis occurred late, from 15 to 20 days after the onset of the general disease, and thus had the character of a paraspecific affection. The diagnosis of paraspecific optic neuritis and its discrimination from meningitic papillitis rest on the negative result of lumbar puncture, the clinical observation in general, and on the, although not quite conclusive, ophthalmoscopic examination. Meningitic papillitis and choked disc are characterized by more or less prominence and considerable enlargement of the optic disc in all diameters, due, according to Schieck and Kuhnt, to a swelling of the intermediate tissue, which under normal conditions is invisible. The pathogenesis of paraspecific optic neuritis has nothing to do with increased cerebral pressure and is not brought about in a mechanical way, so that there is no constriction choking of the disc nor imbibition of the intermediate tissue.

The predisposition to paraspecific optic neuritis in these cases is due to diminished power of resistance in consequence of the retarded reconvalescence. The remarkably favorable course of all cases under treatment with emulsion of cod liver oil was, according to Dutoit, encouraging, and Dutoit recommends it for further trials.

In two cases of influenza the optic neuritis set in with fever and symptoms of a more or less manifest cerebral irritation. Lumbar puncture was negative.

The writer considers optic neuritis as a co-ordinate manifestation or localization of influenza. The affection of the optic nerve leads, according to its intensity, to some general phenomena which are partly signs of a hematogenous infection, partly of cerebral irritation.

From the favorable course of his cases the writer believes that in the papillitic form of infectious optic neuritis the prognosis is good.

The reader who wishes to make a further study of this matter is advised to consult J. M. Griscom (*Annals of Ophthalm.*, Vol. xx. p. 285, 1911

Exanthematophthalmia. (L.) An obsolete term intended to indicate an inflammation of the conjunctiva and eyelids, and sometimes of the eyeball, following a cutaneous eruption, especially a febrile exanthema.

Exarma. (L.) (Obs.) A projecting tumor.

Exarteriitis. (L.) Inflammation of the outer coat of an artery.

Excandescence. EXCANDESCENCY. A white heat.

Excavation of the optic nerve. A hollowing or "cupping" of the disc, or optic nerve entrance, that may be *physiologic* or *congenital,* and without particular significance; or *pathologic,* the result of glaucoma, optic atrophy, etc. (Gould.) See **Glaucoma.**

Excentric. ECCENTRIC. Out of the center or median line.

Excès. (F.) Excess.

Excipient. Any indifferent substance serving to give form, consistence, etc., to a medicinal substance blended with or dissolved in it.

Excision of the lachrymal sac. See **Lachrymal sac, Excision of the;** as well as **Lachrymal apparatus, Diseases of the.**

Excision of the tarsus, Combined. See **Tarsus, Combined excision of the;** as well as **Trachoma (operations).**

Exciting eye. THE EXCITER. In sympathetic ophthalmia the injured eye. See **Sympathetic ophthalmia.**

Excluded pupil. Adhesion of the entire pupillary margin of the iris to the lens. See **Annular synechia.**

Exclusion. This term has various applications in ophthalmology. Among them is *exclusion of the pupil,* or annular synechia (q. v.); another refers to *exclusion* or suppression *of the image,* as in a deviating eye when cerebral impressions and interpretations are in abeyance, or are lost.

Excochleation. The operation of curetting a cavity, as of the orbit or conjunctival sac.

Excœcaria agallocha. (L.) This is a species of the *Euphorbiaceæ,* whose juices are extremely irritating. When an eye is injured by contact with a twig or branch the sap from it sets up an acute ocular inflammation (with marked keratitis, etc.) that may end in blindness.

Excrescentia fungosa. (L.) An ancient and now obsolete term given to the last stages of an intraocular glioma.

Excrescences, Colloid. See **Colloid bodies.**

Excursion test. The extent to which both eyes can move in various directions and yet maintain binocular fixation. It is usually applied roughly by means of a pencil-end (or similar object) carried through the six cardinal directions and observing at what point either eye lags behind or wanders away from the fixation point.

Exenteration. In ophthalmology, the operation of removal or evisceration of the contents of the eyeball or of the orbit; in the former instance leaving the globe as a stump in the orbital cavity. See **Enucleation.**

Exenteration of the eye. See **Enucleation of the eye and its substitutes.**

Exenteration of the orbit. EVISCERATION OF THE ORBIT. The removal of the contents of the orbital cavity. Extirpation of the contents

of the orbit may be partial or complete, and is required when enucleation or an osteoplastic resection is insufficient to eradicate the orbital disease. For a complete account of the various operations under this head, see **Orbit, Diseases of the.**

Exenteratio orbito-sinualis. GOLOVINE'S OPERATION. In extirpating orbital neoplasms, especially of the malignant type, Golovine (*Annals d'Oculist.*, Vol. 142, Dec., 1909) devised a method which has for its object the conversion of the orbit and surrounding cavities into one single space, thus permitting the new growth to be completely removed. See **Orbit, Diseases of the.**

Exenterisis. (L.) Exenteration.

Exenterismus. (L.) Exenteration.

Exérèse. (F.) Excision.

Exeresis. (Obs.) Surgical removal, as by excision, evacuation or extraction.

Exidia auricula Judæ. JUDAS'S-EAR. JEW'S-EAR. An astringent fungus once used in diseases of the throat, in dropsy, and in ophthalmia.

Exit-port. In *optics,* the image of the annular diaphragm that is formed by that part of the optical system which lies behind the diaphragm or aperture-stop.

Exit-pupil. In an optical system a *virtual* aperture-stop conjugate to the entrance-pupil.

Exitura. (L.) An old name for an abscess; also a term applied by Paracelsus to a purulent or putrid discharge.

Exner's color-figures. These are due to homogeneous red, green, and blue light falling successively but interruptedly upon the retina. The red figure is Medusa-shaped, with its centre in the macula. The green figure consists of a number of small black spots covering the green field, and the blue figure takes the form of dark-blue, large, sharply-defined spots.

Exocataphoria. This term has been used to denote the tendency of the visual line in an inward and downward direction.

Exoculation. Removal of the eyeball. Destruction of eyesight.

Exogenous. Acting from the outside; external.

Exoine. (F.) A medical certificate given to insure exemption from some duty, legal or other.

Exoncoma. (L.) (Obs.) A prominent tumor.

Exophoria. WEAKNESS OF ADDUCTION. INSUFFICIENCY OF CONVERGENCE. EXCESSIVE DIVERGENCE. In this oculomuscular anomaly the visual lines tend to diverge, although this tendency may not be visible to the observer and must be developed or proved by certain tests, generally instrumental.

As the word indicates, there is a tendency on the part of the external recti muscles and their synergists to make the visual axes deviate from the point of fixation. If this tendency were not counteracted by antagonists of the externi, the visual axes would either intersect beyond the point of fixation, or they would become parallel or even divergent. Abnormal nervous tension of the interni and their synergists counteracts the inherent tension of the externi and their synergists, so that the tendency is not allowed to become a turning. The visual axes are thus forced to intersect at the point of fixation; and binocular single vision is maintained, but at the expenditure of an undue amount of nerve force. Exophoria, like esophoria, is of two kinds, intrinsic and false. As to causation, the one kind is wholly different from the other, but the two often coexist. As to the results, the one is the same in kind as the other, but the treatment of the one is not at all similar to the treatment of the other.

Intrinsic exophoria.—In this the externi have the advantage over the interni. This imbalance may be due to the fact that the externi are hyper-developed or that the interni are of subnormal development. It may be that the error is not in the size of the muscles, but in the nature of their attachment to the globe, the externi having their attachment nearer the corneo-scleral junction than normal, or that the interni are attached too far back; it may be that the externi are short and tense or that the interni are long and somewhat lax. When either of these conditions causes exophoria, the error may be greater in one eye than in the other, though, as a rule, the exophoria is about equal in the two eyes. When there is a difference, the monocular phorometer quickly shows it.

It must be conceded that the cause of intrinsic exophoria may not reside in the muscles themselves, but may be found in an unequal supply of nerve force, the centers for the externi generating a quantity of nerve impulse greater than normal, or the third conjugate brain-center, of subnormal development, sending a weaker current to the interni.

An intrinsic exophoria can exist without there being a state of imbalance between the externi and the interni. The oblique muscles are always more or less powerful as abvertors. There is but little room for doubt that, in some cases, they may be too short and tense, or they may be too large and powerful, or their attachments may be nearer the posterior pole than normal, so that, in either case, their abverting power would be increased. This increase may be sufficiently great to cause an exophoria, even when there is no cyclophoria.

Malformation of the orbits, only in the sense of their being too far

apart, can cause an exophoria; but when this cause exists alone, the muscle imbalance cannot be great.

The superior and inferior recti may have their attachments so far toward the temples as to greatly lessen their power to help the interni, and thus become a factor in the production of exophoria.

Whether the one or the other of the several conditions named is the cause of exophoria, or whether two or more of them become factors in the production of this error, the treatment, whether surgical or non-surgical, must be directed toward the lateral muscles. As to surgical means, either the tension of the externi must be lessened or the tension of the interni must be increased. If brain-centers are structurally over-developed or under-developed, they must remain so always; if the obliques, because of structure, attachment, or innervation, abvert too powerfully, they cannot be changed; if the orbits are too wide apart, surgery cannot bring them closer together. If the superior and inferior recti, because of faulty attachments, are feeble advertors, they must not be subjected to operations on this account. For these reasons it becomes apparent that any and every treatment of intrinsic exophoria, whatever may be the cause, must be directed toward the externi or toward the interni. An exophoria that is wholly muscular, all innervation centers being normal, will show the same number of degrees in the near as in the far.

Intrinsic exophoria is of two kinds, sthenic and asthenic. The quantity of the error does not determine its character. Only the abduction and the abversion tests, in any given case, can tell the operator that the error is sthenic or that it is asthenic. Exophoria with abduction of less than 8° and abversion of less than 50° is asthenic, and clearly indicates that the externi should not have their tension lessened, and just as clearly indicates that the interni must have their tension increased. Exophoria with abduction of more than 8° and abversion of more than 50° is sthenic, and the case should be treated with the view of lessening the tension of the externi.

Tests in myopic and emmetropic cases will always show the full amount of intrinsic exophoria in the far. In the near test of a myope, the intrinsic exophoria will have the associated pseudo-exophoria added to it. If the emmetrope does not show the same exophoria in the near as in the far, it is increased or diminished because of an abnormal development of the ciliary muscles. If the ciliary muscles are hyper-developed, there will be more exophoria in the near than in the far, for the reason that an impulse less powerful than normal is required of the brain-center controlling them, so that a correspondingly slight associated impulse is sent to the interni. If the ciliary

muscles are subnormally developed, they will require an impulse more powerful than the normal, and a correspondingly strong associated impulse must be sent to the interni, causing a pseudo-esophoria, which, to a certain extent, would neutralize the intrinsic exophoria.

The hyperope will always show less than the full amount of intrinsic exophoria in both the far and the near tests, for the reason that hyperopia always has a pseudo-esophoria associated with it, which neutralizes in part an existing intrinsic exophoria.

Pseudo-exophoria.—There can be but two causes for this condition. One is myopia, or myopic astigmatism; the other is hyper-development of the ciliary muscles, making it necessary for the centers controlling them to generate a less powerful nerve current than would be required by these muscles if normally developed.

When the cause is myopia, or myopic astigmatism, the pseudo-exophoria shows itself only in the near, and is due to the fact that the guiding sensation calls either for no nerve force to excite ciliary action or for a quantity less than is required by an emmetrope, depending on the amount of the focal error; and a correspondingly slight associated impulse is sent to the interni. If the point of view is 16 inches distant, there should be 1.8° of pseudo-exophoria for each dioptre of myopia up to 2.50 D, and .9° for each dioptre of myopic astigmatism up to 5 D. This kind of pseudo-exophoria does one of three things: (a) it increases an intrinsic exophoria in the near, (b) it shows an exophoria in the near when there is real orthophoria, or (c) it lessens an intrinsic esophoria in the near.

When the pseudo-exophoria is due to a hyper-development of the ciliary muscles and the patient is an emmetrope, the error will show itself only in the near test. If a 1.50 D impulse is all that is necessary to effect a 3 D contraction of the ciliary muscles, the pseudo-exophoria, with the test object at 13 inches, should be 2.7°. This may manifest itself in the same three ways as that caused by myopia. Strictly speaking, a pseudo-exophoria cannot exist in a hyperope; although the hyperope who has hyper-developed ciliary muscles will show a less amount of pseudo-esophoria than would be shown if these muscles were of normal development. The difference in amount is equivalent to pseudo-exorphoria.

When the far test shows orthophoria and the near test shows exophoria, the error is pseudo in character, and is dependent on one or other of the two causes above mentioned; and the same is true when an exophoria is less in the far than it is in the near. The same explanation applies when there is esophoria in the far and exophoria in the near. If in an emmetrope there is more exophoria in the far

than there is in the near, the ciliary muscles are subnormally developed, and require an excessive impulse to make them perform their work. The associated impulse to the interni is correspondingly great.

There is a form of exophoria not yet referred to, and probably not fully set forth in any book. The cause unquestionably resides in the third conjugate innervation center, and is structural in character; in other words, the third conjugate innervation center is subnormally developed, and, for this reason, sends a feeble impulse to the interni. The most exaggerated manifestation of this condition would lead one to judge that this brain-center is entirely absent, for occasionally a case is seen which has no power of convergence. Such a person enjoys binocular vision in the distance, but has only monocular vision in the near. In such a case there is no adduction power, for the one visual axis cannot be made to approach the other. Abduction will be normal or even above the normal. Adversion is unimpaired, showing that the fourth and fifth conjugate innervations have full sway. The abversion of the right eye equals the adversion of the left eye, and, *vice versa,* the abversion of the left eye equals the adversion of the right eye. In these movements the visual axes are kept parallel, as when the eyes are looking straight ahead. That the condition is congenital in most cases is shown by the fact that there is no diplopia in the near. This must be due to an acquired mental suppression of images that fall on the temporal half of the retina, or, at least, a portion of it. The power of mental suppression can be acquired only in the earliest years of life. Hansell and Reber speak of a patient in whom this loss of convergence power was acquired, the result of some disease process in the part of the brain in which is located the convergence center. It is reasonable to suppose that this center might be destroyed by disease. In such a case, however, diplopia would exist everywhere except in the distance.

If the third innervation center can be entirely absent in one person and be present and fully developed in another, it is reasonable to conclude that in still another it may be present, but in a state of subnormal development. There may be as many different grades of development of this as there are individuals; but in the majority of persons this center is able, doubtless, to generate 1° of impulse for every 1° of convergence, in association with the center of the ciliary muscles.

Subnormal development of this center must manifest itself in an exophoria in the near many degrees in excess of the exophoria in the far (of itself it can never cause exophoria in the far, but it may be associated with some of those conditions that cause intrinsic exo-

phoria) ; or, if there is orthophoria or even slight esophoria in the far, there will be considerable exophoria in the near. The two ordinary causes of pseudo-exophoria—that is, myopia and hyper-developed ciliary muscles—will not cause more than 5° of the error. A greater degree of variation between the far and the near tests than this, in the exophoric direction, must be attributed to a subnormally developed third conjugate brain-center. A diagnostic feature of this condition is the manifestation of very low abduction power—much lower than is found in intrinsic exophoria of the same degree.

It is barely possible that a failure of connection between the ciliary center and the convergence center accounts for the absence of convergence power in some cases; and a slight connection may account for a feeble convergence.

Tests for exophoria.—The cover test, allowing the eye to turn toward the temple, will be attended by a resetting of the eye toward the nose when the cover is removed, and the false object will move rapidly toward the corresponding side until fused with the true object. The examiner can often see the resetting of the eye, but not so readily as an intelligent patient can detect the apparent movement of the test object.

The red glass, in the higher grades of exophoria, will develop crossed diplopia. The distance between the red light and the true light will give a fair idea of the quantity of the error. This test, resulting in crossed diplopia, practically always indicates operative treatment: but since it does not show whether the case is sthenic or asthenic, it cannot indicate the character of the operation to be done.

The double prism held before the right eye so that the two lights seen through it shall be in the same vertical line, the light seen by the left eye will be to the right, if there is exophoria. The extent of the error is shown by that prism, base toward the nose, that will place the middle light in line with the other two. This test, so far as it goes, is safe and accurate; but it cannot show whether the exophoria is sthenic or asthenic, and cannot, therefore, be relied upon in answering the question: "What operation, if any, shall be done?"

The single six-degree prism, held base up before the right eye, with the axis perfectly vertical, is as reliable as the double prism, though one can never be so certain that the axis is vertical as he can be when using the double prism. The lower, or false, light will be on the opposite side—crossed diplopia. The prism, base in, that brings it directly under the true candle, measures the amount of the exophoria. Like the double-prism test, this one does not show whether the exophoria is sthenic or asthenic.

The rod test is less reliable in exophoria than in esophoria, for the reason that images displaced in the temporal part of the retinal fusion area seem to excite a greater demand for fusion than when displaced in the nasal part. Nevertheless, if the exophoria is sufficiently great, the rod held with its axis horizontal before the right eye will cause the streak of light to appear to the left of the candle. The prism, base in, that brings this vertical streak into the candle, measures, but not with accuracy, the exophoria. It always shows less exophoria than really exists. Maddox thinks that a red rod makes this test practically perfect, if, at the same time, a plain green or blue glass be held before the other eye.

The safe, sure, speedy, and easy test for exophoria is by means of the phorometer, and of all the phorometers the monocular is the most reliable in its results. The method of testing for exophoria is the same as that for esophoria, the position of the false object always determining whether it is the one or the other error. It is always on the opposite side in exophoria. The error is measured by revolving the rotary prism until the false object is brought under the true object, when the index will mark the quantity of the error. In the same way the other eye should be tested. In the phorometer test, as in all others, the exophoria at 16 inches should also be determined.

The next step is the taking of the abduction. This is the chief means for determining whether the exophoria is sthenic or asthenic. Unless the character of the error is known, it is not possible to resort to rational treatment. Whatever means may have been used in detecting the imbalance, the lifting power of the externi—abduction—must be taken.

This can be done, but not quickly nor accurately, by holding prism after prism, base in, before one eye, until the patient can no longer fuse the images. The chief objection to this method is the uncertainty about the axis of this prism being perfectly horizontal. The rotary prism of the phorometer, the instrument being perfectly leveled, is the quickest and best means for determining abduction or any other kind of duction. To test abduction with the rotary prism, the handle must be horizontal and the index must start from zero. Moving the index toward the temple it must be stopped the moment the patient says the test object becomes double. The index stands opposite the number indicating the degree of abduction. If this is less than 8°, the exophoria is asthenic; if more than 8°, it is sthenic. If abduction is just 8°, since it would indicate that the tension of the externus should not be lessened, the exophoria should be classed as asthenic, from an operative standpoint.

Lastly, abversion should be taken either with the perimeter or the tropometer. This will usually be found less than 50° if abduction is low, and more than 50° if abduction is high.

While abduction and abversion are to be relied on most, adduction and adversion should always be taken. In fact, the study of no one muscle error is complete until all other errors have either been found or eliminated; and the individual strength of every muscle must be known. It is only in this way that the real nature of an exophoria can be known, and without this knowledge, rational treatment is impossible.

Complications of exophoria.—These are the same as found in connection with the study of esophoria. They need only be mentioned here, as, under the head *Treatment,* it will be shown how they modify the management of the exophoria. They are: myopia and myopic astigmatism, hyperopia and hyperopic astigmatism, and plus and minus cyclophoria. Thus it appears that not only the relationship of every pair of muscles, and the condition of every individual muscle, must be known, but the refraction must also be understood, if one would deal successfully with exophoria.

The *subjective symptoms*—or, more correctly speaking, the reflex nervous symptoms—caused by exophoria are not due to the inherent tension of the externi and their synergists, but to the nervous tension of the interni and their synergists, necessary for maintaining binocular singular vision. A symptom of which exophorics very commonly complain is a blurring or running together of the letters of the printed page, after more or less prolonged reading. At such times the reader feels compelled to close the eyes tightly before resuming his reading. Another symptom, often present when near work is being done, is a heavy, sleepy feeling of the upper lids, also a stiff feeling of the upper lids, as if they were adherent to the globes. Prolonged near work congests the margins of the lids, even developing a marginal blepharitis, more commonly in exophoria than in any other form of heterophoria. A drawing sensation on the nasal side of the eyes is often complained of. There is no facial expression or pose of the head that is peculiar either to exophoria or to esophoria.

Treatment. Non-operative.—In pseudo-exophoria the cause should always be removed, if practicable, by non-operative means. The pseudo-exophoria caused by myopia and found only in the near, when it serves to neutralize a part of an inherent esophoria, should be allowed to continue until the esophoria has been cured by prisms in positions of rest, by exercise of the externi, or by operations. By the non-treatment of a pseudo-exophoria of this character is meant that

the myopic correction should not be worn in near work. For distant seeing the myopic correction should always be worn, for it neither adds to nor diminishes any form of heterophoria. If a myope is orthophoric for distance, the concave lenses should be worn for all purposes. With the lenses on for distant seeing there will still be orthophoria; with them on in near work the pseudo-exophoria is relieved and the patient becomes orthophoric in the near as well. If the myope is exophoric in the distance, the concave lenses should be worn for all purposes. The distant test will show the same exophoria with and without the lenses. In the near test without the lenses, the exophoria shown will be the intrinsic plus the pseudo; and with the lenses will be only the intrinsic, the pseudo-exophoria having been cured by the establishment of the normal relationship between the center of convergence and the center of ciliary action.

The pseudo-exophoria caused by over-development of the ciliary muscles, requiring less than a 1 D impulse to effect a 1 D contraction of these muscles, is best treated by the wearing of concave lenses, only in the near if the patient is an emmetrope, but both in the far and in the near if the patient is slightly hyperopic. By so doing a pseudo-esophoria is developed which lessens the exophoria. If the diagnosis is correct—that is, if the exophoria is wholly or in part pseudo—the wearing of concave lenses will be attended by a source of relief. When they cause discomfort, they should be discarded; for the exophoria is due to some other cause than hyper-development of the ciliary muscles.

J. J. Chisolm prescribed concave cylinders when his patients had hyperopic astigmatism. Although he did not so teach, nevertheless his patients that were benefited had exophoria. An esophoric patient would not have tolerated such lenses.

Patients who are hyperopic and have either pseudo or inherent exophoria should never be given the full correction of the hyperopia, for the imbalance would be made worse. If the hyperopia is less than 2 dioptres and the exophoria in the near is more than 4°, no correction should be given; if more than 2 dioptres, only the excess should be corrected. After an exophoria has been cured by exercise or by operation, a full correction of the hyperopia may be given, but in most cases 0.50 D should go uncorrected.

Those unfortunate subjects who have no converging power, probably because of absence of the third conjugate innervation center, cannot be relieved by either lenses, prisms, exercise, or operations.

Inherent exophoria.—The treatment of the two forms of inherent exophoria is the same, so far as concerns non-operative means. The

first of these is prisms in positions of rest (bases in) for the weak interni. The full correction of exophoria by prisms should not be attempted: probably only a half correction of the error should be given. Maddox suggests a correction of half or a third of the distant and a quarter of the near exophoria. When there is no complicating cyclophoria, the prismatic effect should be equally divided between the two eyes, and the axes of the prisms should be perfectly horizontal. The same rule holds good when there is a hyperphoria of one eye and a cataphoria of the other. If there is a complicating plus cyclophoria without any hyperphoria, the prismatic effect should be equally divided between the two eyes; but the axis of each should be tilted down at the temporal end, so as to make the externi tort the eyes in while turning them out to fuse the displaced images. The axes should be tilted in the opposite direction if the complication is a minus cyclophoria. When the complication is a plus cyclophoria with a right hyperphoria and a left cataphoria, the exophoric prism should be placed only before the hyperphoric eye and its axis should be tilted down at the temporal end. The muscular action necessary for overcoming the prism will turn the eye out and down and tort it in. If discomfort results, it will be due to the work that the inferior rectus has had to do to overcome the prismatic displacement. If any prism is placed before the left (cataphoric) eye, its axis should be perfectly horizontal, for, if tilted down at the temporal end, it would favor the cyclophoria, but increase the cataphoria; while, if tilted up, it would force a correction of the cataphoria, but would increase the plus cyclophoria. If there is doubt as to whether the axes of the exophoric prisms should be tilted, it is better to place them exactly horizontal. Weak exophoric prisms, with their axes perfectly horizontal, should bring some relief to most patients. When they do not relieve, it thus becomes evident that one externus, if not both, is attached too high, and there is developed a plus cyclophoria.

The objection raised against esophoric rest prisms, that they interfere with the law of direction, applies with equal force to prisms in positions of rest for exophoria.

Decentration of lenses, in for convex and out for concave, will accomplish the same results for exophoria as will prisms with bases in.

Exercise treatment.—There are two useful methods of exercising the weak interni in cases of exophoria. The simplest, if not the best, and certainly the cheapest, is the candle exercise. The candle is mentioned for the reason that the images of its blaze stimulate the two retinas so as to make it more certain that the center of convergence will be excited sufficiently to converge the visual axes, as the candle is brought

from arm's length to a point six or seven inches from the eyes. Images less bright, such as those of a pencil, in some cases would not sufficiently stimulate. If properly conducted and continued sufficiently long, it will do good in all cases except those in whom the interni have attachments too high on the globes. Interni thus attached, when exercised either with the candle or by means of prisms, will call into simultaneous action the inferior obliques, that they may prevent the convergence of the vertical axes of the eyes. In the greater number of cases this would either add to or develop a plus cyclophoria while curing the exophoria. The patient would not be benefited. But when the interni have the ideal attachments, or even when they are attached too low, the candle exercise, as well as prism exercise, will do good. In cases of ideal attachment only the interni are exercised; in cases with attachment too low every contraction of the interni is attended by a contraction of the superior obliques, so that development of the interni is attended by a corresponding development of the superior obliques—a thing to be desired in many cases.

The rapidity of a cure of exophoria by the candle exercise depends in part on the quantity of the exophoria and in part on the character of the blood supply of the interni; abundant blood supply means quicker results. Gentle rhythmic exercise will increase the size and power of a muscle, whether voluntary or involuntary. Permanent results follow such a method. No one can doubt that a muscle can be developed; there is reasonable doubt if a nerve center can be developed as a result of either mild or severe stimulation. A nerve cell is very different from a muscle fiber.

There are two methods of *exercising the interni by means of prisms.* The one is gentle rhythmic exercise by means of weak prisms with their bases out; the other method is that first suggested by Deady, and later advocated by Gould—loading the convergence by means of the strongest prisms possible. The former is intended for the strengthening of the muscles themselves, while the latter is designed to stimulate the convergence center to greater activity. The advocates of the latter method claim that exophoria, in most cases, is purely innervational and should be cured by forced stimulation of the convergence brain-center, the third conjugate innervation center. That this center is susceptible to excessive stimulation cannot be denied, but it is doubtful if this should be done. It is certainly more rational to develop the interni so as to make them respond normally to the impulse that the brain-center can easily generate in its real, though it may be subnormal, state of development. If it were possible to enlarge the ca-

pacity of a brain-center, as it is possible to increase the size and power of a muscle, the Deady method would not be objectionable.

In the rhythmic exercise of the interni by prisms, the design is to produce slight contractions by means of weak prisms (from 1° to 8°) with their bases out, to be followed by complete relaxation, each contraction and relaxation to last about three seconds, throughout a sitting of not more than ten minutes. The exercise should always stop short of fatigue, for exercise that tires does not build. To get practically complete relaxation, the object of fixation should be twenty feet distant. Persistent exercise, after this method, in low degrees of inherent exophoria, will produce permanent results.

In high degrees of intrinsic exophoria, non-operative measures will be productive of but little, and that little will be slow of accomplishment. Exophoria in the distance of 4° or more, and an exophoria in the near equal to the angle of convergence at that point, give little promise of yielding to non-operative means. An exophoria that gives diplopia in the distance under the red-glass test, is practically always a case for surgical treatment. All cases not showing good results, in a reasonable length of time, under non-operative measures, should be given the advantage offered by skilled surgery.

The object in view when exercising the interni in exophoria is to so develop them that they may respond normally to a normal nerve impulse—1° of contraction for every degree of impulse.

Operative treatment.—Before any operation for exophoria is done, the possibility of a cure by non-operative means should be eliminated, and the condition of every extrinsic ocular muscle should be known. Complicating muscle imbalances must be taken into account, and, if possible, should be corrected by the operations for the exophoria. In uncomplicated cases of exophoria, and in cases complicated only by hyperphoria of one eye and cataphoria of the other, the operations must either diminish the tension of the externi or increase the tension of the interni. When the exophoria is complicated by a cyclophoria, not only must the muscle tension be altered, but the muscle plane must also be changed.

In sthenic exophoria the externi should be first subjected to the operation of partial tenotomy, with the view of reducing their tension. The case being uncomplicated, the tenotomy should be central. The operative effect should be equally divided between the two externi, and should not be so extensive as to reduce abduction below 8° or abversion below 50°. In no case of exophoria should a complete tenotomy of an externus ever be done, for the reason that the risk of reducing both the duction and version power below the normal would

be too great. After the two partial tenotomies, any remaining exophoria that cannot be cured by non-operative measures should be still further relieved by a straightforward shortening of one or both interni, with the view of increasing tension without changing the plane of rotation.

When there is a complication of hyperphoria and cataphoria only, the operations, whether partial tenotomies or shortenings, should be done as if no complication existed. At some other time the vertical error must be given the proper treatment.

A sthenic exophoria that is complicated by a plus cyclophoria only should be treated with the view of lessening the tension of both externi and lowering their planes of action. This would be accomplished by cutting the upper and central fibers of each externus as nearly alike as possible, leaving the lower fibers intact. The three-fold effect of these two operations would be: (a) lessening or curing the exophoria; (b) correction, wholly or in part, of the plus cyclophoria; (c) the production of a double cataphoria.

A sthenic exophoria complicated by a plus cyclophoria and a right hyperphoria and left cataphoria should be subjected first to a partial marginal tenotomy of the externus of the hyperphoric eye. The operation of cutting the upper and central fibers of this externus would be attended by these three results: (a) lessening of the exophoria; (b) a partial or complete correction of the plus cyclophoria; (c) the production of a cataphoria equal to, or a little less than, the cataphoria in the other eye. If any remaining exophoria should still be complicated with plus cyclophoria and left cataphoria, the second operation should be a shortening of the left internus in such a way to both increase its tension and elevate its plane of action. This would have three results: (a) still further diminishing, if not curing, the exophoria; (b) a further correction of the plus cyclophoria; (c) an elevation of the cataphoric eye so as to bring it as nearly as possible in the same horizontal plane with the eye that was primarily hyperphoric. Should the first operation cure the complicating plus cyclophoria, even if the hyperphoria were not cured, the remaining exophoria should be relieved by a central partial tenotomy of the externus of the left eye, which would alter its tension without changing its plane of action.

Asthenic exophoria, uncomplicated, should be treated by straightforward shortening of both interni, the operative effect being as equally divided between them as possible. In this way their tension would be increased, but their planes of rotation would not be changed. The same operations should be done when the exophoria is complicated by

hyperphoria and cataphoria. Operations for a lateral error should attempt the simultaneous correction of a vertical error only when there is a complicating cyclophoria.

Asthenic exophoria, complicated by a plus cyclophoria only, should have both conditions relieved by shortenings of both interni in such a way as to increase their tension and elevate their planes. The triple effect would be: (a) correction of the exophoria; (b) cure of the plus cyclophoria; (c) the production of a double hyperphoria. When the complication is not only a plus cyclophoria, but a right hyperphoria and left cataphoria as well, the first operation should be a shortening of the left internus in such a way as to both increase its tension and elevate its plane. These would be the effects of this operation: (a) correction, wholly or in part, of the exophoria; (b) a partial or complete cure of the cyclophoria; (c) the production of a double hyperphoria. If the internus of the right eye must be operated upon, the shortening must be straight-forward, even if the two complications still existed; for an elevation of its plane would increase the hyperphoria while lessening the plus cyclophoria, and lowering its plane would increase the cyclophoria while diminishing the hyperphoria.

If a minus cyclophoria, which is rare, should alone complicate an exophoria, the marginal tenotomies of the externi would be below, and the shortenings of the interni would have to be done so as to depress their plane of rotation. If the minus cyclophoria with a hyperphoria and cataphoria should complicate an exophoria, a lower marginal tenotomy of an externus should be performed only on the externus of the cataphoric eye; while a shortening of an internus with depression of its plane should be done only on the internus of the hyperphoric eye, for reasons that are apparent.

The chief object in operating for exophoria, whether the operation be partial tenotomies of the externi for sthenic exophoria or shortenings of the interni for asthenic exophoria, is to so change the relative tension of the interni as to enable them to respond normally to a normal impulse from the third conjugate innervation center—1° degree of convergence for every degree of impulse—and thus establish harmony between the externi and the interni.

The change of the plane of action, though of vast importance, depends solely on the existence of a complicating cyclophoria.—(G. C. S.)

Wilkinson (*Ophthalmic Year-Book*, p. 106, 1910) believes that exophoria causes more nervous breakdowns than any other single lesion of the eye. He regards basilar headaches as a very constant symptom. His treatment consists of correction by decentered lenses or prisms, exercise of the internal rectus, and finally operation if the deviation

is above 5 degrees and the patient not relieved by the previous methods. Error of refraction if present is always to be corrected.

One of the best expositions of this subject is the paper by Landolt (*Ophthalmic Record,* p. 622, Dec., 1914) who, under the title *Insufficiency of convergence,* gives the diagnosis, measurement and treatment of exophoria and exotropia. He estimates the defect in terms of metre angles by means of his dynamometer, or ophthalmodynamometer, which is described and pictured in the article. He believes that we must first decide whether a patient's convergence is or is not sufficient for his needs by first estimating the number of metre angles corresponding to his usual working distance. Then we ask ourselves whether this amount is less than one-third of the working force required. If not he may work without extrinsic muscular strain. In other words, if we find with asthenopic symptoms, that one-third of the positive convergence is not below the number of metre angles required by the patient's usual working distance then it is highly probable the cause of the asthenopia is outside of the external muscle apparatus.

On the other hand, if the working distance, etc., call for more than one-third of the positive convergence power at the disposal of the patient this disparity will certainly, sooner or later, provoke symptoms of eye-strain. For example, a person forced to work at $\frac{1\text{m}}{3}$ has in all 6 m.a. of convergence, and requires for that purpose a working power of 3 m.a. and a reserve of 6 m.a., or 9 m.a. in all. He has, however, only 4 m.a. (two-thirds of six) in reserve and the balance 2 m.a. for work; hence is defective $3 - 2 = 1$ m.a.

The treatment of insufficient convergence consists either in furnishing the patient with the required convergence (i.e. with additional metre angles of convergence) or in altering his working distance. The latter requirement is met, theoretically at least, by the prescription of prisms with their apices directed towards the temple—abductor prisms, one may call them. But if prismatic glasses are correct in theory are they of practical value?

"If one desires to correct the refractive error of a myopic patient it is necessary to give him a glass corresponding to the amount of his ametropia; a minus 1 D. lens would be of no use to a myope with sixteen D. So is it with the correction of anomalies of convergence. If we decide to order prismatic glasses the lens correcting the ametropia should be combined with the prism but I would advise at first a weak prism—one not fully correcting the convergent error—and then increasing it until full strength is used. However it will, I believe, be

found (just as I showed the unreliability of decentering lenses for their prismatic effect in this same condition) that the use of prisms in this fashion either produces other symptoms (apparent incurvation, coloration of objects, etc.) that are almost as objectionable as the muscular asthenopia itself, or they fail to relieve the asthenopic complaints of the patient.

"It is generally the case that the convergence defect is more than one metre angle. In this instance there is little to be gained by resort to purely optical means for its relief; it is better to endeavor radically to increase the convergent power. Apart from rest, attention to the general condition and other hygienic measures—all of which are important and should ever be borne in mind in the conduct of all these cases—operative measures are the most effective.

"It may be difficult to explain, but tenotomy of an ocular tendon does increase the duction power of its antagonist; and, as we generally desire to decrease divergence and augment convergence, simple tenotomy of one or both external recti would, at first blush, seem to be indicated in insufficiency of convergence. Moreover, as it is a simple procedure, and one more easily carried out than advancement, it appeals to many surgeons. However, my experience shows that, in addition to the danger of producing diplopia and other disagreeable consequences of a complete section of one or both abductor tendons, the muscular asthenopia (for which the operation is done) is not always relieved. This untoward result follows, to my mind, from interference with an important function of the externi—facultative or latent divergence. From these and other reasons I long ago abandoned tenotomy of the externi as a remedy for insufficient convergence in favor of advancement of one or both interni. The latter method is a logical procedure and one that infallibly augments convergence without interfering with the almost equally important relative divergence power. In other words it restores or brings about the normal relations of convergence and divergence.

"I have demonstrated that a simple advancement of one internal rectus, without tenotomy of an antagonist, may increase the convergence power from 3 m.a. to 20 m.a Thus, a single operation, performed on one eye, is able to change an insufficiency into an excess of convergence.

"Strangest result of all (and very important) is that this apparently excessive addition of convergent power does not interfere with the important relative divergence. It is comparable with the well-known fact that in advancement of an internus for divergent squint,

while it markedly increases convergence, does not limit the temporal excursions of the eyeball.

"As to the degree and manner of advancement, when three or six (or more, because one need not be particular in this regard) m.a. of additional convergent power are required I always advance the tendon of one internus to the corneal margin. For the reason I have just alluded to an apparent excess of operative convergence is not vital in these cases. Moreover, the extrinsic ocular muscles are not rigid bands of tissue to be mathematically measured by a millimetre rule; and one cannot surgically place them here or there as if they were pieces of metal. It must not be forgotten, either, that there are other considerations (tonus, innervation, etc.) besides length and position of an advanced tendon to be considered."

In any event we have the principal clinical fact, viz., that even an excessive result is almost invariably satisfactory, is not followed by additional symptoms and relieves the oculomotor asthenopia just as completely as if by operation a normal balance were secured. When by means of an advancement the patient secures twenty or even more metre angles of convergence he will use of the total amount only the portion required for comfortable near work.

One now and then meets with cases that after operation exhibit a normal or satisfactory convergence but whose muscles assume, after a time, a condition very like that which obtained before the advancement. These are invariably neuropaths—persons with defective motor innervation. In such patients, while a second advancement—of the internus tendon of the opposite eye—is indicated, treatment, directed to the general nervous condition, should be instituted in conjunction with the surgical intervention. Fortunately, such instances are very rare and the surgeon will find that advancement of a single internus tendon will suffice to cure practically all cases of muscular asthenopia dependent upon insufficient convergence.

Family exophoria.—Because of the relationship between the shape of the head and the orbital development and of the fact that the latter contributes to faulty extrinsic ocular muscle action, Wendell Reber (*Practical Medicine Series*, p. 142, 1910) undertook the measurement of a number of heads. A series of heads was measured at random, while another series was made up from families known to have so-called family headaches. There were 40 cases in the second series. The heads of the men were measured by a hatter's conformer, and the heads of the women with calipers. These forty people formed the majority of seven families. One was orthophoric, five esophoric and thirty-four were exophoric. Of the thirty-four exophorics, twenty-one sub-

mitted to head measurements. Of this number eighteen were long skulled (dolicocephalic), and three were medium skulled (mesocephalic). The writer believes that if this relation were obtained in a large series of cases it would indicate that dolicocephalus predisposes to exophoria. See, also, **Muscles, Ocular**; as well as **Adductive power, Weakness of.**

Exophoria, Intrinsic. See **Exophoria.**

Exophoria, Pseudo-. See **Exophoria.**

Exophthalmia. Abnormal prominence of the eyeball.

Exophthalmia cachectica. Exophthalmic goitre.

Exophthalmia fungosa. (L.) A term formerly employed to describe a late stage of glioma retinæ, after the malignant growth has filled the eyeball and caused a perforation of the cornea or anterior portion of the sclera. The tumor-growth then protudes, proliferates rapidly, and gives a "fungous" appearance to the front of the eyeball.

Exophthalmic goitre. FLAJANI'S DISEASE. BASEDOW'S DISEASE. GRAVES' DISEASE. PARRY'S DISEASE. HYPERTHYROIDISM. This important subject has, to some extent, been already discussed under the caption **Basedow's disease** in this *Encyclopedia* (Vol. II, page 901), and it is suggested to the reader that he first consult the former section, as well as the rubric **Exophthalmos,** before perusing the matter under this heading.

The three cardinal and characteristic symptoms of this disease are tachycardia, enlargement of the thyroid gland, and exophthalmos. The secondary symptoms are tremor, excessive sweating, nervousness, mental depression, apprehension, emaciation, pain and weakness in the extremities, brittleness of the nails, loss of hair (including eyelashes and eyebrows), increased lachrymation, conjunctivitis, diminished power of convergence, and other less common symptoms. Tremor is very constant, although at times coming on only late in the disease, and has been classed by some writers as a cardinal symptom (Butler).

Of the three cardinal symptoms, tachycardia is almost constant, and is the first to appear. One or both of the other symptoms may be absent for a long time. According to Gowers, exophthalmos is absent in about one-tenth of the cases and the goitre in about one-twelfth. The heart's action always reaches 100 per minute, and has been frequently noted at 200.

The goitre may be unilateral or bilateral; but if bilateral it is generally more marked on one side than on the other, and commences on that side. The exophthalmos may likewise be unilateral or bilateral, but is generally bilateral. It usually corresponds in size to that of the goitre, but several cases have been reported in which the goitre was on one side and the exophthalmos on the opposite side. All degrees

of exophthalmos are found, and very rarely actual dislocation of the eyeball has occurred. Many patients complain of an intolerable sensation of heat, which may lead them to cast aside their clothing and enables them to withstand low degrees of external temperature. The disease is one of early adult life, and principally affects females. Higgins places the percentage of cases occurring in women at 95 or 97 per cent. This is probably too high. Butler states the ratio to be 3 to 1. The same author calls attention to a family tendency.

The special eye symptoms of exophthalmic goitre are important and interesting. Three phenomena affecting the lids are classic, and should be carefully sought for, although they are not always to be found.

Von Graefe's sign consists of a want of a proper co-ordination between the upper lid and the eyeball, when the latter is rotated downward. Normally, in this action of the eyeball the upper lid follows proportionately, the amount of cornea covered by the lid remaining the same. In Graves's disease the lid does not so follow; the cornea passes from under the lid, and a line of sclerotic becomes visible above. Lewin has observed this phenomenon in 55.5 per cent. of the cases of Graves's disease, Hill Griffith in 13.2, Pässler in 17.6, and West in 14 per cent. of the cases. Fitzgerald has noted 4 cases of Graves's disease with one-sided exophthalmos, and von Graefe's sign corresponding to that side. Hack has seen 1 case of unilateral exophthalmos with von Graefe's sign in which the latter disappeared with the former.

Wilbrand and Saenger have collected 39 cases of Graves's disease classified as follows: Exophthalmos in 37 cases—double in 33 and one-sided in 4. Of the cases of bilateral exophthalmos, von Graefe's sign and Stellwag's sign were found in 5. Von Graefe's sign was positive and Stellwag's sign was questionable in 14, and both "signs" were questionable in 4. In all 4 cases of unilateral exophthalmos both "signs" were found affecting the proptosed eye. In 6 cases exophthalmos and both "signs" were not to be found. Von Graefe's sign and Stellwag's sign without exophthalmos were found in 1 case, and in 2 cases Stellwag's sign alone was found. Sharkey, in 613 cases, found von Graefe's sign in 601.

Several theories have been advanced for the explanation of this lid phenomenon. Von Graefe believed it to be due to stimulation of the sympathetic nerves whereby the fibres of Müller's palpebral muscle were contracted, thus holding the lid back. Dilation of the pupils, which should follow stimulation of the cervical sympathetic, is not, however, an accompanying symptom.

Sattler's explanation is a disturbance of the reflex and co-ordination centres (association centres). Against this theory has been urged

an insufficient knowledge of these centres to warrant its acceptance. Also that long-continued disturbance of these centres should produce lasting results, which is not the case. Contraction of the levator palpebræ muscle brought on by increased blood-supply is the theory of Ferri; and an insufficiency of the orbicularis is that of Sharkey.

Möbius and Bruns hold that in Graves's disease there is an increased activity or power of the eye-musculature—an hypertonus of the levator muscle. Möbius believes that the primary phenomenon is Stellwag's sign, and that this is followed by von Graefe's symptom.

Last must be mentioned the mechanical theory of Wilbrand and Saenger, which seeks to explain the phenomenon by a retrograde or reversed action of those muscle-fibres connecting the levator palpebræ and the superior rectus muscles, which also have connection with the fornix of the conjunctiva. Normally, when the eyeball is rotated downward, traction made upon the fornix is transmitted through the above-mentioned fibres to the superior rectus and levator muscles, and the lid is able to follow the eyeball. Under certain circumstances, notably those found in certain cases of exophthalmic goitre, this relationship is disturbed, and the upper lid is mechanically not in condition to follow the eyeball.

Stellwag's sign consists of diminished frequency of, and imperfect, winking. A rapid succession of imperfect winks may be followed by a long pause without winking. The winking is imperfect in that the lids do not meet. The insufficiency is in part due to lessened reflex irritability of the cornea and retina. Sattler considers the lesion one of the reflex centres governing the retina, the cornea, and the conjunctiva. Swanzy thinks the imperfect winking is probably due to insufficiency of the orbicularis rather than to overaction of the levator.

Infrequent nictitation may be found in hystero-epilepsy. It was also noted by Savage in a twenty-five-year-old woman who was otherwise healthy. He could examine the fundus with the ophthalmoscope for half an hour without the patient winking.

On account of the imperfect closing of the lids, the lower portion of the cornea may suffer ulceration or pannus formation.

Dalrymple's sign.—This is a retraction of the upper lid, with consequent widening of the palpebral fissure. It gives to the patient the characteristic stare and look of apprehension. Other conditions producing a similar widening of the palpebral fissure are orbital tumor (mechanically), stimulation of the cervical sympathetic, cocain (probably by action on the sympathetic), hysteria (occurring in women after childbirth), tetanus (spasm of the occipito-frontalis muscle), and complete amaurosis.

Joffroy has noticed that, when the patient with Graves's disease holds the head down and attempts to look up without raising the head, the forehead remains smooth. Normally under such circumstances it should wrinkle. Möbius noted a deficiency in, or it may be a complete loss of, convergence power.

Harold Gifford in 1906 called attention to great difficulty in everting the upper lid, due to retraction and rigidity. This he had observed as an early but not constant phenomenon. Periodic edema of the eyelids has been noted in a number of cases, and in one case three years before the disease declared itself (Wilbrand and Saenger). Discoloration of the skin, similar to that found in Addison's disease, has been noticed in a few cases (Story).

Falling of the eyelashes and eyebrows occasionally occurs in the beginning or in the course of the disease. Sattler attributes it to trophic disturbance.

Conjunctivitis and lachrymation are common in cases with marked exophthalmos. The conjunctivitis is probably due to diminished sensibility of the conjunctiva and imperfect nictitation. The lachrymation and epiphora are thought by Berger to be due to stimulation of the sympathetic nerve, causing increased secretion from the lachrymal gland. Schmidt-Rimpler, on the other hand, considers these symptoms to be the result of mechanical irritation of the conjunctiva, which, on account of the proptosis and widened palpebral fissure, is more exposed than is normally the case. Another element in the causation is displacement of the puncta lacrimalia. The cornea suffers keratitis e lagophthalmo; opacities may appear on the lower portion, followed possibly by ulceration, or the unprotected portion of the cornea may become covered with pannus. One or both eyes may be destroyed. Mooren and Spalding have recorded cases in which enucleation was necessary on account of purulent choroiditis.

The exophthalmos is probably due to increase of the retrobulbar orbital contents. That there is a temporary increase in the amount of orbital fat has been clearly demonstrated; also there is an increased amount of blood in the orbital vessels.

In accordance with the theory of sympathetic irritation, contraction of Müller's orbital muscle, which covers the spheno-maxillary fissure, as well as contraction of other smooth muscle-fibres in the orbit, has been advanced as a causative factor of the exophthalmos. After death the exophthalmos in part disappears, which, of course, favors the theory of muscular spasm and increased blood-supply. Knies states that dilated pupils as well as unequal pupils, with retained reflex activity, are frequently found. This he attributes to sympathetic irritation.

Contrary to what might be expected, fundus changes in exophthalmic goitre are generally wanting, or, if present, are neither pronounced nor characteristic. In some cases the arteries are enlarged from vasomotor paralysis. They may equal the veins in calibre. Spontaneous arterial pulsation was found by Becker six times in seven cases. The veins may be tortuous. Very rarely optic neuritis and optic-nerve atrophy are found.

It should be remembered that exophthalmic goitre occurs often coincidently with other diseases of the nervous system, or constitutional diseases, such as hysteria, multiple sclerosis, bulbar paralysis, diabetes mellitus, or diabetes insipidus. Care must therefore be observed not to attribute to exophthalmic goitre changes which might be due to other diseases.

The *pathology* of exophthalmic goitre is as yet not known with certainty. For a full discussion of the various views on this subject works on nervous diseases and internal medicine must be consulted. Suffice it here to say that there are two chief theories, each of which is warmly supported by many competent observers. The one holds the disease to be primarily of the cervical sympathetic. Gordon says that the theory based on the influence of the sympathetic nerves covers all cases without exception. The other theory is based on an increased thyroid secretion (hyperthyroidization) as well as a perversion of the secretion. This is held to be the primary cause, the other changes being produced secondarily. The latter theory is probably correct.

In cases of pure Graves's disease *prognosis* may be said to be good. As mentioned above, however, there is a great tendency for Graves's disease to occur coincidently with other diseases in which the prognosis is not so favorable. Occurring in highly nervous and debilitated individuals, the prognosis is not so favorable as when occurring in individuals who have previously enjoyed robust health, and are not members of that large class of neurotics. Williams, of Manchester, in a study of 24 cases found 6 to be fatal, complete recovery in 7, improvement in 7, the condition unchanged in 3, and 1 case in which the patient was following his occupation, but the exact condition was unknown. The cases not dead or recovered were observed for a period of five years.

Treatment.—Another portion of this and other sections should be consulted for the general treatment of exophthalmic goitre. At the present time surgical measures for the relief of this affection are being actively discussed and tried. Such are simple exposure of the thyroid gland (exothyropexy), resection of the cervical sympathetic ganglia, ligation of three of the thyroid arteries, and partial extirpation of the gland. The ocular complications must be met as they arise. If the

protrusion of the eyeball is sufficient to threaten the cornea from exposure, the palpebral fissure may be reduced in length by tarsorrhaphy. If more radical measures are necessary, the edges of the lids may be denuded and the two united by stitches in their entire extent, thus obliterating the palpebral fissure. The fissure may at the proper time be re-formed. Protection of the cornea is the important point to be kept constantly in mind.—(J. M. B.)

In addition to the usual signs and symptoms of the disease Rosenbach's sign must not be forgotten. It consists of the trembling of the upper lid when the eyes are gently closed. It disappears when the eyes are opened and does not occur when the patient is actually asleep. Like many other signs in exophthalmic goitre it is sometimes absent and may appear in healthy subjects.

Jackson and Mead (*Practical Medicine Series,* 1909) have found that next to the thyroid, heart and circulation, the eyes are of chief interest in exophthalmic goitre, and in a series of 85 cases the eyes were negative or unnoted in 8. In 20 cases the four cardinal signs, exophthalmos, von Graefe's lid sign, Stellwag's and Moebius' weak convergence were all present. Exophthalmos, von Graefe's and Moebius' in 8. Exophthalmos and von Graefe's in 8. Exophthalmos and Stellwag's in 10. Exophthalmos and Moebius' in 4. Exophthalmos alone in 20. Reflex winking was sometimes lessened, as was also the wrinkling of the forehead in looking up, but neither of these seem important symptoms.

Kocher (*Correspondenzbl. f. Schweizer Aerzte,* No. 7, 1910) adds to the previously recognized ocular signs of early Graves' disease the following: If the patient be caused to fix a stationary object, retraction of the upper lid may be observed. If an object be fixed which moves briskly up and down, a convulsive momentary retraction of the upper lid may occur. Jocqs (*Ophthalmoscope* VIII, p. 743, 1910) refers to a case in which an early diagnosis of Basedow's disease was made on the basis of a unilateral exophthalmos.

In the case reported by Polack (*Practical Medicine Series,* p. 53, 1910) a woman forty-two years of age, had, without other ocular disturbance, the left upper lid retracted so much as to enlarge notably the palpebral fissure. The condition had existed for two months. Both the Stellwag and Graefe signs were present, the patient had been rapidly growing thin for several months, and the pulse was frequent. The author thinks it probable that the levator spasm was a symptom of the early stage of exophthalmic goitre.

There are also a number of other symptoms, arising from anomalies of nutrition, of the intestinal tract, the skin, the urogenital apparatus,

the nervous system, etc. Landstrom (*Ophthalmology,* April, 1909) draws attention to a rigid expression of the eyes (not to be confounded with Stellwag's sign) which is often the first sign of the disease, as well as to a considerable reduction in number of the neutrophile, polynuclear white corpuscles—a point of great importance in the diagnosis and the prognosis.

As to the nature of the disease, Landstrom considers the thyroid theory, advanced by Möbius and Kocher, as generally acknowledged nowadays. One must remember, that the histologic changes of Graves' disease are specific, and that they may be diffuse or circumscribed; a small enlargement of the thyroid may give highly pronounced symptoms; a great enlargement to quite slight ones, especially when a colloid degeneration prevails over the specific changes.

As to the etiology Landstrom points out the frequency of infectious diseases, especially rheumatic fever, angina, etc. He has seen several cases following angina whose course was a very acute one so that they were mistaken for acute endocarditis.

As to the pathogeny of the exophthalmos Landstrom repudiates former theories. The protrusion is due to contraction of a muscle, newly discovered by the author. This muscle, according to him, consists of unstriped fibers, cylindrically arranged, passing from the orbital septum to the ring of connective tissue at the ocular equator, the medial fibres of which are the strongest. Claude Bernard's classic experiment, the production of exophthalmos and widening of the lid aperture by irritation of the sympathetic nerve, shows that the muscle in question must be innervated from the sympathetic itself.

L. B. Wilson (*American Journal of the Medical Sciences,* December, 1913) has made a detailed pathologic study of fixed tissue preparations from 1208 thyroids, removed from patients whose condition would ordinarily have been diagnosed as exophthalmic goiter, showing that 79 per cent. of the thyroids contained large areas of marked hypertrophy and hyperplasia. A parallel clinical study showed that for a period of three years all patients with true exophthalmic goiter, and from whom gland tissue was removed, fall into this list.

In the series of 1208 so-called exophthalmic goiters, plus 585 so-called simple goiters, or a total of 1793 thyroids, but four instances of marked primary hypertrophy and hyperplasia of the parenchyma were noted which did not show clinical symptoms of true exophthalmic goiter. Three of the four patients were children.

Twenty-one per cent. of the 1208 glands studied were either regenerations or adenomas. Clinically, while all of these were markedly

toxic, all were chronic and none of them would now be grouped clinically as true exophthalmic goiter.

By assuming that the symptoms of true exophthalmic goitre are the results of an excretion from the thyroid, and by attempting to determine the amount of such secretion from the pathologic data, one is able to estimate in a large series of cases the clinical stage of the disease with about 80 per cent. of accuracy and the clinical severity of the disease with about 75 per cent. of accuracy. It would, therefore, appear that the relation of primary hypertrophy and hyperplasia of the parenchyma of the thyroid to true exophthalmic goiter is as direct and constant as primary inflammation of the kidney is to the symptoms of true Bright's disease.

J. M. Blackford and A. H. Sanford (*Medical Record,* August 30, 1913) found that from a study of the effects of intravenous injection of extracts of human exophthalmic goiters on the blood-pressure in the dog, using only fresh glands having a parenchymatous hypertrophy and hyperplasia of cuboidal to columnar epithelium, and with little or no stainable colloid material (low iodine content), the authors conclude that a powerful depressor substance exists in these goiters. A primary injection establishes tolerance to the action of further injections. Atropine does not inhibit the action of the substance. This substance does not behave physiologically like choline. Its action takes place chiefly through peripheral vascular dilatation aided by some diminution in cardiac output. Irritability of the vagus is not decreased. The existence of a crossed tolerance between the depressor action of extracts of exophthalmic goiters and of blood-serum from patients with exophthalmic goiter suggests that the substances active in these two products are the same.

P. Sainton and P. Gastaud (Translation from the *Bulletin médical* in the *Monthly Cyclopedia,* Oct., 1914) have met with 3 instances of diabetes among 90 cases of exophthalmic goiter, and after an extensive search in literature have found altogether 60 cases presenting this combination of conditions. They estimate the frequency of diabetes in exophthalmic goiter as 3 in 100 cases. It is undoubtedly a fact that diabetes occurs much oftener in cases of hyperthyroidism than among patients with hypothyroidism, in which it is quite rare, as Parisot has shown.

Clinically, diabetes occurring in the course of Graves's disease is manifested in two ways, viz.: (1) as a temporary or slight glycosuria, with the usual symptoms of diabetes only present in a trifling degree; (2) as a well-established condition, with all the characteristic symptoms present, the latter frequently even dominating the clinical pic-

ture as a whole. In the first group of cases slight thirst or a slight increase in appetite, or a feeling of weakness is at times responsible for the examination of the urine which leads to the discovery of the glycosuria. The amount of sugar excreted may be small, e.g., 3.4 to 5 gm. in one of the author's cases, with a total daily urinary output of 1500 c.c. In the second class of cases, on the other hand, the diabetic disorder is unusually severe, 8 to 14 liters being sometimes excreted daily, and the amount of sugar eliminated ranging from 340 to 1000 gm. a day, or even attaining higher figures, such as are hardly met with in any cases other than those of pituitary diabetes. Polyphagia, polydipsia, and other symptoms are pronounced. It seems to be a uniform rule that in severe cases of Basedow's disease severe diabetes exists, while in mild Basedow cases slight and evanescent glycosuria occurs. In most cases diabetes appears as an epiphenomenon in the course of exophthalmic goiter, and a long time after its onset. Where both conditions have become established, a state of equilibrium seems to occur between them, viz.: when the Basedow condition becomes worse the diabetes improves, and vice versâ. The prognosis varies in different cases. Mild diabetes in Basedow cases runs a course quite like that of arthritic diabetes, presenting the same intermissions and low degree of intensity. In severe forms, on the other hand, the combination of the two diseases constitutes a condition of exceptional gravity. In the series of cases collected by Sattler, 25 patients rapidly succumbed—7 of them in coma. Sometimes, as in one of the author's own observations, pulmonary tuberculosis is superadded, further aggravating the prognosis and hastening death.

The combination of diabetes and exophthalmic goiter may be complicated by other syndromes, as in the cases reported by Lancereaux, Henrot, and Murray, in which acromegaly was added to form a triad of conditions. In a case of Rennie the third component of the triad was myasthenia gravis. In one of the author's own cases myopathic and osseous disorders, the latter of the type of Paget's disease, rendered the interpretation of the symptoms singularly difficult. In diabetic Basedow cases of the female sex signs of ovarian insufficiency are at times noted; in one patient the menstrual period was clearly instrumental in causing glycosuria either to reappear or to become more marked.

What is the mechanism of this diabeto-Basedow syndrome? Pathology as yet yields only incomplete testimony in this connection. A systematic study of the ductless glands in such a case has never been conducted. The lesions mentioned as having been found have been as follows: (1) In several cases the liver showed slight fatty changes;

(2) the condition of the pancreas varies; in Murray's case it showed marked sclerosis and disappearance of the islets of Langerhans, while in those of Sougnes and Marinesco and of Lépine it appeared normal. In the observations of Henrot and Murray, where acromegaly was superadded, the pituitary was enlarged; in the others its condition was not noted.

Of other glandular theories is the adrenal theory. Cases in point are uncommon, and the authors know of but one instance in which a patient afflicted with both exophthalmic goiter and Addison's disease showed temporary glycosuria (personal case). Discussion of the possibility of participation of the adrenals in such a glycosuria is rendered necessary by the fact that many adherents of the Vienna school maintain the thyroidoadrenal origin of exophthalmic goitre. This theory is based on the relations supposed to exist between the thyroid, pancreas, and chromaffin system. In hyperthyroidism there would occur inhibition of the pancreas and stimulation of the adrenal function. The theory offers a plausible explanation of the clinical association in question, it being merely necessary to conceive that, by reason of the pancreatic and thyroidoadrenal antagonism, the disturbance of pancreatic function might extend to complete suppression of glycogenesis. This theory is widely discussed. It has not been proved, indeed, that an increase of adrenal secretion takes place in Basedow's disease; epinephrin is not constantly present in such cases; finally, the association of hyperthyroidism with Addison's disease is hardly in favor of this conception. Basedow cases, moreover, do not show any constant change in the blood-pressure. True, Asher has noticed that in certain subjects with thyrotoxicosis the injection of ¼ to ½ mg. of epinephrin leads to glycosuria. Further investigation is required, however, to confirm the validity of this test. Thus, on the whole, it is difficult to establish the responsibility of the adrenals in the production of diabetes among Basedow cases.

Such is not the case, however, when one looks up a possible rôle of the pituitary in this direction. The reported cases of coincident exophthalmic goiter, acromegaly, and diabetes afford firm support for this theory. Even clinically, there is a marked resemblance between the severe Basedowian diabetes cases and cases of pituitary diabetes. Pituitary diabetes may show itself in the absence of acromegaly. All authors are agreed that it is due to hyperpituitarism. Claude and Baudoin, in a series of researches, found that in a certain proportion of subjects,—arthritic and obese cases,—after mealtime alone, glycosuria appeared after the injection of pituitary extract. Comparison of these cases with those of glycosuria following thyroid treatment in obesity

is of interest in this connection. Clinically and experimentally, there is thus a considerable analogy between Basedowian diabetes and glycosuria, on the one hand, and pituitary diabetes and glycosuria, on the other.

From the above it seems justifiable to assume that in diabetes coupled with exophthalmic goitre two internally secreting glands may be tentatively held responsible, viz., the thyroid and the pituitary. Can one conceive that these two influences are simultaneously operative in the production of Basedowian diabetes? Such a combination seems not unlikely, in view of the close functional synergism existing between the two organs named. As for the more precise mechanism of the glycolytic process taking place, the question arises whether the hypophysis and thyroid cause, through insufficiency in their functions, some disturbance in virtue of which the sugar is no longer retained in the liver. If they act through the pancreas, is this action exerted through the intermediation of the sympathetic system or through a hormone? These are further problems in general pathologic physiology which the association of diabetes with exophthalmic goitre brings up for future solution.

Of 2,917 cases of exophthalmic goitre coming to operation between Jan. 1, 1909, and Jan. 1, 1913, and analyzed by Plummer (Abstract in *Journ. Am. Med. Assocn.*, Dec. 20, 1913) 42.8 per cent. were hyperplastic and 57.2 per cent. were non-hyperplastic. Of the hyperplastic 99.2 per cent. were toxic and 0.8 per cent. were atoxic. Of the non-hyperplastic 23.3 per cent. were toxic and 76.7 per cent. were atoxic. Patients coming under observation with non-hyperplastic toxic goitre gave a history of having first noted the goitre at the average age of 22 years, and the evidence of intoxication at the average age of 36.5 years. The corresponding ages for hyperplastic goitre were respectively 32 and 32.9 years.

Throughout the series the number of cases in which the clinician failed definitely to note and attribute constitutional symptoms to the thyroid and which were later diagnosed by the pathologists hyperplastic thyroid, varied from two cases in 1909 to four cases in 1912. The pathologic reports failed to show the presence of hyperplasia in the cases in which exophthalmos was noted by the clinician six times in 1909, four times in 1910, twice in 1911, and not in a single instance in 1912. As to whether the symptom-complex accompanying hyperplastic goitre is to be directly attributed to disturbed thyroid function, Plummer says that while he has so considered it in his paper only as a matter of convenience for pointing out the association of the clinical and pathologic findings, he calls attention to a point in support

of this theory that, so far as he knows, has not hitherto been made, namely, that an individual, aged 22 years, with an adenoma of the thyroid, has a definite chance of developing a train of symptoms during the thirty-sixth year so similar to the symptom-complex associated with hyperplastic thyroid, that the best-trained diagnosticians are constantly confusing the two conditions. He does not believe that the symptom-complex of non-hyperplastic toxic goitre can be associated with any definite pathologic change in the thyroid.

The order of onset of the most important symptoms of exophthalmic goitre based on the average of the Mayo series was as follows: (1) cerebral stimulation; (2) vasomotor disturbances of the skin; (3) tremor; (4) mental irritability; (5) tachycardia; (6) loss of strength; (7) cardiac insufficiency; (8) exophthalmos; (9) diarrhea; (10) vomiting; (11) mental depression; (12) jaundice, and (13) death.

Widal and Abrani (*Rec. d'opht.*, p. 367, August, 1908) report a case of simple goitre in which there was in one eye evidence of excitation of the cervical sympathetic, enophthalmos, enlargement of the palpebral aperture, and marked mydriasis. Cantonnet (*Soc. d'opht. de Paris,* January 14, 1908) reports a case in which the ocular symptoms were the only clinical evidence of aortic aneurism. There was mydriasis of the left eye, the palpebral fissure was narrowed, and increased sweating occurred on the left side of the face.

Owing to drying of the corneal surface (through infrequent winking and widening results of the palpebral fissure) the epithelium is easily removed; infection follows and with sloughing sufficient to destroy the eye. Sometimes, in these cases, vessels develop in the lower part of the cornea. Slight anesthesia of the cornea is often present. In severe types of exophthalmic goitre, long-continued exposure of the cornea may bring about a condition of pannus.

Non-operative treatment.—S. Solis Cohen (*Am. Journ. Med. Sciences,* July, 1912) says of this subject, "I have had the opportunity to observe a number of patients for periods varying from a few months to twenty-five years after apparent recovery under non-surgical treatment. In but one instance has there been relapse, and in no case had death occurred from any condition with which Graves' disorder could be causatively associated.

"What then constitutes 'proper' medical treatment? Rest is the most important factor. The therapeutic utilization of various preparations of animal tissues, and especially of the ductless glands, finds a peculiarly appropriate field in Graves' disorder.

"On the whole, thymus gland is the most useful of the ductless gland preparations in the largest number of cases. It must be given in

sufficient quantity—from 0.5 to 3 grammes (8 to 45 grains)—daily for months together.

"I still, however, find, as reported to the American Medical Association fifteen years ago, the conjoint or alternate use of adrenal and thymus preparations even better.

"More recently I have been making observations with pituitary preparations. One of the earlier patients to receive pituitrin injections was a woman at the Philadelphia General Hospital, who had been in the house for more than two years before she was brought to my personal attention. This case was one of moderate severity, with periods of extreme tachycardia, and the exophthalmos was of such a degree that about one-fourth of the eyeball was left uncovered when the attempt was made to close the lids. Intramuscular injections of pituitrin at first in small (circa 5 minims) and afterward in rather large doses (20 to 30 minims) were given, at first once and afterward twice daily. Improvement, both subjective and objective, was marked and rapid. The heart had become quiet, the goitre was scarcely more than visible, and the eyelids closed almost completely. Such rapid improvement is not the rule. The effect is gradual, but progressive, and the pituitrin needs to be supplemented by thymus or other appropriate adjuvant."

OPERATIVE MEASURES

A. J. Ochsner (*Jour. Oph. and Oto-Laryng.*, February, 1912) discusses a number of practical points on this subject under the following heads:

1. Surgical treatment should be employed in every case which does not recover permanently upon treatment with rest, hygiene, diet and the use of a few harmless remedies, and possibly also the treatment with serum, provided, first, that the patient is not suffering from temporary exacerbation of the hyperthyroidism, and, second, that the condition has not existed sufficiently long to leave the circulation and the nervous system of the patient in an absolutely hopeless condition.

2. It may be that one entire lobe and a part of the other must be removed in order to cure a patient, but the latter's condition may make it wise to remove only one lobe or possibly to ligate one or two vessels, and later to add the remaining treatment, as the patient's condition may indicate.

3. There is practically always a sufficient amount of serum secreted to indicate the use of good drainage.

4. It is extremely important to guard against violence in connection with the operative manipulations.

5. One-fourth of a grain of morphine and one one-hundredth of a

grain of atropine is administered hypodermically half an hour before the operation is begun, and the patient is then thoroughly anesthetized with ether by the drop method, and the head of the table is elevated so that the body lies at an angle of 45°. The operation can be completed without the further administration of ether. This makes the use of ether perfectly safe, and the patient's pulse regularly improves during the operation. The jaw must, however, be held forward by a reliable assistant during the entire operation in order not to permit the tongue to obstruct respiration by falling into the larynx.

6. The necessity of avoiding injury to the recurrent laryngeal nerve, to the parathyroid glands and the trachea is fully established.

7. Hot water should be taken by the mouth, or normal salt solution given as an enema by the continuous drop method.

8. Give patients definite instructions to avoid overwork, excitement, alcohol, tobacco, tea and coffee, late hours, social and business worries, absolutely and permanently, after recovering from the operation, and to select a diet largely composed of milk, cooked vegetables and fruit.

9. The tremor, the muscular weakness, the nervous excitability, some tachycardia and many of the minor symptoms are often present in young people. There may even be present a very slight degree of exophthalmus, and still these patients will almost invariably recover without operation with physical, mental and emotional rest, a diet composed largely of milk, cooked vegetables and fruit, favorable hygienic surroundings and absence of conditions which might cause nervous excitement.

As indicated under the heading **Basedow's disease** the indications for and the steps in the various operations for the relief and cure of exophthalmic goiter will be given here.

Much of the text and some of the illustrations have been taken—after revision by the writer—from Wood's *System of Ophthalmic Operations.*

The following observations are made for the purpose of giving the history of and developing the arguments for operative interference in this disease based on its pathology:

As first shown by Möbius, the essential cause of the disease known as exophthalmic goitre is a hypersecretion of the thyroid gland. The many symptoms presented are undoubtedly due to a toxemia. This condition is not generally termed hyperthyroidism. It is not unlikely, therefore, that definite and constant pathological changes are to be found in the thyroid gland. In nearly all the type of goitre corresponds to a hypertrophy of gland tissue, either circumscribed or diffuse. The gland may not be greatly enlarged. Microscopically, the alveoli

are not found increased in size, but there is present a hyperplasia of the epithelial lining, either as one layer or in reduplication of layers of epithelial cells. There may also be found an infolding of the alveolar wall with the formation of papillæ in the alveoli. In some cases in place of a hypertrophy an actual hyperplasia of gland tissue, with a numerical increase of the follicles, exists. This increase in the number of follicles is associated with hyperplasia of the lining epithelium of the alveoli. Degenerative changes with desquamation of alveolar epithelium are to be seen in more chronic cases. Degeneration of active functionating cells may with blocking of the lymphatics bring about a cessation of the symptoms due to hypersecretion of the gland. In this way a spontaneous cure takes place, providing the patient lives long enough.

Most observers are agreed upon the following gross characteristics of the thyroid gland in true exophthalmic goitre:

1. Generally diffuse enlargement of the gland, with a firm elastic consistency, the firm consistency being due to the lumen of the follicles being relatively free from colloid and filled with epithelial cells.

2. Expansile pulsation due to increased vascularity often approaching the type recognized as the struma vasculosa. This is due to an increase in the size and number of the vessels, both arteries and veins, of the gland. Albert Kocher (*Mitt. a. d. Grenzgb. d. Med. u. Chir.*, Bd. II, Heft, I, pp. 1-304) is authority for the statement that in their clinic all cases of exophthalmic goitre examined presented indubitable evidence of an increased vascularity both of the capsule and substance of the gland.

Although the pathogenic changes just described, and which correspond closely in most respects with those found in simple diffuse hypertrophic goitre, are considered by von Eiselsberg (*Deutsche Chirurgie*, 1891, Lieferung 38) and others as constant and pathognomonic of exophthalmic goitre, yet any anatomical form of goitre may be associated with symptoms of hyperthyroidism, viz., tachycardia, tremor, etc. The cases are best termed secondary exophthalmic goitre or simply as hyperthyroidism.

In other organs, changes of a secondary character are found. Frequently the heart is dilated; there may be hypertrophy of the left ventricle; in many, fatty degeneration of the muscle and myocarditis are present. A constant finding is the widespread changes in the voluntary muscles throughout the body. In old cases, intramuscular lipomatosis and degeneration of the muscle cells is a nearly constant finding.

The degeneration which takes place in the muscles throughout

the body, and which is probably the direct result of the action of a toxic substance upon them, explains practically all the symptoms of the disease. To these changes we can trace the origin of the tremor, the general emaciation, and the loss of converging power. A weakening of the pharyngeal and tongue muscles from the same cause will give the so-called bulbar symptoms which were formerly regarded as evidence of disease of the medulla. The phenomenon of Bryson—loss of inspiratory expansion of the muscles of the thorax—depends upon a degeneration of the muscles of inspiration; namely, the thoracic muscles and the diaphragm. Lastly, the exophthalmos may be explained by the weakening of the ocular muscles, that permits of over-distension of the vessels of the eye and causes the bulging forward of the organ. This over-distension is the direct result of the loss of support furnished by the muscles that normally control the eye and retain it in place. Frequently enlargement of the lymphatic glands is found throughout the body. This is often associated with a persistent thymus gland giving the anatomical findings that have been termed the status thymicus, or status lymphaticus. In the absence of any other known cause, it would seem reasonable to suggest a possible relation between a diseased condition of the thyroid gland and this lymphatic hypertrophy.

The surgical history of exophthalmic goitre dates from the publication of Tillaux (*Bull. de l'Acad. de Med. de Paris*, April 27, 1880), in 1880. In 1884 Rhen (*Berliner Klin. Woch.*, XXI, No. 11, 1884, pp. 163-166) reported four cases of exophthalmic goitre cured by partial thyroidectomy. Both operators resorted to surgical measures because of the local condition, size and character of the goitre, which called for removal of the tumor, and not with the idea of curing the disease. In both the cessation of the active symptoms of the disease was unlooked for.

Others during this decade (1880-1890) operated with success, although the exact way by which a cure was brought about was not understood. Of those who were among the first to develop and improve operative technic may be mentioned Krönlein, Kocher, Riedel, Mikulicz and Lemke. Heydenreich, in 1895, published 61 cases, of which 51 recovered or were greatly improved, 4 died, and 6 were not benefited.

After the publication of the excellent monograph of Möbius, in 1895, in which a definite pathology was established, the operative treatment was generally accepted as providing the most certain method of diminishing the pathologic secretion of the gland by removal of a part of the diseased organ.

Indications for operative treatment of exophthalmic goitre.—In my opinion, the favorable results obtained by the operative removal of a portion of the thyroid gland, whenever symptoms of hyperthyroidism exist, should lead us to adopt this method of treatment in all cases where the symptoms are not readily controlled by the usual non-surgical remedial agents.

Of the special indications which may be considered as positive for operative treatment of this disease, I may mention: 1. When the degree of exophthalmos is such that destruction of the eye from ulceration and infection is imminent. In long-standing cases the usual operative procedure, partial thyroidectomy, may not immediately bring about the desired result. It is in this class of cases that the operation of total excision of the cervical sympathetic has been extolled, particularly by Jonnesco and Jaboulay. After partial thyroidectomy in the more acute cases, the recession of the eye may be immediate. I have seen a marked decrease in the degree of exophthalmos occur during the first few hours after the operation. Accepting the reports of the cases treated by total cervical sympathectomy, it would appear that improvement in the exophthalmos occurs with more certainty and even earlier than after operative procedures on the thyroid gland.

2. A second positive indication for operative treatment is where the goitre is large and the pressure symptoms are urgent. In these cases no delay should be tolerated if the general condition of the patient warrants an operation. If the patient's condition does not warrant removal of a portion of the gland, relief from the most urgent manifestations of pressure may be had in selected cases by division of the isthmus of the gland, evacuation of cysts or by tracheotomy, if the anatomical relations of the organs permit.

A small-sized goitre need not influence against an operation. Frequently, with comparatively small glands, the effects of excessive secretion with resulting toxemia are most pronounced.

A contraindication to operative treatment is excessively high pulse rate, particularly if it is irregular or weak and thready in character. Generally an operation under a general anesthetic is contraindicated if the pulse rate reaches 180. When in selected cases the less dangerous operation of ligation of the superior thyroid vessels is chosen, this high pulse rate may constitute only a relative contraindication.

Edema, if general, exhausting diarrhea and ascites and prolonged vomiting constitute positive contraindications to any operative treatment until by rest and judicious medical treatment the patient's gen-

eral condition is improved to a point when operative measures may be considered. In general, a dilatation of the heart, sufficient to be recognized by physical signs, constitutes a contraindication to opera-

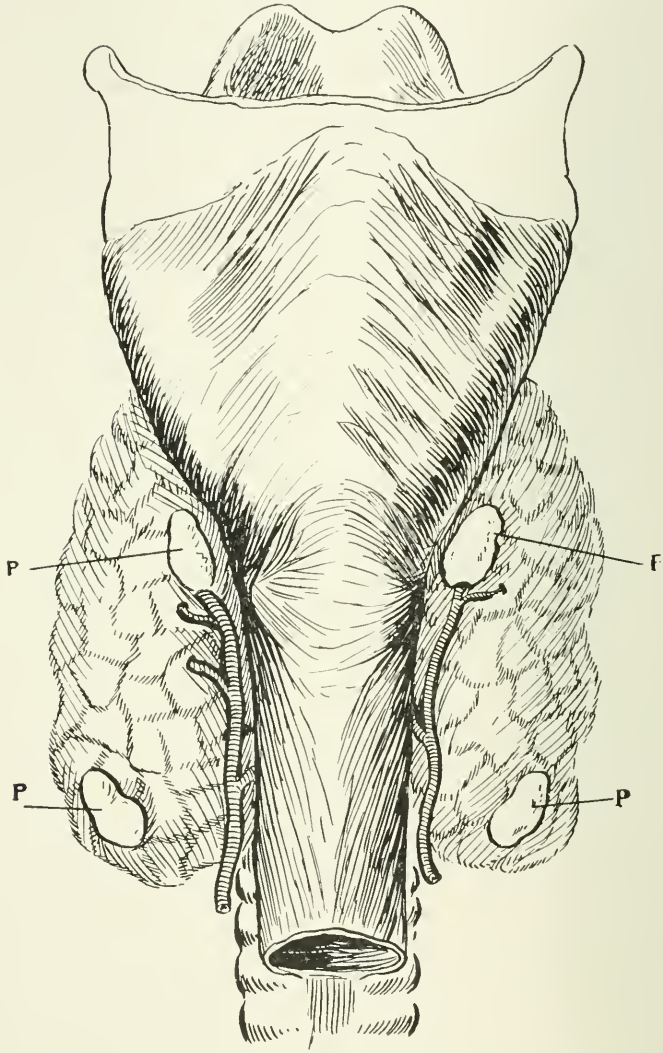

Parathyroid Glands in their Normal Relations to the Thyroid Gland. (After Ochsner.)

tive treatment, excepting when the operation is done under local anesthesia.

It may be stated, in general terms, that in the most severe forms

of exophthalmic goitre, when the pulse rate is extremely high, with wide variations in volume and rhythm, and where there are other evidences of a high grade of toxic myocarditis, or where psychic disturbances are manifested, no operation should be considered.

As a preparation for operation in severe cases, these patients should be placed at rest in bed and receive such medical treatment as their peculiar symptoms demand.

Frequently, as a result of rest and quiet alone, great improvement may be noted. If this desired result is attained, an operation when the patient's condition is most favorable may be considered. If, on the other hand, the symptoms do not improve, or become worse, an operation should never be considered as a last resort. In this class of cases a fatal outcome is to be expected and to operate under these conditions results only in discredit to the art of surgery.

The operative procedures employed in the treatment of exophthalmic goitre may be classified as follows:

1. Operations on the gland itself. (a) Partial excision, generally unilateral thyroidectomy. (b) Enucleation of cysts, cystic tumors and encapsulated growths, as adenoma. (c) Incision and drainage of cysts. (d) Exothyropexy.

2. Ligation of thyroid vessels.

3. Operations on the cervical sympathetic nerves and ganglion. (a) Section of sympathetic cord, either unilateral, as practised by Edmonds, or bilateral, after Jaboulay. (b) Partial resection, Jaboulay, Vignard and Quenu. (c) Total bilateral resection by which the three ganglia on each side, with their connecting cords, are completely removed, Jaboulay.

At the present time the operation usually chosen in the treatment of exophthalmic goitre is unilateral or partial excision of the gland. The technic is practically the same as when a portion of the gland is removed in simple goitre.

1. Position of the patient: The patient should be placed upon the operating table with the head slightly elevated and the tumor brought into prominence by placing a (bolster) pillow between the shoulders and underneath the neck.

2. Anesthetic: Formerly it was our practice to operate under Schleich's method of local anesthesia, employing a 1:1000 solution of cocaine for infiltration of the skin and subcutaneous tissue. During the last two years this method has been abandoned and ether anesthesia by the drop method from an open mask has been used exclusively. Our reason for substituting ether anesthesia for local is that we believe that the psychic shock where the patient is not rendered

unconscious is generally more dangerous than is the effect of a general anesthetic. It is also true that the operator is not capable of doing his work as expeditiously and as dextrously when operating with the patient conscious.

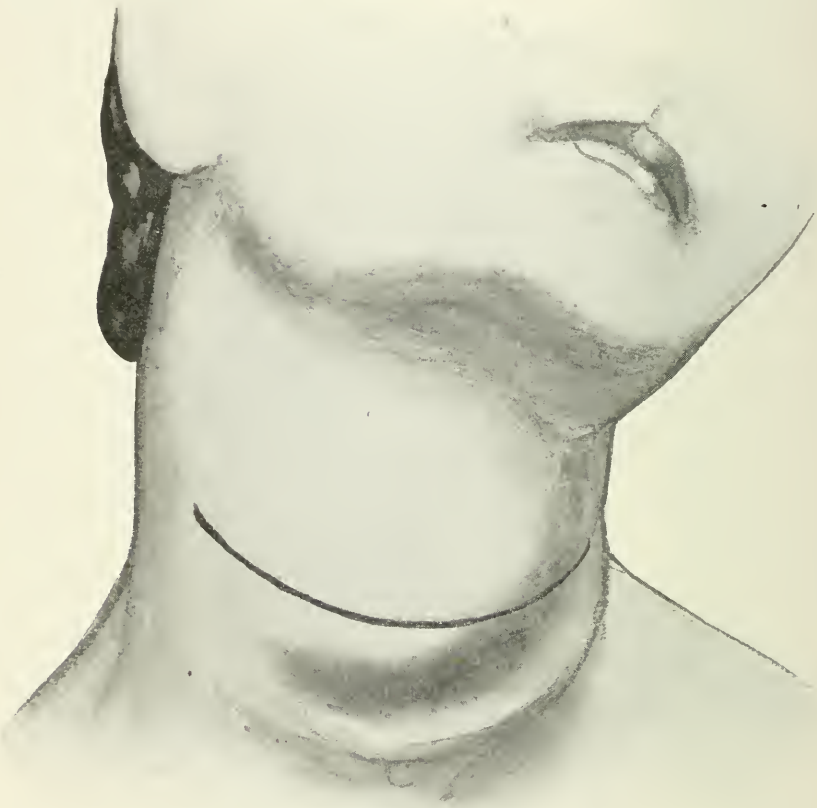

Kocher's Transverse or Collar Incision in Strumectomy.

We believe that chloroform is in every case contraindicated by reason of the toxic myocarditis that is an essential and constant feature of the disease.

Here, as in brain surgery, the success or failure of the operation in a considerable measure depends upon the skill of the anesthetist. In all cases he prepares himself as if he were to assist in the opera-

tive work by scrubbing the hands and donning gloves, gown, cap and mouth gauze.

3. Preparation of the field of operation: This is generally made after the patient has been anesthetized. Preliminary preparation, as carried out in other operations, is not practised in exophthalmic goitre, for the reason that any psychic stimulation greatly increases the activity of the gland, thereby increasing the toxemia, thus enhancing the dangers of the operation.

We believe with Crile that before the operation anything that would tend to excite the patient should scrupulously be avoided. For this reason no preparation of the field is made until after the anesthesia is complete.

Kocher warns against the use of strong antiseptic solutions even on the skin of a patient suffering from exophthalmic goitre. He claims that the greatly increased capability of absorption in these cases renders their use extremely dangerous. It is our plan to scrub the skin lightly with gauze, using green soap and then alcohol only. No other antiseptic is employed.

4. Skin incision. We employ the Kocher transverse incision through the skin and platysma over the more prominent part of the tumor. The incision, starting from the outer border of the sterno-mastoid, passes across the neck with the convexity downwards. A generous incision is to be recommended. The skin and platysma are now reflected upwards, exposing to view sterno-hyoid, sterno-thyroid, omo-hyoid and sterno-mastoid. The vessels in the skin, of which the most important are the anterior and external jugular veins, are caught and immediately ligated with fine iodized catgut.

The medium line of the neck is sought for and the fascia divided upwards to the lower border of the larynx. The depressor muscles of the larynx of the two sides may then be separated. In small-sized tumors, lateral retraction of these muscles may be sufficient to permit of dislocation of the part of the gland to be removed. Generally transverse division of the sterno-thyroid and sterno-hyoid at a level slightly above the skin incision will be found necessary. This should be done only after the muscles are first secured above and below by forceps that prevent retraction of the divided ends. In extremely large glands the inner border of the sterno-mastoid may be incised.

The lamina of the deep cervical fascia forming the fibrous capsule of the gland is recognized and divided transversely across the portion of the gland to be removed.

The second step consists in freeing the gland from the fibrous capsule by blunt dissection or with the fingers, and dislocating the

lateral half of the gland outwards to the surface of the neck. Hemorrhage from small vessels torn by this act is controlled immediately by ligature.

The operation is continued by retraction of the sterno-mastoid outwards and the fibrous capsule and superficial soft structures upwards, exposing the superior pole of the gland with the superior thyroid vessels. These are isolated and crushed by a heavy artery forceps and ligated first separately and then together, and severed between the ligatures and a large Kocher forceps placed close to the gland.

The partially liberated gland is now drawn toward the opposite side, the sterno-mastoid retracted farther outwards and the inferior thyroid artery sought for at the lower and outer angle, where it reaches the gland by passing underneath the carotid after being given off from the thyroid axis. The recurrent laryngeal nerve is generally behind the artery. By making gentle but firm traction toward the opposite side and upwards, the artery is rendered tense and may be felt as a pulsating cord. If at the same time the gland is lifted forward the artery may be separated from the recurrent laryngeal nerve behind. This act is of great importance in preventing injury to the nerve when the ligature is applied to the vessel.

Ligation of the main trunk of the vessel should be made as close to the surface of the gland as practicable, so as to still further insure the safety of the nerve.

In ligating both the superior and inferior thyroid vessels, we always employ Pagenstecher linen for the ligature material. This offers additional security against the ligature slipping, with the consequent serious hemorrhage.

The middle thyroid vein should be isolated and tied with a separate ligature of linen. The thyroid ima artery, with its accompanying vein, should be searched for on the median side of the dislocated lobe. If present, they should be tied.

The lateral half of the gland is now separated carefully from the fibrous capsule posteriorly as far as the isthmus. This is well freed from the trachea and caught with a Kocher goitre clamp and crushed. It is now divided distal to the clamp with a cautery knife. Ligation is unnecessary. The wound is now sponged dry and all bleeding points secured by forceps and then ligated. The most absolute hemostasis must be secured.

The wound is carefully washed with normal salt solution, the divided muscles reunited by catgut sutures and tubular drainage inserted into the deepest angle of the wound. The skin is sutured,

excepting at the exit of the drains, by a continuous horsehair suture. The wound, excepting the point where drainage passes out, is covered with silver foil and a large dressing applied.

Kocher's Angular Incision in Unilateral Resection of the Thyroid Gland; Skin, Fascia and Platysma Divided; Median Jugular Vein Crossing the Incision.

At the end of forty-eight hours the tubular drainage is removed and, if the discharge of wound secretion is small, no other drain is inserted. If, on the other hand, the secretion from the gland and the wound is still considerable, a small strip of gutta percha tissue is inserted and secured by a safety pin. At the end of the fourth day

all drainage is removed and the wound sealed with collodion over the silver foil.

Opium and belladonna are given after the operation in sufficient quantities to secure rest and quiet for the patient.

In common with operations on simple goitre, hemorrhage, either immediate or subsequent, constitutes an element of danger. Hemorrhage at the time of the operation is more to be feared in exophthalmic goitre than in excision of the gland in ordinary cases of goitre. In the former the great vascularity of the gland, the increased friability and lost retractile power of the walls of the vessels, as shown by Albert Kocher (*Mitt. a. d. Gr. der Med. und Chir.*, Bd. 9, 1902, p. 1-304) and Gerhardt (*Mitt. a. d. Grenzgebiet der Med. und Chir.*, 1896, Vol. 1, pp. 135-138), constitute an important factor in the causation of a dangerous hemorrhage. In the late stages of the disease in particular we find extensive degeneration of the media, with loss of elastic substance and separation of the media and adventitia, rendering the structure of the vessel exceedingly brittle. As a consequence, small vessels are not automatically closed and the large ones frequently are torn through by the ligature, permitting a continuation of the hemorrhage or later promoting a secondary hemorrhage. A second frequent cause of secondary hemorrhage is the inclusion in the ligature of a portion of muscle, which, upon contraction of the muscle, pulls the ligature from the vessel. This accident can be avoided if the vessels are isolated carefully before ligature is applied and the dangers of muscle inclusion are borne in mind. In simple goitre, when the vascular system is in a relatively normal condition, a considerable loss of blood can be borne without great risk to life. In exophthalmic goitre, especially in the later stages of the disease, with toxic myocarditis and cardiac dilatation, a relatively small hemorrhage may prove fatal.

Besides the dangers incident to operation for simple goitres, we have in exophthalmic goitre certain conditions that may be developed during and after the operation that may cause a fatal termination. It is well known that patients suffering from this disease, especially those with pronounced tachycardia, bear general anesthesia of any kind badly. The degenerated heart muscle, with the increased irritability of the heart centers in these cases, greatly increases the chance of death in chloroform narcosis. In other cases where the goitre is large, or in the retro-sternal or retro-clavicular struma, the dangers from ether are equally great. In a few no general anesthetic should be given. In quite a number of cases the symptoms that were present before operation become greatly exaggerated immediately following

it. The pulse increases in frequency and becomes arhythmical, the exophthalmos becomes more pronounced, tremor and elevation of

Unilateral Thyroidectomy Through Kocher's Angular Incision after the fibrous capsule has been incised and the lateral half of the gland dislocated toward the median line; the sterno thyroid and the sterno hyoid muscles cut. The inferior thyroid artery and recurrent laryngeal nerve are shown at the lower angle of the wound.

temperature rapidly increase. Great muscular weakness and delirium, with suppression of urine, are the symptoms which usually precede

speedy dissolution. These symptoms are due to an escape into the tissues, thence into the circulation, of a large quantity of toxic secretion of the gland. The already weakened nerve centers are simply overwhelmed and the patient succumbs.

It is rarely after an operation for exophthalmic goitre that we see a case run an apyretic course. Usually, for a while at least, the pulse is accelerated and the temperature elevated, even where no sepsis is present. Sudden deaths some hours or days after the operation may unexpectedly occur. These deaths are probably the result of general lymphatic and thymic hypertrophy, which is so often found in cases of exophthalmic goitre. It is now well known that sudden death, when no operation has been performed, is a possible termination of these cases of status lymphaticus. On post-mortem nothing but degeneration of the heart muscle and general lymphatic hyperplasia is found.

Death from collapse of the trachea occurs after operation for any form of goitre. Fütterer has shown that in cases where continued pressure by a tumor is made upon the trachea for some time, a mucoid degeneration of the cartilage, with softening of the rings, results. After a sudden inspiratory effort the weakened cartilages may collapse and death from asphyxia follow.

A remote risk to the patient lies in injury to the parathyroid glands. If the technic of the operation, as described, is followed, there is no great danger of injuring these glands. C. H. Mayo believes that the risk is about as great as that of embolism following abdominal operations.

In considering the curative value of the operation, great difficulty is encountered because of the great variation in what different observers consider a cure. In a series of cases reported by Sorgo (*Centralbl. f. Grenzgb. d. Med. u. Chir.*, May, 1898, Bd. I, No. 6, p. 329) the results regarding the individual symptoms are tabulated. His table includes 172 cases. Of these, the tremor entirely disappeared in 57.9 per cent., the tachycardia in 48.7 per cent., and the exophthalmos in 48.2 per cent. The general condition of the patient was practically normal in 30 per cent. of the cases. In about 25 per cent. of the others there was great improvement in the symptoms, but the patients could not be said to be cured of any. The operation mortality in these cases is 13.9 per cent. The results, as shown in the cases reviewed by von Eiselsberg, which include those reported by Mattisen (*Inaugural Diss., Erlangen*, 1896), Heydenreich (*Semaine Med.*, 1895, XV, p. 32), Starr (*Jour. of Nerv. and Ment. Dis.*, 1894; also *Med. News*, 1896, Vol. LXVIII, pp. 421-529), Schulz, Buschan,

Manheim, and Sorgo, giving in all 1,223 cases, show complete recovery in 44.8 per cent., and great improvement in 23 per cent. The mortality in these cases was 8.3 per cent.

Friedhain (*Arch. f. Klin. Chir.*, Bd. 77, p. 917) investigated the late results in 20 cases operated upon by Kümmell. These cases were examined from four and one-half to fifteen and one-half years after the operation. Of these, 14 were absolutely cured. Five, after periods varying from three and one-half to nine and one-half years, were found to be greatly improved and able to go about and continue their occupations, although all of the symptoms had not disappeared. One death resulted in this series, probably from hyperthyroidism, although necropsy did not reveal the cause.

With the improvement in technic the operative mortality and the percentage of cures have steadily improved up to the present time. Rehn, in 1900, reported 50 per cent. recoveries, with 22.1 per cent. mortality. Friedhain, 70 per cent. cures, with 5 per cent. mortality, in a series of 20 cases. Reviewing the reported cases from the clinics of Mikulicz, Krönlein, Kocher and König, he found, of the 105 cases reported, 75 cured (70.1 per cent.), 23 improved (21.9 per cent.), and 8 deaths (7.6 per cent.).

The mortality of partial thyroidectomy for exophthalmic goitre runs, in the cases reported within the last two years by various operators, from 13 to about 6 per cent.

C. H. Mayo (*Surgery Gynecology and Obstetrics*, March, 1909, p. 237) reported in 1908, 295 cases treated by partial thyroidectomy, with 18 deaths (6.1 per cent.), 7 of which occurred in the first 46 cases operated on by him. One death occurred on the table from shock, fifteen from acute thyroid intoxication—all within twenty hours after the operation. Two deaths resulted from embolism, one cerebral and one pulmonary.

Intraglandular thyroid enucleation.—This operation, first practised by Porta and later extensively employed by Billroth, Wolff, Bruns and others, in the treatment of circumscribed simple goitre, has but a limited field of application in the treatment of exophthalmic goitre. It is applicable only to those cases of goitre upon which symptoms of hyperthyroidism have been grafted and is not to be considered in the operative treatment of the type of goitre that is characteristic of primary Graves' disease. As we have shown, this type represents the more or less diffuse form of hypertrophy or hyperplasia of the thyroid gland. Although this form may appear as a unilateral goitre, yet the nature of the glandular enlargement does not permit of the enucleation of the tumor.

In adenoma, either pure or those having undergone the various metamorphoses common to these growths, and in cystic tumors, we have in this method the safest means of removing the tumor and reducing and favorably influencing the thyroid secretion that is the essential cause of the disease.

Technic. The incision is the same as for unilateral thyroidectomy, namely, the transverse collar incision of Kocher, or the angular incision, depending upon the size, position and form of the tumor. The incision includes the skin, fascia and platysma. The deep fascia is incised in the median line as in the operation for excision of the gland. The depressors of the larynx are either retracted or incised transversely, depending upon the location and size of the growth. The thyroid is exposed but not dislocated, as in thyroidectomy. Between the larger vessels of the capsule the cellular tissue and capsule are incised, with what gland tissue may exist, down to the tumor. The small vessels that are cut are caught and ligated. When the enveloping capsule of the growth is reached, the tumor is quickly but carefully separated from the capsule, either by means of the fingers or by Kocher's director. Hemorrhage at this stage of the operation is usually insignificant and can be readily controlled by temporarily packing the cavity left by enucleation of the tumor. Permanent hemostasis is best accomplished by closing the cavity by a suture of catgut.

After bringing together the edges of the cavity by suture of the gland tissue, no drainage is necessary, providing the hemostasis is effective and complete. The cut muscles and skin are reunited as in partial thyroidectomy.

The greatest danger in intraglandular enucleation is hemorrhage. In extremely vascular growths or in hypertrophy or hyperplasia, or in the so-called struma vasculosa, it goes without saying that this procedure should not be chosen, but systematic ligation of the thyroid arteries and excision of a half of the gland should be selected.

The advantages presented by this operation, under favorable conditions, are that it saves from injury the neighboring important structures, namely, the recurrent laryngeal nerve and the parathyroid glands, and that it does not by cicatrization and interference with blood supply expose to remote changes these delicate structures. It also permits of a second operation on the same side or on the opposite side by conserving gland tissue.

The chief objection to its application to exophthalmic goitre or cases of hyperthyroidism is that by it we frequently do not remove

sufficient secreting thyroid substance, and therefore do not control the excessive secretion that is the cause of the symptoms.

Resection-enucleation of Kocher.—This operation is occasionally employed by Kocher in the treatment of exophthalmic goitre. Like intraglandular enucleation, it has a greater field of application in simple goitre. It is, according to Kocher, chiefly of value in diffuse follicular colloid or cystic degeneration.

The various steps of the operation up to the point where the gland is exposed are the same as described under intraglandular enucleation. The isthmus is freed from the trachea, crushed and divided between two ligatures. The goiteroid mass is then freed by means of the fingers from the posterior surface of the gland, leaving the posterior portion of the gland and the glandular capsule intact. After separation of the tumor from the overlying gland tissue and the posterior portion of the capsule, the outer remaining pedicle, consisting of gland tissue and capsule, is crushed, ligated and incised. This procedure protects the recurrent laryngeal and the parathyroids.

Hemorrhage is controlled by suture ligature as in the enucleation operation. This method possesses the advantage of conserving considerable gland tissue, which is of great importance when both lobes are extensively diseased in diffuse cystic degeneration. This type of goitre is seldom associated with symptoms of excessive secretion.

Incision and drainage of the thyroid.—This operation is indicated only in large cystic goitres when repeated attacks of inflammation have caused dense adhesions of the cyst wall to the surrounding structures. The method of operating is as follows: (*Surgery, Gynecology and Obstetrics*, March, 1909, p. 237):

An incision is made over the most prominent part of the tumor down to the gland. The vessels of the capsule, both fibrous and glandular, are ligated and divided. The cyst wall is incised and the cut edges are sutured to the skin. From the cavity all colloid masses are removed with the fingers. The cavity is packed with gauze to control hemorrhage and facilitate drainage.

Exothyropexy, as practised by Jaboulay, consists in freeing the gland from its environs and dislocating it upon the surface of the skin, where it is allowed to remain. As a result of atrophy and resorption, the gland gradually shrinks and becomes cicatrized. This operation has been practised chiefly in France, and there by but a few surgeons. Following exothyropexy, symptoms of acute thyroid intoxication are frequently noted from the escape into the tissues of the secretion of the gland. An improvement in the most favorable cases is extremely slow.

Berard (*Thérap. Chirurgicale du Goitre,* 1897; also *Traité de Chirurgie*, Vol. XX, 1908, p. 398) mentions 12 cases operated upon by Jaboulay and Poncet. Of these, 7 were considerably improved, but none could be said to be cured, although later other surgical procedures, such as excision, enucleation and sympathectomy, were more easily performed and cured the patients.

In the 12 cases operated upon there were 2 deaths from acute hyperthyroidism following the operation. In this country exothyropexy has not been practised, and is not generally sanctioned by the profession.

The principal objection to this operation is the difficulty in dislocating the gland, particularly when the goitre is large and deep-seated. Dyspnea and venous hemorrhage are frequent, and constitute the greatest risk to the patient. Healing is slow and frequently accompanied by septic infection. Finally, the deformity resulting is great and the cures infrequent.

Technic. A vertical incision along the median line of the neck from the larynx to the episternal notch is carefully made through the skin and fascia down to the cellular space between the sternothyroid muscles. Retraction of these muscles from the median line exposes the fibrous capsule of the gland. Each thyroid lobe is then separated anteriorly from its capsule by means of the fingers until the margins of the gland are reached. If retraction of the muscles does not give sufficient room, the muscles, fascia and skin are incised. Each lateral lobe is now drawn forward by hooking the fingers underneath its external border and lifting it out of the wound. Occasionally both lobes may be dislocated simultaneously. This, however, is dangerous because of the risk of compression of the trachea. The glandular capsule should never be penetrated.

Strips of gauze are now packed about the gland to protect the wound from contact with the secretion of the gland and to prevent the gland from being drawn back into the incision. The skin is allowed to unite with the gland and to gradually cover it. Great care is necessary in preventing infection during the process of cicatrization, which on an average, requires two months.

Ligation of thyroid arteries.—This operation, as with the other operations mentioned, was first practised in the treatment of simple goitre. Its application to exophthalmic goitre was first recommended by Mikulicz (*Verhand. der Deutschen Gesellschaft f. Chirurgie,* 1895, 24th Congress, p. 21) and Kocher.

Various operators have advised the ligation of one or more thyroid vessels in extreme cases as a preliminary step where later exci-

sion is to be practised if the patient's condition will warrant this operation. At the present time the operation is seldom practised excepting as a means of preparing the patient for a more radical operation. Under these circumstances one or both superior thyroid arteries, with the accompanying veins, are ligated, either by isolation

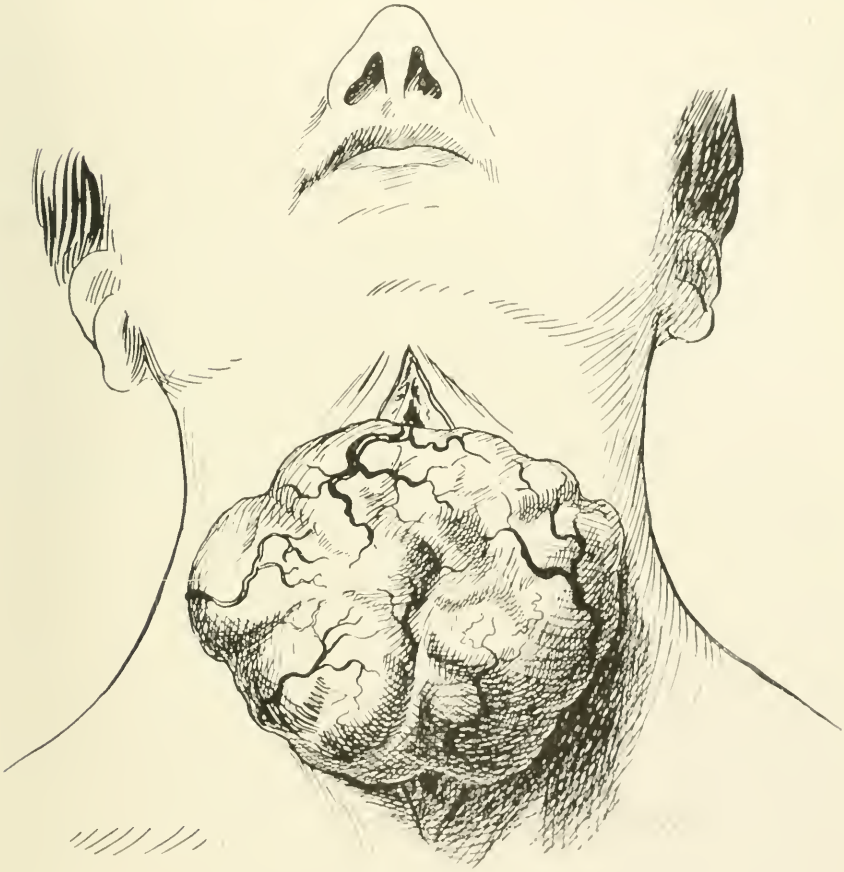

Exothyropexy in Graves' Disease.

of the vessels or by including it in a mass ligature applied to the superior pole of the gland. As a curative operation, ligation of two vessels is not to be considered. The ligation of three vessels, two superior and one inferior, may sufficiently control the circulation to cause atrophy of the gland, but the dangers of this operation are as great as those of partial resection, and the chances of effecting a cure

considerably less. Even ligation of the superior thyroids alone in extreme cases of Graves' disease is not free from danger.

Rehn (*Mitt. a. d. Gr. d. Med. u. Chir.*, Bd. 7, p. 169) mentions 20 cases in which he ligated from one to three vessels, with a mortality of 20 per cent. Of these, only 5 were cured and 10 slightly improved.

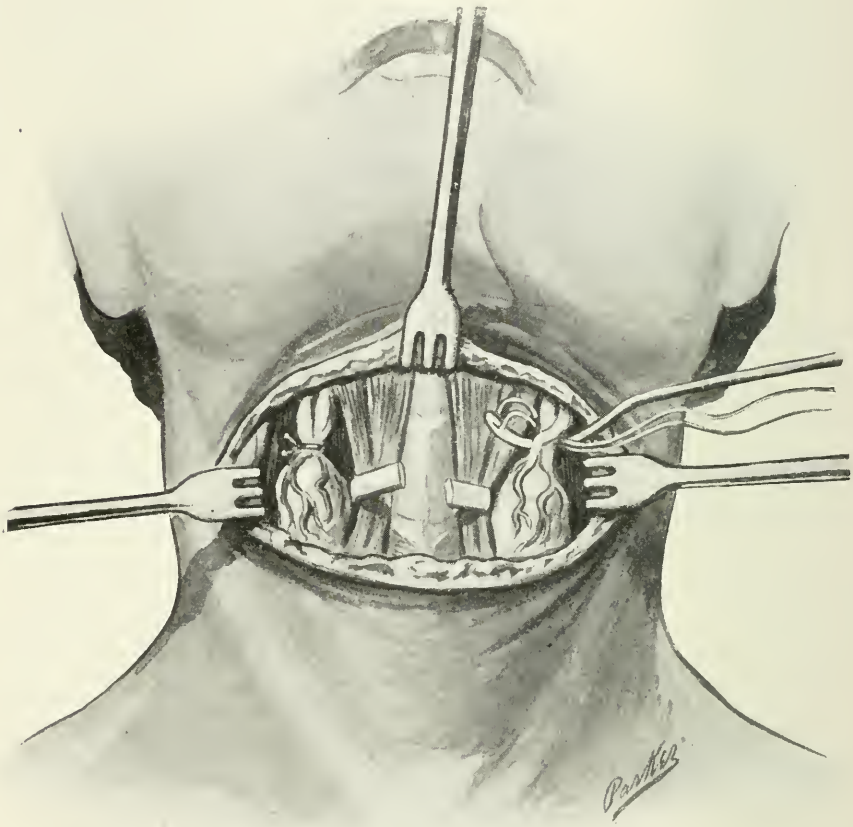

Mayo's Incision for Ligation of the Superior Thyroid arteries in exophthalmic goitre.

When after extirpation of one lobe the symptoms persist, indicating that sufficient gland tissue has not been removed to effect a cure, ligation of the opposite superior thyroid vessels may be considered. Kocher strongly recommends this procedure under these conditions.

In patients in whom the disease is not too far advanced, the danger associated with ligation of the superior thyroid alone is, in my opinion, very small. The operative mortality in 97 cases of double ligation, reported by C. H. Mayo (*Surgery, Gynecology and Obstetrics,* March, 1909, p. 237) was one. In fourteen cases the superior thyroid on the side remaining after extirpation of a lateral half gave no mortality.

The same operator reports later (*Annals of Surgery*, Dec., 1909, Vol. 50, p. 1018) 225 cases of ligation of the thyroid artery with a mortality of 2 per cent. The curative value of the procedure was considered in this paper. The results were as follows:

There was slight improvement in 9, great improvement in 44, very marked improvement in 11, absolutely cured, 4, no improvement, 9. In the majority of these cases the operation was made as a preliminary step to removal of a part of the gland.

Kocher's skin incision transversely across the neck, on a level with the lower border of the thyroid cartilage, slightly curved, with convexity downwards and the extremities of the incision carried vertically upwards for a short distance along the anterior border of the sterno-mastoid. After division of the skin, platysma, the sterno-mastoid is retracted outwards, exposing the lower border of the larynx and the omo-hyoid, which is pulled upwards and toward the median line. The superior pole is isolated. The superior thyroids are found just above the omo-hyoid muscle, are isolated and doubly ligated.

If the ligature is thus applied, the superior or recurrent laryngeal nerves are not likely to be injured, as the field of operation lies between these two structures.

Ligation of the superior poles of the gland.—This operation has been practised by Jacobson (*Thyroid and Parathyroid Glands*, 1910, p. 163), of Toledo, in the treatment of exophthalmic goitre. The theory upon which the operation is based is met by including in the ligature both arteries and veins and, in addition, a considerable part of the poles of the gland, that not only is the blood supply to the gland lessened, but the escape of thyroid secretion into the circulation is prevented by occlusion of the lympathic vessels of the gland. Jacobson reported 8 cases operated upon by this method, with 1 death. The immediate effect of the operation seems to be about as satisfactory as ligation of both superior thyroids after the method of Mikulicz and Kocher. The ultimate results cannot be compared with those of other operative methods because of the comparatively short time that the cases were under observation.

Jacobson's technic is similar to that employed by Rydyger (*Arch.*

f. Klin. Chir., Bd. 40, p. 806) for ligation of the superior thyroid arteries.

The superior pole of the gland is reached through a short vertical incision to the inner side of the sterno-mastoid muscle, directly over

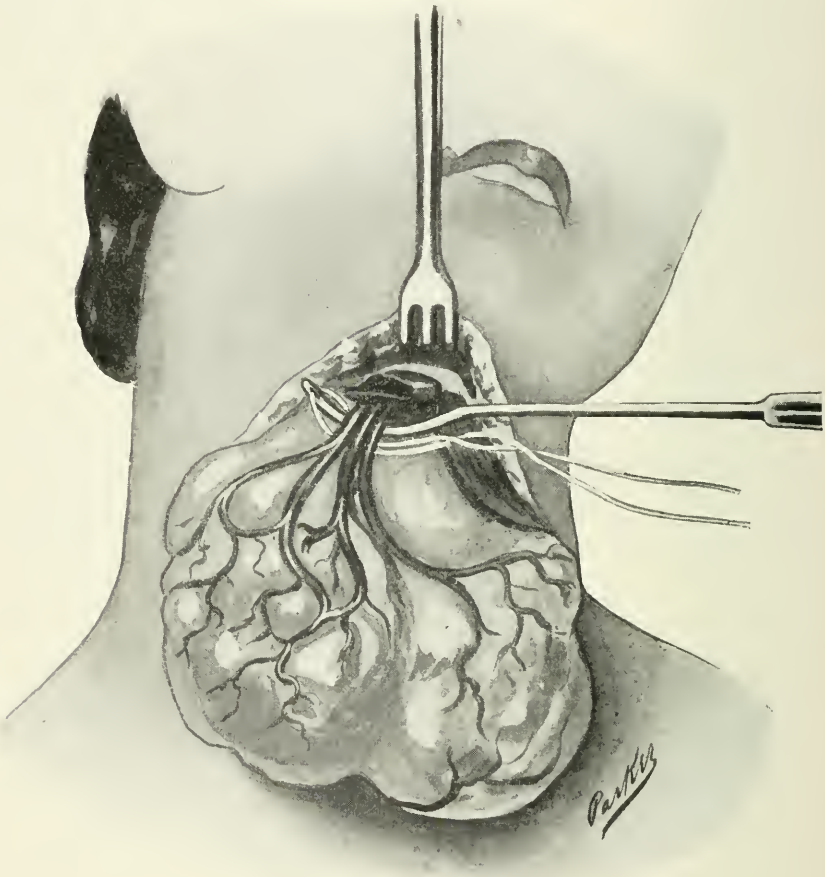

Unilateral Thyroidectomy. Ligation of the superior thyroid vessels after dislocation of the gland.

the upper pole of the gland. The sterno-mastoid is retracted outwards and the sterno-thyroid inwards, exposing the capsule of the gland, which is now incised. By means of a large aneurysm needle two strong ligatures of silk or linen are passed about the exposed portion of the gland, one and a half centimeters apart, and tightly tied.

The exact stages of this operation are thus described (*Surgery, Gynecology and Obstetrics*, Nov., 1910, p. 510), by the writer:

"The method consists in doubly ligating both upper horns of the thyroid gland and is carried out as follows: After carefully palpating and determining the position of the upper pole of the right lobe, either a transverse or an oblique skin incision is made directly over it. The incision is one and one-half inches long and extends through the skin, superficial fascia, platysma, down to deep fascia, when the inner border of the sterno-mastoid muscle can be seen. The inner border of the sterno-mastoid is then loosened, raised and retracted, exposing the fibers of the sterno-thyroid muscle which run in the opposite direction to those of the sterno-mastoid. These fibers are separated for about one inch; the deep fascia covering the thyroid will then be exposed. This fascia is next divided, and the capsule of the gland brought into view. The muscles are well retracted by blunt hooks. A ligature carrier or a large curved pedicle or aneurism needle is used to pass the ligatures. The material used for ligation has been mostly linen or silk. Theoretically it seems that heavy black linen on account of its slowness of absorption is best.

In passing the ligature around the upper pole on the right side, the blunt needle is passed from within out, while upon the left it is passed from without in, after first freeing and raising the pole somewhat by blunt dissection.

Theoretically at least, it seems that the ligature should be placed extra-capsular, for the reason that the lymphatic vessels of the gland parenchyma empty into the lymphatics contained within the capsule, and that the extra-capsular ligature will more effectually stop the gland excretion.

Some little resistance may be encountered in passing the blunt needle about the pole; this, however, is quickly overcome. When the blunt point of the needle has been passed, the ligature is grasped and the instrument withdrawn. By cutting the loop, we have two ligatures surrounding the gland pole. These are carefully separated and tied, leaving a space between them of from one-fourth to one-half inch. Immediately after ligation the gland tissue in the vicinity of the ligature becomes blanched.

The closure of the wound consists in the approximation of the muscles by one or two interrupted catgut sutures, followed by approximation of superficial fascia and skin.

The operation of "pole ligation" may be used in combination with other operations on the thyroid gland for the relief of exophthalmic goiter. It may be used in conjunction with the pressure atrophy

operation of Werelius, with partial thyroidectomy in which the ligation of the pole is made on the remaining lobe, and also in combination with ligation of one or both inferior thyroid arteries.

Aside from the possible advantage of including in the ligature gland tissue, blood and lymphatic vessels, this procedure has to recommend it simplicity and freedom from any great risk to the patient. It can usually be performed under local anesthesia and at the hands of a skilful operator should consume only a few moments. The chief danger lies in injury to the internal jugular vein or the carotid artery.

In discussing the treatment of exophthalmic goitre by *operative measures directed against the cervical sympathetic*, the stretching operation may be left out of consideration. The effect of simple section of the sympathetic cord has also but slight, if any, influence on the disease. This operation was first proposed by Edmonds. (*Path. Soc., London*, 1895, May 21st, p. 224.) Jaboulay (*Tr. 12th International Med. Cong.*, p. 515) reported six cases of unilateral and two of bilateral section of the sympathetic cord. In all the retraction of the eye became noticeable after the first day. The size of the goitre was lessened and the heart symptoms were somewhat improved. The pulse rate was not materially changed, but the heart's action became more regular and the tones clearer. One patient observed four years after the operation was greatly improved in health.

The results of partial resection, including both unilateral and bilateral operations, are, on the whole, more favorable than those obtained by simple section.

Balascescu (*Arch. f. Klin. Chir.*, Bd. 67, p. 59) reports from Jonnesco's clinic 27 cases treated by partial resection. These cases were observed from one to four years. Of these, 9 were cured, 11 improved, and 2 unimproved. There were five deaths. The same author reported 17 cases of total bilateral sympathectomy. Of these, 14 were operated upon by Jaboulay. Of the 17 cases reported by Balascescu, 10, or 58.9 per cent., recovered completely, the exophthalmos being the first to disappear. Improvement of the tachycardia was not so rapid nor, in general, so satisfactory as that of the first-named symptom. In some cases the pulse quickly reached the normal and so remained. In two cases the tachycardia reappeared after the pulse rate had been normal for some time. In five of the seventeen there was great improvement either in the exophthalmus, the general nervous manifestations, or in the tachycardia, although the patients could not be considered cured.

Curtis (*Annals of Surgery*, Vol. 43, p. 336), of New York, reported

7 cases of sympathectomy for exophthalmic goitre. Of these, 3 died, 2 from acute hyperthyroidism and 1 from the anesthetic. Of the 4

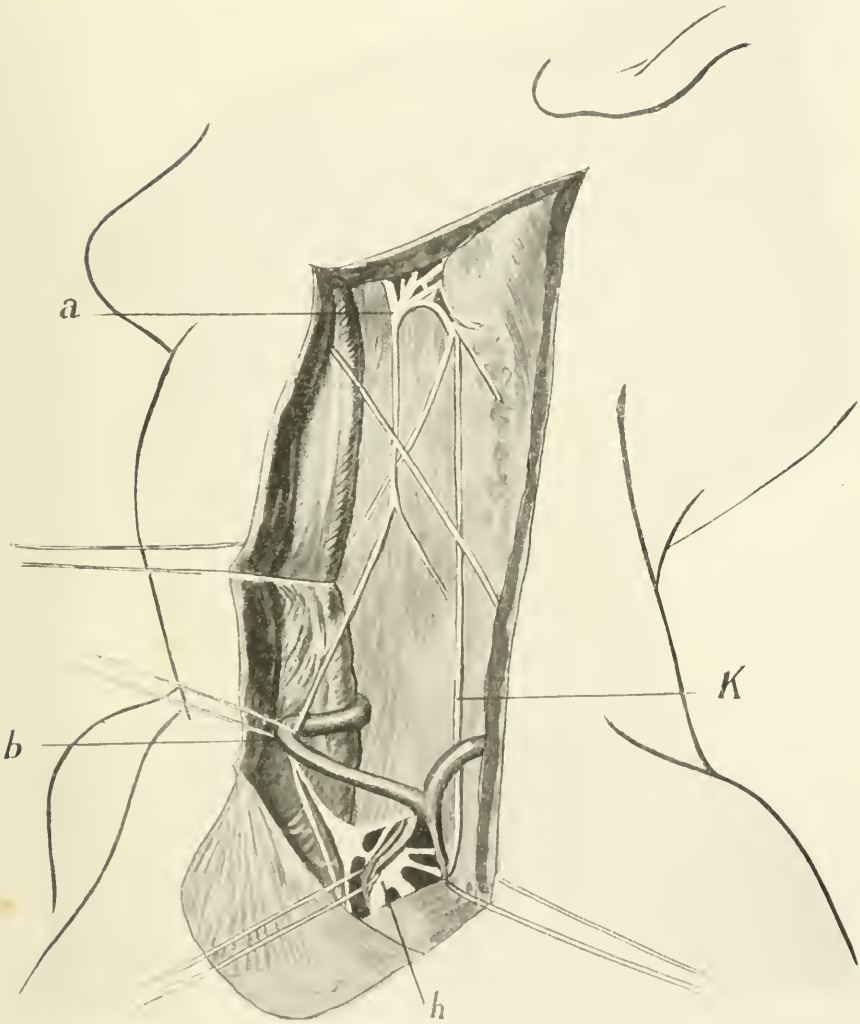

The Cervical Sympathetic Nerve and Ganglion.

a, Superior cervical ganglion. *b*, Inferior thyroid artery. *k*, Phrenic nerve. *h*, Middle cervical ganglion.

cases that survived the operation, one relapsed within nine months and died ultimately of an acute endocarditis. One case had greatly improved at the end of one year, but died of nephritis. One was com-

pletely cured at the end of five years, and one was improved. These results were so discouraging that Curtis abandoned the operation and advised partial thyroidectomy when an operation was to be considered. In reporting the cases he mentions as contraindicating this operation the unsightly scars, the high mortality and the uncertainties of relief that have attended this procedure.

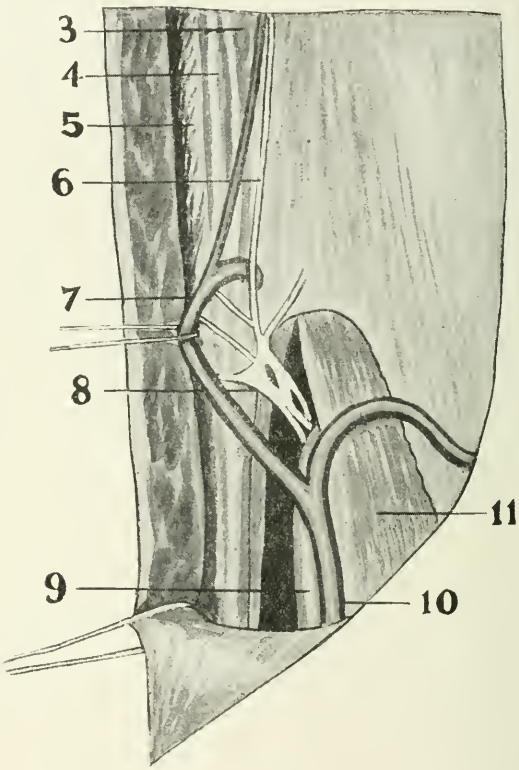

The Middle Cervical Ganglion. (After Bryant.)

3. Common carotid artery. 4. Pneumogastric nerve in sheath. 5. Internal jugular vein. 6. Sympathetic cord. 7. Inferior thyroid artery. 8. Middle sympathetic ganglion. 9. Thyroid axis.

The death rate, according to Rhem (*Mitt. a. d. Grenzgeb. der Med. und Chir.*, Vol. 37, p. 165), in total resection is 9.3 per cent. This, when compared to the mortality rate in unilateral resection of the thyroid for exophthalmic goitre, argues strongly in favor of the latter operation.

In considering the relative merits of the two procedures we must strongly advise partial thyroidectomy in preference to any operation

on the sympathetic. Total resection is an operation, in my opinion, many times more difficult and offering less hope of curative results than operations on the thyroid gland, particularly excision of a portion of the gland or ligation of the thyroid arteries. One of the strongest arguments against sympathectomy is that it has never been popular with surgical masters; that the theory upon which these procedures are based never has been accepted as adequately explaining the phenomena of the disease.

Total unilateral sympathectomy. The superior ganglion, the largest of the three, is generally found opposite the second and third vertebræ, although it may be as low as the fourth. It lies behind the carotid sheath and rests upon the rectus capitus anticus major muscle. The inferior ganglion lies between the base of the transverse process of the seventh cervical vertebra and the neck of the first rib, deep in the root of the neck. It is in relation with the superior intercostal artery internally. Externally, it is in intimate relation with the vertebral artery, which it invests with its branches. The middle ganglion, which is the smallest, is frequently but a slight fusiform enlargement of the cord opposite the sixth cervical vertebra, and in close relation to the inferior thyroid artery from which it derives the name of the thyroid ganglion. The cervical cord is in close relation to the vagus, descending branch of the hypoglossal and below with the phrenic nerves. Superficial to the cord and crossing it about the middle of the neck is the spinal accessory.

The patient is placed on the table with the head and shoulders slightly elevated. The head is allowed to hang over a pillow placed underneath the neck and shoulders, and the face is turned toward the side opposite to the one to be operated upon.

An incision is made beginning at the lower and posterior part of the mastoid, running parallel with the posterior border of the sterno-mastoid muscle, down to a point on a level with the lower border of the clavicle. This is carried through the skin and superficial fascia and platysma to the superficial lamina of the deep cervical fascia which forms the anterior layer of the sheath enclosing the sterno-mastoid muscle. The external jugular is caught between tissue forceps and cut between these. The deep fascia is incised close to the posterior border of the sterno-mastoid and the muscle retracted forward. Care is taken not to injure the spinal accessory nerve. Upon retraction of the muscle inward, with the common sheath of the carotid artery and jugular vein, the sympathetic cord is sought for about the middle of the wound. It will be found posterior to the sheath of the vessels resting upon the longus colli and scalenus anticus muscles.

Internally, it is in relation with the pneumogastric nerve, from which it must be differentiated. The sympathetic is recognized by tracing it upwards to the superior cervical ganglion. The ganglion is now isolated, its communicating branches divided, and with the cervical cord dissected downwards. As the lower angle of the wound is reached

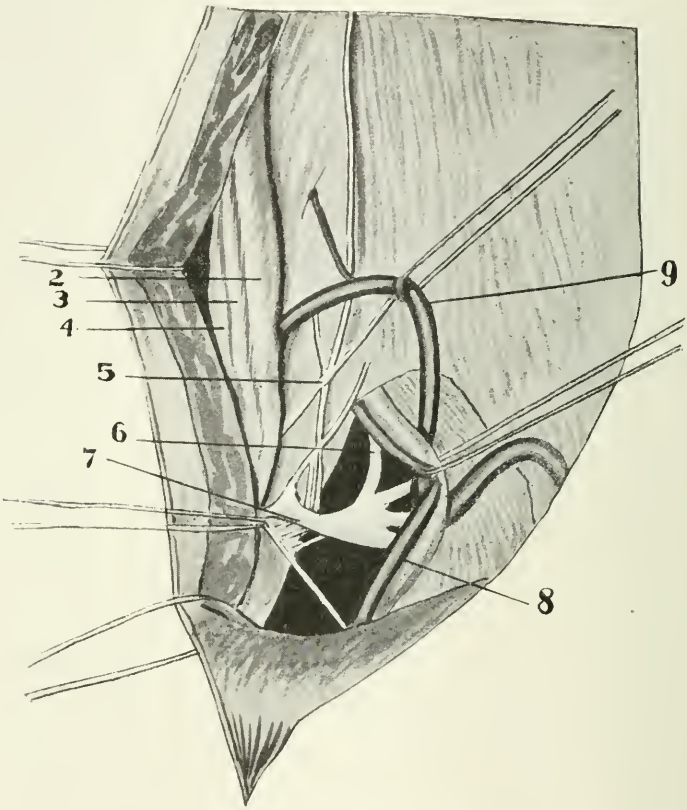

Inferior Cervical Ganglion. (After Bryant.)

2. Common carotid artery. 3. Pneumogastric nerve. 4. Internal jugular vein. 5. Middle cervical ganglion. 6. Vertebral nerve. 7. Inferior cervical ganglion. 8. Vertebral artery and vein. 9. Inferior thyroid artery.

the cord is drawn tense and the middle ganglionic enlargement freed from the inferior thyroid. At this stage of the operation I have found that division of the sterno-mastoid muscle through its tendinous lower end greatly facilitates this step, as it also does the succeeding steps of the operation. Continuing downwards, while making gentle traction on the nerve trunk, the lower ganglion is reached behind the

neck of the first rib. The vertebral artery and vein are isolated and with the scalenus anticus muscle are retracted outwards. Above, the inferior thyroid is at this time in danger of being injured. This is avoided by gentle retraction of that vessel inwards and upwards. With the sterno-mastoid divided the ganglion is found without great difficulty by tracing downward the sympathetic cord. Its branches of communication are divided with a blunt scissors and the ganglion removed.

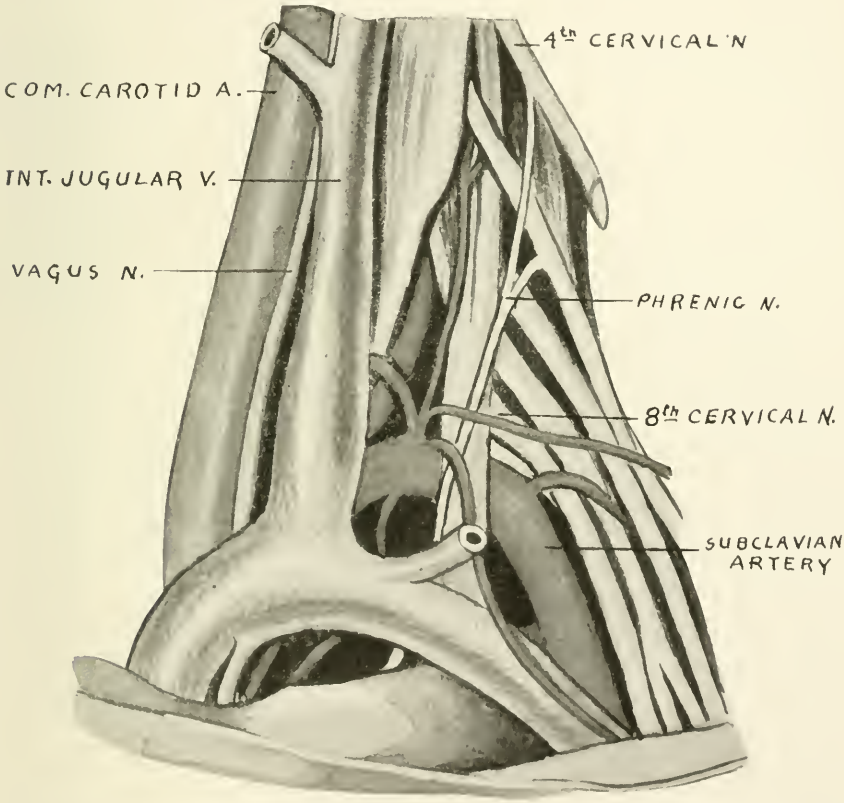

The Relations of the Structures Concerned in Removal of the Third cervical sympathetic ganglion.

The wound is closed without drainage after uniting the divided sterno-mastoid with deep sutures of catgut and the skin with silk-worm gut.

The chief danger of the operation is from injury to the large veins of the neck, with consequent hemorrhage or air embolism. A

clear conception of the anatomical structures that are in relation with the operative tract will enable the operator who has at his command the necessary dexterity to avoid injuring these important structures. Injury of the pneumogastric and phrenic nerves, though not necessarily followed by serious consequences, may be a source of trouble both to the operator and the patient and must be avoided. The pneumogastric is distinguished from the cervical cord by its greater size and by its more intimate relation to the carotid artery and jugular vein. A slight enlargement of the pneumogastric trunk that frequently is seen near the level of the third cervical vertebra may at first cause some confusion to the operator.

The removal of the superior ganglion alone with the sympathetic cord down to the middle ganglion is an operation that presents no great technical difficulties, and from this standpoint is of slight importance.—(A. E. H.)

W. S. Halsted (*Annals of Surgery*, August, 1913) reports that for the past two years or more he has tied the inferior in preference to the superior thyroid arteries, for the following reasons: The cosmetic effect is better; the wounds made for ligation of the inferior arteries are partly outside of the field of the lobectomy operations; as the inferior thyroid artery is usually larger than the superior, the effect of the ligation may be greater; the location of the inferior artery is less variable than that of the superior, which is subject to great changes because of the inconstant position of the superior pole. The ligation of the inferior thyroid artery is done as follows: A transverse incision from 4 to 4.5 cm. in length is made over the tendon of the omohyoid muscle precisely in the line of the Kocher collar incision as contemplated for the subsequent lobectomy. The fibers of the sterno-mastoid muscle are separated in the line of the common carotid artery at the level of the omohyoid tendon. The thyroid lobe is exposed behind the posterior fibers of the sternothyroid muscle and drawn inward by a retractor designed for this purpose. The common carotid is retracted outward by a similar though somewhat shorter instrument, and the layers of the fascia covering the inferior thyroid artery are divided at the level of the omohyoid tendon. Dissection is then carried out solely with two long, delicate, blunt dissectors, for the artery is sometimes at a great depth (greatest when Graves's disease has been engrafted on a colloid goiter), and the space is only large enough, as a rule, to admit one finger between the deeply concave retractors. A special aneurism needle is used for carrying the fine-silk ligatures around the artery. The wound is not drained.

Sedziak (*Zeit. f. Augenh.*, Vol. 30, p. 354), in a case of Basedow's

disease, noticed the immediate disappearance of the exophthalmos after cauterization of the hypertrophied inferior turbinated bones. Several weeks later tremor, tachycardia and goitre also disappeared. In two other cases a similar result was obtained by vibratory massage. Removal of adenoids in three children with exophthalmos caused the latter to disappear immediately.

In treating the exposed cornea in severe cases of exophthalmic goitre, H. Kuhnt (*Zeitschr. f. Augenheilk.*, April, 1912) regards decompression of the orbit by removal of the temporal orbital wall an *ultima ratio*. He does not approve of Dollinger's recommendation to perform this operation prophylactically, *i. e.*, before ulcers of the cornea exist, as it deprives the eye permanently of an important protection and may entail disagreeable consequences to the function of the external rectus muscle.

In doing a tarsorrhaphy or canthorrhaphy no attention is paid to the increasing pressure on the anterior segment of the globe in growing exophthalmus, but the aim is simply mechanical protection of the cornea. To improve this Kuhnt combines with tarsorrhaphy cutting of the temporal fascicles of fixation fibers and of the orbital septum. If the relaxation of the lids is not sufficient he adds a vertical tarsotomy at the medial lid angle. But even this relaxation of the lid in the horizontal direction does not in severe cases sufficiently relieve the pressure and protect the eyeball. The retracting tendency of the upper lid, produced by the increased tonus of the levator, still persists and exerts a permanent pressure on the eyeball. For its temporal relief Kuhnt aimed to enlarge the tarsal surface of the upper lid and to check or abolish the action of the levator on the margin of the lid and the lower half of the tarsus by severing the conjunctiva, tarsus and orbicularis parallel to, and about 3 mm. above, the inner edge from the medial to the lateral orbital margin. The writer reports the clinical history of a woman, aged 65, in whom the corneal ulcer healed after this operation. He emphasizes the importance of careful general treatment in such serious cases.

Exophthalmitis. (L.) An obsolete term for exophthalmia accompanied by inflammation of the contents of the orbit or of the capsule of Tenon.

UC SOUTHERN REGIONAL
AA 000 221 126 6